

NINTH EDITION

*See inside to start your  
digital learning experience*

Lippincott® Connect

# SURGICAL RECALL

Lorne H. Blackbourne

## MALIGNANT HYPERTHERMIA (MH)

What is it?

Inherited predisposition to an anesthetic reaction, causing uncoupling of the excitation-contraction system in skeletal muscle, which in turn causes malignant hyperthermia; hypermetabolism is fatal if untreated.

What is the incidence?

Very rare

What are the causative agents?

Volatile anesthetics, succinylcholine

What are the signs/symptoms?

Increased body temperature; hypoxia; acidosis; tachycardia,  $\uparrow$   $\text{PCO}_2$  ( $\uparrow$  end tidal  $\text{CO}_2$ )

What is the earliest sign of MH?

Rising end tidal  $\text{CO}_2$

What is the treatment?

IV dantrolene, body cooling, discontinuation of volatile anesthetics

## MISCELLANEOUS



Wolters Kluwer

are the antidotes to the  
polarizing neuromuscular

Neostigmine

Uploaded by [Medicalstudyzone.com](http://Medicalstudyzone.com)

Time: endogenous blood pse

# **SURGICAL RECALL**

## **Ninth Edition**

Recall Series Editor and Senior Editor

**Lorne H. Blackbourne, M.D., F.A.C.S.**

*Trauma, Surgical Critical Care*

*Round Rock, Texas*

*“In the operating room we can save more lives, cure more cancer, restore more function, and relieve more suffering than anywhere else in the hospital.”*

**—R. Scott Jones, M.D.**



**Wolters Kluwer**

Philadelphia • Baltimore • New York • London  
Buenos Aires • Hong Kong • Sydney • Tokyo

*Acquisitions Editor:* Matt Hauber  
*Development Editors:* Andrea Vosburgh and Kelly Horvath  
*Editorial Coordinator:* Annette Ferran  
*Marketing Manager:* Mike McMahon  
*Manufacturing Manager:* Margie Orzech  
*Design Coordinator:* Terry Mallon  
*Art Director:* Jennifer Clements  
*Compositor:* Aptara, Inc.

Ninth Edition

Two Commerce Square  
351 West Camden Street  
2001 Market Street  
Baltimore, MD 21201  
Philadelphia, PA 19103 USA

Printed in China

All rights reserved. This book is protected by copyright. No part of this book may be reproduced or transmitted in any form or by any means, including as photocopies or scanned-in or other electronic copies, or utilized by any information storage and retrieval system without written permission from the copyright owner, except for brief quotations embodied in critical articles and reviews. Materials appearing in this book prepared by individuals as part of their official duties as U.S. government employees are not covered by the above-mentioned copyright. To request permission, please contact Lippincott Williams & Wilkins at Two Commerce Square, 2001 Market Street, Philadelphia, PA 19103, via email at [permissions@lww.com](mailto:permissions@lww.com), or via website at [lww.com](http://lww.com) (products and services).

9 8 7 6 5 4 3 2 1

**Library of Congress Cataloging-in-Publication Data**

Names: Blackbourne, Lorne H., editor.

Title: Surgical recall / Recall series editor and senior editor, Lorne H. Blackbourne.

Other titles: Recall series.

Description: Eighth edition. | Philadelphia : Wolters Kluwer, [2017] |

Series: Recall series | Includes bibliographical references and index.

Identifiers: LCCN 2017040695 | ISBN 978-1-4963-7106-5

Subjects: | MESH: Surgical Procedures, Operative | Examination Questions

Classification: LCC RD37.2 | NLM WO 18.2 | DDC 617.0076—dc23

LC record available at <https://lcn.loc.gov/2017040695>

## DISCLAIMER

Care has been taken to confirm the accuracy of the information present and to describe generally accepted practices. However, the authors, editors, and publisher are not responsible for errors or omissions or for any consequences from application of the information in this book and make no warranty, expressed or implied, with respect to the currency, completeness, or accuracy of the contents of the publication. Application of this information in a particular situation remains the professional responsibility of the practitioner; the clinical treatments described and recommended may not be considered absolute and universal recommendations.

The authors, editors, and publisher have exerted every effort to ensure that drug selection and dosage set forth in this text are in accordance with the current recommendations and practice at the time of publication. However, in view of ongoing research, changes in government regulations, and the constant flow of information relating to drug therapy and drug reactions, the reader is urged to check the package insert for each drug for any change in indications and dosage and for added warnings and precautions. This is particularly important when the recommended agent is a new or infrequently employed drug.


Some drugs and medical devices presented in this publication have Food and Drug Administration (FDA) clearance for limited use in restricted research settings. It is the responsibility of the health care provider to ascertain the FDA status of each drug or device planned for use in their clinical practice.

To purchase additional copies of this book, call our customer service department at (800) 638-3030 or fax orders to (301) 223-2320. International customers

should call (301) 223-2300.

Visit Lippincott Williams & Wilkins on the Internet: <http://www.lww.com>.  
Lippincott Williams & Wilkins customer service representatives are available  
from 8:30 AM to 6:00 PM, EST.

# Dedication



**T**his book is dedicated to the memory of Leslie E. Rudolf, Professor of Surgery and Vice-Chairman of the Department of Surgery at the University of Virginia. Dr. Rudolf was born on November 12, 1927, in New Rochelle, New York. He served in the U.S. Army Counter-Intelligence Corps in Europe after World War II.

He graduated from Union College in 1951 and attended Cornell Medical College, where he graduated in 1955. He then entered his surgical residency at Peter Brigham Hospital in Boston, Massachusetts, and completed his residency there, serving as Chief Resident

Surgeon in 1961.

Dr. Rudolf came to Charlottesville, Virginia as an Assistant Professor of Surgery in 1963. He rapidly rose through the ranks, becoming Professor of Surgery and Vice-Chairman of the Department in 1974 and a Markle Scholar in Academic Medicine from 1966 until 1971. His research interests included organ and tissue transplantation and preservation. Dr. Rudolf was instrumental in initiating the Kidney Transplant Program at the University of Virginia Health Sciences Center. His active involvement in service to the Charlottesville community is particularly exemplified by his early work with the Charlottesville/Albemarle Rescue Squad, and he received the Governor's Citation for the Commonwealth of Virginia Emergency Medical Services in 1980.

His colleagues at the University of Virginia Health Sciences Center, including faculty and residents, recognized his keen interests in teaching medical students, evaluating and teaching residents, and helping the young surgical faculty. He took a serious interest in medical student education, and he would have strongly approved of this teaching manual, affectionately known as the "Rudolf" guide, as an extension of ward rounds and textbook reading.

In addition to his distinguished academic accomplishments, Dr. Rudolf was a

talented person with many diverse scholarly pursuits and hobbies. His advice and counsel on topics ranging from Chinese cooking to orchid raising were sought by a wide spectrum of friends and admirers.

This book is a logical extension of Dr. Rudolf's interests in teaching. No one book, operation, or set of rounds can begin to answer all questions of surgical disease processes; however, in a constellation of learning endeavors, this effort would certainly have pleased him.

**John B. Hanks, M.D.**  
*Professor of Surgery*  
*University of Virginia*  
*Charlottesville, Virginia*

# Editors

## **SENIOR EDITOR**

**Lorne H. Blackbourne, M.D., F.A.C.S.**

Trauma, Surgical Critical Care  
Round Rock, Texas

## **EDITOR**

**Ramon F. Cestero, M.D., F.A.C.S., F.C.C.M.**

Associate Professor of Surgery  
Fellowship Program Director  
Trauma Surgery and Surgical Critical Care  
Medical Director  
Surgical ICU  
University of Texas Health San Antonio  
San Antonio, Texas

# Preface

**T**his edition of *Surgical Recall* has been reengineered and distilled even further to allow optimal performance on BOTH the shelf exam and the wards. We have added Rapid-Fire “microvignettes” throughout the text so you can test your knowledge and also get familiar with finding the words in every vignette that are the key to unraveling the puzzle they hold.

The formula for success on the shelf exam is simple:

Disease Information (raw data facts) × Disease Recognition in a Vignette =  
SUCCESS on the SHELF exam.

The formula for success on the wards is also straightforward:

Clinical Care Knowledge × Performance = Optimal WARD SUCCESS.

This text is unique in that it holds the knowledge in a very concise manner—in a self-study, right-and-left-column format—to excel on both the Wards and the Shelf exam.

**Lorne H. Blackbourne, M.D., F.A.C.S**

*Trauma, Surgical Critical Care  
Round Rock, Texas*

# Figure Credits

## **Chapter 9 (carotid endarterectomy)**

Lawrence PF, Bell RM, Dayton MT. *Essentials of General Surgery*. 5th ed. Philadelphia, PA: Wolters Kluwer; 2012:545.

## **Chapter 13 (Nissen)**

Jarrell BE. *NMS Surgery*. 6th ed. Baltimore, MD: Wolters Kluwer; 2016.

## **Chapter 13 (Lap Nissen)**

Jarrell BE. *NMS Surgery*. 6th ed. Baltimore, MD: Wolters Kluwer; 2016.

## **Chapter 13 (Heineke–Mikulicz pyloroplasty)**

Mulholland MW. *Greenfield's Surgery*. 6th ed. Baltimore, MD: Wolters Kluwer; 2016.

## **Chapter 13 (Pringle maneuver)**

Blackbourne LH. *Advanced Surgical Recall*. 4th ed. Baltimore, MD: Wolters Kluwer; 2015.

## **Chapter 13 (percutaneous endoscopic gastrostomy)**

Blackbourne LH. *Advanced Surgical Recall*. 4th ed. Baltimore, MD: Wolters Kluwer; 2015.

## **Chapter 15 (suprapubic catheter)**

Carter P. *Lippincott Textbook for Nursing Assistants*. Philadelphia, PA: Wolters Kluwer; 2015.

## **Chapter 17 (causes of hypercalcemia mnemonic)**

Blackbourne LH. *Advanced Surgical Recall*. 4th ed. Baltimore, MD: Wolters Kluwer; 2015.

## **Chapter 37 (cricothyroidotomy)**

Britt LD, Peitzman A, Barie P. *Acute Care Surgery*. Baltimore, MD: Wolters

Kluwer; 2012.

### **Chapter 37 (pneumothorax)**

Daffner RH. *Clinical Radiology*. 4th ed. Baltimore, MD: Wolters Kluwer; 2013.

### **Chapter 37 (anterior hip dislocation)**

Blackbourne LH. *Advanced Surgical Recall*. 4th ed. Baltimore, MD: Wolters Kluwer; 2015.

### **Chapter 37 (brown recluse spider bite)**

Blackbourne LH. *Advanced Surgical Recall*. 4th ed. Baltimore, MD: Wolters Kluwer; 2015.

### **Chapter 41 (sleeve gastrectomy)**

Jarrell BE. *NMS Surgery*. 6th ed. Baltimore, MD: Wolters Kluwer; 2015.

### **Chapter 41 (gastric bypass)**

Lawrence PF, Bell RM, Dayton MT, et al. *Essentials of General Surgery*. 5th ed. Baltimore, MD: Wolters Kluwer; 2012.

### **Chapter 41 (lap-band)**

Daffner RH, Hartman M. *Clinical Radiology*. 4th ed. Baltimore, MD: Wolters Kluwer; 2013.

### **Chapter 42 (loop colostomy)**

Albo D. *Operative Techniques in Colon and Rectal Surgery*. Baltimore, MD: Wolters Kluwer; 2015.

### **Chapter 47 (sigmoid volvulus)**

Moore KL, Agur AMR, Dalley AF. *Clinically Oriented Anatomy*. 7th ed. Baltimore, MD: Wolters Kluwer; 2013.

### **Chapter 48 (anal fissure triad)**

Mulholland MW. *Greenfield's Surgery*. 6th ed. Baltimore, MD: Wolters Kluwer; 2016.

### **Chapter 51 (French system)**

Blackbourne LH. *Advanced Surgical Recall*. 4th ed. Baltimore, MD: Wolters Kluwer; 2014.

**Chapter 51 (liver segments)**

Blackbourne LH. *Advanced Surgical Recall*. 4th ed. Baltimore, MD: Wolters Kluwer; 2014.

**Chapter 55 (spiculated mass)**

Daffner RH, Hartman M. *Clinical Radiology*. 4th ed. Baltimore, MD: Wolters Kluwer Health; 2013.

**Chapter 55 (rectus abdominis flap reconstruction)**

Mulholland MW. *Greenfield's Surgery*. 6th ed. Philadelphia, PA: Wolters Kluwer; 2016.

**Chapter 56 (gastrinoma triangle)**

Mulholland MW. *Greenfield's Surgery*. 6th ed. Philadelphia, PA: Wolters Kluwer Health; 2016.

**Chapter 65 (endovascular repair)**

Zelenock GB, Huber TS, Messina LM, et al. *Mastery of Vascular and Endovascular Surgery*. Philadelphia, PA: Lippincott Williams & Wilkins; 2005.

**Chapter 68 (paronychia)**

Henretig FM, King C, eds. *Textbook of Pediatric Emergency Procedures*. Philadelphia, PA: Wolters Kluwer; 1997.

**Chapter 68 (Jersey finger)**

Miller MD, Chhabra AB, Konin J, et al. *Sports Medicine Conditions: Return to Play: Recognition, Treatment, Planning*. Philadelphia, PA: Wolters Kluwer; 2013.

**Chapter 73 (Colles' fracture)**

McKenney MG, Mangonon PC, Moylan JA. *Understanding Surgical Disease: The Miami Manual of Surgery*. Philadelphia, PA: Lippincott-Raven; 1998.

**Chapter 73 (Lachman test)**

Redrawn from Spindler KP, Wright RW. Clinical practice. Anterior cruciate ligament tear. *N Engl J Med* 2008;359:2135–2142.

**Chapter 74 (Kocher's point)**

Spector SA. *Clinical Companion in Surgery*. Philadelphia, PA: Lippincott

Williams & Wilkins; 1999.

**Chapter 74 (bitemporal hemianopsia)**

Blackbourne LH. *Advanced Surgical Recall*. 4th ed. Baltimore, MD: Wolters Kluwer; 2015.

# Contents

*Dedication*

*Editors*

*Preface*

*Figure Credits*

*Pre- and Post-Book Test: Top 100 Clinical Microvignettes for the Shelf Exam*

## **SECTION I** **OVERVIEW**

---

1. Introduction
2. Surgical Syndromes
3. Surgical Most Commons
4. Surgical Percentages
5. Surgical Instruments
6. Sutures and Stitches
7. Surgical Knot Tying
8. Procedures for the Surgical Ward and Clinic
9. Incisions
10. Surgical Positions
11. Surgical Speak
12. Preoperative
13. Surgical Operations You Should Know
14. Wounds
15. Drains and Tubes
16. Surgical Anatomy Pearls

## **SECTION II** **BACKGROUND SURGICAL INFORMATION**

---

17. Fluids and Electrolytes

18. Blood and Blood Products
19. Surgical Hemostasis
20. Common Surgical Medications
21. Complications
22. Common Causes of Ward Emergencies
23. Surgical Respiratory Care
24. Surgical Nutrition
25. Shock
26. Surgical Infection
27. Fever
28. Surgical Prophylaxis
29. Surgical Radiology
30. Anesthesia
31. Surgical Ulcers
32. Surgical Oncology

## **SECTION III**

### **GENERAL SURGERY**

---

33. GI Hormones and Physiology
34. Acute Abdomen and Referred Pain
35. Hernias
36. Laparoscopy
37. Trauma
38. Burns
39. Upper GI Bleeding
40. Stomach
41. Bariatric Surgery
42. Ostomies
43. Small Intestine
44. Appendix
45. Carcinoid Tumors
46. Fistulas
47. Colon and Rectum
48. Anus
49. Lower GI Bleeding
50. Inflammatory Bowel Disease: Crohn's Disease and Ulcerative

- Colitis
- 51. Liver
- 52. Portal Hypertension
- 53. Biliary Tract
- 54. Pancreas
- 55. Breast
- 56. Endocrine
- 57. Thyroid Gland
- 58. Parathyroid
- 59. Spleen and Splenectomy
- 60. Surgically Correctable HTN
- 61. Soft Tissue Sarcomas and Lymphomas
- 62. Skin Lesions
- 63. Melanoma
- 64. Surgical Intensive Care
- 65. Vascular Surgery

## **SECTION IV**

### **SUBSPECIALTY SURGERY**

---

- 66. Pediatric Surgery
- 67. Plastic Surgery
- 68. Hand Surgery
- 69. Otolaryngology: Head and Neck Surgery
- 70. Thoracic Surgery
- 71. Cardiovascular Surgery
- 72. Transplant Surgery
- 73. Orthopedic Surgery
- 74. Neurosurgery
- 75. Urology

*Index*

# Pre- and Post-Book Study Test for the Shelf Exam

## HOW TO USE THIS CHAPTER

First cover the right-hand side of the page (i.e., cover the answers). Then answer all the microvignettes on the left-hand side. Record the number answered correctly at the bottom of the page before reading the book (Pre-test) and then after finishing the book (Post-test). This will facilitate self-assessment of vignette subject knowledge and reveal what areas to restudy until the material is mastered.

## TOP 100 CLINICAL SURGICAL MICROVIGNETTES

|  |  |
|--|--|
| <b>1. Elderly woman, SBO, and air in biliary tract</b>               | Gallstone ileus                          |
| <b>2. Elderly woman with pain down inner aspect of thigh</b>         | Obturator hernia (Howship–Romberg sign)  |
| <b>3. Abdominal pain, hypotension, and abdominal pulsatile mass</b>  | Ruptured abdominal aortic aneurysm (AAA) |
| <b>4. Abdominal pain “out of proportion” to abdominal exam</b>       | Mesenteric ischemia                      |
| <b>5. Arm pain and syncope with arm movement</b>                     | Subclavian steal syndrome                |
| <b>6. Increasing creatinine on ACE inhibitor</b>                     | Renal artery stenosis                    |
| <b>7. Child with MIDLINE neck mass</b>                               | Thyroglossal duct cyst                   |
| <b>8. Child with LATERAL neck mass</b>                               | Branchial cleft cyst                     |
| <b>9. Crush injury and dark urine</b>                                | Myoglobinuria                            |
| <b>10. Emesis, chest pain radiating to back, and mediastinal air</b> | Boerhaave’s                              |

## SCORE YOUR ANSWERS Pre- and Post-Book Self-Assessment of Surgical Knowledge

Pre-test: \_\_\_\_/10

Post-test: \_\_\_\_/10

Cumulative: Pre-test: \_\_\_\_/10

Cumulative: Post-test: \_\_\_\_/10

|  |  |
|--|--|
| <b>11. Lower GI bleed + technetium pertechnetate scan</b>                        | Meckel's diverticulum                  |
| <b>12. Flushing, diarrhea, and right-sided heart failure</b>                     | Carcinoid                              |
| <b>13. Pneumaturia and LLQ pain</b>  | Colovesicular fistula                  |
| <b>14. Desmoid tumor, osteoma, and colon cancer</b>                              | Gardner's syndrome                     |
| <b>15. Epigastric pain radiating to back and flank ecchymosis</b>                | Hemorrhagic pancreatitis               |
| <b>16. Pancreatitis and palpable epigastric mass</b>                             | Pancreatic pseudocyst                  |
| <b>17. Liver abscess with "anchovy paste"</b>                                    | Amebic abscess                         |
| <b>18. RUQ pain, travel, and exposure to sheep</b>                               | Hydatid cyst                           |
| <b>19. Caput medusa</b>  | Portal hypertension                    |
| <b>20. 45-year-old woman with RUQ pain for 12 hours, fever, and leukocytosis</b> | Acute cholecystitis                    |
| <b>21. Elderly man with large nontender palpable gallbladder</b>                 | Pancreatic cancer (Courvoisier's sign) |
| <b>22. Female taking birth control pills with liver mass</b>                     | Hepatic adenoma                        |
| <b>23. Liver tumor with "central scar"</b>                                       | Focal nodular hyperplasia              |
| <b>24. Pancreatic mass, gallstones, diabetes, and diarrhea</b>                   | Somatostatinoma                        |
| <b>25. RUQ bruit and CHF in young adult</b>                                      | Liver hemangioma                       |
| <b>26. Excruciating pain with bowel movement</b>                                 | Anal fissure                           |
| <b>27. Abdominal pain, diarrhea, and anal fistulae</b>                           | Crohn's disease                        |
| <b>28. EKG with "peaked" T waves</b>   | Hyperkalemia                           |
| <b>29. Buccal mucosa with pigmentation</b>                                       | Peutz-Jeghers syndrome                 |

## SCORE YOUR ANSWERS Pre- and Post-Book Self-Assessment of Surgical Knowledge

Pre-test: \_\_\_\_/19

Post-test: \_\_\_\_/19

Cumulative: Pre-test: \_\_\_\_/29

Cumulative: Post-test: \_\_\_\_/29

|   |  |
|---|--|
| <b>30. LLQ pain, fever, and change in bowel habits</b>  | Diverticulitis                             |
| <b>31. Elevated urine 5-HIAA</b>  | Carcinoid                                  |
| <b>32. Institutionalized, abdominal pain, vomiting, and distention, with proximal colonic dilation</b>  | Sigmoid volvulus                           |
| <b>33. Infant with projectile vomiting</b>  | Pyloric stenosis                           |
| <b>34. Newborn with failure to pass meconium in first 24 hours</b>  | Hirschsprung's                             |
| <b>35. Infant with bilious vomiting</b>   | Malrotation                                |
| <b>36. Newborn with abdominal defect and umbilical cord on sac</b>  | Omphalocele                                |
| <b>37. Teenager with knee pain and "onion skinning" on x-ray</b>  | Ewing's sarcoma                            |
| <b>38. Pulmonary capillary wedge pressure &lt;18, CXR with bilateral pulmonary infiltrates, and PaO<sub>2</sub>:FiO<sub>2</sub> ratio &lt;300</b> | Acute respiratory distress syndrome (ARDS) |
| <b>39. Increased peak airway pressure, low urine output, and urinary bladder &gt;25 mm Hg</b>   | Abdominal compartment syndrome             |
| <b>40. Newborn with inability to "pass an NGT"</b>  | Esophageal atresia                         |
| <b>41. Traumatic blinding in one eye followed by blindness in the contralateral eye 2 weeks later</b>   | Sympathetic ophthalmia                     |
| <b>42. Miotic pupil, ptosis, and anhidrosis</b>   | Horner's syndrome                          |
| <b>43. Traumatic head injury, conscious in ER followed by unconsciousness</b>   | Epidural hematoma ("lucid interval")       |
| <b>44. "Worst headache of my life"</b>  | Subarachnoid hemorrhage                    |
| <b>45. Hematuria, flank pain, and abdominal mass (palpable)</b>   | Renal cell carcinoma                       |

## SCORE YOUR ANSWERS Pre- and Post-Book Self-Assessment of Surgical Knowledge

Pre-test: \_\_\_\_/16

Post-test: \_\_\_\_/16

Cumulative: Pre-test: \_\_\_\_/45

Cumulative: Post-test: \_\_\_\_/45

|  |                |
|--|----------------|
| <b>46. 60-year-old white man with painless hematuria</b>               | Bladder cancer |
| <b>47. RUQ pain, jaundice, and fever</b>                               | Cholangitis    |
| <b>48. Epigastric pain radiating to back, with nausea and vomiting</b> | Pancreatitis   |

|  |                                 |
|--|---------------------------------|
| <b>49. Chest pain radiating to back and described as a “tearing” pain</b>                      | Aortic dissection               |
| <b>50. 40-year-old man with tachycardia/hypertension and confusion on postoperative day #2</b> | Alcohol withdrawal              |
| <b>51. Marfanoid body habitus and mucosal neuromas</b>   | MEN II-b                        |
| <b>52. Psammoma bodies</b>   | Papillary thyroid cancer        |
| <b>53. Sulfur granules</b>   | <i>Actinomyces</i> infection    |
| <b>54. Thyroid tumor with AMYLOID tissue</b>   | Thyroid medullary cancer        |
| <b>55. PALPABLE neck tumor and hypercalcemia</b>   | Parathyroid cancer              |
| <b>56. Hypertension, diaphoresis (episodic), and palpitations</b>                              | Pheochromocytoma                |
| <b>57. Jejunal ulcers</b>  | Zollinger–Ellison syndrome      |
| <b>58. Pituitary tumor, pancreatic tumor, and parathyroid tumor</b>                            | MEN-I                           |
| <b>59. Necrotizing migratory erythema</b>  | Glucagonoma                     |
| <b>60. Medullary thyroid cancer, pheochromocytoma, and hyperparathyroidism</b>                 | MEN-IIa                         |
| <b>61. Hypokalemia refractory to IV potassium supplementation</b>                              | Hypomagnesemia                  |
| <b>62. Newborn with pneumatosis</b>  | Necrotizing enterocolitis (NEC) |

## SCORE YOUR ANSWERS Pre- and Post-Book Self-Assessment of Surgical Knowledge

Pre-test: \_\_\_\_/17 Post-test: \_\_\_\_/17  
Cumulative: Pre-test: \_\_\_\_/62 Cumulative: Post-test: \_\_\_\_/62

|  |                                      |
|--|--------------------------------------|
| <b>63. Child with abdominal mass that crosses midline</b>                            | Neuroblastoma                        |
| <b>64. Child &lt;4 years of age with abdominal tumor that does NOT cross midline</b> | Wilms' tumor                         |
| <b>65. “Currant jelly” stools and abdominal colic</b>                                | Intussusception                      |
| <b>66. Femur fracture, respiratory failure, petechiae, and mental status changes</b> | Fat embolism                         |
| <b>67. Hearing loss, tinnitus, and vertigo</b>                                       | Ménière's disease                    |
| <b>68. Adolescent boy with nasal obstruction and recurrent epistaxis</b>             | Juvenile nasopharyngeal angiofibroma |

|   |  |
|---|--|
| <b>69. Child &lt;5 years of age sitting upright and drooling, with “hot-potato” voice</b>               | Epiglottitis                           |
| <b>70. Angina, syncope, and CHF</b>   | Aortic stenosis                        |
| <b>71. Tobacco use, asbestos exposure, and pleuritic chest pain</b>                                     | Mesothelioma                           |
| <b>72. Supracondylar fracture and contracture of forearm flexors</b>                                    | Volkman's contracture                  |
| <b>73. Tibia fracture, “pain out of proportion,” pain on passive foot movement, and palpable pulses</b> | Compartment syndrome                   |
| <b>74. 25-year-old man with liver mass with fibrous septae and NO history of cirrhosis or hepatitis</b> | Fibrolamellar hepatocellular carcinoma |
| <b>75. EKG with flattening of T waves and U waves</b>   | Hypokalemia                            |
| <b>76. Central pontine myelinolysis</b>   | Too-rapid correction of hyponatremia   |
| <b>77. Polydipsia, polyuria, and constipation</b>   | Hypercalcemia                          |

## SCORE YOUR ANSWERS Pre- and Post-Book Self-Assessment of Surgical Knowledge

Pre-test: \_\_\_\_/15

Post-test: \_\_\_\_/15

Cumulative: Pre-test: \_\_\_\_/77

Cumulative: Post-test: \_\_\_\_/77

|  |   |
|--|---|
| <b>78. Factor VIII deficiency</b>  | Hemophilia A  |
| <b>79. Abdominal pain, fever, hypotension, HYPERkalemia, and HYPONatremia</b>        | Adrenal insufficiency (addisonian crisis)             |
| <b>80. Massive urine output and HYPERnatremia</b>                                    | Diabetes insipidus                                    |
| <b>81. Increased urine osmolality, HYPONatremia, and low serum osmolality</b>        | SIADH   |
| <b>82. IV antibiotics, fever, diarrhea</b>   | <i>Clostridium difficile</i> pseudomembranous colitis |
| <b>83. Bleeding gums and wound dehiscence</b>  | Vitamin C deficiency                                  |
| <b>84. Fever, central line, and HYPERglycemia</b>                                    | Central line infection                                |
| <b>85. Appendectomy followed by fever and abdominal pain on postoperative day #7</b> | Peritoneal abscess                                    |
| <b>86. Advancing crepitus, fever, and blood blisters</b>                             | Necrotizing fasciitis                                 |
| <b>87. High INTRAoperative fever</b>   | Malignant hyperthermia                                |
| <b>88. Confusion, ataxia, and ophthalmoplegia</b>                                    | Wernicke's encephalopathy                             |
| <b>89. Tracheal deviation, decreased breath</b>                                      | Tension pneumothorax                                  |

sounds, and hyperresonance

|   |                        |
|---|------------------------|
| <b>90. Hypotension, decreased heart sounds, and JVD</b>           | Pericardial tamponade  |
| <b>91. Four ribs broken in two places and pulmonary contusion</b> | Flail chest            |
| <b>92. Otorrhea (clear) and Battle's sign</b>                     | Basilar skull fracture |
| <b>93. Ulcer and decreased pain with food</b>                     | Duodenal ulcer         |

## SCORE YOUR ANSWERS Pre- and Post-Book Self-Assessment of Surgical Knowledge

Pre-test: \_\_\_\_/16

Post-test: \_\_\_\_/16

Cumulative: Pre-test: \_\_\_\_/93

Cumulative: Post-test: \_\_\_\_/93

|  |                             |
|--|-----------------------------|
| <b>94. Vomiting, retching, and epigastric pain</b>                               | Mallory–Weiss tear          |
| <b>95. Fever on postoperative day #1, with “bronze” weeping, tender wound</b>    | Clostridial wound infection |
| <b>96. Hematochezia and tenesmus</b>   | Rectal cancer               |
| <b>97. Upper GI bleed, jaundice, and RUQ pain</b>                                | Hemobilia                   |
| <b>98. Gallstones, epigastric pain radiating to back, and nausea</b>             | Gallstone pancreatitis      |
| <b>99. 18-year-old woman with bloody nipple discharge</b>                        | Ductal papilloma            |
| <b>100. Irritability, diaphoresis, weakness, tremulousness, and palpitations</b> | Insulinoma                  |

## SCORE YOUR ANSWERS Pre- and Post-Book Self-Assessment of Surgical Knowledge

Pre-test: \_\_\_\_/7

Post-test: \_\_\_\_/7

Total number of microvignettes answered correctly:

Pre-test: \_\_\_\_/100

Post-test: \_\_\_\_/100

# SECTION I

## Overview

# Chapter 1 Introduction

## OPERATING ROOM FAQs

### **What if I have to sneeze?**

Back up STRAIGHT back; do not turn your head, as the sneeze exits through the sides of your mask!

### **What if I feel faint?**

Do not be a hero—say, “I feel faint. May I sit down?” This is no big deal and is very common (*Note:* It helps to always eat before going to the O.R.)

### **What should I say when I first enter the O.R.?**

Introduce yourself as a student; state that you have been invited to scrub and ask if you need to get out your gloves and/or gown

### **Should I wear my ID tag into the O.R.?**

Yes

### **Can I wear nail polish?**

Yes, as long as it is not chipped

### **Can I wear my rings and my watch when scrubbed in the O.R.?**

No

### **Can I wear earrings?**

No

### **When scrubbed, is my back sterile?**

No

### **When in the surgical gown, are my underarms sterile?**

No; do not put your hands under your arms

**How far down my gown is considered part of the sterile field?**

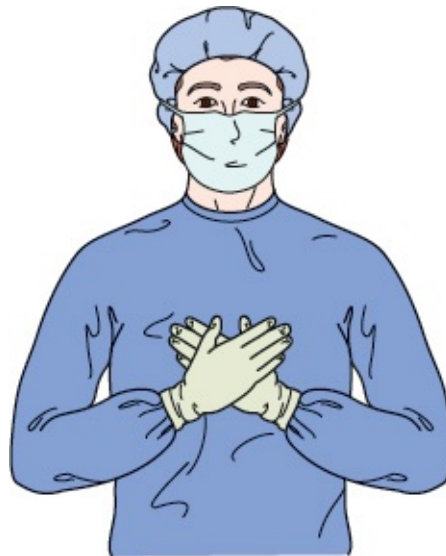Just to your waist

**How far up my gown is considered sterile?**

Up to the nipples

**How do I stand if I am waiting for the case to start?**

Hands together in front above your waist



**Can I button up a surgical gown (when I am not scrubbed!) with bare hands?**

Yes (**Remember:** the back of the gown is NOT sterile)

**How many pairs of gloves should I wear when scrubbed?**

2 (2 layers)

**What is the normal order of sizes of gloves: small pair, then larger pair?**

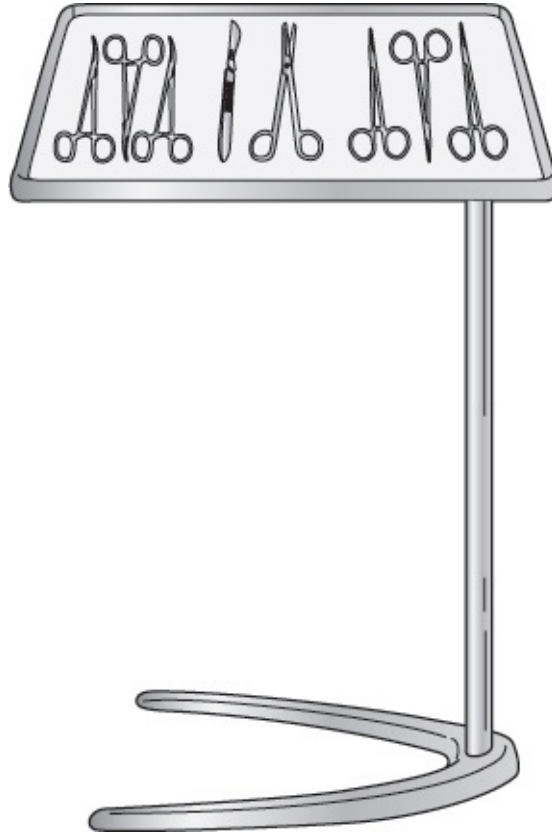
No; usually the order is a larger size followed by a smaller size (e.g., men commonly wear a size #8 covered by a size #7.5; women commonly wear a size #7 covered by a size #6.5)

**What items comprise the sterile field in the operating room?**

Instrument table, Mayo tray, and anterior drapes on the patient

**What is the tray with the instruments called?**

Mayo tray



**Can I grab things off the Mayo tray?**

No; ask the scrub nurse/tech for permission

**How do you remove blood with a laparotomy pad (“lap pad”)?**

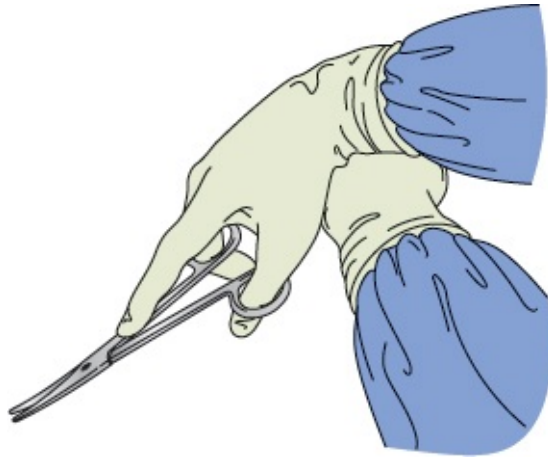
*Dab*; do not wipe, because wiping removes platelet plugs

**Can you grab the skin with DeBakey pickups?**

NO; pickups for the skin must have teeth (e.g., Adson, rat-tooth) because it is “better to cut the skin than crush it”

**How should you cut the sutures after tying a knot?**

- . Rest the cutting hand on the noncutting hand
- . Slip the scissors down to the knot and then cant the scissors at a 45° angle so you do not cut the knot itself



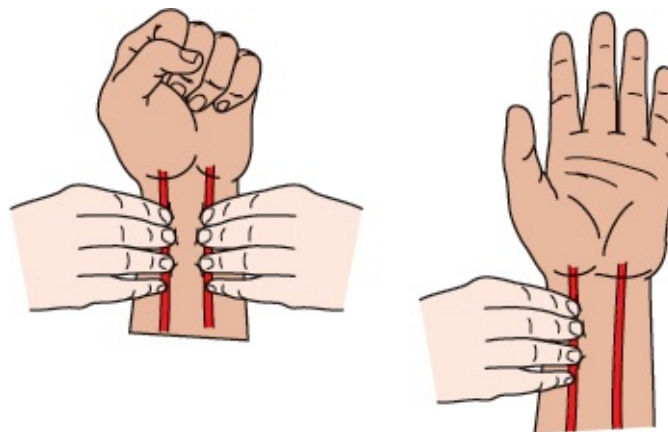
### **What should you do when you are scrubbed and someone is tying a suture?**

Ask the scrub nurse for a pair of suture scissors, so you are ready if you are asked to cut the sutures

## **SURGERY SIGNS, TRIADS, ETC. YOU SHOULD KNOW**

### **What is the Allen's test?**

Test for patency of ulnar artery prior to placing a radial arterial line or performing an ABG: Examiner occludes both ulnar and radial arteries with fingers as patient makes fist; patient opens fist while examiner releases ulnar artery occlusion to assess blood flow to hand (28% of pop. have complete radial artery dominance!)



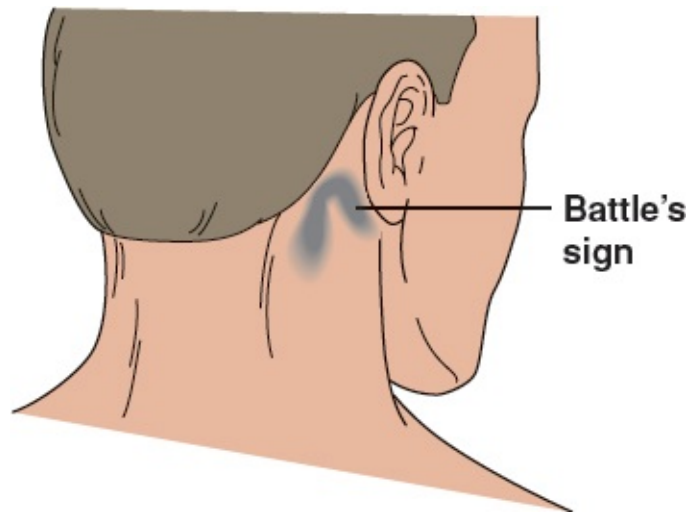
**Define the following terms:**

### **Ballance's sign**

Constant dullness to percussion in the left flank/LUQ and resonance to percussion in the right flank seen with splenic rupture/hematoma

### **Battle's sign**

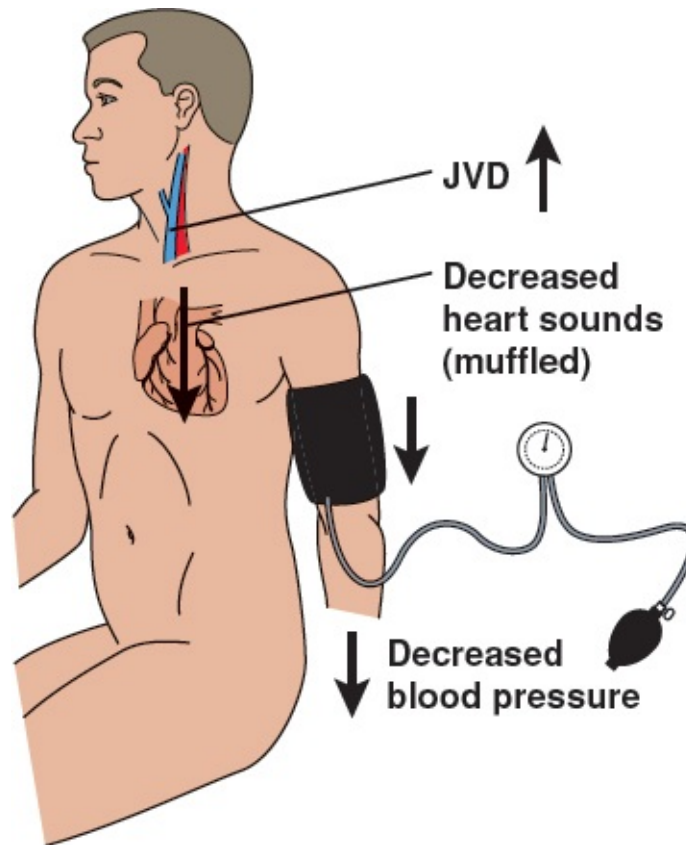
Ecchymosis over the mastoid process in patients with basilar skull fractures



### **Beck's triad**

Seen in patients with cardiac tamponade:

1. JVD
2. Decreased or muffled heart sounds
3. Decreased blood pressure



### **Blumer's shelf**

Metastatic disease to the rectouterine (pouch of Douglas) or rectovesical pouch creating a "shelf" that is palpable on rectal examination

### **Carcinoid triad**

Seen with carcinoid syndrome (Think: **"FDR"**):

1. **F**lushing
2. **D**iarrhea
3. **R**ight-sided heart failure

### **Charcot's triad**

Seen with cholangitis:

1. Fever (chills)
  2. Jaundice
  3. Right upper quadrant pain
- (Pronounced "char-cohs")

### **Chvostek's sign**

Twitching of facial muscles upon tapping the facial nerve in patients with hypocalcemia (Think: **CH**vostek's = **CH**eck)

### **Courvoisier's law**

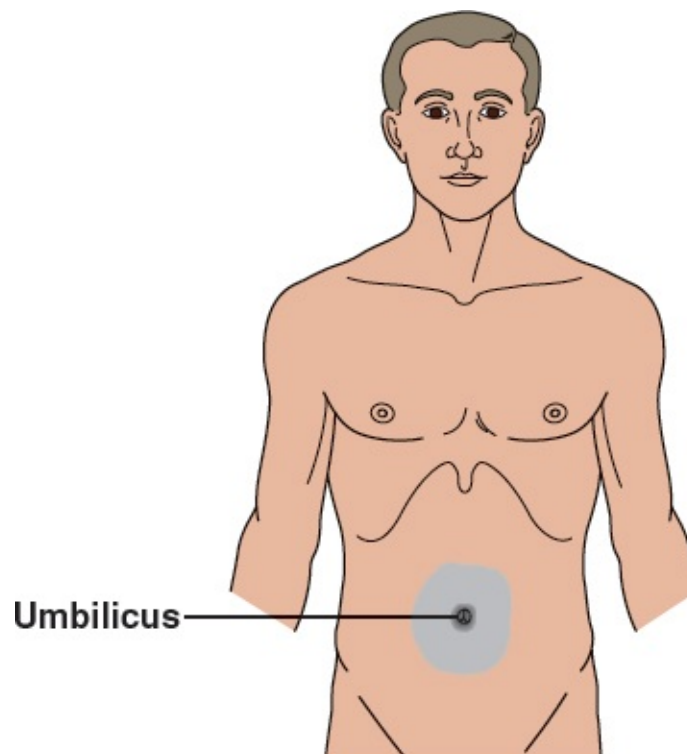
Enlarged nontender gallbladder seen with obstruction of the common bile duct, most commonly with pancreatic cancer

**Note:** Not seen with gallstone obstruction because the gallbladder is scarred secondary to chronic cholelithiasis

(Pronounced "koor-vwah-ze-ay")

### **Cullen's sign**

Bluish discoloration of the periumbilical area due to retroperitoneal hemorrhage tracking around to the anterior abdominal wall through fascial planes (e.g., acute hemorrhagic pancreatitis)



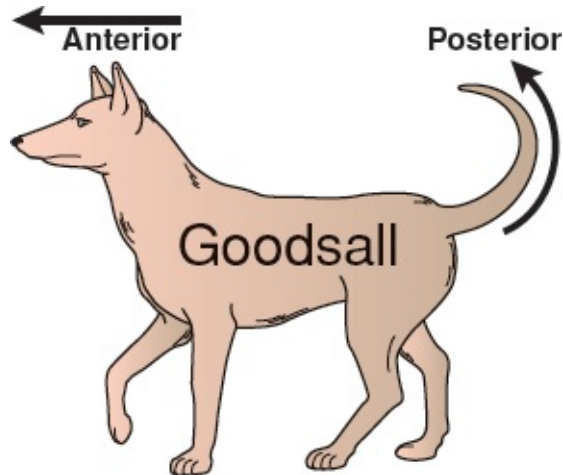
### **Cushing's triad**

Signs of increased intracranial pressure:

1. Hypertension
2. Bradycardia
3. Irregular respirations

### **Goodsall's rule**

Anal fistulae course in a straight path anteriorly and a curved path posteriorly from midline (Think of a dog with a straight anterior nose and a curved posterior tail)



### **Hamman's sign/crunch**

Crunching sound on auscultation of the heart resulting from emphysematous mediastinum; seen with Boerhaave's syndrome, pneumomediastinum, etc.

### **Howship-Romberg sign**

Pain along the inner aspect of the thigh; seen with an obturator hernia as the result of nerve compression

### **McBurney's point**

One third the distance from the anterior iliac spine to the umbilicus on a line connecting the two

### **Meckel's diverticulum rule of 2s**

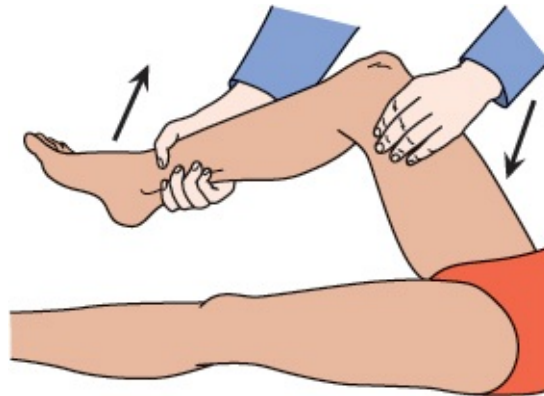
2% of the population have a Meckel's diverticulum, 2% of those are symptomatic, and they occur within  $\approx 2$  feet of the ileocecal valve

### **Murphy's sign**

Cessation of inspiration while palpating under the right costal margin; the patient cannot continue to inspire deeply because it brings an inflamed gallbladder under pressure (seen in acute cholecystitis)

### **Obturator sign**

Pain upon internal rotation of the leg with the hip and knee flexed; seen in patients with appendicitis/pelvic abscess



### **Pheochromocytoma SYMPTOMS triad**

Think of the first three letters in the word pheochromocytoma—“**P-H-E**”:

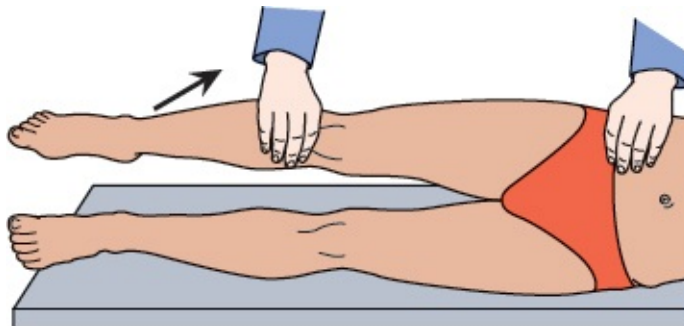
**P**alpitations

**H**eadache

**E**pisodic diaphoresis

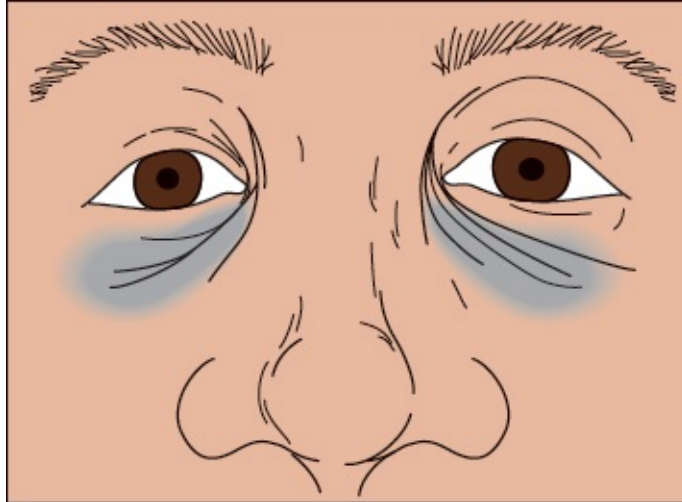
### **Psoas sign**

Pain elicited by extending the hip with the knee in full extension, seen with appendicitis and psoas inflammation



### **Raccoon eyes**

Bilateral black eyes as a result of basilar skull fracture



### **Reynolds' pentad**

1. Fever
2. Jaundice
3. Right upper quadrant pain
4. Mental status changes
5. Shock/sepsis

Thus, Charcot's triad plus #4 and #5; seen in patients with **suppurative** cholangitis

### **Rovsing's sign**

Palpation of the left lower quadrant resulting in pain in the right lower quadrant; seen in appendicitis

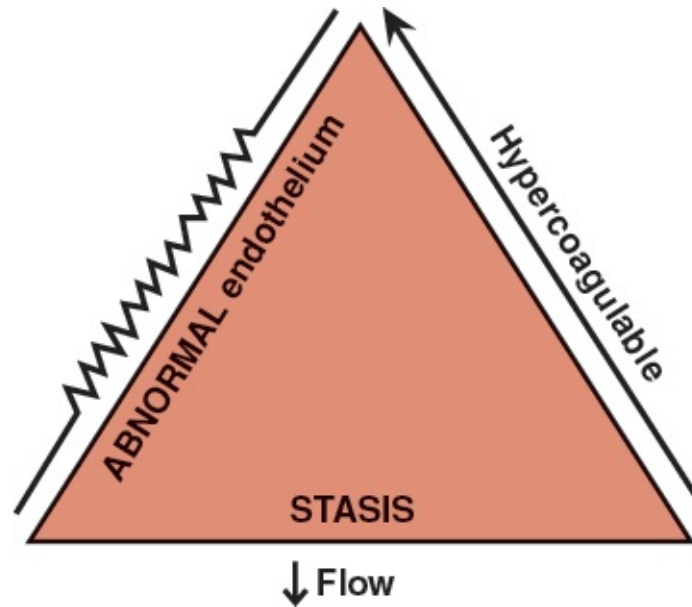
### **Virchow's node**

Metastatic tumor to left supraclavicular node (classically due to gastric cancer)

### **Virchow's triad**

Risk factors for thrombosis:

1. Stasis
2. Abnormal endothelium
3. Hypercoagulability



### **Trousseau's sign**

Carpal spasm after occlusion of blood to the forearm with a BP cuff in patients with hypocalcemia

### **Valentino's sign**

Right lower quadrant pain from a perforated peptic ulcer due to succus/pus draining into the RLQ

### **Whipple's triad**

Evidence for insulinoma:

1. Hypoglycemia ( $<50$ )
2. CNS and vasomotor symptoms (e.g., syncope, diaphoresis)
3. Relief of symptoms with administration of glucose

## Chapter 2 Surgical Syndromes

### **What is afferent loop syndrome?**

Obstruction of the afferent loop of a Billroth II gastrojejunostomy

### **What does ARDS stand for?**

**A**cute **R**espiratory **D**istress **S**yndrome (poor oxygenation caused by alveolar and capillary inflammation)

### **What is blind loop syndrome?**

Bacterial overgrowth of intestine caused by stasis

### **What is Boerhaave's syndrome?**

Esophageal perforation

### **What is Budd–Chiari syndrome?**

Thrombosis of hepatic veins

### **What is carcinoid syndrome?**

Syndrome of “**B FDR**”:

**B**ronchospasm

**F**lushing

**D**iarrhea

**R**ight-sided heart failure (caused by factors released by carcinoid tumor)

### **What is compartment syndrome?**

Compartmental hypertension caused by edema, resulting in muscle necrosis of the lower extremity, because the fascial compartments do NOT stretch, often seen in the calf; patient may have a distal pulse

### **What is Cushing's syndrome?**

Excessive cortisol production

**What is dumping syndrome?**

Delivery of a large amount of hyperosmolar chyme into the small bowel, usually after vagotomy and a gastric drainage procedure (pyloroplasty/gastrojejunostomy); results in autonomic instability, abdominal pain, and diarrhea

**What is Fitz–Hugh–Curtis syndrome?**

Perihepatic gonorrhea infection (perihepatic adhesions)

**What is Gardner's syndrome?**

GI polyps and associated findings of Sebaceous cysts, Osteomas, and Desmoid tumors (**SOD**); polyps have high malignancy potential (Think: A **Gardner** plants **SOD**)

**What is HITT syndrome?**

**H**eparin-**I**nduced **T**hrombocytopenic **T**hrombosis syndrome: Heparin-induced platelet antibodies cause platelets to thrombose vessels, often resulting in loss of limb or life

**What is Leriche's syndrome?**

Claudication of buttocks and thighs, Impotence, Atrophy of legs (seen with iliac occlusive disease) (Think: **CIA**)

**What is Mallory–Weiss syndrome?**

Postemesis/retching tears in the gastric mucosa (near gastroesophageal junction)

**What is Mendelson's syndrome?**

Chemical pneumonitis after aspiration of gastric contents

**What is Mirizzi's syndrome?**

Extrinsic obstruction of the common hepatic bile duct from a gallstone in the gallbladder or cystic duct

**What is Munchausen's syndrome?**

Self-induced illness; patient desires the attention comfort of the “sick” role

**What is Ogilvie's syndrome?**

Massive **nonobstructive** colonic dilatation

**What is Peutz–Jeghers syndrome?**

Benign GI polyps and buccal pigmentation (Think: **P**eutz = **P**igmentation)

**What is RED reaction syndrome?**

Syndrome of rapid vancomycin infusion, resulting in skin erythema

**What is refeeding syndrome?**

Hypokalemia, hypomagnesemia, and hypophosphatemia after refeeding a starved patient

**What is Rendu–Osler–Weber (ROW) syndrome?**

Syndrome of GI tract telangiectasia/  
A-V malformations

**What is short-gut syndrome?**

Malnutrition resulting from <200 cm of viable small bowel

**What is SIADH?**

Syndrome of **I**nappropriate **A**nti**D**iuretic **H**ormone (Think: **I**nappropriately **I**ncreased ADH)

**What is superior vena cava (SVC) syndrome?**

Obstruction of the SVC (e.g., by tumor, thrombosis)

**What is thoracic outlet syndrome?**

Compression of the structures exiting from the thoracic outlet

**What is toxic shock syndrome?**

*Staphylococcus aureus* toxin-induced syndrome marked by fever, hypotension, organ failure, and **rash** (desquamation—especially palms and soles)

**What is Trousseau's syndrome?**

Syndrome of deep venous thrombosis (DVT) associated with carcinoma

**What is Zollinger–Ellison syndrome?**

Gastrinoma and PUD

## Chapter 3 Surgical Most Commons

**What is the most common:**

**Type of melanoma?**

Superficial spreading

**Type of breast cancer?**

Infiltrating ductal

**Site of breast cancer?**

Upper outer quadrant

**Vessel involved with a bleeding duodenal ulcer?**

Gastroduodenal artery

**Cause of common bile duct obstruction?**

Choledocholithiasis

**Cause of small bowel obstruction (SBO) in adults in the United States?**

Postoperative peritoneal adhesions

**Cause of SBO in children?**

Hernias

**Cause of emergency abdominal surgery in the United States?**

Acute appendicitis

**Electrolyte deficiency causing ileus?**

Hypokalemia

**Cause of blood transfusion resulting in death?**

Clerical error (wrong blood types)

**Site of distant metastasis of sarcoma?**

Lungs (hematogenous spread)

**Position of anal fissure?**

Posterior

**Acute pancreatitis?**

Gallstones

**Chronic pancreatitis?**

Alcohol

**Cause of large bowel obstruction?**

Colon cancer

**Cause of fever <48 postoperative hours?**

Atelectasis

**Bacterial cause of urinary tract infection (UTI)?**

*Escherichia coli*

**Abdominal organ injured in blunt abdominal trauma?**

Liver (not the spleen, as noted in recent studies!)

**Benign tumor of the liver?**

Hemangioma

**Malignancy of the liver?**

Metastasis

**Pneumonia in the ICU?**

Gram-negative bacteria

**Cause of epidural hematoma?**

Middle meningeal artery injury

**Cause of lower GI bleeding?**

Upper GI bleeding

**Cancer in females?**

Breast cancer

**Cancer in males?**

Prostate cancer

**Type of cancer causing DEATH in males and females?**

LUNG cancer

**Cause of free peritoneal air?**

Perforated peptic ulcer disease

**Cause of death ages 1 to 44?**

TRAUMA

## Chapter 4 Surgical Percentages

**What percentage of people in the United States will develop acute appendicitis?**

≈7%

**What is the acceptable percentage of normal appendices removed with the preoperative diagnosis of appendicitis?**

Up to 20%; it is better to remove some normal appendices than to miss a case of acute appendicitis, which could result in a ruptured appendix

**In what percentage of cases does a upper gastrointestinal bleed stop spontaneously?**

≈80%

**What percentage of American women develop breast cancer?**

12%

**What percentage of patients with gallstones will have radiopaque gallstones on abdominal x ray (AXR)?**

≈10%

**What percentage of kidney stones are radiopaque on AXR?**

≈90%

**At 6 weeks, wounds have achieved what percentage of their total tensile strength?**

≈90%

**What percentage of the population have a Meckel's diverticulum?**

2%

**One unit of packed RBCs increases the hematocrit by how much?**

3%

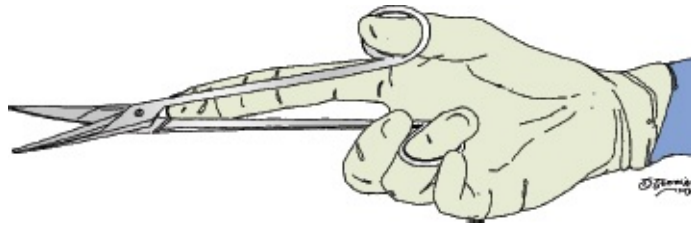
**Additional 1 liter by nasal cannula increases  $\text{FIO}_2$  by how much?**

3%

# Chapter 5 Surgical Instruments

**How should a pair of scissors/needle driver/clamp be held?**

With the thumb and **fourth** finger, using the index finger to steady

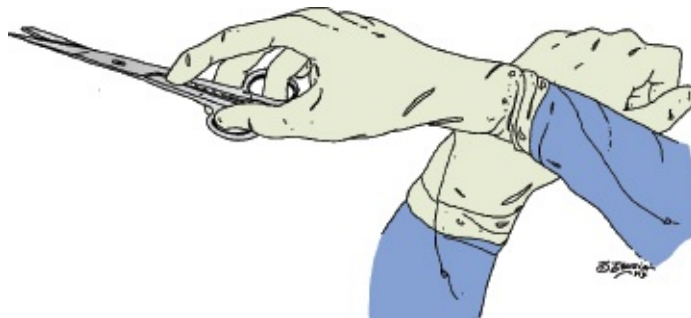


**Is it better to hold the skin with a DeBakey or an Adson, or toothed, forceps?**

Better to use an Adson, or toothed, pickup because it is better to cut the skin rather than crush it!

**What helps steady the scissor or Bovie hand?**

Resting it on the opposite hand

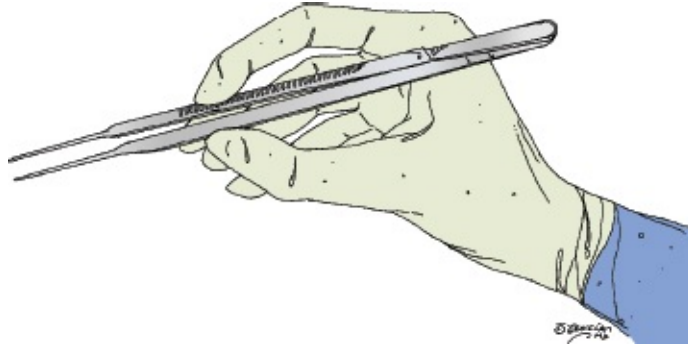


**What can be done to guarantee that you do not cut the knot when cutting sutures?**

Slide the scissors down to the knot, then turn the scissors at a 45-degree angle, and cut

**How should a pair of forceps be held?**

Like a pencil



**What are forceps also known as?**

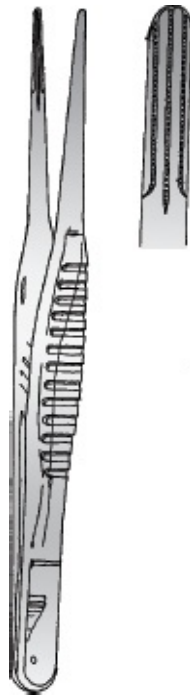
“Pickups”

**Identify the following instruments:**

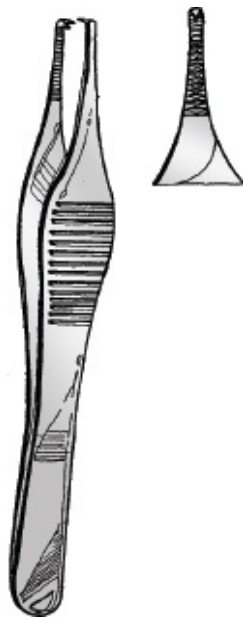Forceps



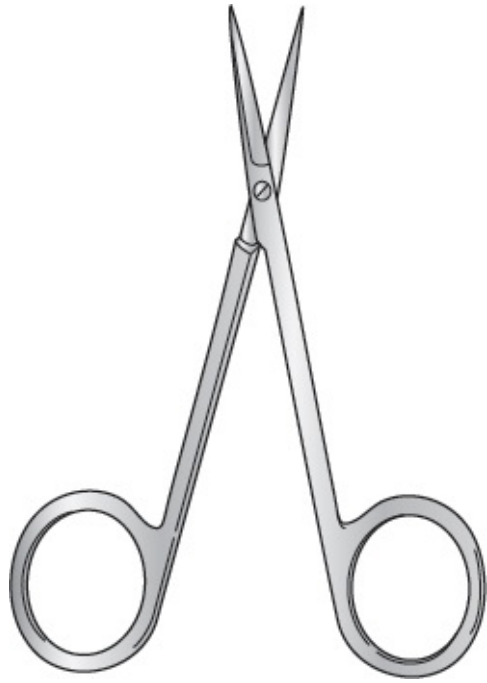
DeBakey pickup



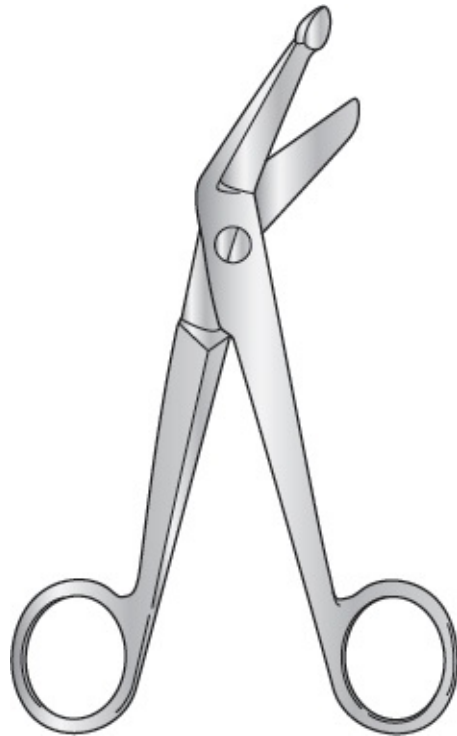
Adson pickup



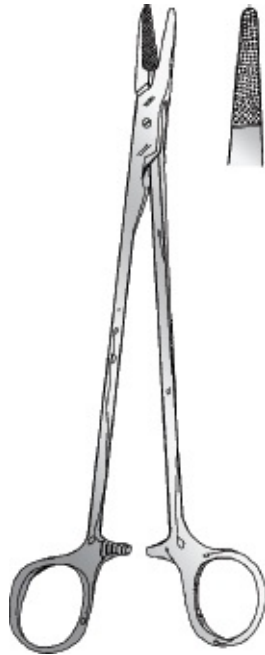
Iris scissors



Bandage scissors



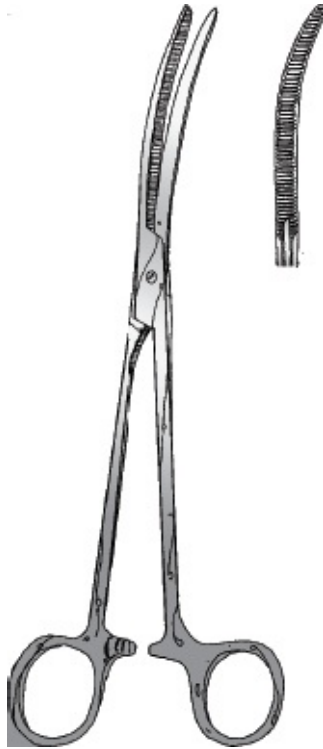
Needle driver



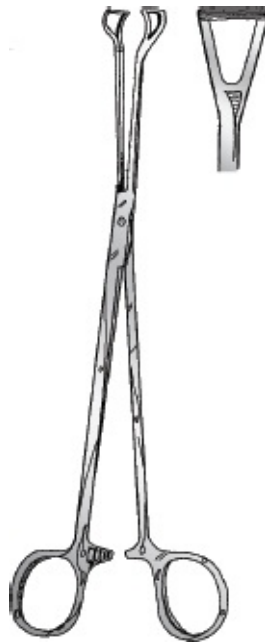
Right-angle clamp



Kelly clamp



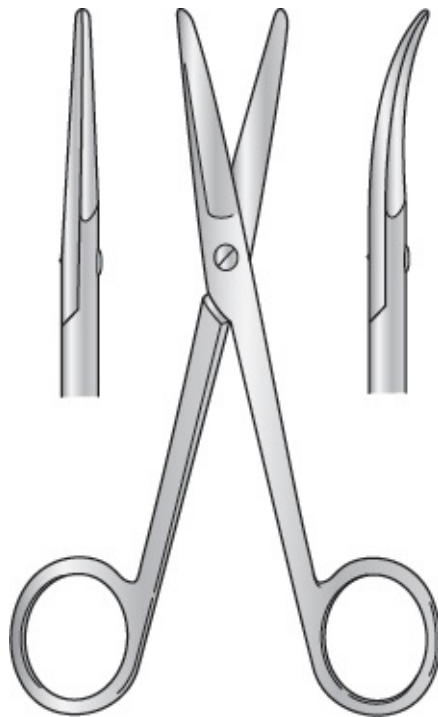
Babcock clamp



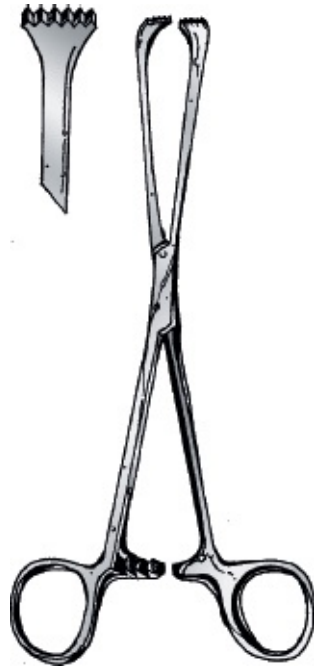Metzenbaum scissors



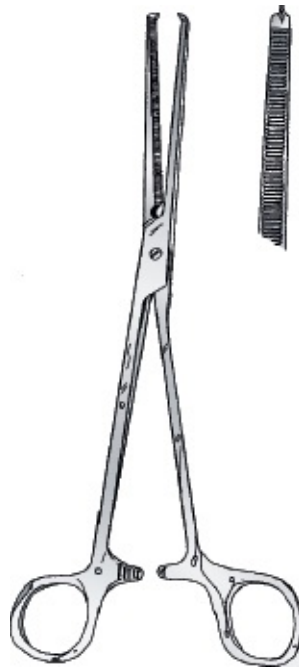
Mayo scissors (heavy scissors)



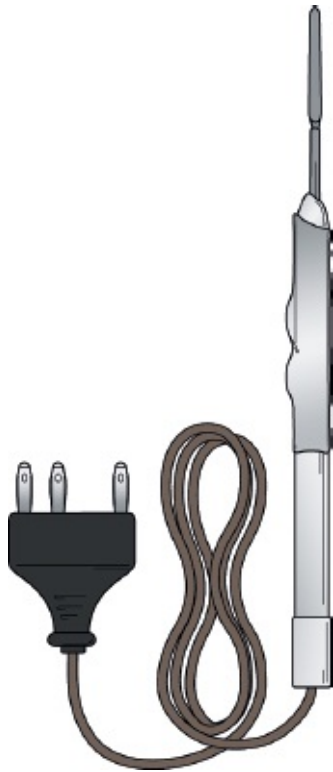
Allis clamp



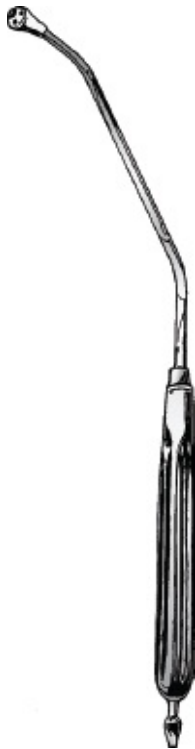Kocher clamp, for very thick tissue (e.g., fascia)



Bovie electrocautery



Yankauer suction (sucker)



**Define the following scalpel blades:**

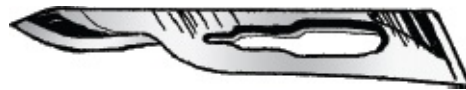Number 10



Number 11



Number 15



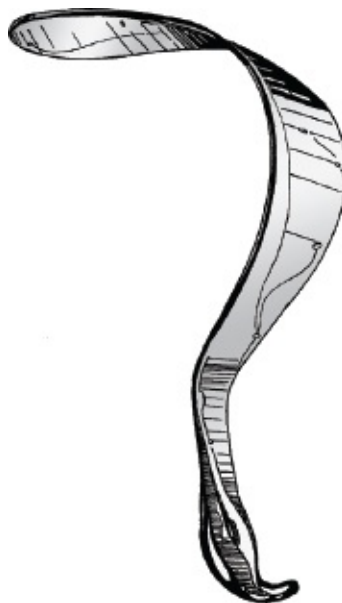## RETRACTORS (YOU WILL GET TO KNOW THEM WELL!)

**What does it mean to “toe in” the retractor?**

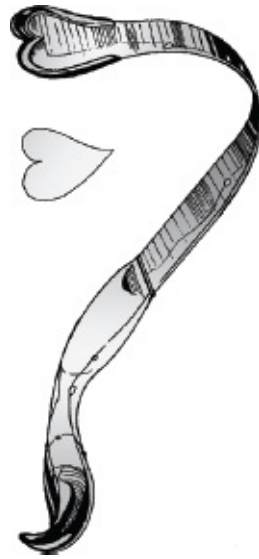
To angle the tip of the retractor in by angling the retractor handle up

**Identify the following retractors:**

Deaver retractor



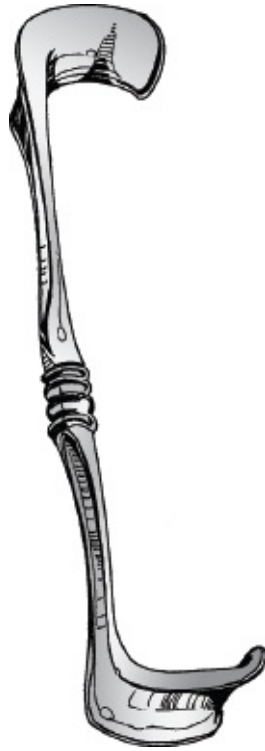Sweetheart retractor (Harrington)



Army–Navy retractor




Richardson retractor, also known as a “RICH”



**What is a “malleable” retractor?**

Metal retractor that can be bent to customize to the situation at hand



# Chapter 6 Sutures and Stitches

## SUTURE MATERIALS

### ■ General Information

#### **What is a suture?**

Any strand of material used to ligate blood vessels or to approximate tissues

#### **How are sutures sized?**

By diameter; stated as a number of 0's: the higher the number of 0's, the smaller the diameter (e.g., 2-0 suture has larger diameter than 5-0 suture)

#### **Which is thicker, 1-0 suture or 3-0 suture?**

1-0 suture (pronounced "one oh")

### ■ Classification

#### **What are the two most basic suture types?**

Absorbable and nonabsorbable

#### **What is an absorbable suture?**

Suture that is completely broken down by the body (dissolving suture)

#### **What is a nonabsorbable suture?**

Suture is not broken down (permanent suture)

### ■ Sutures

## ► *Catgut*

### **What are “catgut” sutures made of?**

Purified collagen fibers from the intestines of healthy cows or sheep (sorry, no cats)

### **What are the two types of gut sutures?**

Plain and chromic

What is the difference between plain and chromic gut?

Chromic gut is treated with chromium salts (chromium trioxide), which results in more collagen crosslinks, making the suture more resistant to breakdown by the body

## ► *Vicryl® Suture*

### **What is it?**

Absorbable, braided, and multifilamentous copolymer of lactide and glycolide

### **How long does it retain its strength?**

60% at 2 weeks, 8% at 4 weeks

### **Should you ever use PURPLE-colored Vicryl® for skin closure?**

NO—it may cause purple tattooing

## ► *PDS®*

### **What is it?**

Absorbable, monofilament polymer of polydioxanone (absorbable fishing line)

### **How long does it maintain its tensile strength?**

70% to 74% at 2 weeks, 50% to 58% at 4 weeks, 25% to 41% at 6 weeks

### **How long does it take to complete absorption?**

180 days (6 months)

**What is silk?**

Braided protein filaments spun by the silkworm larva; known as a nonabsorbable suture

**What is Prolene®?**

Nonabsorbable suture (used for vascular anastomoses, hernias, abdominal fascial closure)

**What is nylon?**

Nonabsorbable “fishing line”

**What is monocryl?**

Absorbable monofilament

**What kind of suture should be used for the biliary tract or the urinary tract?**

ABSORBABLE—otherwise the suture will end up as a nidus for stone formation!

## WOUND CLOSURE

### ■ General Information

**What are the three types of wound healing?**

- . Primary closure (intention)
- . Secondary intention
- . Tertiary intention (**Delayed Primary Closure: DPC**)

**What is primary intention?**

When the edges of a clean wound are closed in some manner immediately (e.g., suture, Steri-Strips®, staples)

**What is secondary intention?**

When a wound is allowed to remain open and heal by granulation, epithelization, and contraction—used for dirty wounds, otherwise an abscess can form

### **What is tertiary intention?**

When a wound is allowed to remain open for a time and then closed, allowing for débridement and other wound care to reduce bacterial counts prior to closure (i.e., delayed primary closure)

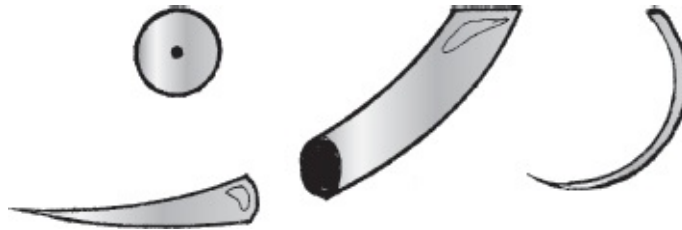### **What is another term for tertiary intention?**

**DPC** = **D**elayed **P**imary **C**losure

## **Suture Techniques**

### **What is a taper-point needle?**

Round body, leaves a round hole in tissue (spreads without cutting tissue)



### **What is it used for?**

Suturing of soft tissues other than skin (e.g., GI tract, muscle, nerve, peritoneum, fascia)

### **What is a conventional cutting needle?**

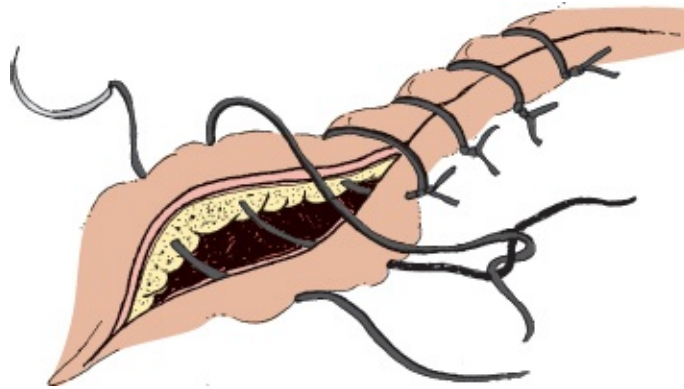
Triangular body with the sharp edge toward the inner circumference; leaves a triangular hole in tissue



### **What are its uses?**

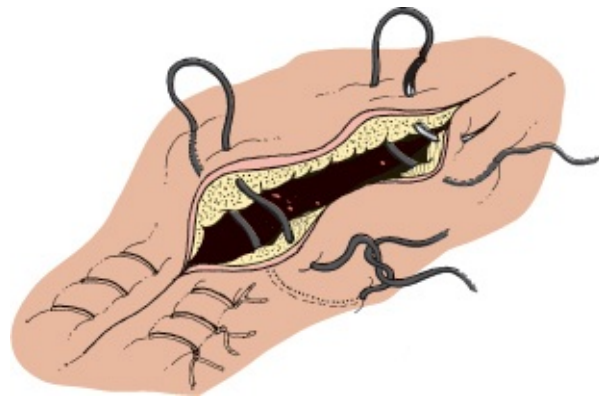
Suturing of **skin**

### **What is a simple interrupted stitch?**



### **What is a vertical mattress stitch?**

Simple stitch is made, the needle is reversed, and a small bite is taken from each wound edge; the knot ends up on one side of the wound



### **What is the vertical mattress stitch also known as?**

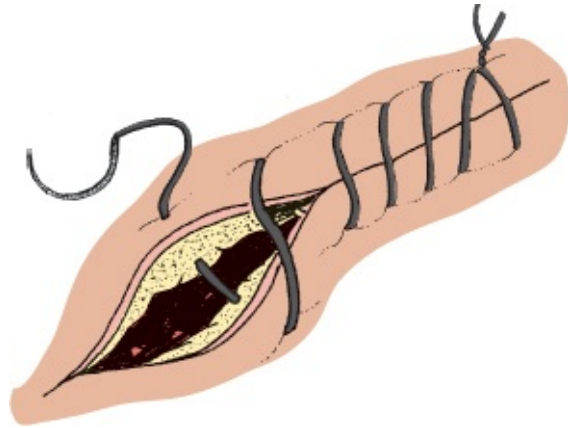
Far–far, near–near stitch—oriented perpendicular to wound

### **What is it used for?**

Difficult-to-approximate skin edges; everts tissue well

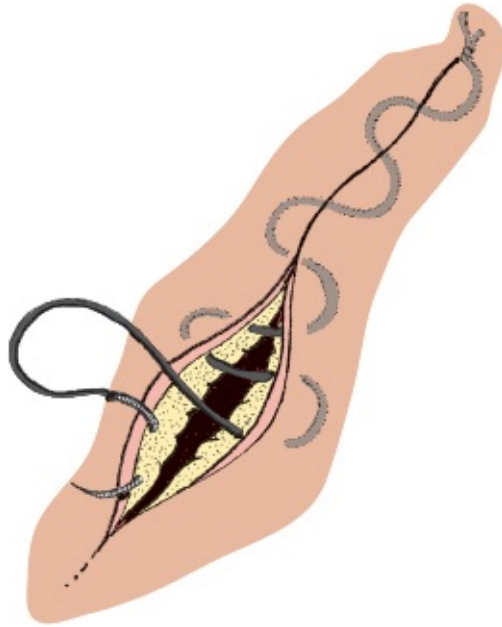
### **What is a simple running (continuous) stitch?**

Stitches made in succession without knotting each stitch



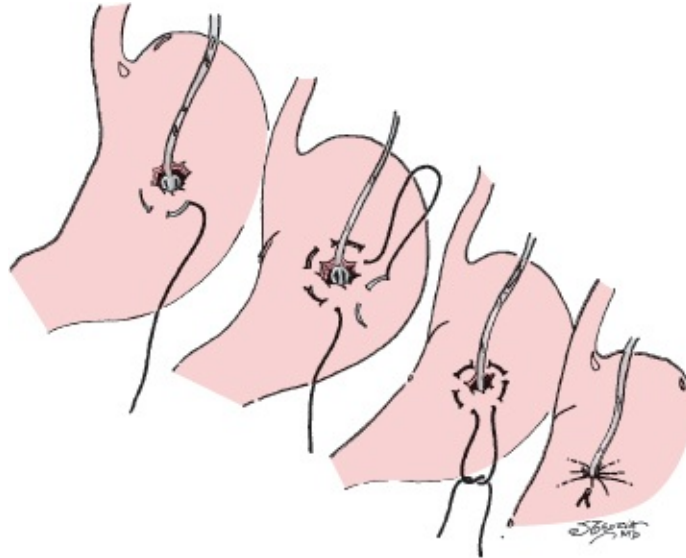
### **What is a subcuticular stitch?**

Stitch (usually running) placed just underneath the epidermis, can be either absorbable or nonabsorbable (pull-out stitch if nonabsorbable)

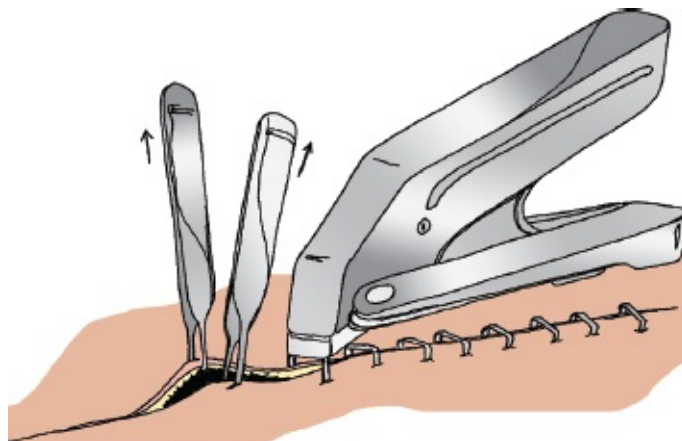


### **What is a pursestring suture?**

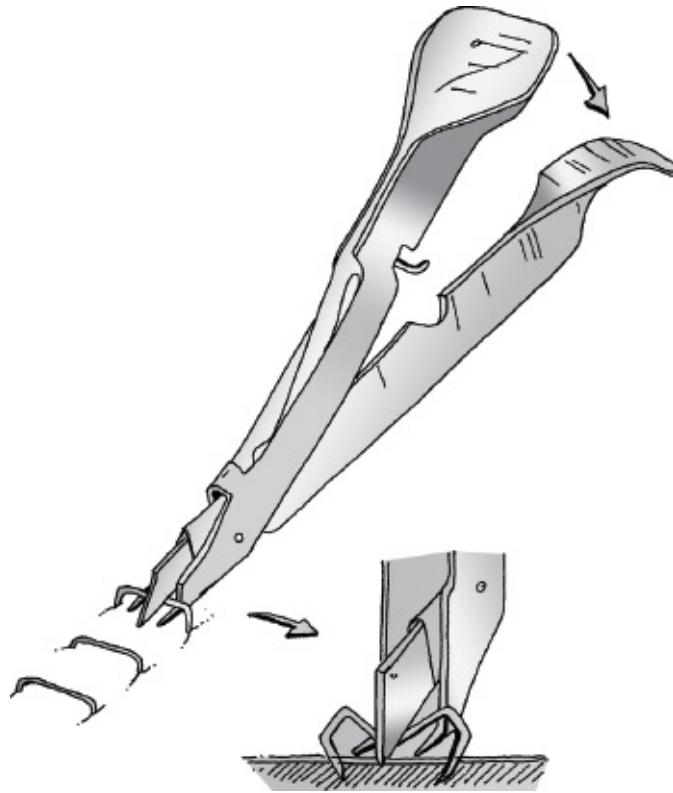
Stitch that encircles a tube perforating a hollow viscus (e.g., gastrostomy tube), allowing the hole to be drawn tight and thus preventing leakage



**What are metallic skin staples?**

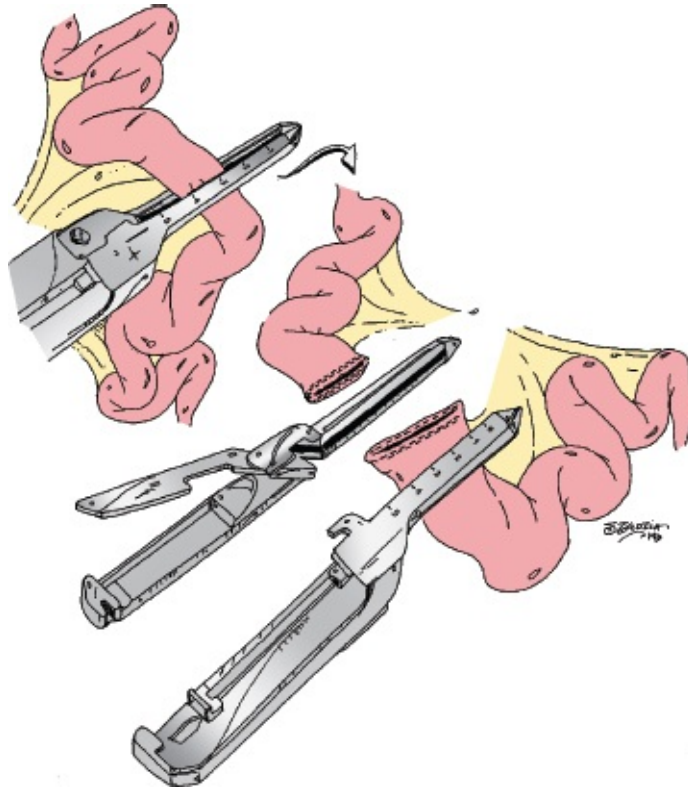


**What is a staple removal device?**



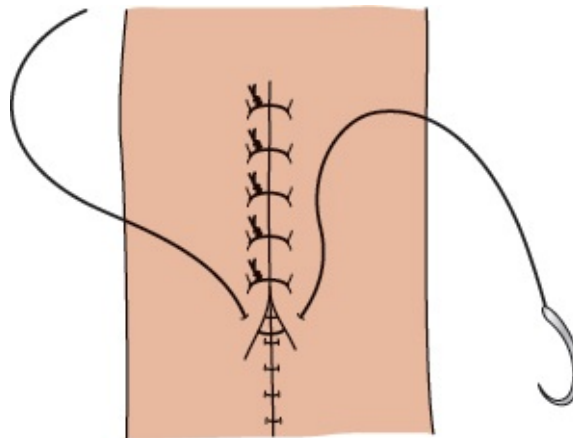
**What is a gastrointestinal anastomosis (GIA) device?**

Stapling device that lays two rows of small staples in a hemostatic row and **automatically cuts** in between them



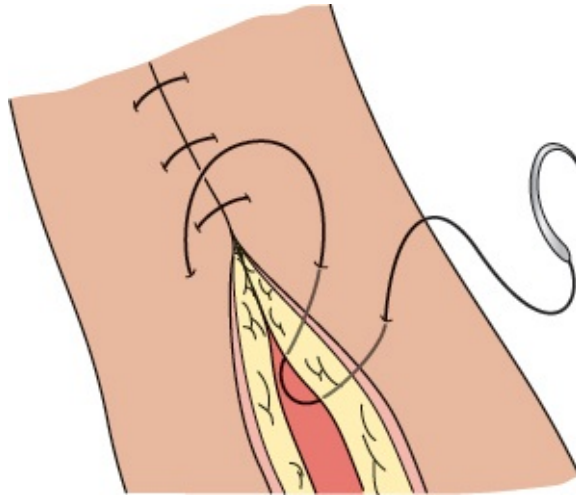
### **What is a Lambert stitch?**

It is a second layer in bowel anastomoses



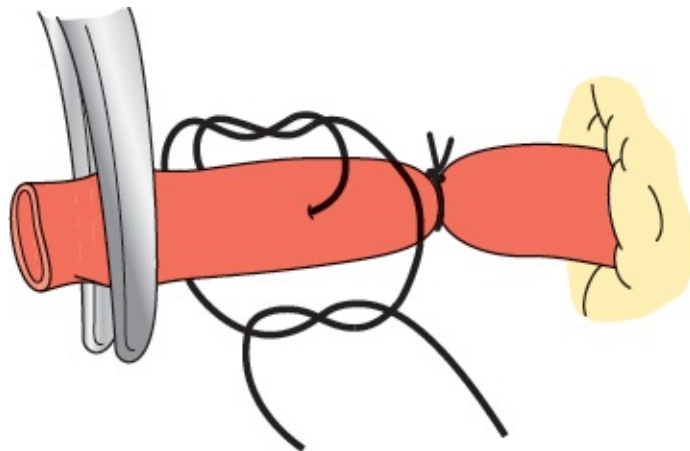
### **What is a Connell's stitch?**

The first mucosa-to-mucosa layer in an anastomosis; basically a running U stitch



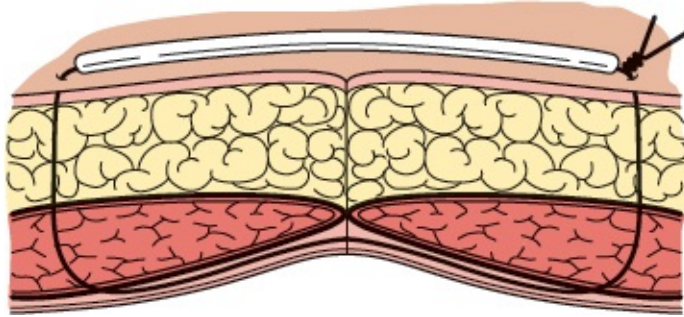
### **What is a suture ligature (a.k.a. “stick tie”)?**

Suture is anchored by passing it through the vessel **on a needle** before wrapping it around and occluding the vessel; prevents slippage of knot-use on larger vessels



### **What is a retention suture?**

Large suture (#2) that is full thickness through the entire abdominal wall except the peritoneum; used to buttress an abdominal wound at risk for dehiscence and evisceration



### **What is a pop-off suture?**


Suture that is not permanently swaged to the needle, allowing the surgeon to “pop off” the needle from the suture without cutting the suture

# Chapter 7 Surgical Knot Tying

## KNOTS AND EARS

**What is the basic surgical knot?**

Square knot

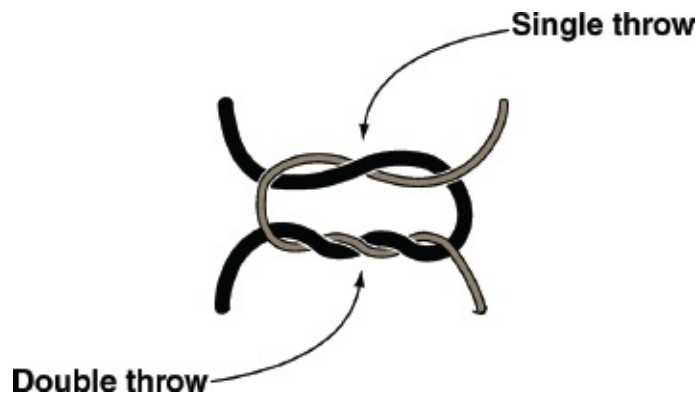


**What is the first knot that should be mastered?**

Instrument knot

**What is a “surgeon’s knot”?**

Double-wrap throw followed by single-square knot throws



**What are the guidelines for the number of minimal throws needed?**

Depends on the suture material:

**Silk—3**

**Gut—4**

**Vicryl<sup>®</sup>, Dexon<sup>®</sup>, other braided synthetics—4**  
**Nylon, polyester, polypropylene, PDS, Maxon—6**

### **How long should the ears of the knot be cut?**

Some guidelines are:

**Silk vessel ties—1 to 2 mm**

**Abdominal fascia closure—5 mm**

**Skin sutures, drain sutures—5 to 10 mm** (makes them easier to find and remove)

### **When should skin sutures be removed?**

As soon as the wound has healed enough to withstand expected mechanical trauma

Any stitch left in more than  $\approx 10$  days will leave a scar

Guidelines are:

**Face—3 to 5 days**

**Extremities—10 days**

**Joints—10 to 14 days**

**Back—14 days**

**Abdomen—7 days**

### **How can strength be added to an incision during and after suture removal?**

With Steri-Strips<sup>®</sup>

### **In general, in which group of patients should skin sutures be left in longer than normal?**

Patients on steroids

### **How should the sutures be cut?**

Use the tips of the scissors to avoid cutting other tissues

Try to remove the cut ends (less foreign material decreases risk of infection)

Rest the scissor-hand on the non-scissor-hand to steady

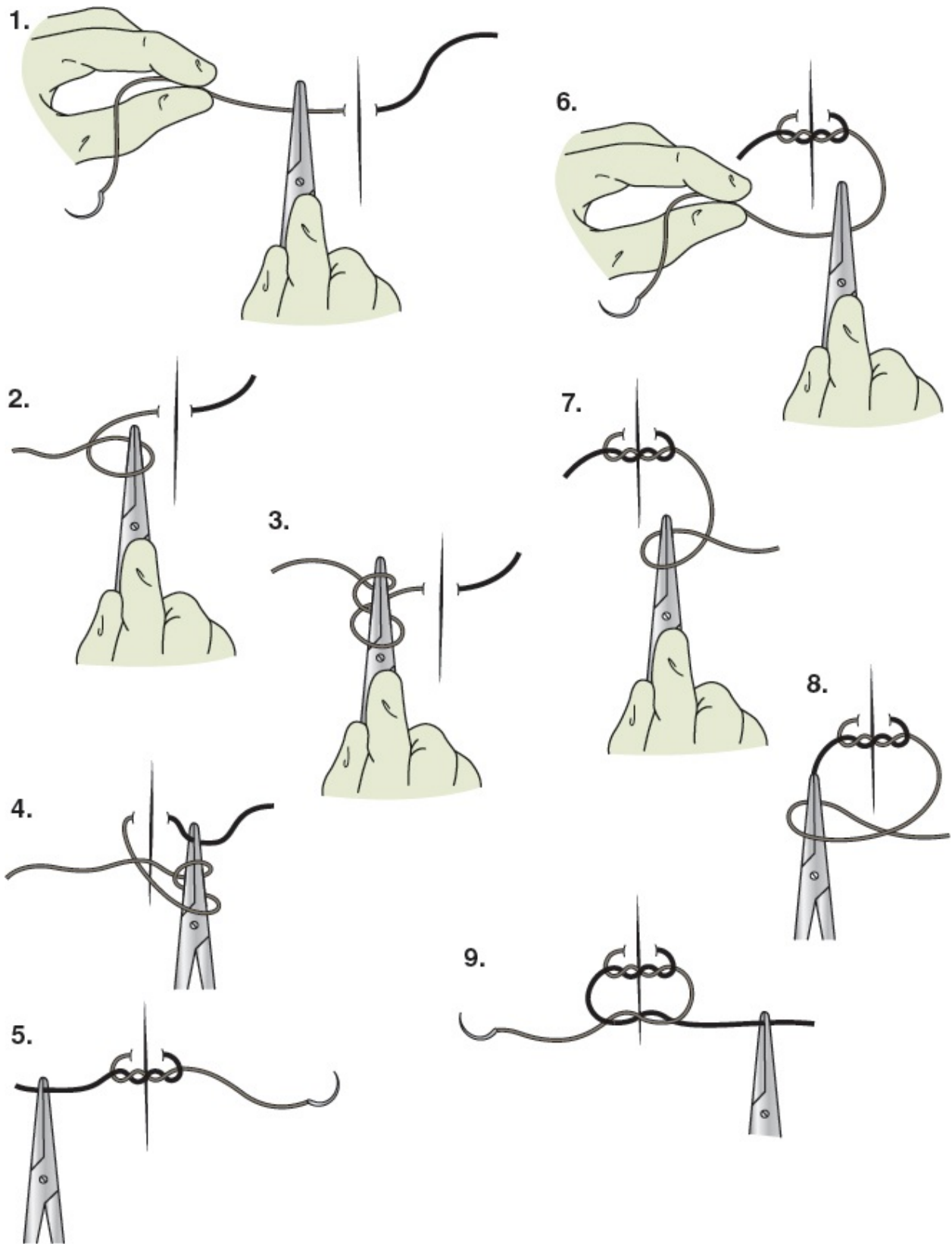
### **How is an instrument knot tied?**

Always start with a double wrap, known as a “surgeon’s knot,” and then use a single wrap, pulling the suture in the opposite directions after every “throw”

**Does a student need to know a one-hand tie?**

No! Master the two-hand tie and the instrument tie

## INSTRUMENT TIE

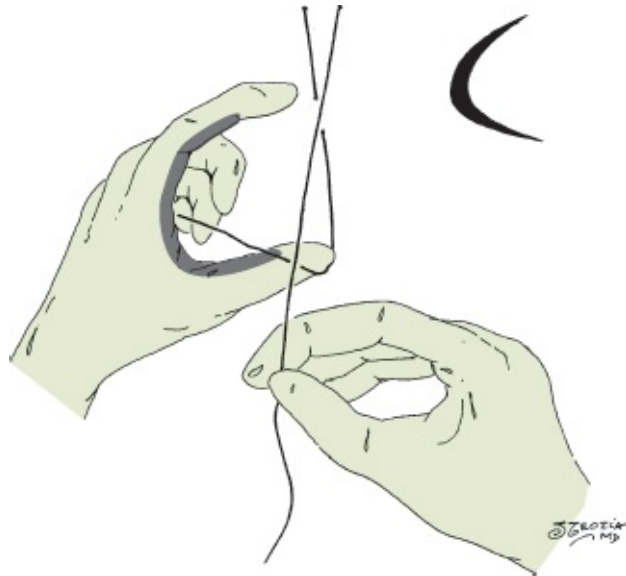

Then continue with single throws

## TWO-HAND TIE

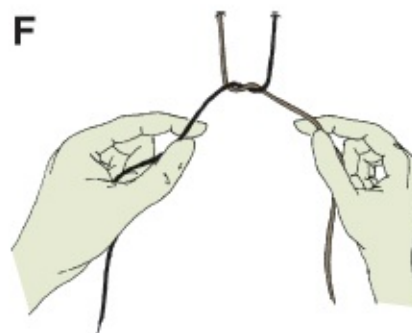
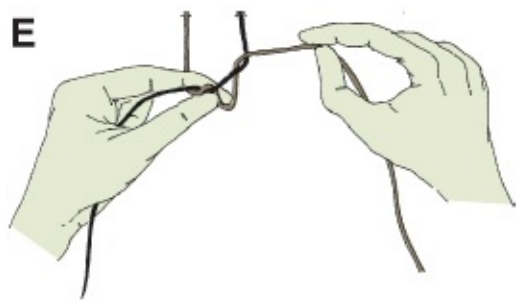
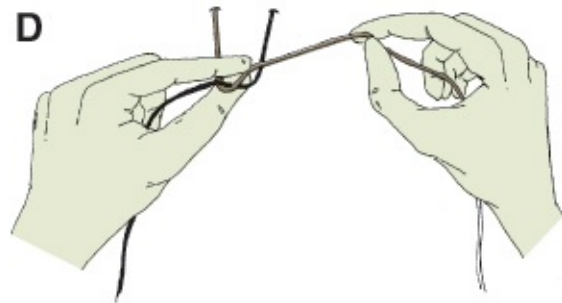
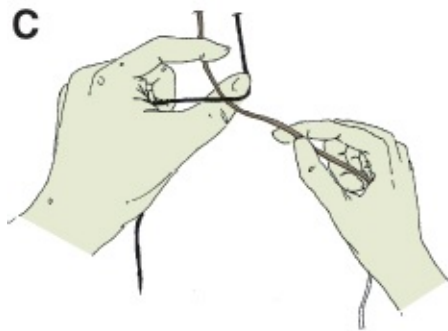
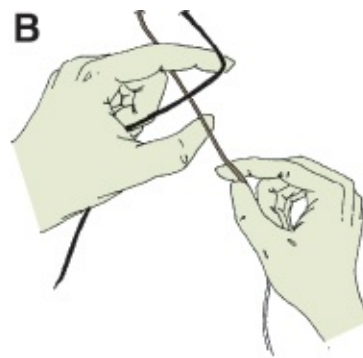
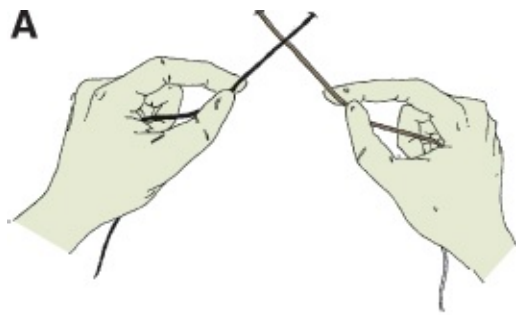
### What is the basic position for the two-hand tie?

“C” position, formed by the thumb and index finger; the suture will **alternate** over the thumb and then the index finger for each throw

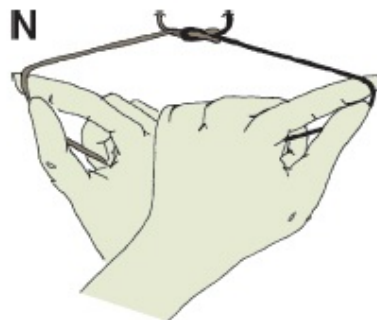
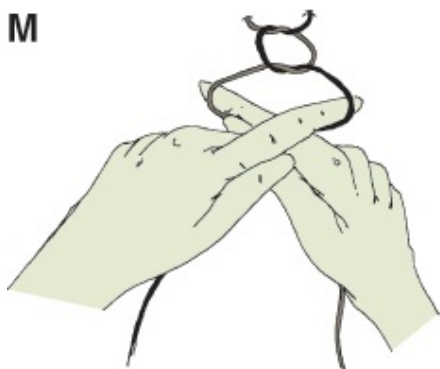
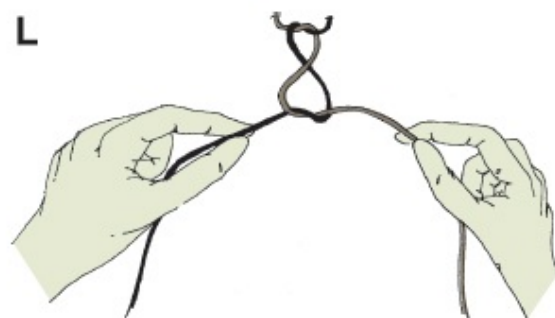
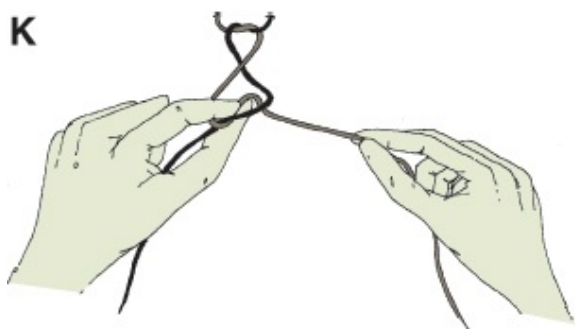
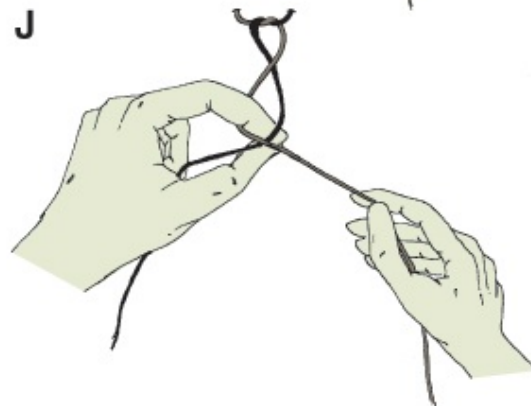
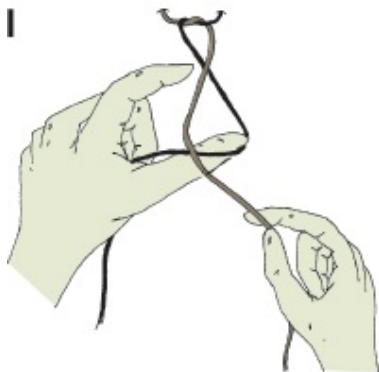
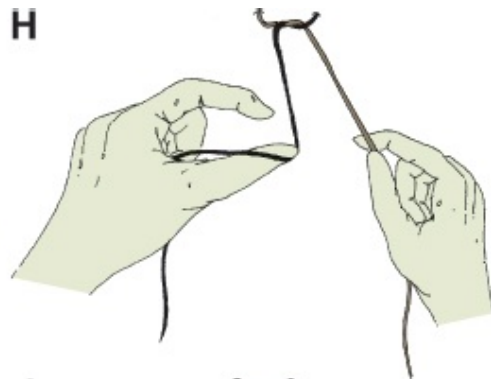
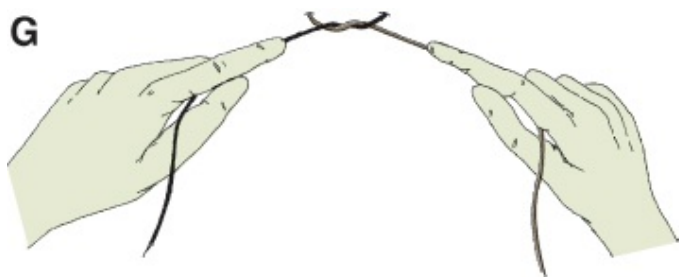


### How is a two-hand knot tied?

First, use the index finger to lead



Then use thumb to lead:



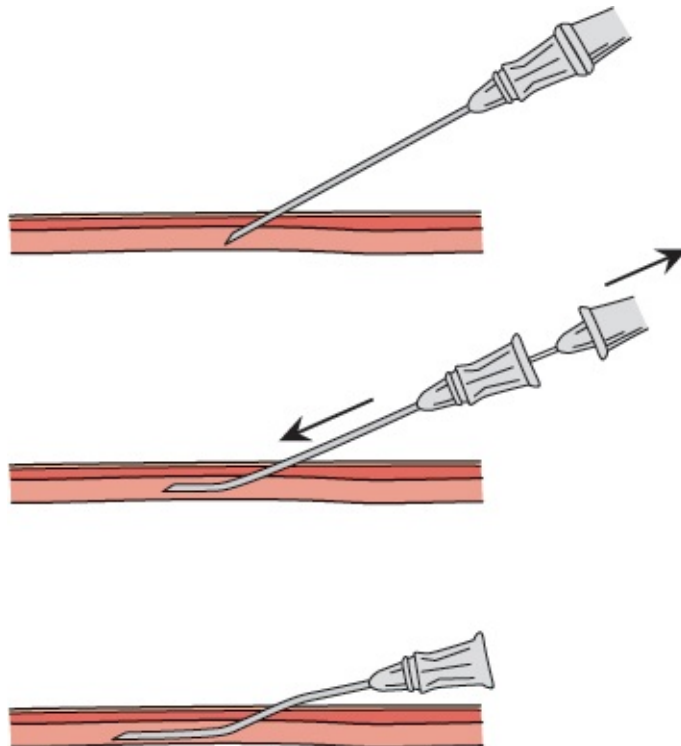
Ask a resident or intern to help you after you have tried for a while.  
Open book to this page for guidance.

# Chapter 8 Procedures for the Surgical Ward and Clinic

## COMMON PROCEDURES

### How do you place a peripheral intravenous (IV) catheter?

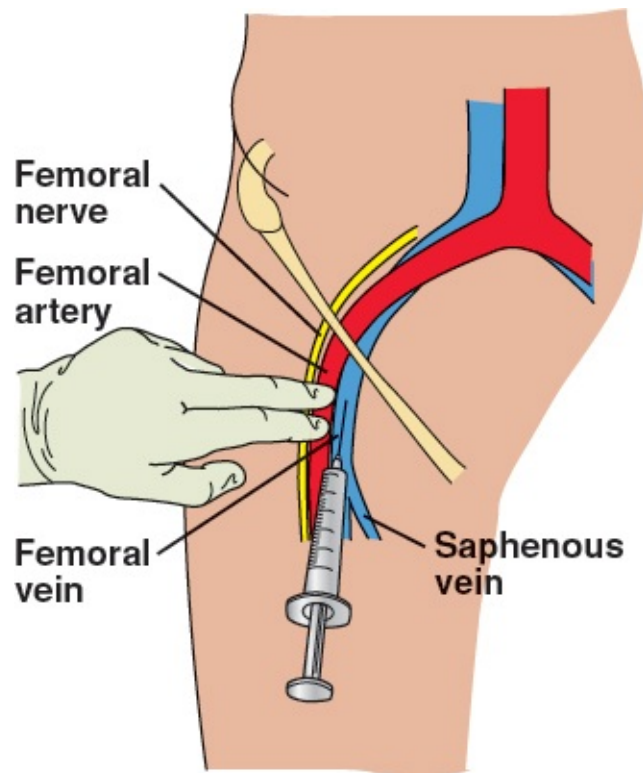
- . Place a rubber tourniquet above the site
- . Use alcohol antiseptic
- . Place IV into vein with “flash” of blood
- . Remove inner needle while advancing IV catheter
- . Secure with tape



### How do you draw blood from the femoral vein?

Remember “NAVEL”: In the lateral to medial direction—Nerve, Artery, Vein,

Empty space, Lymphatics—and thus place needle medial to the femoral pulse



### How do you remove staples?

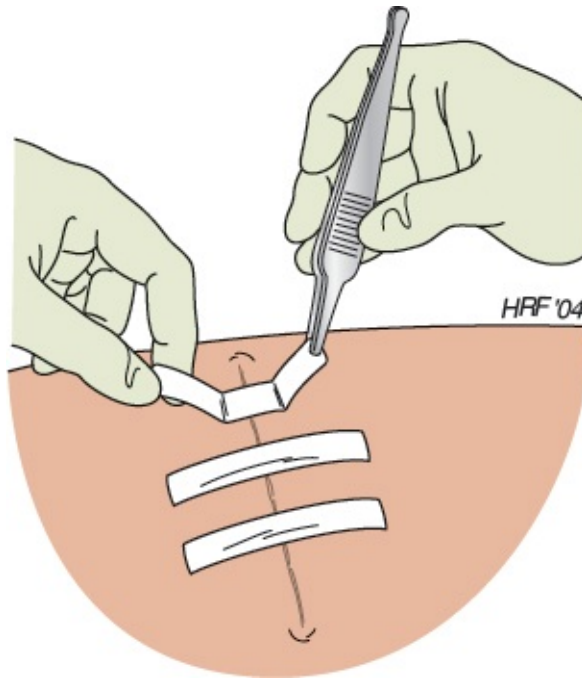
Use a staple remover (see [Chapter 6](#)), then place Steri-Strips®

### How do you remove stitches?

- . Cut the suture next to the knot
- . Pull end of suture out by holding onto the knot
- . Place Steri-Strips®

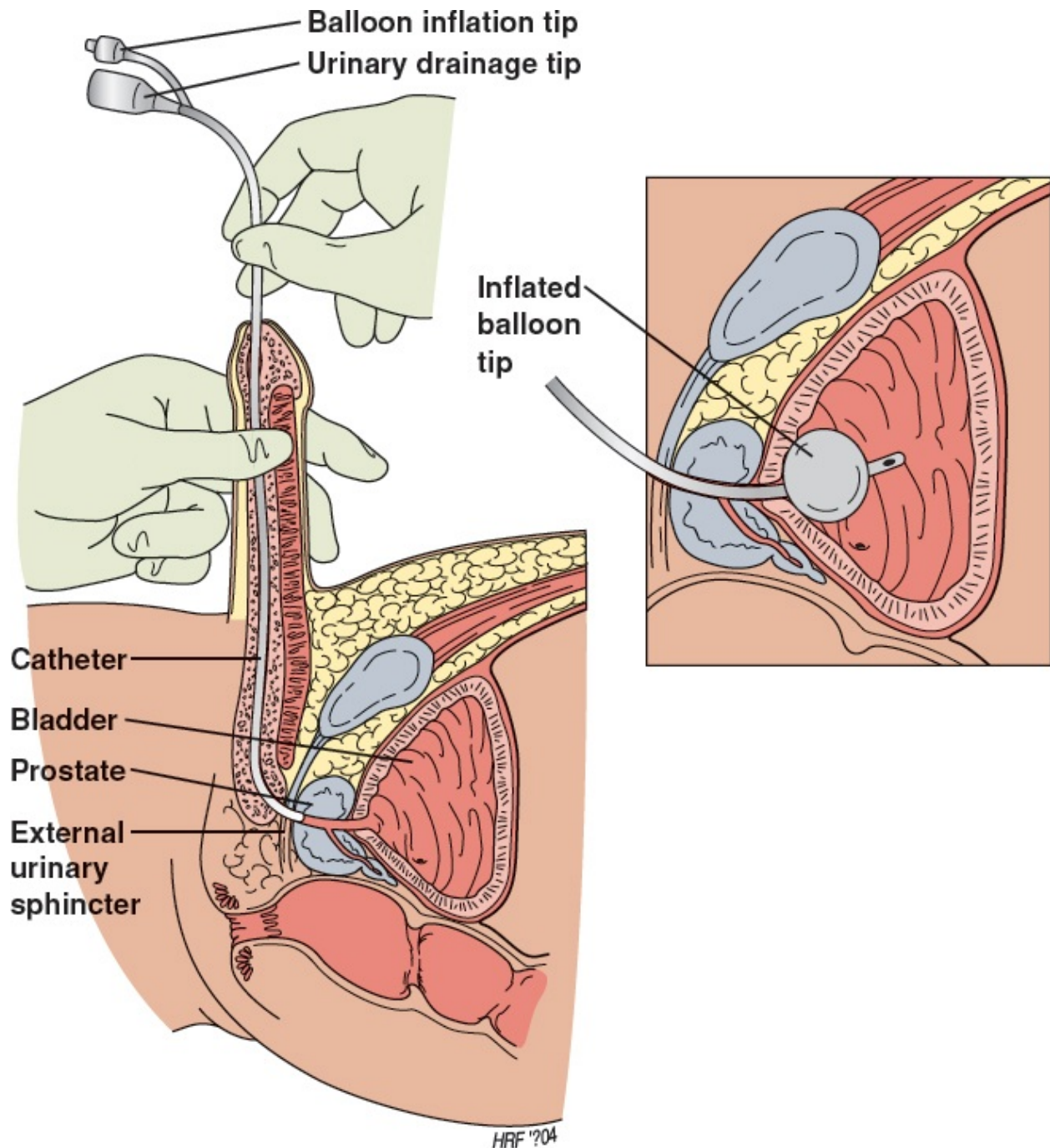
### How do you place Steri-Strips®?

- . Dry the skin edges of the wound
- . Place adhesive (e.g., benzoin)
- . With the Adson pickup or with your fingers, place strips to gently appose epidermis (**Note:** Avoid any tension or blisters will appear)



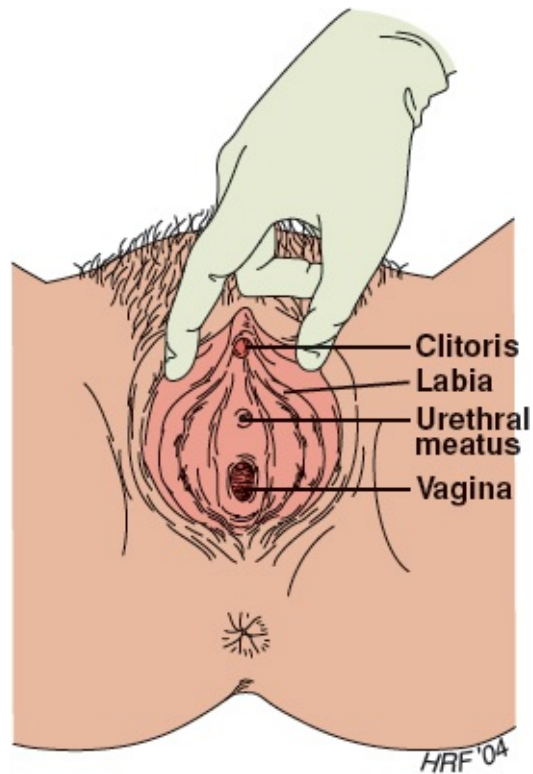
### **How do you place a Foley catheter?**

- . Stay sterile
- . Apply Betadine® to the urethral opening (meatus)
- . Lubricate the catheter
- . Place catheter into urethra
- . As soon as urine returns, inflate balloon with saline (balloon size is given in cc on the catheter)



### How do you find the urethra in females?

First find the clitoris and clitoral hood: The urethra is just below these structures; wiping a Betadine®-soaked sponge over this area will often result in having the urethra “wink” open



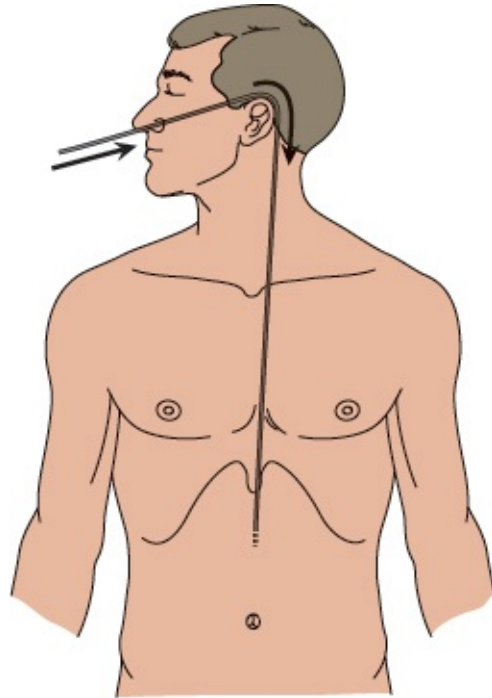
**Can you inflate the Foley balloon before you get urine return?**

No, you might inflate a balloon in the urethra!

## **NASOGASTRIC TUBE (NGT) PROCEDURES**

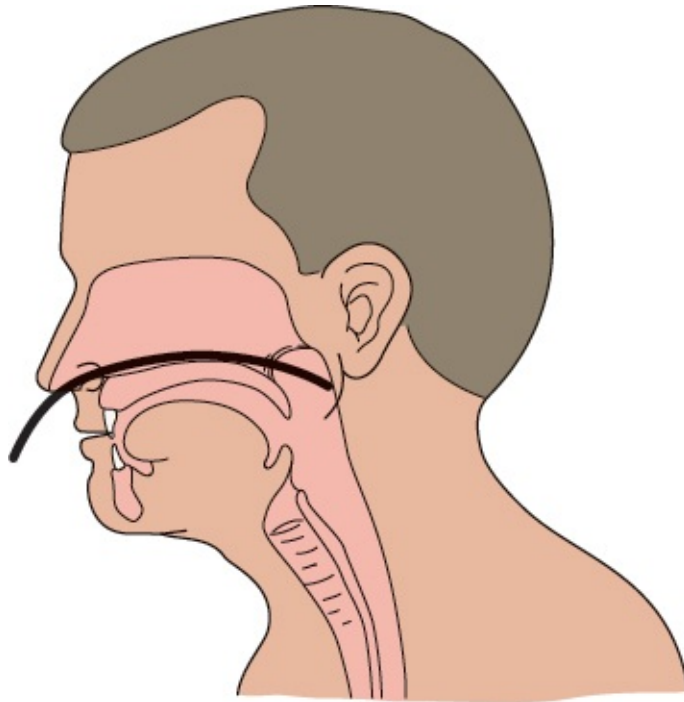
**How do you determine how much of the NGT should be advanced into the body for the correct position?**

Rough guide: from nose, around ear, to 5 cm below the xiphoid



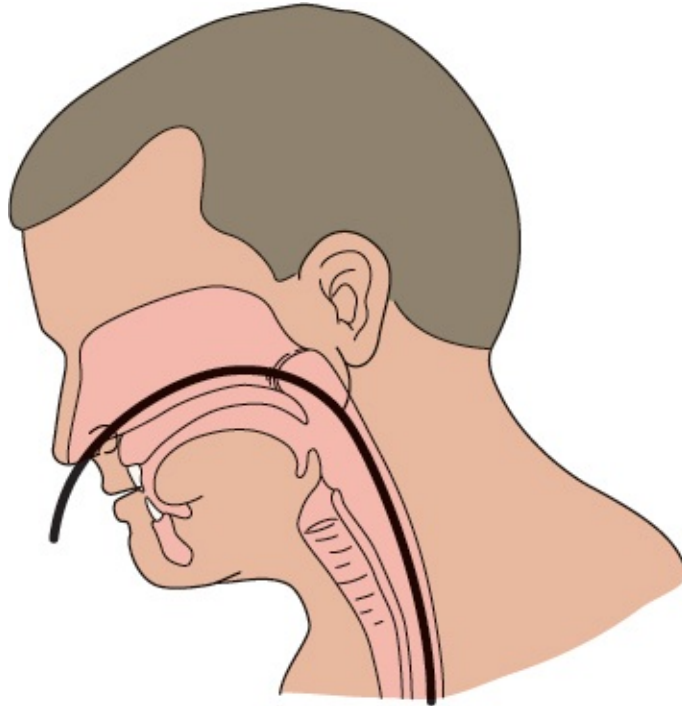
### **How do you place the NGT in a nare?**

First place lubrication (e.g., Surgilube®) then place NGT straight back—not up or down!



**What is the best neck position for advancing the NGT?**

Neck FLEXED! Also have the patient drink some water (using a straw)

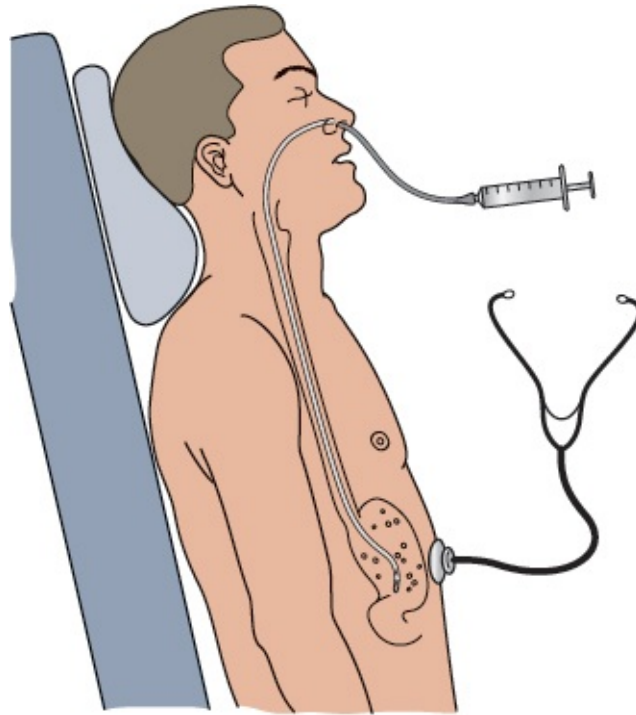


**What if there is 3 liters/24 hours drainage from an NGT?**

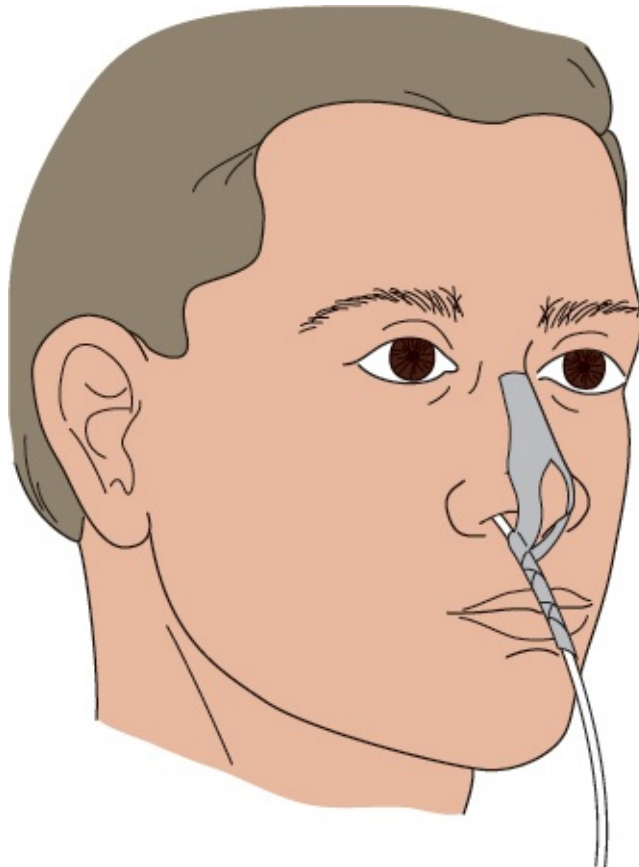
Think DUODENUM—the NGT may be in the duodenum and not in the stomach! Check an x-ray

**How can you clinically confirm that an NGT is in the stomach?**

Use a Toomey syringe to “inject” air while listening over the stomach with a stethoscope; you will hear the “swish” if the NGT is in place



**How do you tape an NGT?**

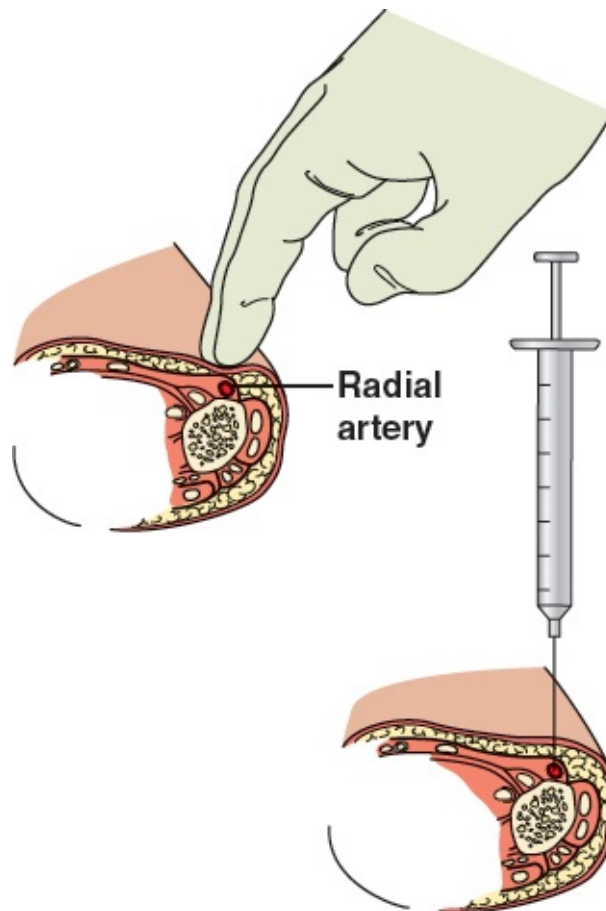


## **What MUST you obtain and examine before using an NGT for feeding?**

LOWER chest/upper abdominal x-ray to absolutely verify placement into the stomach and NOT into the LUNG—patients have died from pulmonary tube feeding!

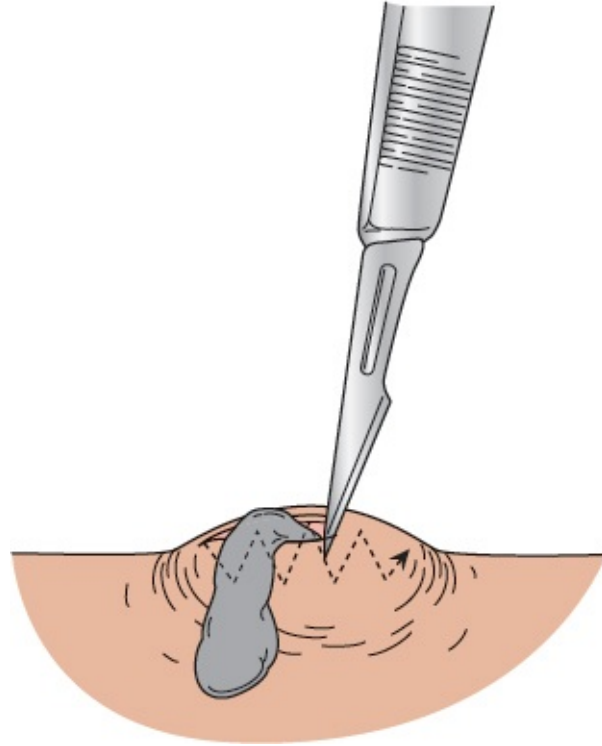
## **How do you draw a radial arterial blood gas (ABG)?**

Feel for the pulse and advance directly into the artery; ABG syringes do not have to have the plunger withdrawn manually



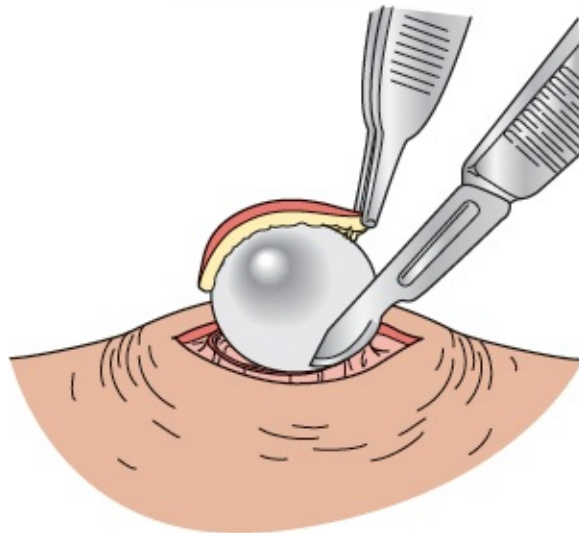
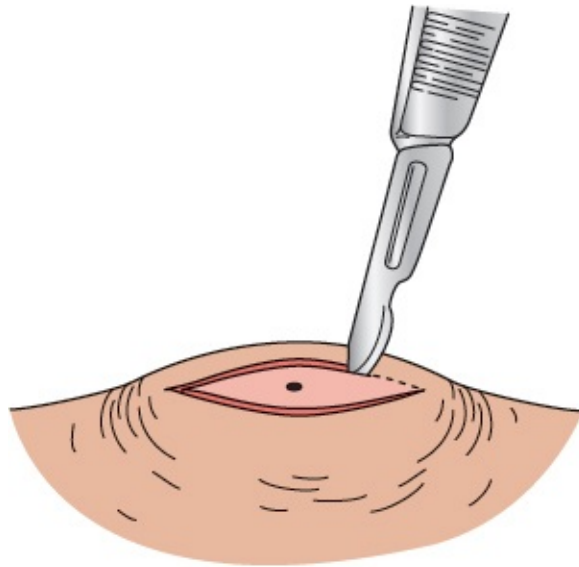
## **How do you drain an abscess?**

By incision and drainage (or “I & D”): After using local anesthetic, use a #11 blade to incise and then open the abscess pocket; large abscesses are best drained with a cruciate incision or removal of a piece of skin; pack the open wound



**How do you remove an epidermal cyst or sebaceous cyst?**

- . Administer local anesthetic
- . Remove the ellipse of skin overlying the cyst, including the pore
- . Remove the cyst with the encompassing sac lining



# Chapter 9 Incisions

**If a patient has an old incision, is it best to make a subsequent incision next to or through the old incision?**

Through the old incision, or excise the old incision, because it has scar tissue that limits the amount of collaterals that would be needed to heal an incision placed next to it

**What is used to incise the epidermis?**

Scalpel blade

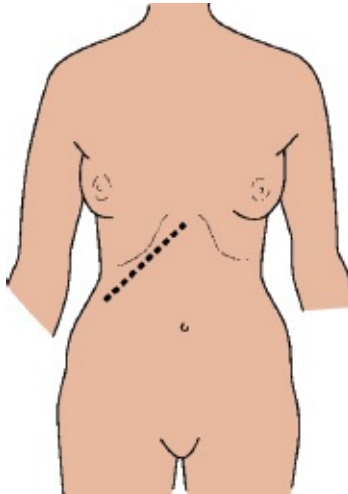
**What is used to incise the dermis?**

Scalpel or electrocautery

**Describe the following incisions:**

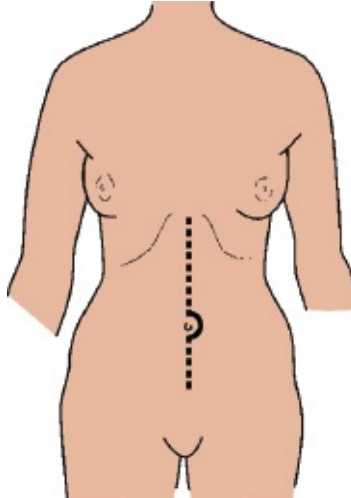
**Kocher**

Right subcostal incision for open cholecystectomy:



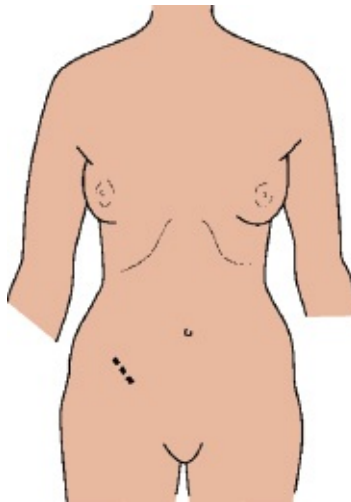
**Midline laparotomy**

Incision down the middle of abdomen along and through the linea alba:



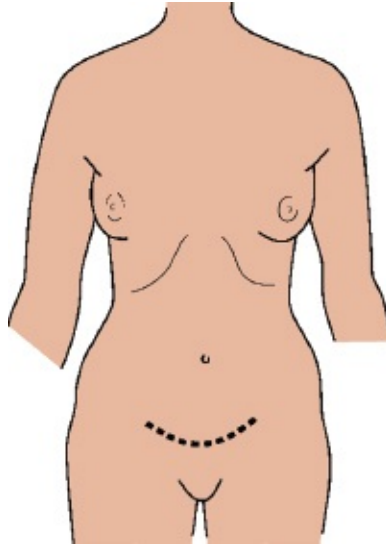
### **McBurney's**

Small, oblique right lower quadrant incision for an appendectomy through McBurney's point (one third from the anterior superior iliac spine to the umbilicus):



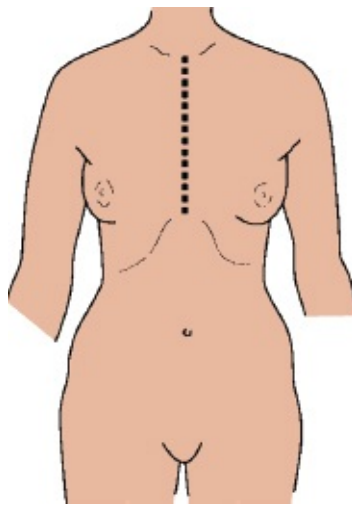
### **Pfannenstiel ("fan-en-steel")**

Low transverse abdominal incision with retraction of the rectus muscles laterally; most often used for gynecologic procedures:



### **Median sternotomy**

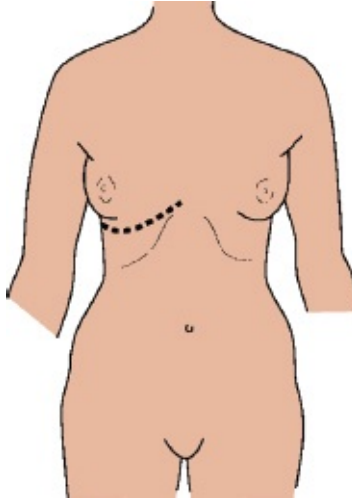
Midline sternotomy incision for heart procedures; less painful than a lateral thoracotomy:



### **Thoracotomy**

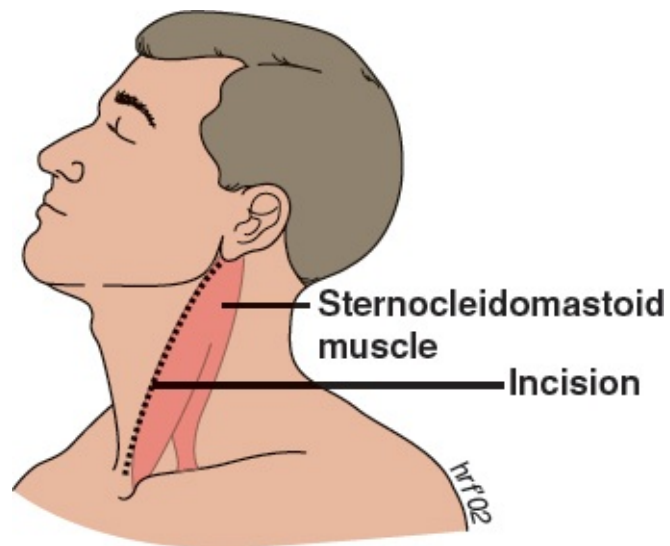
Usually through the fourth or fifth intercostal space; may be anterior or posterior lateral incisions

Very painful, but many are performed with muscle sparing (muscle retraction and not muscle transection):

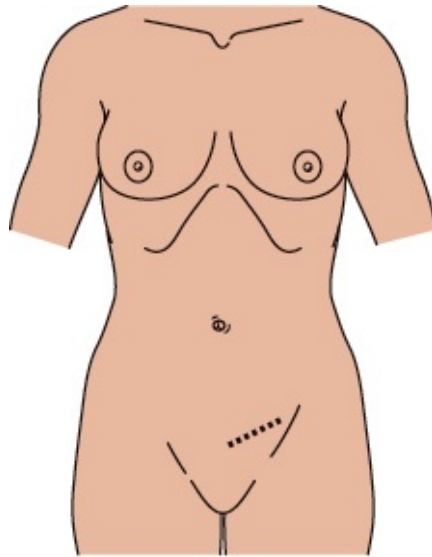


### **CEA (carotid endarterectomy)**

Incision down anterior border of the sternocleidomastoid muscle to expose the carotid:

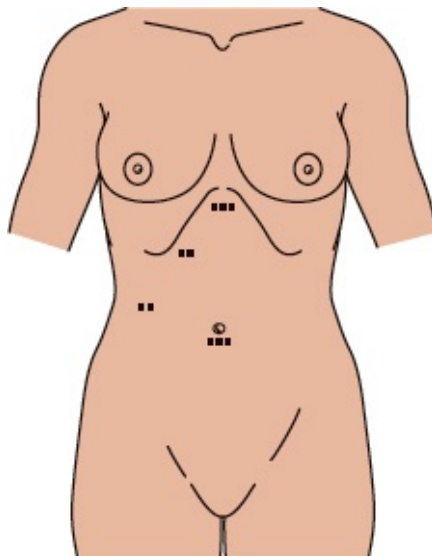


### **Inguinal hernia repair (open)**



## **Laparoscopic cholecystectomy**

Four trocar incisions:



# Chapter 10 Surgical Positions

**Define the following positions:**

## **Supine**

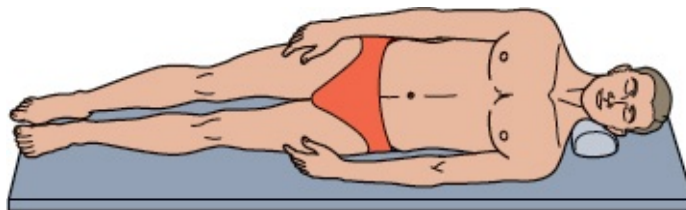Patient lying flat, face up

## **Prone**

Patient lying flat, face down

## **Left lateral decubitus**

Patient lying down on his left side (Think: **left** lateral decubitus = **left** side down)

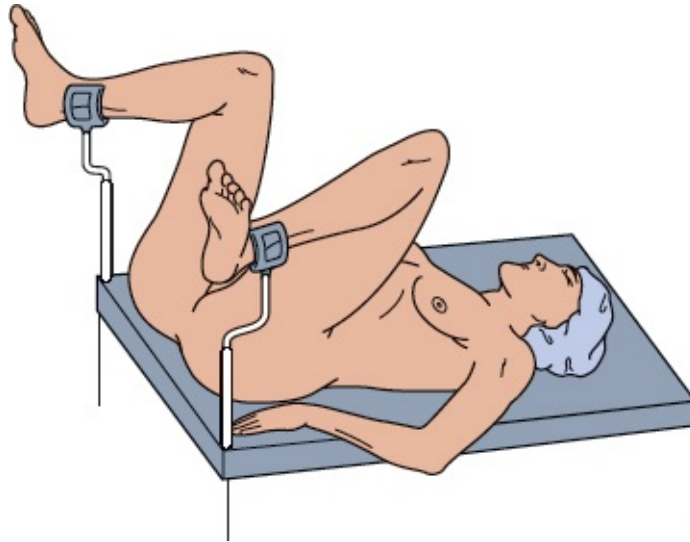


## **Right lateral decubitus**

Patient lying down on his right side (Think: **right** lateral decubitus = **right** side down)

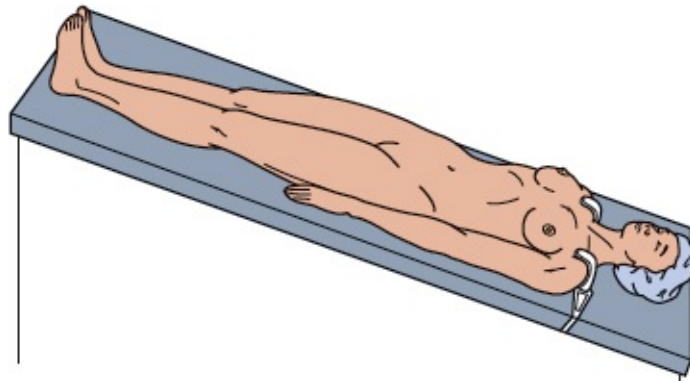
## **Lithotomy**

Patient lying supine with legs spread



### **Trendelenburg**

Patient supine with head lowered (a.k.a. “headdownenburg”—used during placement of a subclavian vein catheter as the veins distend with blood from gravity flow)



### **Reverse Trendelenburg**

Patient supine with head elevated (usual position for laparoscopic cholecystectomy to make the intestines fall away from the operative field)

### **What is the best position for a pregnant patient?**

Left side down to take gravid uterus off the IVC

# Chapter 11 Surgical Speak

The language of surgery is quite simple if you master a few suffixes.

## Define the suffix:

### **-ectomy**

To surgically **remove** part of or an entire structure/organ

### **-orrhaphy**

Surgical **repair**

### **-otomy**

Surgical **incision into** an organ

### **-ostomy**

Surgically created **opening** between two organs, or organ and skin

### **-plasty**

Surgical “shaping” or formation

## Now test your knowledge of surgical speak:

### **Word for the surgical repair of a hernia**

Herniorrhaphy

### **Word for the surgical removal of the stomach**

Gastrectomy

### **Word for the surgical creation of an opening between the colon and the skin**

Colostomy

**Word for the surgical formation of a “new” pylorus**

Pyloroplasty

**Word for the surgical opening of the stomach**

Gastrotomy

**Surgical creation of an opening (anastomosis) between the common bile duct and jejunum**

Choledochojejunostomy

**Surgical creation of an opening (anastomosis) between the stomach and jejunum**

Gastrojejunostomy

## Chapter 12 Preoperative 101

### **When can a patient eat prior to major surgery?**

Patient should be NPO after midnight the night before or for at least 8 hours before surgery

### **What risks should be discussed with all patients and documented on the consent form for a surgical procedure?**

Bleeding, infection, anesthesia, scar; other risks are specific to the individual procedure (also MI, CVA, and death if cardiovascular disease is present)

### **If a patient is on antihypertensive medications, should the patient take them on the day of the procedure?**

Yes (remember clonidine “rebound”)

### **If a patient is on an oral hypoglycemic agent (OHA), should the patient take the OHA on the day of surgery?**

Not if the patient is to be NPO on the day of surgery

### **If a patient is taking insulin, should the patient take it on the day of surgery?**

No, only half of a long-acting insulin (e.g., Lente) and start D5NS IV; check glucose levels often preoperatively, operatively, and postoperatively

### **Should a patient who smokes cigarettes stop before an operation?**

Yes, improvement is seen in just 2 to 4 weeks after smoking cessation

### **What laboratory test must all women of childbearing age have before entering the O.R.?**

$\beta$ -HCG and CBC because of the possibility of pregnancy and anemia from menses

### **What is a preoperative colon surgery “bowel prep”?**

Bowel prep with colon cathartic (e.g., GoLYTELY®), oral antibiotics (neomycin and erythromycin base), and IV antibiotic before incision (controversial)

**Has a preoperative bowel prep been shown conclusively to decrease postoperative infections in colon surgery?**

No, there is no data to support its use

**What must you always order preoperatively for your patient undergoing a major operation?**

- . NPO/IVF
- . Preoperative antibiotics
- . Type and cross blood (PRBCs)

**What electrolyte must you check preoperatively if a patient is on hemodialysis?**

Potassium

**Who gets a preoperative ECG?**

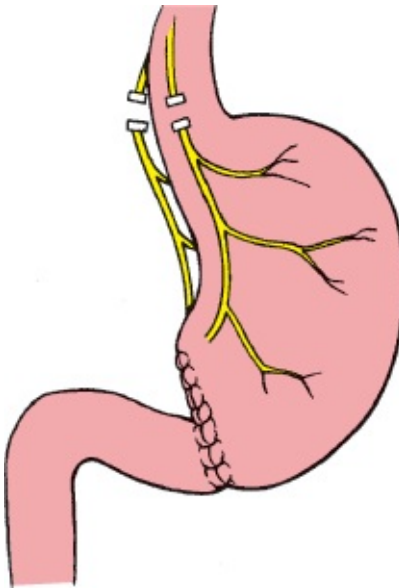
Patients age >40 years

# Chapter 13 Surgical Operations You Should Know

Define the following procedures:

## **Billroth I**

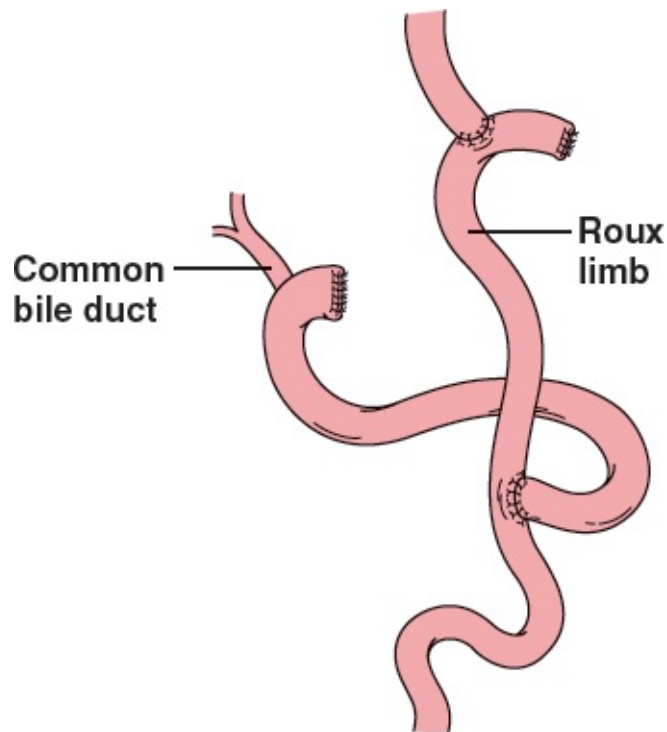
Antrectomy with gastroduodenostomy



## **Billroth II**

Antrectomy with gastrojejunostomy

Jejunojejunostomy forming a Y-shaped figure of small bowel; the free end can then be anastomosed to a second hollow structure (e.g., esophagojejunostomy)



### Brooke ileostomy

Standard ileostomy that is **folded on itself** to protrude from the abdomen  $\approx 2$  cm to allow easy appliance placement and collection of succus

### CEA

Carotid **End**Arterectomy; removal of atherosclerotic plaque from a carotid artery

### APR

Abdomino**P**erineal **R**esection; removal of the rectum and sigmoid colon through abdominal and perineal incisions (patient is left with a colostomy); used for low rectal cancers

### LAR

Low **A**nterior **R**esection; **resection** of **low** rectal tumors through an **anterior** abdominal incision

### Hartmann's procedure

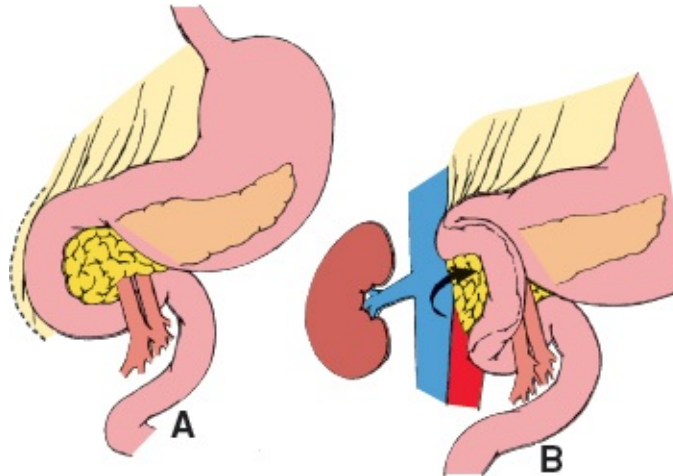
1. Proximal colostomy
2. Distal stapled-off colon or rectum that is left in peritoneal cavity

### **Mucous fistula**

Distal end of the colon is brought to the abdominal skin as a stoma (proximal end is brought up to skin as an end colostomy)

### **Kocher (“koh-ker”) maneuver**

Dissection of the duodenum from the right-sided peritoneal attachment to allow mobilization and visualization of the back of the duodenum/pancreas



### **Cattel maneuver**

Mobilization of the ascending colon to the midline. If combined with a Kocher maneuver, exposes the vena cava (Think: **C**attel = **K**ocher = right sided)

### **Seldinger technique**

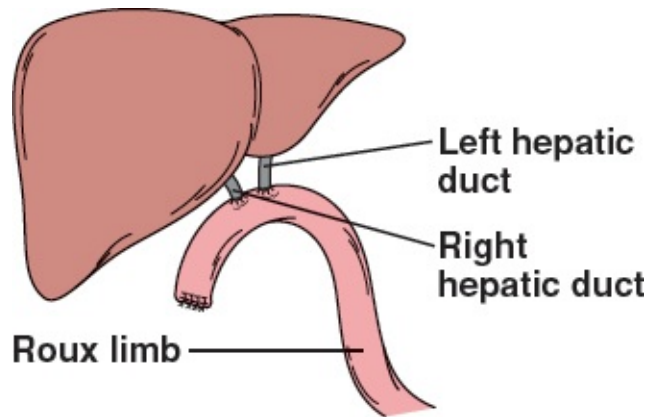
Placement of a central line by first placing a wire in the vein, followed by placing the catheter over the wire

### **Cricothyroidotomy**

Emergent surgical airway through the cricoid membrane

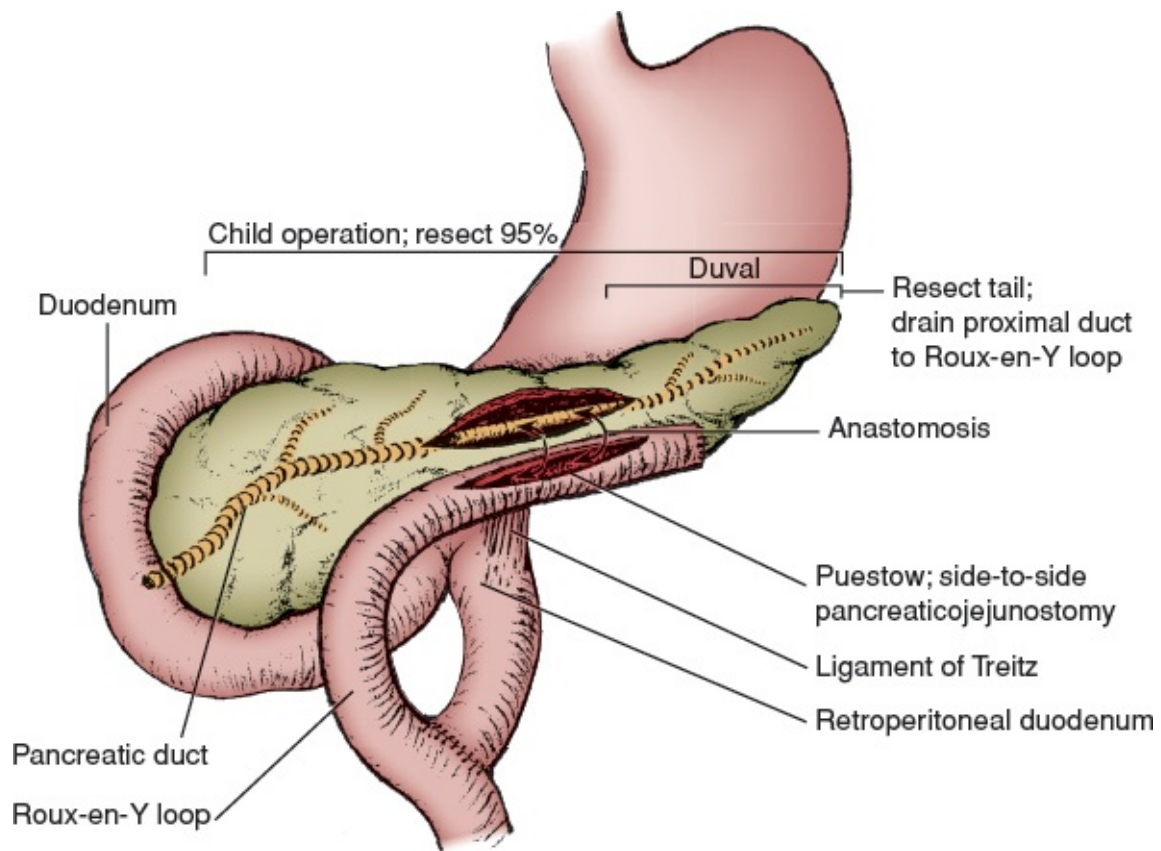
### **Hepaticojejunostomy**

Anastomosis between a jejunal roux limb and the hepatic bile ducts



## Puestow procedure

Side-to-side anastomosis of the pancreas and jejunum (pancreatic duct is filleted open)



## Enterolysis

Lysis of peritoneal adhesions

## LOA

**Lysis Of Adhesions (enterolysis)**

### **Appendectomy**

Removal of the appendix

### **Lap appy**

Laparoscopic removal of the appendix

### **Cholecystectomy**

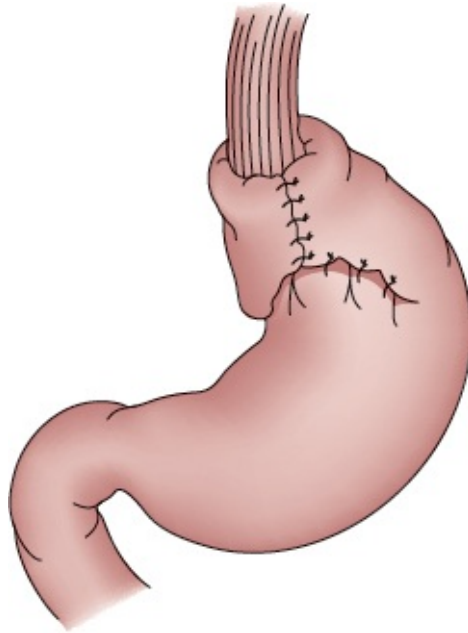
Removal of the gallbladder

### **Lap chole**

Laparoscopic removal of the gallbladder

### **Nissen**

Nissen fundoplication; 360-degree wrap of the stomach by the fundus of the stomach around the distal esophagus to prevent reflux



### **Lap Nissen**

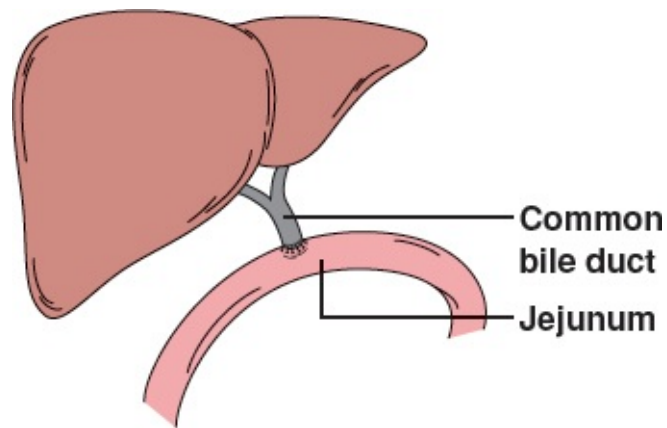
Nissen fundoplication with laparoscopy

### **Simple mastectomy**

Removal of breast and nipple without removal of nodes

## **Choledochojejunostomy**

Anastomosis of the common bile duct to the jejunum (end to side)

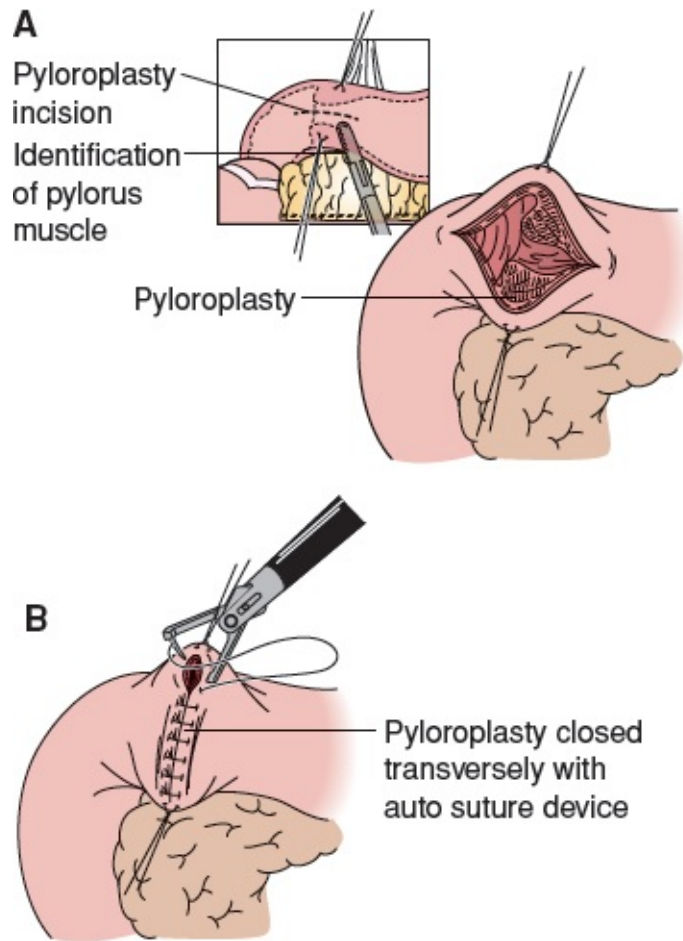


## **Graham patch**

Placement of omentum with stitches over a gastric or duodenal perforation (i.e., omentum is used to plug the hole)

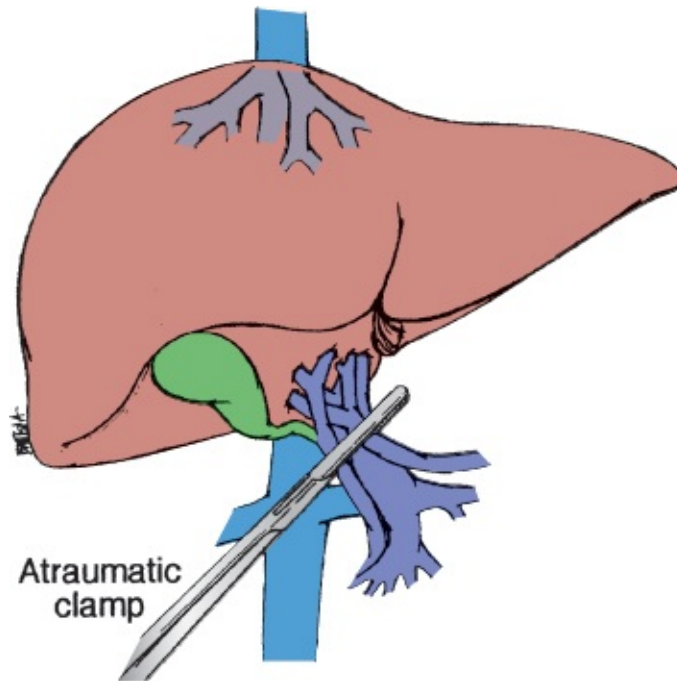
## **Heineke–Mikulicz pyloroplasty**

Longitudinal incision through all layers of the pylorus, sewing closed in a transverse direction to make the pylorus nonfunctional (used after truncal vagotomy)



### **Pringle maneuver**

Temporary occlusion of the porta hepatis (for temporary control of liver blood flow when liver parenchyma is actively bleeding)



### **Modified radical mastectomy**

Removal of the breast, nipple, **and axillary lymph nodes** (no muscle is removed)

### **Lumpectomy and radiation**

Removal of breast mass and axillary lymph nodes; normal surrounding breast tissue is spared; patient then undergoes postoperative radiation treatments

### **I & D**

Incision and **D**rainage of pus; the wound is then packed open

### **Exploratory laparotomy**

Laparotomy to explore the peritoneal cavity looking for the cause of pain, peritoneal signs, obstruction, hemorrhage, etc.

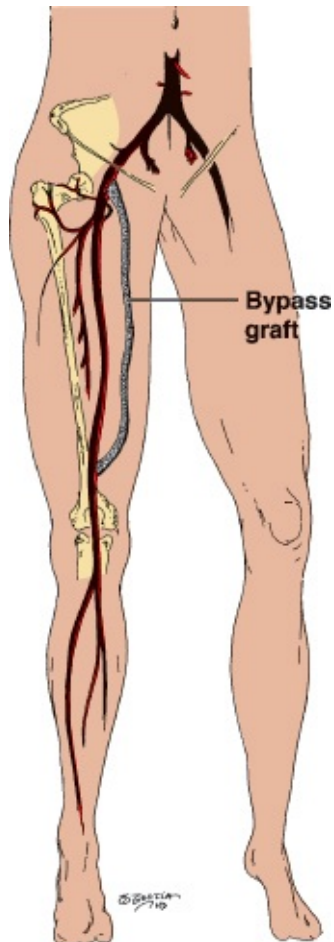
### **TURP**

Trans**U**rethral **R**esection of the **P**rostate; removal of obstructing prostatic tissue via scope in the urethral lumen

### **Fem pop bypass**

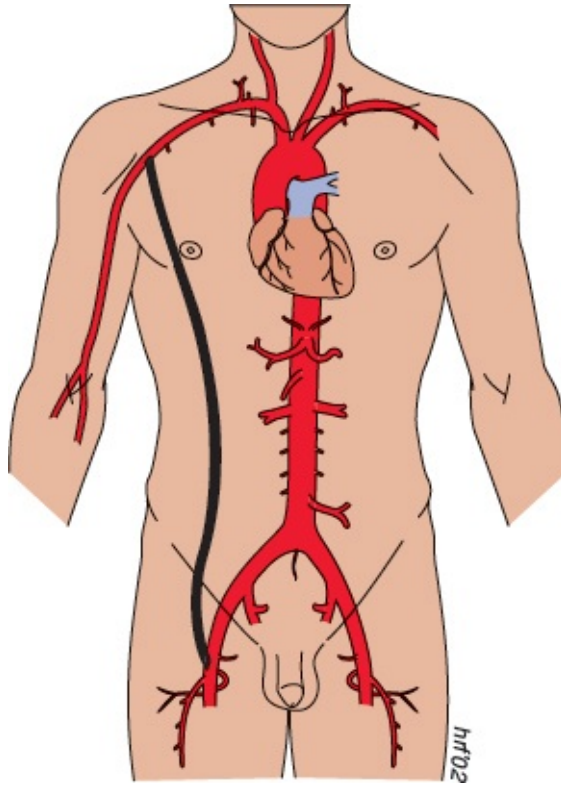
**FEM**oral artery to **POP**liteal artery bypass using synthetic graft or saphenous

vein; used to bypass blockage in the femoral artery



### **Ax Fem**

Long prosthetic graft tunneled under the skin placed from the **AX**illary artery to the **FEM**oral artery (Extra-Anatomic bypass)

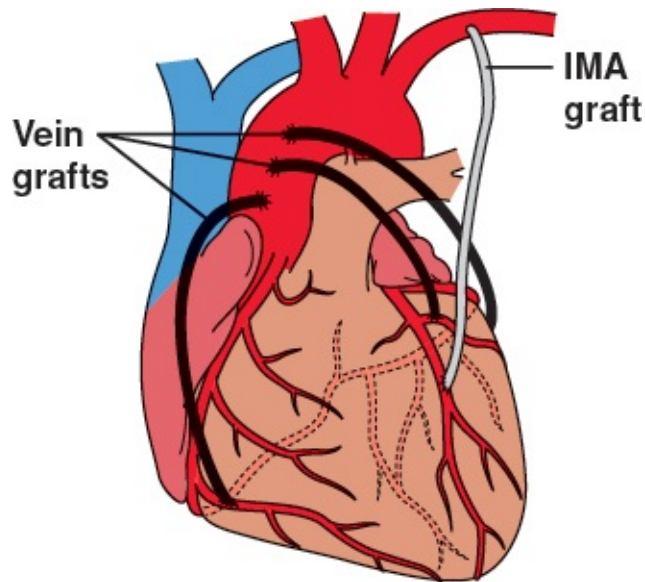


### **Triple A repair**

Repair of an **AAA** (**A**bsdominal **A**ortic **A**neurysm): Open aneurysm and place prosthetic graft; then close old aneurysm sac around graft

### **CABG**

**C**oronary **A**rtery **B**ypass **G**rafting; via saphenous vein graft or internal mammary artery bypass grafts to coronary arteries from aorta (cardiac revascularization)

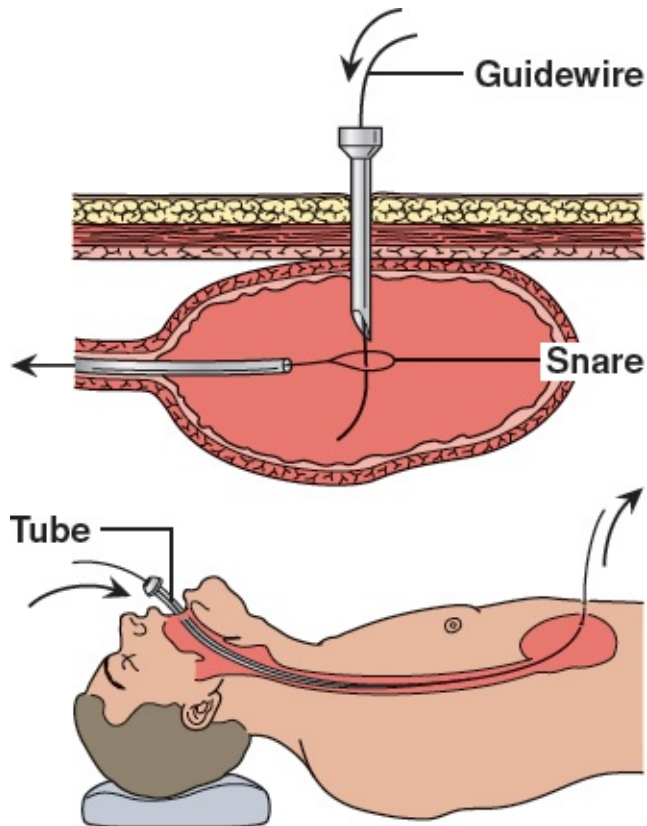


### **Hartmann's pouch**

Oversewing of a rectal stump (or distal colonic stump) after resection of a colonic segment; patient is left with a proximal colostomy

### **PEG**

**Percutaneous Endoscopic Gastrostomy:** Endoscope is placed in the stomach, which is then inflated with air; a needle is passed into the stomach percutaneously, wire is passed through the needle traversing the abdominal wall, and the gastrostomy is then placed by using the Seldinger technique over the wire

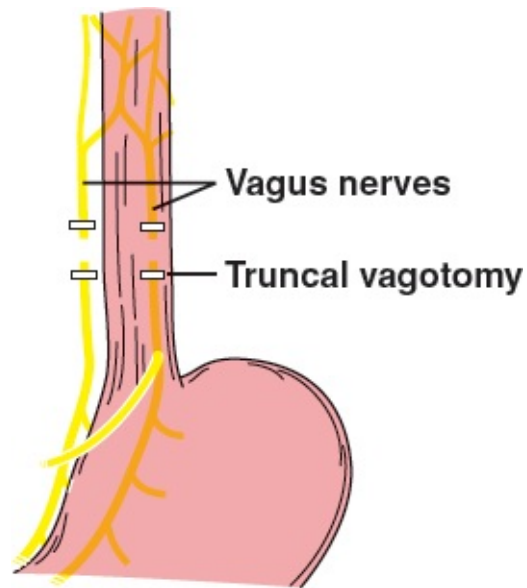


### Hemicolectomy

Removal of a colonic segment (i.e., partial colectomy)

### Truncal vagotomy

Transection of the vagus nerve trunks; must provide drainage procedure to stomach (e.g., gastrojejunostomy or pyloroplasty) because after truncal vagotomy, the **pylorus does not relax**



## **Antrectomy**

Removal of stomach antrum

## **Whipple procedure**

Pancreaticoduodenectomy:

- Cholecystectomy

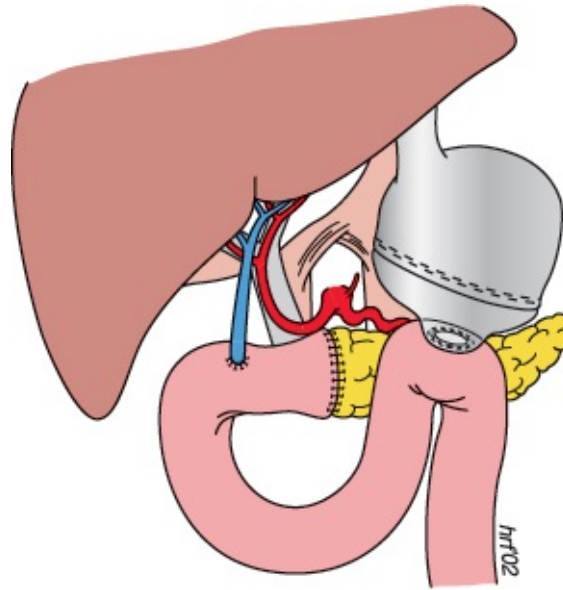
- Truncal vagotomy

- Pancreaticoduodenectomy—removal of the head of the pancreas and duodenum

- Choledochojejunostomy

- Pancreaticojejunostomy (anastomosis of distal pancreas remnant to the jejunum)

- Gastrojejunostomy (anastomosis of stomach to jejunum)



### **Excisional biopsy**

Biopsy with complete excision of all suspect tissue (mass)

### **Incisional biopsy**

Biopsy with incomplete removal of suspect tissue (incises tissue from mass)

### **Tracheostomy**

Placement of airway tube into trachea surgically or percutaneously

# Chapter 14 Wounds

**Define the following terms:**

**Primary wound closure**

Suture wound closed immediately (a.k.a. “first intention”)

**Secondary wound closure**

Wound is left open and heals over time **without sutures** (a.k.a. “secondary intention”); it heals by granulation, contraction, and epithelialization over weeks (leaves a larger scar)

**Delayed primary closure (DPC)**

Suture wound closed 3 to 5 days AFTER incision (classically 5 days)

**How long a sutured wound epithelializes?**

24 to 48 hours

**After a primary closure, when should the dressing be removed?**

POD #2

**When can a patient take a shower after a primary closure?**

Anytime after POD #2 (after wound epithelializes)

**What is a wet-to-dry dressing?**

Damp (not wet) gauze dressing placed over a granulating wound and then allowed to dry to the wound; removal allows for “microdébridement” of the wound

**What inhibits wound healing?**

Infection, ischemia, diabetes mellitus, malnutrition, anemia, steroids, cancer, radiation, and smoking

**What reverses the deleterious effects of steroids on wound healing?**

Vitamin A

**What is an abdominal wound dehiscence?**

Opening of the fascial closure (not skin); treat by returning to the O.R. for immediate fascial reclosure

**What is Dakin solution?**

Dilute sodium hypochlorite (**bleach**) used on contaminated wounds

**What is negative-pressure wound therapy (a.k.a. “wound vac”)?**

Occlusive dressing with sponge and negative pressure system used to accelerate wound healing in acute and chronic wounds

**What are the components of an negative pressure wound therapy (NPWT) system?**

- . Negative pressure unit
- . Occlusive dressing
- . Foam sponge

**What are the potential advantages of negative-pressure wound therapy?**

Draws wound edges together, removes exudates and infectious materials, reduces edema, promotes perfusion, and facilitates formation of granulation tissue

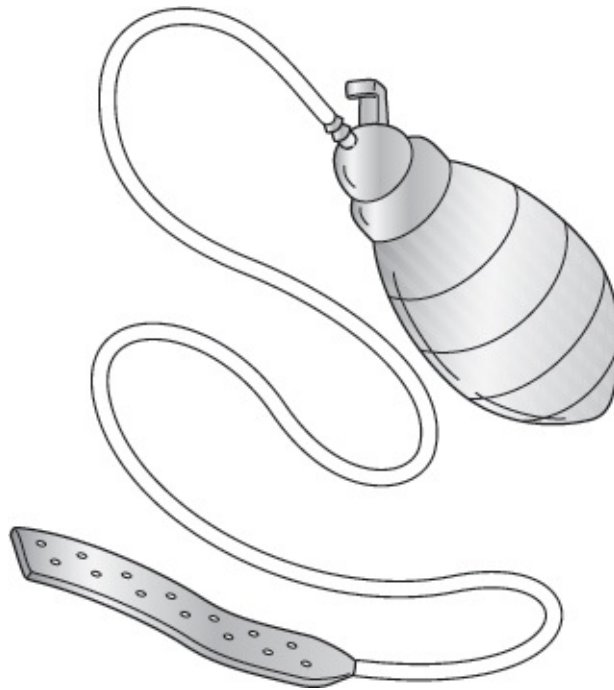
# Chapter 15 Drains and Tubes

## What is the purpose of drains?

- . Withdrawal of fluids
- . Apposition of tissues to remove a potential space by suction
- . Monitor fluid output

## What is a Jackson–Pratt (JP) drain?

Closed drainage system attached to a suction bulb (“grenade”)



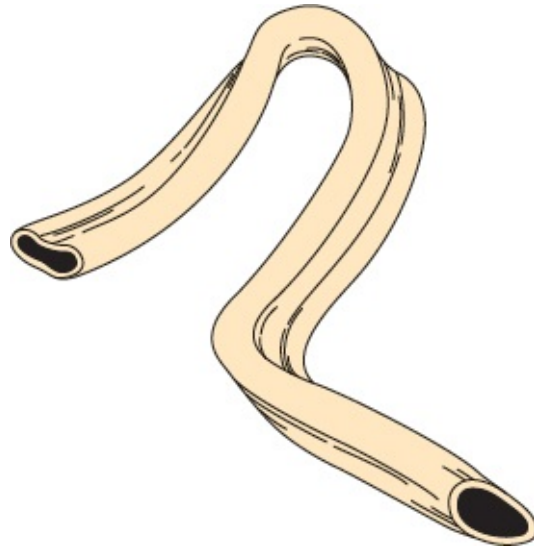
## What are the “three S’s” of Jackson–Pratt drain removal?

- . Stitch removal
- . Suction discontinuation
- . Slow, steady pull (cover with 4 × 4 to reduce splashing)

## What is a Penrose drain?

Open drainage system composed of a thin rubber hose; associated with increased

infection rate in clean wounds



**Define the following terms:**

**G-tube**

Gastrostomy tube; used for drainage or feeding

**J-tube**

Jejunostomy tube; used for feeding; may be a small-needle catheter (remember to flush after use or it will clog) or a large, red rubber catheter

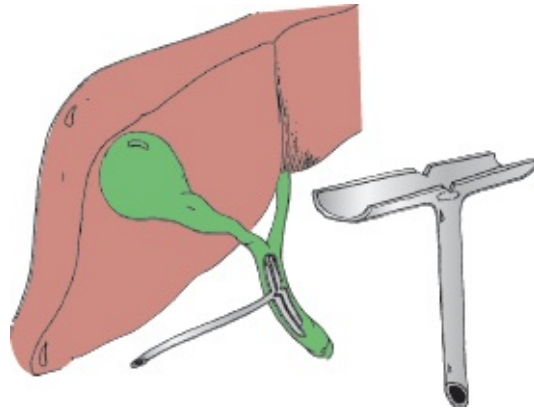
**Cholecystostomy tube**

Tube placed surgically or percutaneously with ultrasound guidance to drain the gallbladder

**T-tube**

Tube placed in the common bile duct with an ascending and descending limb that forms a “T”

Drains percutaneously; placed after common bile duct exploration



## CHEST TUBES

### What is a thoracostomy tube?

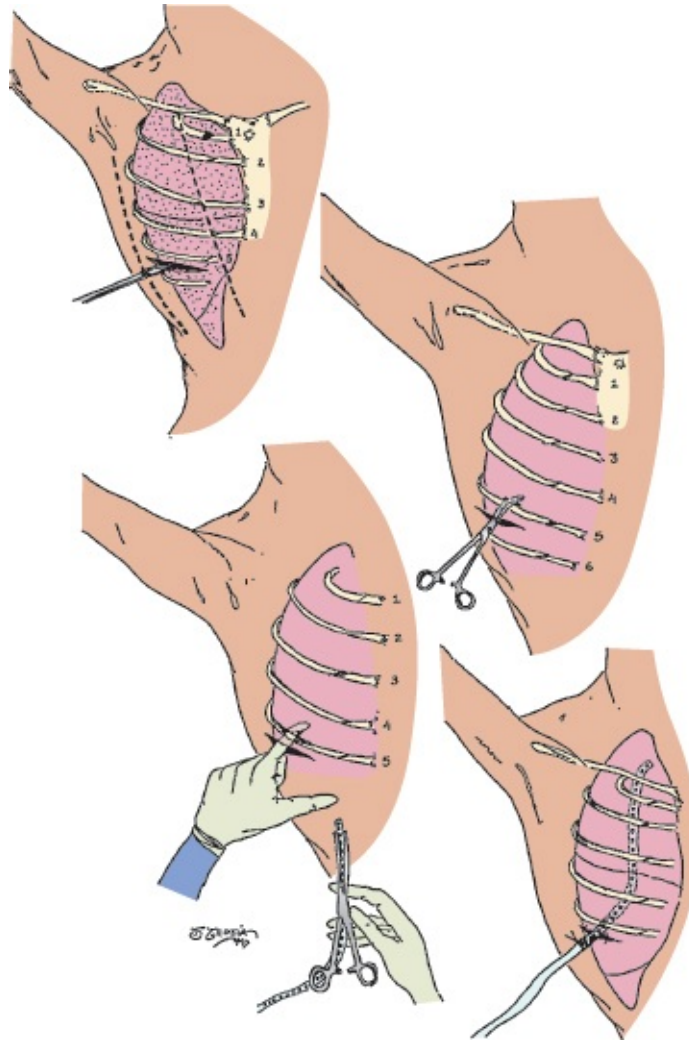
Chest tube

### What is the purpose of a chest tube?

To appose the parietal and visceral pleura by draining blood, pus, fluid, chyle, or air

### How is a chest tube inserted?

- . Administer local anesthetic
- . Incise skin in the fourth or fifth intercostal space between the mid- and anterior-axillary lines
- . Perform blunt Kelly-clamp dissection **over** the rib into the pleural space
- . Perform finger exploration to confirm intrapleural placement
- . Place tube posteriorly and superiorly



**Is the chest tube placed under or over the rib?**

**Over** to avoid the vessels and nerves

**What are the goals of chest tube insertion?**

**Drain** the pleural cavity

**Appose** parietal and visceral pleura to seal any visceral pleural holes

**In most cases, where should the chest tube be positioned?**

Posteriorly into the apex

**How can you tell on CXR if the last hole on the chest tube is in the pleural cavity?**

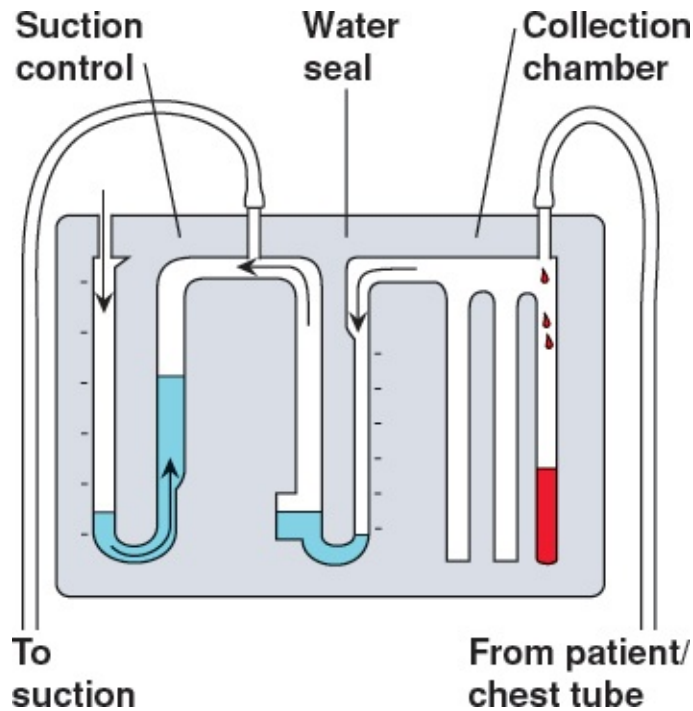
Last hole is cut through the radiopaque line in the chest tube and is seen on CXR as a break in the line, which should be within the pleural cavity

## What are the centimeter measurements on a chest tube?

Centimeters from the last hole on the chest tube

## What is the chest tube connected to?

Suction, waterseal, collection system (three-chambered box, e.g., Pleurovac®)



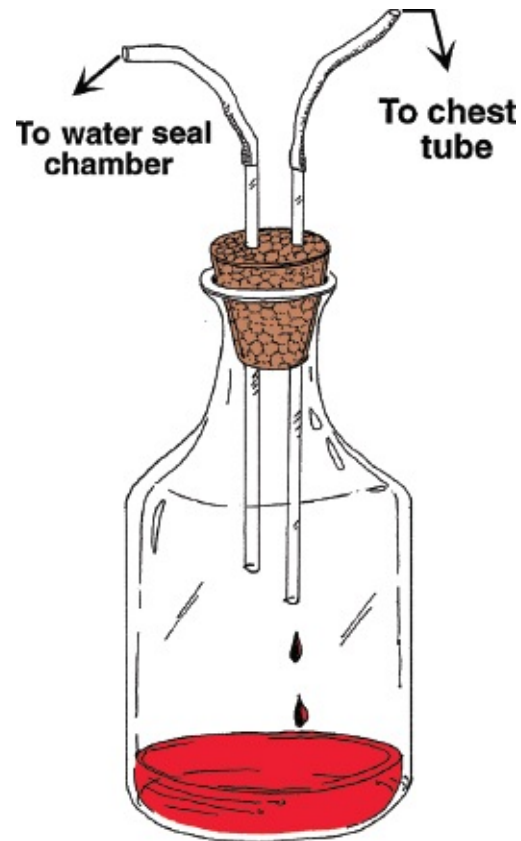
## What are the three chambers of the Pleurovac®?

- . Collection chamber
- . Water seal
- . Suction control

## Describe how each chamber of the Pleurovac® box works as the old three-bottle system:

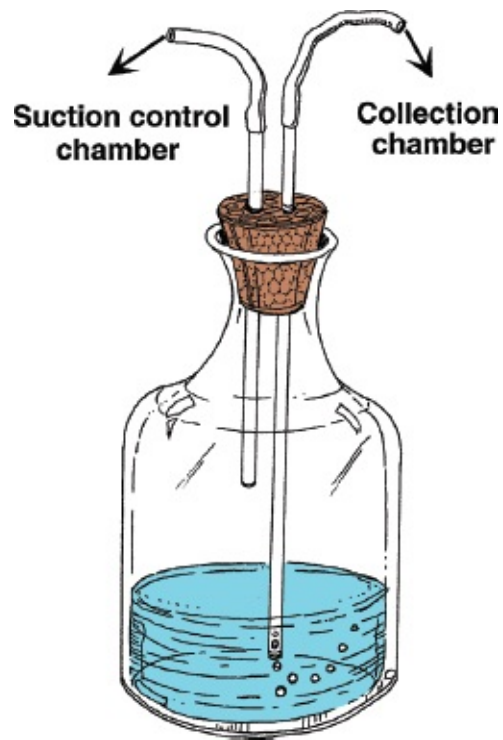
### Collection chamber

Collects fluid, pus, blood, or chyle and measures the amount; connects to the water seal bottle and to the chest tube



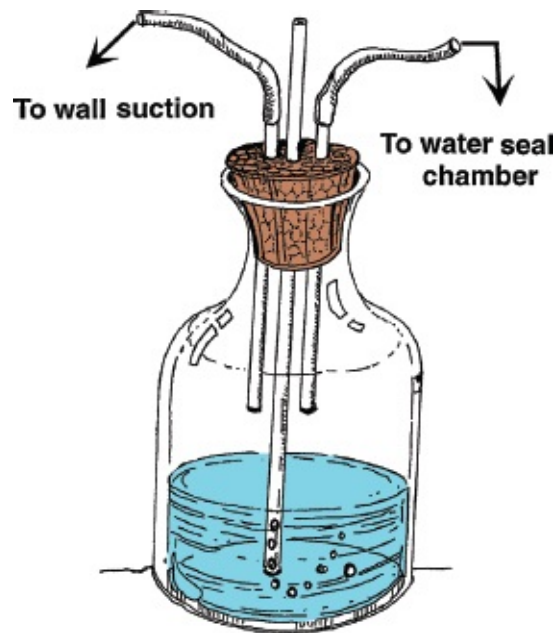
### **Water-seal chamber**

One-way valve—allows air to be removed from the pleural space; does not allow air to enter pleural cavity; connects to the suction control bottle and to the collection chamber



### **Suction-control chamber**

Controls the amount of suction by the height of the water column; sucking in room air releases excessive suction; connects to wall suction and to the water seal bottle



**Give a good example of a water seal.**

Place a straw in a cup of water—you can blow air out but if you suck in, the straw fills with water and thus forms a one-way valve for air just like the chest tube water seal

### **How is a chest tube placed on water seal?**

By removing the suction; a tension pneumothorax (PTX) cannot form because the one-way valve (water seal) allows release of air buildup

### **Should a chest tube ever be clamped off?**

No, except to “run the system” **momentarily**

### **What does it mean to “run the system” of a chest tube?**

To see if the air leak is from a leak in the pleural cavity (e.g., hole in lung) or from a leak in the tubing

**Momentarily** occlude the chest tube and if the air leak is still present, it is from the tubing or tubing connection, not from the chest

### **How can you tell if the chest tube is “tidling”?**

Take off suction and look at the water seal chamber: Fluid should move with respiration/ventilation (called “tidling”); this decreases and ceases if the pleura seals off the chest tube

### **How can you check for an air leak?**

Look at the water seal chamber on suction:

If bubbles pass through the water seal fluid, a large air leak (i.e., air leaking into chest tube) is present; if no air leak is evident on suction, remove suction and ask the patient to cough

If air bubbles through the water seal, a small air leak is present

### **What is the usual course for removing a chest tube placed for a PTX?**

- . Suction until the PTX resolves and the air leak is gone
- . Water seal for 24 hours
- . Remove the chest tube if no PTX or air leak is present after 24 hours of water seal

### **How fast is a small, stable PTX absorbed?**

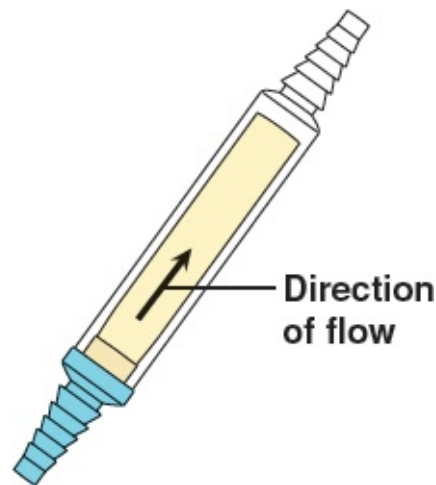
≈1% daily; therefore, a 10% PTX by volume will absorb in ≈10 days

## How should a chest tube be removed?

- . Cut the stitch
- . Ask the patient to exhale or inhale maximally
- . Rapidly remove the tube (split second) and at same time, place petroleum jelly gauze covered by  $4 \times 4$ 's and then tape
- . Obtain a CXR

## What is a Heimlich valve?

One-way flutter valve for a chest tube



## NASOGASTRIC TUBES (NGT)

### How should an NGT be placed?

- . Use lubrication and have suction up on the bed
- . Use anesthetic to numb nose
- . Place head in flexion
- . Ask patient to drink a small amount of water when the tube is in the back of the throat and to swallow the tube; if the patient can talk without difficulty and succus returns, the tube should be in the stomach (Get an x-ray if there is any question about position)

### How should an NGT be removed?

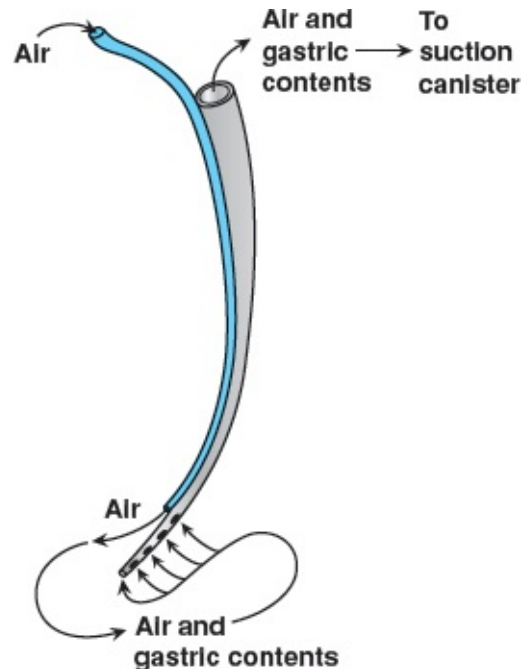
Give patient a tissue, discontinue suction, untape nose, remove quickly, and tell patient to blow nose

## What test should be performed before feeding via any tube?

High abdominal x-ray to confirm placement into the GI tract and NOT the lung!

## How does an NGT work?

**Sump pump**, dual lumen tube—the large clear tube is hooked to suction and the small blue tube allows for air sump (i.e., circuit sump pump with air in the blue tube and air and succus sucked out through the large clear lumen)



## How can you check to see if the NGT is working?

Blue port will make a sucking noise; always keep the blue port opening above the stomach

## Should an NGT be placed on continuous or intermittent suction?

Continuous low suction—side holes disengage if they are against mucosa because of the sump mechanism and multiple holes

## What happens if the NGT is clogged/not functional?

Tube will not decompress the stomach and will keep the low esophageal sphincter (LES) open (i.e., a setup for aspiration)

## How should an NGT be unclogged?

Saline-flush the clear port, reconnect to suction, and flush air down the blue

sump port

### **What is the common cause of excessive NGT drainage?**

Tip of the NGT is inadvertently placed in the duodenum and drains the pancreatic fluid and bile; an x-ray should be taken and the tube repositioned into the stomach

### **What is the difference between a feeding tube (Dobbhoff tube) and an NGT?**

A feeding tube is a thin tube weighted at the end that is not a sump pump but a simple catheter; usually placed past the pylorus, which is facilitated by the weighted end and peristalsis

## **FOLEY CATHETER**

### **What is a Foley catheter?**

Catheter into the bladder, allowing accurate urine output determination

### **What is a coudé catheter?**

Foley catheter with a small, curved tip to help maneuver around a large prostate

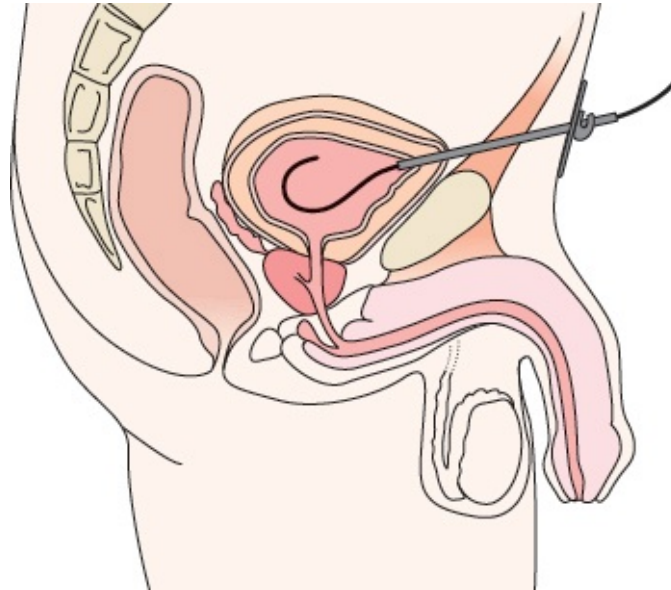


**If a Foley catheter cannot be inserted, what are the next steps?**

- . Anesthetize the urethra with a sterile local anesthetic (e.g., lidocaine jelly)
- . Try a **larger** Foley catheter
- . Try coude catheter
- . Consult Urology

**What if a patient has a urethral injury and a Foley cannot be placed?**

Suprapubic catheter will need to be placed



## CENTRAL LINES

**What are they?**

Catheters placed into the major veins (central veins) via subclavian, internal jugular, or femoral vein approaches

**What major complications result from placement?**

PTX (always obtain postplacement CXR), bleeding, malposition (e.g., into the neck from subclavian approach), dysrhythmias

**In long-term central lines, what does the “cuff” do?**

Allows ingrowth of fibrous tissue, which:

1. Holds the line in place
2. Forms a barrier to the advance of bacteria

**What is a Hickman® or Hickman-type catheter?**

External central line tunneled under the skin with a “cuff”

**What is a Port-A-Cath®?**

Central line that has a port buried under the skin, which must be accessed through the skin (percutaneously)

**What is a “cordis”?**

Large central line catheter; used for massive fluid resuscitation or for placing a Swan–Ganz catheter

**If you try to place a subclavian central line unsuccessfully, what must you do before trying the other side?**

Get a CXR—a bilateral pneumothorax can be fatal!

**How can diameter in mm be determined from a French measurement?**

Divide the French size by  $\pi$  or 3.14 (e.g., a 15 French tube has a diameter of 5 mm)

# Chapter 16 Surgical Anatomy Pearls

**What is the drainage of the left testicular vein?**

Left renal vein

**What is the drainage of the right testicular vein?**

IVC

**Which artery bleeds in bleeding duodenal ulcers?**

Gastroduodenal artery

**What is Morrison's pouch?**

Hepatorenal recess; the most posterior cavity within the peritoneal cavity

**Where are the blood vessels on a rib?**

Vein, Artery, and Nerve (VAN) are underneath the rib (thus, place chest tubes and thoracentesis needles above the rib!)

**What is the order of the femoral vessels?**

Femoral vein is medial to the femoral artery (Think: “NAVEL” for the order of the right femoral vessels—Nerve, Artery, Vein, Empty space, Lymphatics)

**What is Hesselbach's triangle?**

The area bordered by:

1. Inguinal ligament
2. Epigastric vessels
3. Lateral border of the rectus sheath

**What nerve is located on top of the spermatic cord?**

Ilioinguinal nerve

**What is Calot's triangle?**

The area bordered by:

1. Cystic duct
  2. Common hepatic duct
  3. Cystic artery
- (Pronounced “kal-ohs”)

### **What is Calot’s node?**

Lymph node found in Calot’s triangle

### **What separates the right and left lobes of the liver?**

Cantle’s line—a line drawn from the IVC to just left of the gallbladder fossa

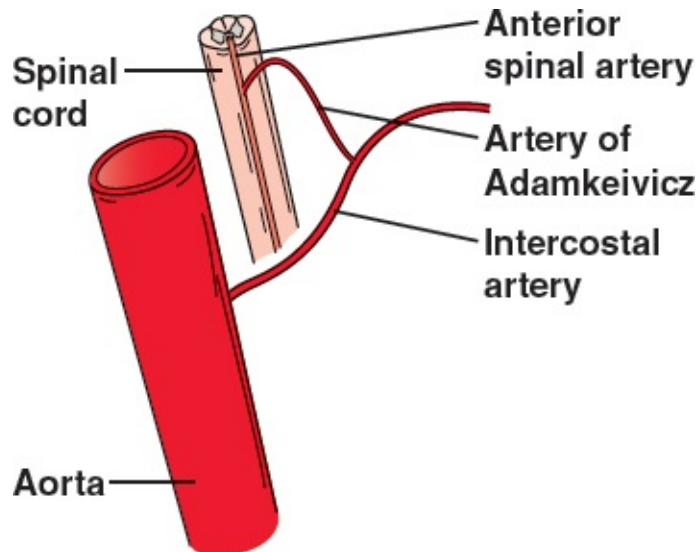
### **What is the gastrinoma triangle?**

Triangle where >90% of gastrinomas are located, bordered by:

1. Junction of the second and third portions of the duodenum
2. Cystic duct
3. Pancreatic neck

### **Which artery is responsible for anterior spinal syndrome?**

Artery of Adamkiewicz (pronounced “ah-dahm’kē-ā’vich”)



### **Where is McBurney’s point?**

One third the distance from the anterior superior iliac spine to the umbilicus (estimate of the position of the appendix)

### **How can you find the appendix after you find the cecum?**

Trace the taeniae back as they converge on the origin of the appendix

**What are the white lines of Toldt?**

Lateral peritoneal reflections of the ascending and descending colon

**What is the strongest layer of the small bowel?**

Submucosa (*not* the serosa, think: SUBmucosa = SUPerior)

**Which parts of the GI tract do not have a serosa?**

Esophagus

Middle and distal rectum

**What are the plicae circulares?**

Plicae = folds, circulares = circular; thus, the circular folds of mucosa of the small bowel

**What are the major structural differences between the jejunum and ileum?**

Jejunum—long vasa rectae; large plicae circulares; thicker wall

Ileum—shorter vasa rectae; smaller plicae circulares; thinner wall (Think: Ileum = Inferior vasa rectae, Inferior plicae circulares, and Inferior wall)

**What are the major anatomic differences between the colon and the small bowel?**

Colon has taeniae coli, haustra, and appendices epiploicae (fat appendages), whereas the small intestine is smooth

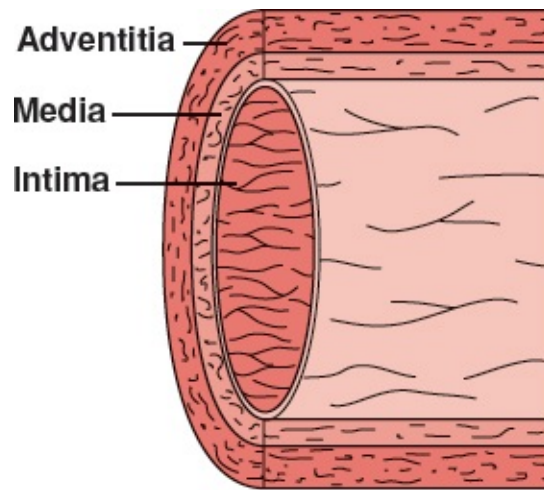
**How far up does the diaphragm extend?**

To the nipples in men (fourth intercostal space; thus, the abdomen extends to the level of the nipples)

**Which dermatome is at the umbilicus?**

T10

**What are the major layers of an artery?**



# SECTION II

## **Background Surgical Information**

# Chapter 17 Fluids and Electrolytes

**What are the two major body fluid compartments?**

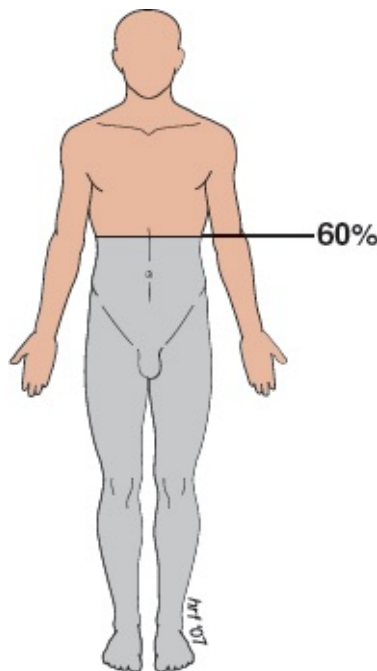
- . Intracellular
- . Extracellular

**What are the two subcompartments of extracellular fluid?**

- . Interstitial fluid (in between cells)
- . Intravascular fluid (plasma)

**What percentage of body weight is in fluid?**

60%



**What percentage of body fluid is intracellular?**

66%

**What percentage of body fluid is extracellular?**

33%

**What is the composition of body fluid?**

Fluids = 60% total body weight:

Intracellular = 40% total body weight

Extracellular = 20% total body weight

(Think: 60, 40, 20)

**On average, what percentage of ideal body weight does blood account for in adults?**

≈7%

**How many liters of blood are in a 70-kg man?**

$0.07 \times 70 = 5$  liters

**What is the physiologic response to hypovolemia?**

Sodium/H<sub>2</sub>O retention via renin → aldosterone, water retention via ADH, vasoconstriction via angiotensin II and sympathetics, low urine output and tachycardia (early), hypotension (late)

## THIRD SPACING

**What is it?**

Fluid accumulation in the interstitium of tissues, as in edema (think of the intravascular and intracellular spaces as the first two spaces)

**When does “third-spacing” occur postoperatively?**

Third-spaced fluid tends to mobilize back into the intravascular space around POD #3

**What are the classic signs of third spacing?**

Tachycardia

Decreased urine output

**What is the treatment?**

IV hydration with isotonic fluids

**What are the surgical causes of the following conditions:**

**Metabolic acidosis**

Loss of bicarbonate: diarrhea, ileus, fistula, high-output ileostomy, carbonic anhydrase inhibitors

Increase in acids: lactic acidosis (ischemia), ketoacidosis, renal failure, necrotic tissue

**Hypochloremic alkalosis**

NGT suction, loss of gastric HCl through vomiting/NGT

**Metabolic alkalosis**

Vomiting, NG suction, diuretics, alkali ingestion, mineralocorticoid excess

**Respiratory acidosis**

Hypoventilation (e.g., CNS depression), drugs (e.g., morphine), PTX, pleural effusion, parenchymal lung disease, acute airway obstruction

**Respiratory alkalosis**

Hyperventilation (e.g., anxiety, pain, fever, wrong ventilator settings)

**What is the “classic” acid–base finding with significant vomiting or NGT suctioning?**

Hypokalemic and hypochloremic metabolic alkalosis

**Why hypokalemia with NGT suctioning?**

Loss in gastric fluid—loss of HCl causes alkalosis, driving  $K^+$  into cells

**What is the treatment for hypokalemic and hypochloremic metabolic alkalosis?**

IVF,  $Cl^-/K^+$  replacement (e.g., NS with KCl)

**What is paradoxical alkalotic aciduria?**

Seen in severe hypokalemic, hypovolemic, and hypochloremic metabolic alkalosis with paradoxical metabolic alkalosis of serum and acidic urine

**How does paradoxical alkalotic aciduria occur?**

$H^+$  is lost in the urine in exchange for  $Na^+$  in an attempt to restore volume

**With paradoxical alkalotic aciduria, why is  $H^+$  preferentially lost?**

H<sup>+</sup> is exchanged preferentially into the urine instead of K<sup>+</sup> because of the low concentration of K<sup>+</sup>

### **What can be followed to assess fluid status?**

Urine output, base deficit, lactic acid, vital signs, weight changes, skin turgor, jugular venous distention (JVD), mucosal membranes, rales (crackles), central venous pressure, PCWP, chest x-ray findings

### **With hypovolemia, what changes occur in vital signs?**

Tachycardia, tachypnea, initial rise in diastolic blood pressure because of clamping down (peripheral vasoconstriction) with subsequent decrease in both systolic and diastolic blood pressures, pulse pressure variability during inspiration on positive pressure ventilation

### **How can the estimated levels of daily secretions from bile, gastric, and small-bowel sources be remembered?**

Alphabetically and numerically: **BGS** and **123** or **B1, G2, S3**, because **B**ile, **G**astric, and **S**mall bowel produce roughly **1 L, 2 L, and 3 L**, respectively!

### **What is the correct diagnosis?**

**57-year-old man develops confusion and wide swings in heart rate and systolic blood pressure POD #2 after an appendectomy for a perforated appendix; sats = 99%, HCT stable, electrolytes normal, chest x-ray normal**

Alcohol withdrawal

**34-year-old in the ICU s/p laparotomy with fascia closed, decreased urine output, increased peak airway pressure, decreased CVP, normal chest x-ray, normal EKG**

Abdominal compartment syndrome

**A 77-year-old man s/p laparoscopic cholecystomy returns to the clinic with a palpable lower abdominal mass, confusion, and weak urine stream**

Urinary retention

### **Name the diagnostic modality:**

**74-year-old female s/p ex lap now POD #4 with acute onset of shortness of breath; ABG reveals hypoxia and hypocapnia**

Chest CTA to rule out pulmonary embolism

## **COMMON IV REPLACEMENT FLUIDS (ALL VALUES ARE PER LITER)**

**What comprises normal saline (NS)?**

154 mEq of  $\text{Cl}^-$

154 mEq of  $\text{Na}^+$

**What comprises 1/2 NS?**

77 mEq of  $\text{Cl}^-$

77 mEq of  $\text{Na}^+$

**What comprises 1/4 NS?**

39 mEq of  $\text{Cl}^-$

39 mEq of  $\text{Na}^+$

**What comprises Lactated Ringer's (LR)?**

130 mEq  $\text{Na}^+$

109 mEq  $\text{Cl}^-$

28 mEq lactate

4 mEq  $\text{K}^+$

3 mEq  $\text{Ca}^+$

**What comprises D5W?**

5% dextrose (50 g) in  $\text{H}_2\text{O}$

**What accounts for tonicity?**

Mainly electrolytes; thus, NS and LR are both isotonic, whereas 1/2 NS is hypotonic to serum

**What happens to the lactate in LR in the body?**

Converted into bicarbonate; thus, LR cannot be used as a maintenance fluid

because patients would become alkalotic

### **IVF replacement by anatomic site:**

#### **Gastric (NGT)**

D5 1/2 NS + 20 KCl

#### **Biliary**

LR  $\pm$  sodium bicarbonate

#### **Pancreatic**

LR  $\pm$  sodium bicarbonate

#### **Small bowel (ileostomy)**

LR

#### **Colonic (diarrhea)**

LR  $\pm$  sodium bicarbonate

## **CALCULATION OF MAINTENANCE FLUIDS**

### **What is the 4/2/1 rule?**

Maintenance IV fluids for hourly rate:

4 mL/kg for the first 10 kg

2 mL/kg for the next 10 kg

1 mL/kg for every kg over 20

### **What is the maintenance rate for a 70-kg man?**

Using 4/2/1:

$$4 \times 10 \text{ kg} = 40$$

$$2 \times 10 \text{ kg} = 20$$

$$1 \times 50 \text{ kg} = 50$$

Total = 110 mL/hr maintenance rate

### **What is the common adult maintenance fluid?**

D5 1/2 NS with 20 mEq KCl/L

**What is the common pediatric maintenance fluid?**

D5 1/4 NS with 20 mEq KCl/L (use 1/4 NS because of the decreased ability of children to concentrate urine)

**Why should sugar (dextrose) be added to maintenance fluid?**

To inhibit muscle breakdown

**What is the best way to assess fluid status?**

Urine output (unless the patient has cardiac or renal dysfunction, in which case central venous pressure or wedge pressure is often used)

**What is the minimal urine output for an adult on maintenance IV?**

30 mL/hr (0.5 cc/kg/hr)

**What are the common isotonic fluids?**

NS, LR

**What is a bolus?**

Volume of fluid given IV rapidly (e.g., 1 L over 1 hour); used for increasing intravascular volume, and isotonic fluids should be used (i.e., NS or LR)

**After a laparotomy, when should a patient's fluid be "mobilized"?**

Classically, POD #3; the patient begins to "mobilize" the third-space fluid back into the intravascular space

## ELECTROLYTE IMBALANCES

### ■ Hyperkalemia

**What is the normal range for potassium level?**

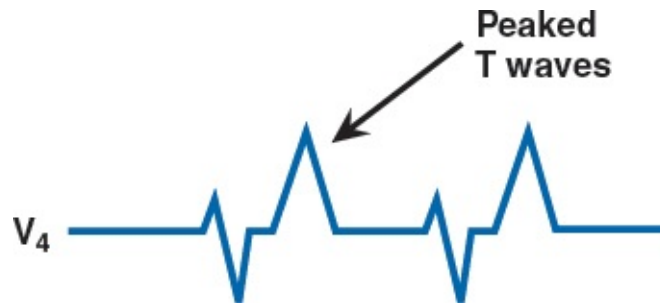3.5 to 5.0 mEq/L

**What are the surgical causes of hyperkalemia?**

Iatrogenic overdose, blood transfusion, renal failure, diuretics, acidosis, tissue destruction (injury/hemolysis)

**What are the ECG findings?**

**Peaked T waves**, depressed ST segment, prolonged PR, wide QRS, bradycardia, ventricular fibrillation

**What are the critical values?**

$K^+ > 6.5$

**What is the nonacute treatment?**

Furosemide (Lasix®), sodium polystyrene sulfonate (Kayexalate®)

**What is the acronym for the treatment of acute symptomatic hyperkalemia?**

**“CB DIAL K”:**

Calcium  
Bicarbonate  
Dialysis  
Insulin/dextrose  
Albuterol  
Lasix  
Kayexalate

**What is “pseudohyperkalemia”?**

Spurious hyperkalemia as a result of falsely elevated  $K^+$  in sample from sample hemolysis

**What acid–base change lowers the serum potassium?**

Alkalosis (thus, give bicarbonate for hyperkalemia)

**What nebulizer treatment can help lower  $K^+$  level?**

Albuterol

## ■ Hypokalemia

### What are the surgical causes?

Diuretics, certain antibiotics, steroids, alkalosis, diarrhea, intestinal fistulae, NG aspiration, vomiting, insulin, insufficient supplementation, amphotericin

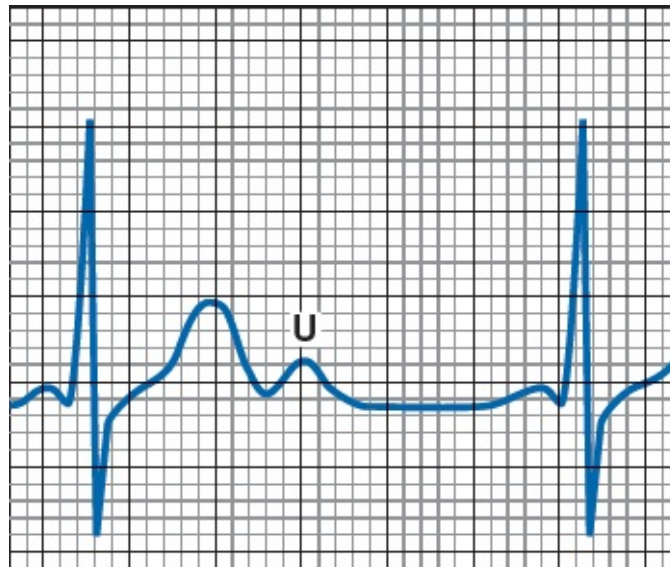
### What are the signs/symptoms?

Weakness, tetany, nausea, vomiting, **ileus**, paraesthesia

### What are the ECG findings?

**Flattening of T waves, U waves, ST segment depression, PAC, PVC, atrial fibrillation**

### What is a U wave?



### What is the rapid treatment?

KCl IV

### What is the most common electrolyte-mediated ileus in the surgical patient?

Hypokalemia

### What electrolyte deficiency can actually cause hypokalemia?

Low magnesium

**What electrolyte must you replace first before replacing  $K^+$ ?**

Magnesium

**Why does hypomagnesemia make replacement of  $K^+$  with hypokalemia nearly impossible?**

Hypomagnesemia inhibits  $K^+$  reabsorption from the renal tubules

## ■ Hyponatremia

**What is the normal range for sodium level?**

135 to 145 mEq/L

**What are the surgical causes?**

Inadequate hydration, diabetes insipidus, diuresis, vomiting, diarrhea, diaphoresis, tachypnea, iatrogenic (e.g., TPN)

**What are the signs/symptoms?**

Seizures, confusion, stupor, pulmonary or peripheral edema, tremors, respiratory paralysis

**What is the usual treatment supplementation slowly over days?**

D5W, 1/4 NS, or 1/2 NS

**How fast should you lower the sodium level in hyponatremia?**

Guideline is  $<12$  mEq/L per day

**What is the major complication of lowering the sodium level too fast?**

Seizures due to cerebral edema (**not** central pontine myelinolysis)

## ■ Hyponatremia

**What are the surgical causes of the following types:**

**Hypovolemic**

Diuretic excess, hypoaldosteronism, vomiting, NG suction, burns, pancreatitis, diaphoresis

**Euvolemic**

SIADH, CNS abnormalities, drugs

**Hypervolemic**

Renal failure, CHF, liver failure (cirrhosis), iatrogenic fluid overload (dilutional)

**What are the signs/symptoms?**

Seizures, coma, nausea, vomiting, ileus, lethargy, confusion, weakness

**What are the treatments of the following types:****Hypovolemic**

NS IV, correct underlying cause

**Euvolemic**

SIADH: furosemide and NS acutely, fluid restriction

**Hypervolemic**

Dilutional: fluid restriction and diuretics

**How fast should you increase the sodium level in hyponatremia?**

Guideline is <12 mEq/L per day

**What may occur if you correct hyponatremia too quickly?**

Central pontine myelinolysis!

**What are the signs of central pontine myelinolysis?**

- . Confusion
- . Spastic quadriplegia
- . Horizontal gaze paralysis

**What is the most common cause of mild postoperative**

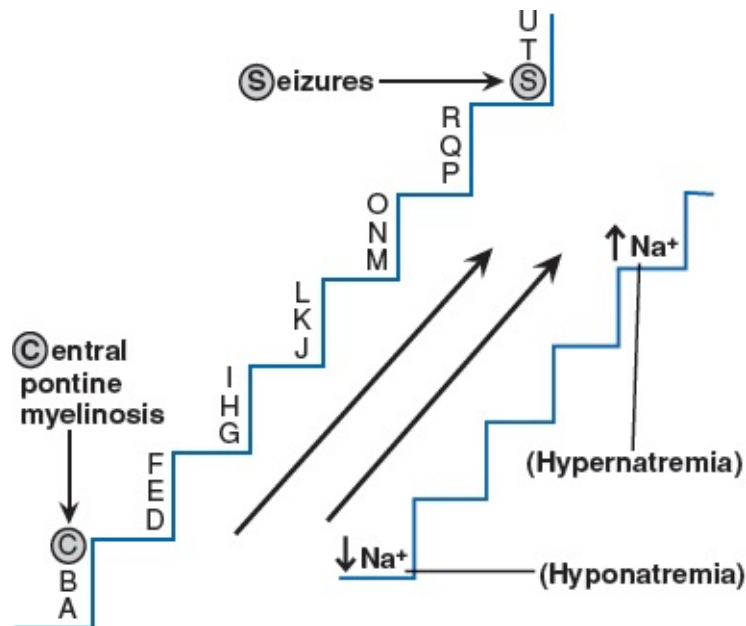
## hyponatremia?

Fluid overload

## How can the sodium level in SIADH be remembered?

SIADH (Sodium Is Always Down Here) = Hyponatremia

## How can you remember the complications of correcting sodium abnormality too quickly?



## “Pseudohyponatremia”

### What is it?

Spurious lab value of hyponatremia as a result of hyperglycemia, hyperlipidemia, or hyperproteinemia

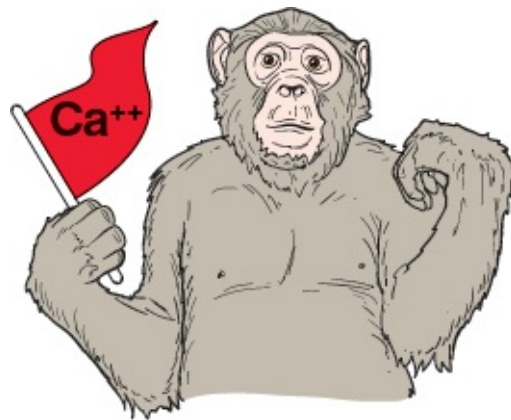
## Hypercalcemia

### What are the causes?

#### “CHIMPANZEES”:

1. Calcium supplementation IV

2. **H**yperparathyroidism (1°/3°) hyperthyroidism
3. **I**mmobility/**I**atrogenic (thiazide diuretics)
4. **M**ets/**M**ilk alkali syndrome
5. **P**aget's disease (bone)
6. **A**ddison's disease/**A**cromegaly
7. **N**eoplasm (colon, lung, breast, prostate, multiple myeloma)
8. **Z**ollinger–**E**llison syndrome (as part of MEN I)
9. **E**xcessive vitamin D
10. **E**xcessive vitamin A
11. **S**arcoid



### **What are the signs/symptoms?**

Hypercalcemia—"Stones, bones, abdominal groans, and psychiatric overtones"

Polydipsia, polyuria, constipation

### **What are the ECG findings?**

Short QT interval, prolonged PR interval

### **What is the acute treatment of hypercalcemic crisis?**

Volume expansion with NS, diuresis with furosemide (not thiazides)

### **What are other options for lowering $\text{Ca}^{+}$ level?**

Steroids, calcitonin, bisphosphonates (pamidronate, etc.), mithramycin, dialysis (last resort)

## **■ Hypocalcemia**

**How can the calcium level be determined with hypoalbuminemia?**

$(4 - \text{measured albumin level}) \times 0.8$ , then add this value to the measured calcium level

**What are the surgical causes?**

Short bowel syndrome, intestinal bypass, vitamin D deficiency, sepsis, acute pancreatitis, osteoblastic metastasis, aminoglycosides, diuretics, renal failure, hypomagnesemia, rhabdomyolysis

**What is Chvostek's sign?**

Facial muscle spasm with tapping of facial nerve (Think: **CH**vostek = **CH**eck)

**What is Trousseau's sign?**

Carpal spasm after occluding blood flow in forearm with blood pressure cuff

**What are the signs/symptoms?**

Chvostek's and Trousseau's signs, perioral paresthesia (early), increased deep tendon reflexes (late), confusion, abdominal cramps, laryngospasm, stridor, seizures, tetany, psychiatric abnormalities (e.g., paranoia, depression, hallucinations)

**What are the ECG findings?**

Prolonged QT and ST intervals (peaked T waves are also possible, as in hyperkalemia)

**What is the acute treatment?**

Calcium gluconate IV

**What is the chronic treatment?**

Calcium PO, vitamin D

**What is the possible complication of infused calcium if the IV infiltrates?**

**Tissue necrosis**; never administer peripherally unless absolutely necessary (calcium gluconate is less toxic than calcium chloride during an infiltration)

**What is the best way to check the calcium level in the ICU?**

Check ionized calcium

## ■ Hypermagnesemia

**What is the normal range for magnesium level?**

1.5 to 2.5 mEq/L

**What is the surgical cause?**

TPN, renal failure, IV over supplementation

**What are the signs/symptoms?**

Respiratory failure, CNS depression, decreased deep tendon reflexes

**What is the treatment?**

Calcium gluconate IV, insulin plus glucose, dialysis (similar to treatment of hyperkalemia), furosemide (Lasix®)

## ■ Hypomagnesemia

**What are the surgical causes?**

TPN, hypocalcemia, gastric suctioning, aminoglycosides, renal failure, diarrhea, vomiting

**What are the signs/symptoms?**

Increased deep tendon reflexes, tetany, asterixis, tremor, Chvostek's sign, ventricular ectopy, vertigo, tachycardia, dysrhythmias

**What is the acute treatment?**

MgSO<sub>4</sub> IV

**What is the chronic treatment?**

Magnesium oxide PO (side effect: diarrhea)

**What is the other electrolyte abnormality that hypomagnesemia may make it impossible to correct?**

Hypokalemia (always fix hypomagnesemia with hypokalemia)

## ■ Hyperglycemia

### **What are the surgical causes?**

Diabetes (poor control), infection, stress, TPN, drugs, lab error, drawing over IV site, somatostatinoma, glucagonoma

### **What are the signs/symptoms?**

Polyuria, hypovolemia, confusion/coma, polydipsia, ileus, DKA (Kussmaul breathing), abdominal pain, hyporeflexia

### **What is the treatment?**

Insulin

### **What is the Weiss protocol?**

Sliding scale insulin

### **What is the goal glucose level in the ICU?**

80 to 110 mg/dL

## ■ Hypoglycemia

### **What are the surgical causes?**

Excess insulin, decreased caloric intake, insulinoma, drugs, liver failure, adrenal insufficiency, gastrojejunostomy

### **What are the signs/symptoms?**

Sympathetic response (diaphoresis, tachycardia, palpitations), confusion, coma, headache, diplopia, neurologic deficits, seizures

### **What is the treatment?**

Glucose (IV or PO)

## ■ Hypophosphatemia

**What are the signs/symptoms?**

Weakness, cardiomyopathy, neurologic dysfunction (e.g., ataxia), rhabdomyolysis, hemolysis, poor pressor response

**What is the complication of severe hypophosphatemia?**

Respiratory failure

**What are the causes?**

GI losses, inadequate supplementation, medications, sepsis, alcohol abuse, renal loss

**What is the critical value?**

<1.0 mg/dL

**What is the treatment?**

Supplement with sodium phosphate or potassium phosphate IV (depending on potassium level)

## ■ Hyperphosphatemia

**What are the signs/symptoms?**

Calcification (ectopic), heart block

**What are the causes?**

Renal failure, sepsis, chemotherapy, hyperthyroidism

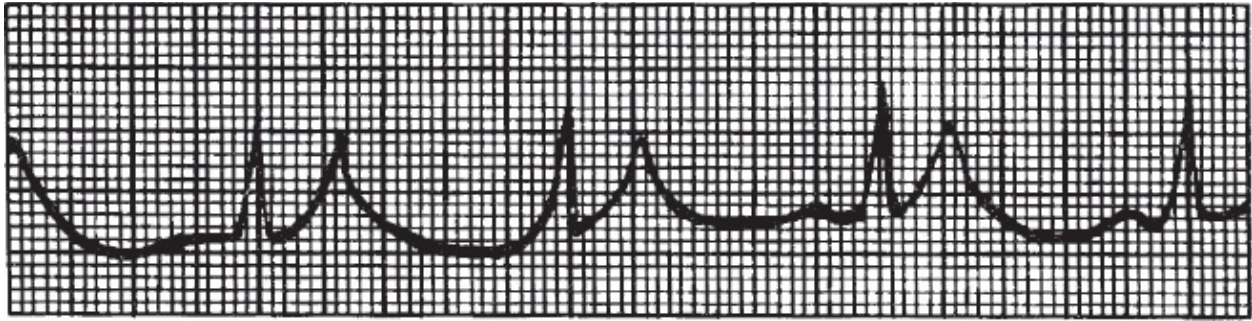
**What is the treatment?**

Aluminum hydroxide (binds phosphate)

## ■ Miscellaneous

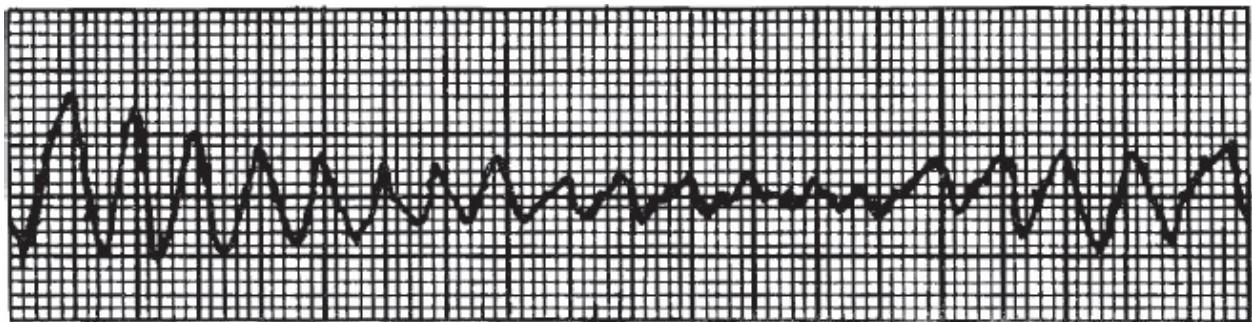
**This ECG pattern is consistent with which electrolyte abnormality?**

Hyperkalemia: peaked T waves



**If hyperkalemia is left untreated, what can occur?**

Ventricular tachycardia/fibrillation → death



**Which electrolyte is an inotrope?**

Calcium

**What are the major cardiac electrolytes?**

Potassium (dysrhythmias), magnesium (dysrhythmias), calcium (dysrhythmias/inotrope)

**What is the most common cause of electrolyte-mediated ileus?**

Hypokalemia

**What is a colloid fluid?**

Protein-containing fluid (albumin)

**An elderly patient goes into CHF (congestive heart failure) on POD #3 after a laparotomy. What is going on?**

Mobilization of the “third-space” fluid into the intravascular space, resulting in fluid overload and resultant CHF (but also must rule out MI)

**What fluid is used to replace NGT (gastric) aspirate?**

D5 1/2 NS with 20 KCl

**What electrolyte is associated with succinylcholine?**

Hyperkalemia

## RAPID FIRE REVIEW

**Name the most likely diagnosis:**

**28-year-old woman s/p total abdominal colectomy and ileostomy now with increased ileostomy output and U waves on EKG**

Hypokalemia

**51-year-old man with alcoholic cirrhosis has a sodium level of 127. The intern corrects the sodium to 140 in 1 hour with hypertonic saline and reveals neurologic signs and symptoms**

Central pontine myelinosis

**56-year-old male alcoholic with new-onset NGT feeds develops hypokalemia, hypophosphatemia, and hypomagnesemia**

Refeeding syndrome

**70-year-old male s/p fall with a subdural develops hypernatremia with copious amounts of urine**

Diabetes insipidus

**80-year-old female s/p fall with a subdural hematoma develops hyponatremia and increase in urine osmolality with normal urine output**

SIADH

# Chapter 18 Blood and Blood Products

**Define the following terms:**

**PT**

Prothrombin Time: Tests extrinsic coagulation pathway

**PTT**

Partial Thromboplastin Time: Tests intrinsic coagulation pathway

**INR**

International Normalized Ratio (reports PT results)

**Packed red blood cells (PRBCs)**

One unit equals  $\approx 300$  mL ( $\pm 50$  mL); no platelets or clotting factors; can be mixed with NS to infuse faster

**Platelets**

Replace platelets with units of platelets (6 to 10 units from single donor or random donors)

**Fresh frozen plasma (FFP)**

Replaces **clotting factors**; (no RBCs/WBCs/platelets)

**Cryoprecipitate (cryo)**

Replaces fibrinogen, von Willebrand factor (vWF), and some clotting factors

**Which electrolyte is most likely to fall with the infusion of stored blood? Why?**

Ionized calcium; the citrate preservative used for the storage of blood binds serum calcium

**What changes occur in the storage of PRBCs?**

↓Ca<sup>+</sup>, ↑K<sup>+</sup>, ↓2,3-DPG, ↑H<sup>+</sup> (↓pH), ↓PMNs

**What is the rough formula for converting Hgb to Hct?**

Hgb × 3 = Hct

**One unit of PRBC increases Hct by how much?**

≈3% to 4%

**Which blood type is the “universal” donor for PRBCs?**

O negative

**Which blood type is the “universal” donor for FFP?**

AB

**What is a type and screen?**

Patient’s blood type is determined and the blood is screened for antibodies; a type and cross from that sample can then be ordered if needed later

**What is a type and cross?**

Patient’s BLOOD is sent to the blood bank and cross-matched for **specific donor units for possible blood transfusion**

**What is thrombocytopenia?**

Low platelet count (<100,000)

**What can be given to help correct platelet dysfunction from uremia, aspirin, or bypass?**

DDAVP (desmopressin)

**What common medication causes platelets to irreversibly malfunction?**

Aspirin (inhibits cyclooxygenase)

**What is Plavix®?**

Clopidogrel—irreversibly inhibits platelet P2Y<sub>12</sub> ADP receptor (blocks fibrin crosslinking of platelets)

**What platelet count is associated with spontaneous bleeding?**

<20,000

**What should the platelet count be before surgery?**

>50,000

**When should “prophylactic” platelet transfusions be given?**

With platelets <10,000 (old recommendation was 20,000)

**How to reverse the effect of Clopidogrel (Plavix®)?**

No reversal known. Many treat with platelet transfusion

**What is microcytic anemia “until proven otherwise” in a man or postmenopausal woman?**

Colon cancer

**Why not infuse PRBCs with Lactated Ringer’s (LR)?**

Calcium in LR may result in coagulation within the IV line (use NS)

**For how long can packed RBCs be stored?**

≈6 weeks (42 days)

**What is the most common cause of transfusion hemolysis?**

ABO incompatibility as a result of **clerical error**

**What is the risk of receiving a unit of blood infected with HIV?**

≈1 in 1,000,000

**What are the symptoms of a transfusion reaction?**

**Fever**, chills, nausea, hypotension, lumbar pain, chest pain, abnormal bleeding

**What is the treatment for transfusion hemolysis?**

**Stop** transfusion; provide fluids; perform diuresis (Lasix) to protect kidneys; alkalinize urine (bicarbonate); give pressors as needed

**What component of the blood transfusion can cause a fever?**

WBCs

**What is the transfusion “trigger” Hgb?**

<7.0

**What is the widely considered “optimal” Hgb in a patient with a history of heart disease or stroke?**

Focus Trial = Liberal (<10 Hgb) vs restrictive (<8 Hgb) Trigger = No difference in mortality or morbidity

**When should aspirin administration be discontinued preoperatively?**

At 1 week because platelets live 7 to 10 days (must use judgment if patient is at risk for stroke or MI; it may be better to continue and use excellent surgical hemostasis in these patients)

**What can move the oxyhemoglobin dissociation curve to the right?**

Acidosis; 2,3-DPG; fever; elevated PCO<sub>2</sub> (to the right means greater ability to release the O<sub>2</sub> to the tissues)

**What is the normal life of RBCs?**

120 days

**What is the normal life of platelets?**

7 to 10 days

**How can the clotting factor for hemophilia A be remembered?**

Think: “**Eight**” sounds like “**A**”

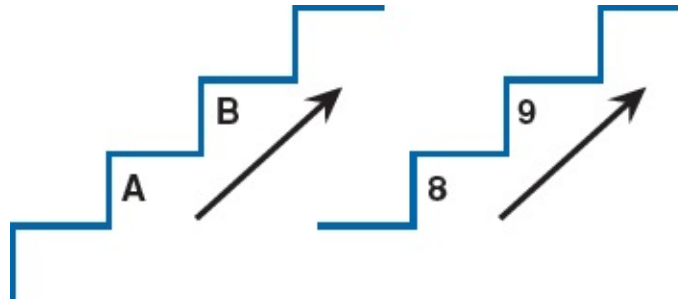
**How do you remember which factors are deficient with hemophilia A and hemophilia B?**

Think alphabetically and chronologically:

**A** before **B**—**8** before **9**

Hemophilia **A** = factor **VIII**

Hemophilia **B** = factor **IX**



**What is von Willebrand's disease?**

Deficiency of vWF and factor VIII:C

**What is used to correct von Willebrand's disease?**

DDAVP or cryoprecipitate

**What coagulation is abnormal with the following disorders:**

**Hemophilia A**

PTT (elevated)

**Hemophilia B**

PTT (elevated)

**von Willebrand's disease**

Bleeding time

**What is the usual "therapeutic" PT?**

With Coumadin®, usually shoot for an INR of 2.0 to 3.0

**What is the acronym basis for the word WARFARIN?**

Wisconsin Alumni Research Foundation-ARIN

**What is the most common inherited hypercoagulable state?**

Factor V Leiden (Think: LEiden = LEader)

## RAPID FIRE REVIEW

**List the blood product or medication(s) that you would give for**

**each of the following patients:**

**18-year-old woman in high-speed motorcycle collision with subdural hematoma and flail chest; platelets = 189,000; fibrinogen = 400, ionized calcium = 2.8; PT 23 (INR = 3.4); PTT = 35**

FFP (fresh frozen plasma)

**44-year-old man involved in a fall from scaffolding going to the operating room for exploratory laparotomy for significant free air on CT scan; platelets = 25,000; PT = 13.1; PTT = 38; fibrinogen = 200**

Platelets

**Patient s/p (status post) prostate resection develops diffuse oozing; platelets = 200,000; PT = 13; PTT = 39**

Amicar® (epsilon-aminocaproic acid) (an antifibrinolytic)

**56-year-old woman 1 hour s/p CABG × 4 on bypass with continued mediastinal bleeding; surgeons confirm excellent surgical hemostasis; the patient is warm, platelets 178,000; PT = 12.9; PTT = 78**

Protamine

**67-year-old patient with liver failure and s/p fall in the operating room for an exploratory laparotomy; the patient develops progressive oozing; the PT and PTT are normalized; platelets = 300,000; fibrinogen = 49.7**

Cryoprecipitate—provides fibrinogen

**Patient with liver failure and poor nutrition with elevated PT that is refractory to multiple transfusions of FFP**

Vitamin K, prothrombin complex concentrate (PCC)

**8-year-old boy with hemophilia A with spontaneous bruising and nosebleed**

Factor VIII

**7-year-old boy with hemophilia B with large right knee**

**hemarthrosis**

Factor IX

**23-year-old woman with von Willebrand's disease who develops bleeding complications**

First try DDAVP; then cryoprecipitate prn

# Chapter 19 Surgical Hemostasis

**What motto is associated with surgical hemostasis?**

“All bleeding stops”

**What is the most immediate method to obtain hemostasis?**

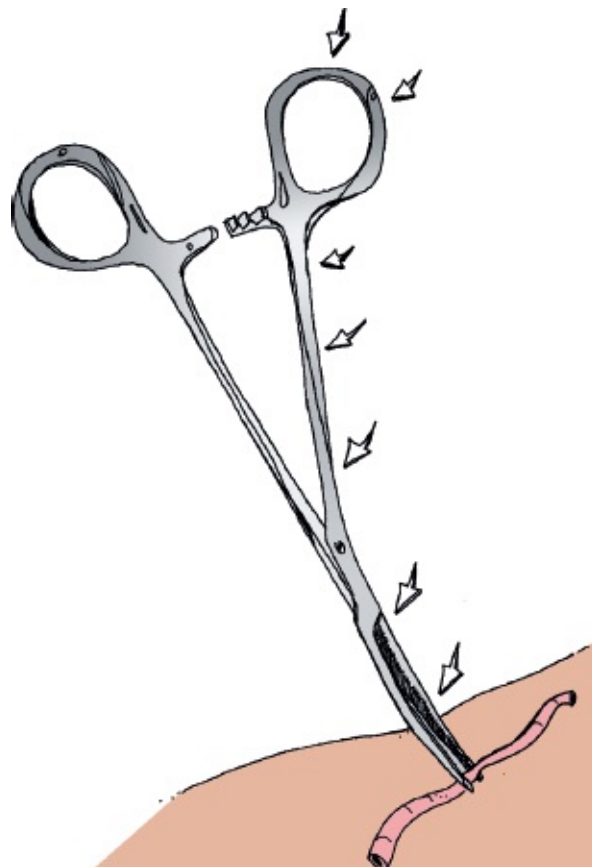
Pressure (finger)

**What is a “Bovie”?**

Electrocautery (designed by Bovie with Cushing for neurosurgery in the 1920s)

**Where should a Bovie be applied to a clamp or pick-up to coagulate a vessel?**

**Anywhere** on the clamp/pick-up

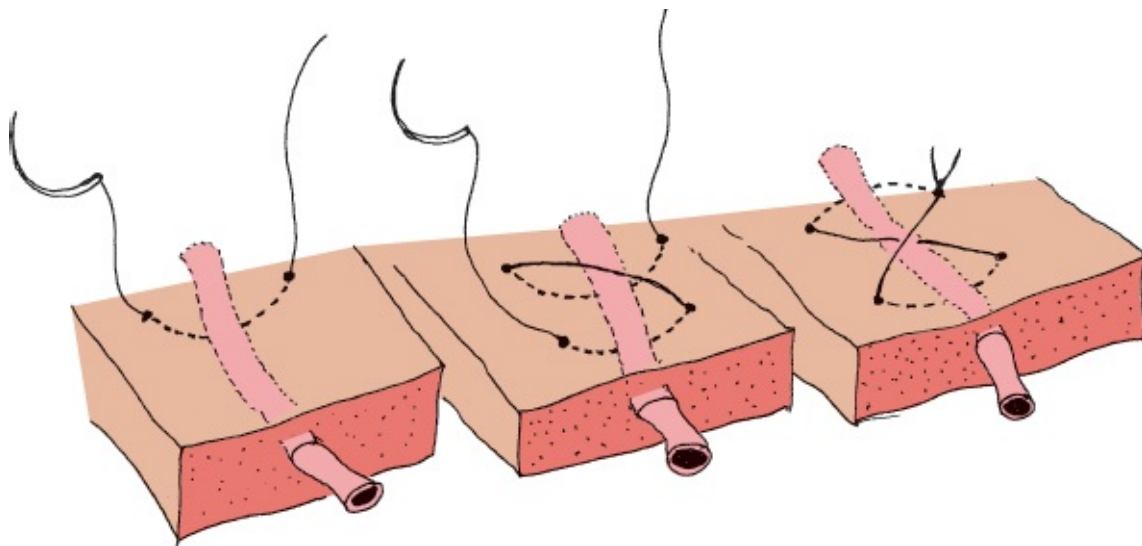


**Should you ever “blindly” place a clamp in a wound to stop bleeding?**

No, you may injure surrounding tissues such as nerves

**What is a figure-of-eight suture?**

Suture ligature placed **twice** in the tissue prior to being tied



# Chapter 20 Common Surgical Medications

## ANTIBIOTICS

### **What is an “antibiogram?”**

List of bacteria and the antibiotic sensitivities at a specific hospital

### **Which antibiotics are commonly used for anaerobic infections?**

Metronidazole, clindamycin, cefoxitin, cefotetan, imipenem, ticarcillin-clavulanic acid, Augmentin<sup>®</sup>, Zosyn<sup>®</sup>

### **Which antibiotics are commonly used for gram-negative infections?**

Gentamicin and other aminoglycosides, ciprofloxacin, aztreonam, third-generation cephalosporins, sulfamethoxazole-trimethoprim

### **Which antibiotic, if taken with alcohol, will produce a disulfiram-like reaction?**

Metronidazole (Flagyl<sup>®</sup>) (disulfiram is Antabuse<sup>®</sup>)

### **What is the drug of choice for treating amoebic infections?**

Metronidazole (Flagyl<sup>®</sup>)

### **Which antibiotic is associated with cholestasis?**

Ceftriaxone (Rocephin<sup>®</sup>)

### **Which antibiotic cannot be given to children or pregnant women?**

Ciprofloxacin (interferes with the growth plate)

### **Is rash (only) in response to penicillins a contraindication to cephalosporins?**

No, but breathing problems, urticaria, and edema in response to penicillins are contraindications to the cephalosporins

### **Describe the following medications:**

#### **Augmentin®**

Amoxicillin and clavulanic acid

#### **Unasyn®**

Ampicillin and sulbactam

#### **Zosyn®**

Piperacillin and tazobactam: Extended spectrum penicillin with  $\beta$ -lactamase inhibitor

#### **Cefazolin (Ancef®)**

First-generation cephalosporin; surgical prophylaxis for **skin flora**

#### **Ceftazidime (Ceftaz®)**

Third-generation cephalosporin; strong activity against *Pseudomonas*

#### **Clindamycin**

Strong activity against gram-negative **anaerobes** such as *Bacteroides fragilis*; adequate gram-positive activity

#### **Gentamicin**

Aminoglycoside used to treat aerobic **gram-negative** bacteria; nephrotoxic, ototoxic; blood peak/trough levels should be monitored

#### **Metronidazole (Flagyl®)**

Used for serious **anaerobic** infections (e.g., diverticulitis); also used to treat amebiasis; patient must abstain from alcohol use during therapy

#### **Vancomycin**

Used to treat methicillin-resistant *Staphylococcus aureus* (MRSA), nephrotoxicity, and red-man syndrome; used orally to treat *Clostridium difficile* pseudomembranous colitis (poorly absorbed from the gut); with IV

administration, peak levels should be maintained >15

### **Ciprofloxacin (Cipro®)**

Quinoline antibiotic with activity against gram-negative bacteria, including *Pseudomonas*

### **Aztreonam (Azactam®)**

Monobactam with gram-negative spectrum

### **Amphotericin**

IV antifungal antibiotic associated with renal toxicity, hypokalemia

### **Fluconazole (Diflucan®)**

Antifungal agent (IV or PO) **not** associated with renal toxicity

### **Nystatin**

PO and topical antifungal

## **STERIODS**

### **Can steroids be stopped abruptly?**

No, steroids should never be stopped abruptly; always taper

### **Which patients need stress-dose steroids before surgery?**

Those who are on steroids, were on steroids in the past year, have suspected hypoadrenalism, or are about to undergo adrenalectomy

### **What is the “stress dose” for steroids?**

**100** mg of hydrocortisone IV every 8 hours and then taper (adults)

### **Which vitamin helps counteract the deleterious effects of steroids on wound healing?**

Vitamin A

## **HEPARIN**

**Describe the action**

Heparin binds with and activates antithrombin III

**What are its uses?**

Prophylaxis/treatment—DVT, pulmonary embolism, stroke, atrial fibrillation, acute arterial occlusion, cardiopulmonary bypass

**What are the side effects?**

Bleeding complications; can cause thrombocytopenia

**What reverses the effects?**

**Protamine IV** (1:100, 1 mg of protamine to every 100 units of heparin)

**What laboratory test should be used to follow effect?**

aPTT—activated partial thromboplastin time

**What is the standard lab target for therapeutic heparinization?**

1.5 to 2.5 times control or measured antifactor Xa level

**Who is at risk for a protamine anaphylactic reaction?**

Patients with type 1 diabetes mellitus, s/p prostate surgery

**What is the half-life of heparin?**

≈90 minutes (1 to 2 hours)

**How long before surgery should it be discontinued?**

From 4 to 6 hours preoperatively

**Does heparin dissolve clots?**

No; it stops the progression of clot formation and allows the body's own fibrinolytic systems to dissolve the clot

**What is LMWH?**

**Low-Molecular-Weight Heparin**

**WARFARIN (COUMADIN®)**

**ACRONYM basis for name?**

Wisconsin Alumni Research Foundation

**Describe its action**

**Inhibits vitamin K–dependent clotting factors II, VII, IX, and X**, (i.e., 2, 7, 9 and 10 [Think:  $2 + 7 = 9$  and **10**]), produced in the liver

**What are its uses?**

Long-term anticoagulation (PO)

**What are its associated risks?**

Bleeding complications, teratogenic in pregnancy, skin necrosis, dermatitis

**What laboratory test should be used to follow its effect?**

PT (prothrombin time) as reported as INR

**What is INR?**

International Normalized Ratio

**What is the classic therapeutic INR?**

INR of 2 to 3

**What is the half-life of effect?**

40 hours; thus, it takes  $\approx 2$  days to observe a change in the PT

**What is PCC?**

Prothrombin Complex Concentrate

**What reverses the action?**

**Cessation**, vitamin K, fresh-frozen plasma, PCC

**How long before surgery should it be discontinued?**

From 3 to 5 days preoperatively and IV heparin should be started; heparin should be discontinued from 4 to 6 hours preoperatively and can be restarted postoperatively; Coumadin<sup>®</sup> can be restarted in a few days

**How can warfarin cause skin necrosis when first started?**

Initially depressed protein C and S result in a HYPERcoagulable state; Avoid by

using heparin concomitantly when starting

## MISCELLANEOUS AGENTS

**What is an antibiotic option for colon/appendectomy coverage if the patient is allergic to penicillin?**

- . IV ciprofloxacin (Cipro®) AND
- . IV clindamycin or IV Flagyl

**If the patient does not respond to a dose of furosemide, should the dose be repeated, increased, or decreased?**

Dose should be doubled if there is no response to the initial dose

**What medication is used to treat promethazine-induced dystonia?**

Diphenhydramine hydrochloride IV (Benadryl®)

**What type of antihypertensive medication is contraindicated in patients with renal artery stenosis?**

ACE inhibitors

**What medications are used to stop seizures?**

Benzodiazepines (e.g., lorazepam [Ativan®]); phenytoin [Dilantin®])

## NARCOTICS

**What medication reverses the effects of narcotic overdose?**

Naloxone (Narcan®), 0.4 mg IV

**What is the half-life of Naloxone?**

0.5 to 1.5 hours. May need to redose when narcotic half-life is longer

## MISCELLANEOUS

**What reverses the effects of benzodiazepines?**

Flumazenil (Romazicon®), 0.2 mg IV

**What is Toradol®?**

Ketorolac = IV NSAID

**What are the risks of Toradol®?**

GI bleed, renal injury, platelet dysfunction

**Why give patients IV Cipro® if they are eating a regular diet?**

No reason—500 mg of Cipro® PO gives the same serum level as 400 mg Cipro® IV! And PO is much cheaper!

**What is clonidine “rebound”?**

Abruptly stopping clonidine can cause the patient to have severe “rebound” hypertension (also seen with  $\beta$ -blockers)

## RAPID FIRE REVIEW

**Give the medical treatment for each surgical disease process:**

**Pheochromocytoma**

$\alpha$ -Blocker

**Zollinger–Ellison syndrome**

Omeprazole

**Carcinoid**

Cyproheptadine

**Desmoid tumors**

Tamoxifen

**Bleeding esophageal varices**

Somatostatin

**Diabetes insipidus**

DDAVP

**Malignant hyperthermia**

Dantrolene

**Necrotizing migrating erythema**

Octreotide

**Pancreatic fistula**

Somatostatin

 **$\beta$ -Blocker overdose**

Glucagon

**Benzodiazepine overdose**

Flumazenil

**Narcotic overdose**

Narcan

**Melanoma metastasis**

Interferon

**Heparin overdose**

Protamine

**Name the most likely diagnosis:**

**56-year-old man on IV heparin with atrial fibrillation develops thrombocytopenia**

HIT (heparin-induced thrombocytopenia)

# Chapter 21 Complications

## ATELECTASIS

### **What is it?**

Collapse of the alveoli

### **What are the signs?**

Fever, decreased breath sounds with rales, tachypnea, tachycardia, and increased density on CXR

### **What is its claim to fame?**

Most common cause of fever during PODs #1 to #2

### **What prophylactic measures can be taken?**

Preoperative smoking cessation, incentive spirometry, good pain control

### **What is the treatment?**

Postoperative **incentive spirometry**, deep breathing, coughing, early ambulation, NT suctioning, and chest PT

## POSTOPERATIVE RESPIRATORY FAILURE

### **What is it?**

Respiratory impairment with increased respiratory rate, shortness of breath, dyspnea

### **What is the treatment?**

Supplemental O<sub>2</sub>, chest PT; suctioning, intubation, and ventilation if necessary

### **What is the initial workup?**

ABG, CXR, EKG, pulse oximetry, and auscultation

### **What are the indications for intubation and ventilation?**

Cannot protect airway (unconscious), excessive work of breathing, progressive **hypoxemia** ( $\text{PaO}_2 < 55$  despite supplemental  $\text{O}_2$ ), progressive **acidosis** ( $\text{pH} < 7.3$  and  $\text{PCO}_2 > 50$ ),  $\text{RR} > 35$

### **What is the treatment of postoperative wheezing?**

Albuterol nebulizer

### **Why may it be dangerous to give a patient with chronic COPD supplemental oxygen?**

This patient uses relative hypoxia for respiratory drive, and supplemental  $\text{O}_2$  may remove this drive!

## **PULMONARY EMBOLISM**

### **What is a pulmonary embolism (PE)?**

DVT that embolizes to the pulmonary arterial system

### **What is DVT?**

**Deep Venous Thrombosis**—a clot forming in the pelvic or lower extremity veins

### **What are the signs/symptoms of DVT?**

Lower extremity pain, swelling, tenderness, Homan's sign, PE  
Up to 50% can be asymptomatic!

### **What is Homan's sign?**

Calf pain with dorsiflexion of the foot classically seen with DVT, but actually found in fewer than one third of patients with DVT

### **What test is used to evaluate for DVT?**

Duplex ultrasonography

### **What is Virchow's triad?**

. Stasis

- . Endothelial injury
- . Hypercoagulable state (risk factors for thrombosis)

### **What are the signs/symptoms of PE?**

Shortness of breath, tachypnea, hypotension, CP, occasional fever, loud pulmonic component of S2, hemoptysis with pulmonary infarction

### **What are the associated lab findings?**

ABG—decreased  $PO_2$  and  $PCO_2$  (from hyperventilation)

### **What diagnostic test is indicated?**

CT angiogram

### **What are the associated CXR findings?**

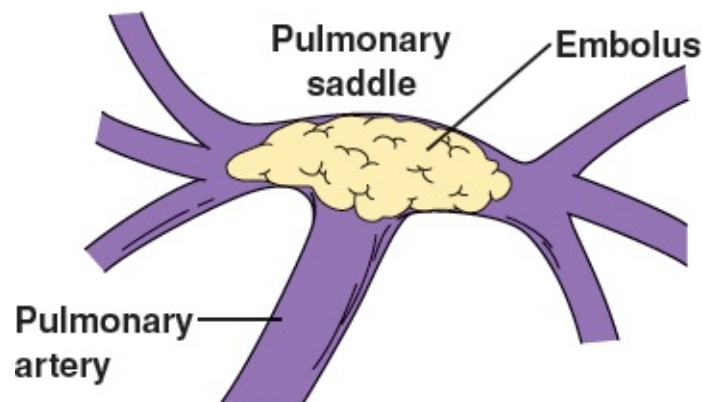
- . Westermark's sign (wedge-shaped area of decreased pulmonary vasculature resulting in hyperlucency)
- . Opacity with base at pleural edge from pulmonary infarction

### **What are the associated EKG findings?**

>50% are abnormal; classic finding is cor pulmonale (S1Q3T3 RBBB and right-axis deviation); EKG most commonly shows flipped T waves or ST depression

### **What is a “saddle” embolus?**

PE that “straddles” the pulmonary artery and is in the lumen of both the right and left pulmonary arteries



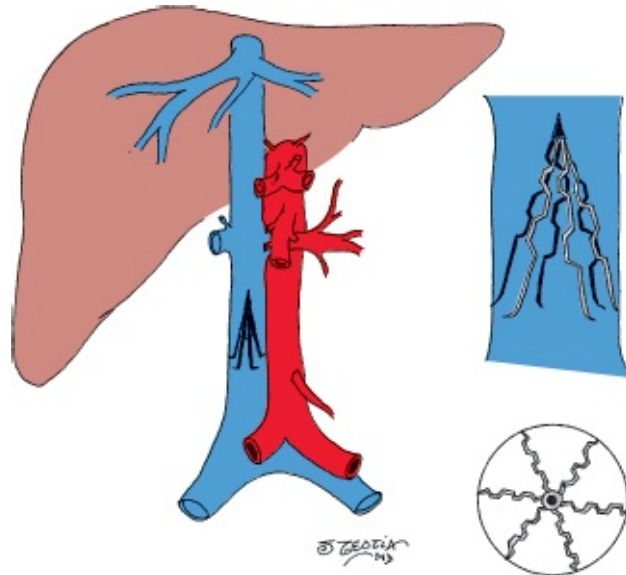
### **What is the treatment if the patient is stable?**

Anticoagulation (heparin followed by long-term [3 to 6 months] Coumadin®) or

Greenfield filter

### **What is an IVC filter?**

Metallic filter placed into IVC via jugular vein to catch emboli prior to lodging in the pulmonary artery



### **Where did Dr. Greenfield get the idea for the IVC filter?**

Oil pipeline filters!

### **When is an IVC filter indicated?**

If anticoagulation is contraindicated or patient has further PE on adequate anticoagulation or is high risk (e.g., pelvic and femur fractures)

### **What is the treatment if the patient's condition is unstable?**

Consider thrombolytic therapy; consult thoracic surgeon for possible Trendelenburg operation; consider catheter suction embolectomy

### **What is the Trendelenburg operation?**

Pulmonary artery embolectomy

### **What is a “retrievable” IVC filter?**

IVC filter that can be removed (“retrieved”)

### **What prophylactic measures can be taken for DVT/PE?**

LMWH (Lovenox®) 40 mg SQ QD; **or** 30 mg SQ b.i.d.; subQ heparin (5000

units subQ every 8 hrs; and SCD boots

## ASPIRATION PNEUMONIA

### **What is it?**

Pneumonia following aspiration of vomitus

### **What are the signs/symptoms?**

Respiratory failure, CP, increased sputum production, fever, cough, mental status changes, tachycardia, cyanosis, infiltrate on CXR

### **What is the treatment?**

Bronchoscopy, antibiotics if pneumonia develops, intubation if respiratory failure occurs, ventilation with PEEP if ARDS develops

### **What is Mendelson's syndrome?**

Chemical pneumonitis secondary to aspiration of stomach contents (i.e., gastric acid)

### **Are prophylactic antibiotics indicated for aspiration pneumonitis?**

NO

## GASTROINTESTINAL COMPLICATIONS

### **Gastric Dilatation**

#### **What are the risk factors?**

Abdominal surgery, gastric outlet obstruction, splenectomy, narcotics

#### **What are the signs/symptoms?**

Abdominal distension, hiccups, electrolyte abnormalities, nausea

#### **What is the treatment?**

NGT decompression

### **What do you do if you have a patient with high NGT output?**

Check high abdominal x-ray and, if the NGT is in duodenum, pull back the NGT into the stomach

## **■ Postoperative Pancreatitis**

### **What is it?**

Pancreatitis resulting from manipulation of the pancreas during surgery or low blood flow during the procedure (i.e., cardiopulmonary bypass), gallstones, hypercalcemia, medications, idiopathic

### **What lab tests are performed?**

Amylase and lipase

### **What is the initial treatment?**

Same as that for the other causes of pancreatitis (e.g., NPO, aggressive fluid resuscitation,  $\pm$  NGT PRN)

## **■ Constipation**

### **What are the postoperative causes?**

Narcotics, immobility

### **What is the treatment?**

OBR

### **What is OBR?**

Ortho **B**owel **R**outine: docusate sodium (daily), dicacodyl suppository if no bowel movement occurs, Fleet® enema if suppository is ineffective

## **■ Short Bowel Syndrome**

### **What is it?**

Malabsorption and diarrhea resulting from extensive bowel resection (<200 cm of small bowel remaining)

**What is the initial treatment?**

TPN early, followed by many small meals chronically

## ■ Blind Loop Syndrome

**What is it?**

Bacterial overgrowth in the small intestine

**What are the causes?**

Anything that disrupts the normal flow of intestinal contents (i.e., causes stasis)

**What are the surgical causes of B12 deficiency?**

Blind loop syndrome, gastrectomy (decreased secretion of intrinsic factor) and excision of the terminal ileum (site of B12 absorption)

## ■ Postvagotomy Diarrhea

**What is it?**

Diarrhea after a truncal vagotomy

**What is the cause?**

It is thought that after truncal vagotomy, a rapid transport of bile salts to the colon results in osmotic inhibition of water absorption in the colon, leading to diarrhea

## ■ Dumping Syndrome

**What is it?**

Delivery of **hyperosmotic** chyme to the small intestine causing massive fluid shifts into the bowel (normally the stomach will decrease the osmolality of the

chyme prior to its emptying)

**With what conditions is it associated?**

Any procedure that bypasses the pylorus or compromises its function (i.e., gastroenterostomies or pyloroplasty); thus, “dumping” of chyme into small intestine

**What are the signs/symptoms?**

Postprandial diaphoresis, tachycardia, abdominal pain/distention, emesis, increased flatus, dizziness, weakness

**What is the medical treatment?**

Small, multiple, low-fat/carbohydrate meals that are high in protein content

**What is the surgical treatment?**

Conversion to Roux-en-Y ( $\pm$  reversed jejunal interposition loop)

## ENDOCRINE COMPLICATIONS

### ■ Diabetic Ketoacidosis (DKA)

**What is it?**

Deficiency of body insulin, resulting in hyperglycemia, formation of ketoacids, osmotic diuresis, and metabolic acidosis

**What are the signs of DKA?**

Polyuria, tachypnea, dehydration, confusion, abdominal pain

**What is the treatment?**

Insulin drip, IVF rehydration,  $K^+$  supplementation,  $\pm$  bicarbonate IV

**What electrolyte must be monitored closely in DKA?**

Potassium and HYPOkalemia (Remember correction of acidosis and GLC/insulin drive  $K^+$  into cells and are treatment for HYPERkalemia!)

**What must you rule out in a diabetic with DKA?**

Infection (perirectal abscess is classically missed!)

## ■ Addisonian Crisis

### What is it?

Acute adrenal insufficiency in the face of a stressor (i.e., surgery, trauma, infection)

### How can you remember what it is?

Think: **ADD**isonian = **AD**renal **D**own

### What is the cause?

Postoperatively, inadequate cortisol release usually results from steroid administration in the past year

### What are the signs/symptoms?

Tachycardia, nausea, vomiting, diarrhea, **abdominal pain**,  $\pm$  fever, progressive lethargy, **hypotension**, **eventual hypovolemic shock**

### What is its clinical claim to infamy?

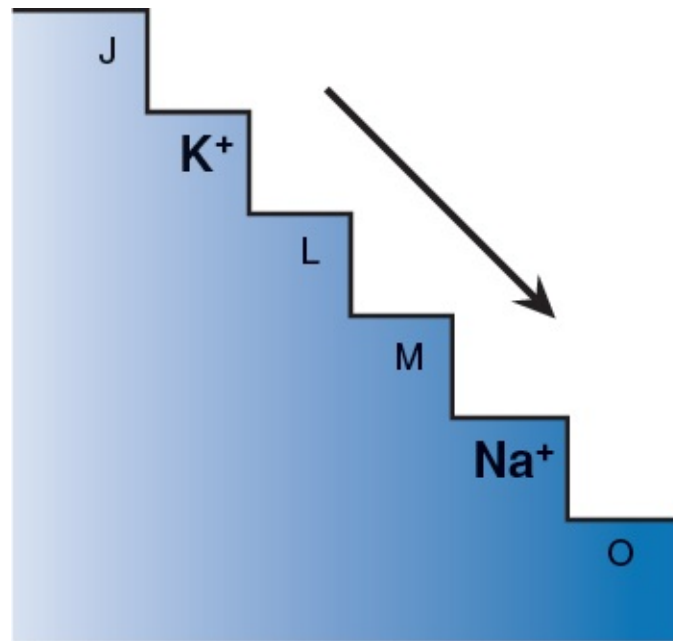
Tachycardia and hypotension refractory to IVF and pressors!

### Which lab values are classic?

Decreased  $\text{Na}^+$ , increased  $\text{K}^+$  (secondary to decreased aldosterone)

### How can the electrolytes with ADDisonian = ADrenal Down be remembered?

Think: **D**OWN the alphabetical electrolyte stairs



### What is the treatment?

IVFs (D5 NS), hydrocortisone IV, fludrocortisone PO

### What is fludrocortisone?

Mineralocorticoid replacement (aldosterone)

## ■ SIADH

### What is it?

Syndrome of **In**appropriate **Anti**Diuretic **H**ormone (ADH) secretion (think of **inappropriate increase** in ADH secretion)

### What does ADH do?

ADH increases NaCl and H<sub>2</sub>O resorption in the kidney, increasing intravascular volume (released from posterior pituitary)

### What are the causes?

**Mainly lung/CNS:** CNS trauma, oat-cell lung cancer, small cell lung carcinoma, pancreatic cancer, duodenal cancer, pneumonia/lung abscess, increased PEEP, stroke, general anesthesia, idiopathic, postoperative, morphine

**What are the associated lab findings?**

Low sodium, low chloride, low serum osmolality; increased urine osmolality

**How can the serum sodium level in SIADH be remembered?**

Remember, **SIADH** = Sodium Is Always Down Here = hyponatremia

**What is the treatment?**

Treat the primary cause and restrict fluid intake

## ■ Diabetes Insipidus (DI)

**What is it?**

Failure of ADH renal fluid conservation resulting in dilute urine in large amounts (Think: **DI** = **D**ecreased ADH)

**What is the source of ADH?**

POSTERIOR pituitary

**What are the two major types?**

- . Central (neurogenic) DI
- . Nephrogenic DI

**What is the mechanism of the two types?**

- . Central DI = decreased production of ADH
- . Nephrogenic DI = decreased ADH effect on kidney

**What are the classic causes of central DI?**

**BRAIN** injury, tumor, surgery, and infection

**What are the classic causes of nephrogenic DI?**

Amphotericin B, hypercalcemia, and chronic kidney infection

**What lab values are associated with DI?**

**HYPER**natremia, decreased urine sodium, decreased urine osmolality, and increased serum osmolality

### **What is the treatment?**

Fluid replacement; follow  $\text{NA}^+$  levels and urine output; central DI warrants vasopressin; nephrogenic DI may respond to thiazide diuretics

## **CARDIOVASCULAR COMPLICATIONS**

### **■ Myocardial Infarction (MI)**

#### **What is the most dangerous period for a postoperative MI following a previous MI?**

6 months after an MI

#### **What are the risk factors for postoperative MI?**

History of MI, angina, QS on EKG, S3, JVD, CHF, aortic stenosis, advanced age, extensive surgical procedure, MI within 6 months, EKG changes

#### **How do postoperative MIs present?**

Often without chest pain

New-onset **CHF**, new-onset **cardiac dysrhythmia**, hypotension, chest pain, tachypnea, tachycardia, nausea/vomiting, bradycardia, neck pain, arm pain

#### **What EKG findings are associated with cardiac ischemia/MI?**

Flipped T waves, ST elevation, ST depression, dysrhythmias (e.g., new-onset AFib, PVC, V tach)

#### **Which lab tests are indicated?**

Troponin I, cardiac isoenzymes (elevated CK-MB fraction)

#### **How can the treatment of postoperative MI be remembered?**

##### **“BEMOAN”:**

**B**eta-blocker (as tolerated)

**M**orphine

**O**xygen

**A**spirin

**N**itrates

### **When do postoperative MIs occur?**

Two thirds occur on PODs #2 to #5 (often silent and present with **dyspnea** or **dysrhythmia**)

## **■ Postoperative CVA**

### **What is a CVA?**

CerebroVascular Accident (stroke)

### **What are the signs/symptoms?**

Aphasia, motor/sensory deficits usually lateralizing

### **What is the workup?**

Head CT scan; must rule out hemorrhage if anticoagulation is going to be used; carotid Doppler ultrasound study to evaluate for carotid occlusive disease

### **What is the treatment?**

ASA,  $\pm$  heparin if feasible postoperatively; Thrombolytic therapy is not usually postoperative option

### **What is the perioperative prevention?**

Avoid hypotension; continue aspirin therapy preoperatively in high-risk patients if feasible; preoperative carotid Doppler study in high-risk patients

## **MISCELLANEOUS**

## **■ Postoperative Renal Failure**

### **What is it?**

Increase in serum creatinine and decrease in creatinine clearance; usually associated with decreased urine output

### **Define the following terms:**

## **Anuria**

<50 cc urine output in 24 hours

## **Oliguria**

50 to 400 cc of urine output in 24 hours

## **What is the differential diagnosis?**

### **Prerenal**

**Inadequate blood perfusing the kidney:** inadequate fluids, hypotension, cardiac pump failure (CHF)

### **Renal**

**Kidney parenchymal dysfunction:** acute tubular necrosis, nephrotoxic contrast or drugs

### **Postrenal**

**Obstruction to outflow of urine from kidney:** Foley catheter obstruction/stone, ureteral/urethral injury, BPH, bladder dysfunction (e.g., medications, spinal anesthesia)

## **What is the workup?**

Lab tests: electrolytes, BUN, Cr, urine lytes, FENa, urinalysis, renal ultrasound

## **What is FENa?**

Fractional Excretion of  $\text{Na}^+$  (sodium)

## **What is the formula for FENa?**

“YOU NEED PEE” =  $\text{UNP}$

$(\text{U}_{\text{Na}^+} \times \text{P}_{\text{Cr}} / \text{P}_{\text{Na}^+} \times \text{U}_{\text{Cr}}) \times 100$  (U = urine, Cr = creatinine,  $\text{Na}^+$  = sodium, P = plasma)

## **Define the lab results with prerenal versus renal failure:**

### **BUN/Cr ratio**

Prerenal: >20:1

Renal: <20:1

### **Specific gravity**

Prerenal:  $>1.020$  (as the body tries to retain fluid)

Renal:  $<1.020$  (kidney has decreased ability to concentrate urine)

### **FENa**

Prerenal:  $<1\%$

Renal:  $>2\%$

### **Urine $\text{Na}^+$ (sodium)**

Prerenal:  $<20$

Renal:  $>40$

### **Urine osmolality**

Prerenal:  $>450$  mOsm/kg

Renal:  $<300$  mOsm/kg

### **What are the indications for dialysis?**

Fluid overload, refractory hyperkalemia, BUN  $>130$ , acidosis, uremic complication (encephalopathy, pericardial effusion)

### **What acronym helps you remember the indications for dialysis?**

**“AEIOU”:**

Acidosis

Electrolytes

Intoxication

Volume **O**verload

Uremic complication

## **DIC**

### **What is it?**

Activation of the coagulation cascade leading to **thrombosis** and **consumption** of clotting factors and platelets and activation of fibrinolytic system (fibrinolysis), resulting in **bleeding**

### **What is the treatment?**

**Removal of the cause;** otherwise supportive: IVFs, O<sub>2</sub>, platelets, FFP, cryoprecipitate (fibrin), epsilon-aminocaproic acid, as needed in predominantly thrombotic cases

Use of heparin is indicated in cases that are predominantly thrombotic with antithrombin III supplementation as needed

## ■ Abdominal Compartment Syndrome

### **What is it?**

Increased intra-abdominal pressure usually seen after laparotomy or after massive IVF resuscitation (e.g., burn patients)

### **What are the signs/symptoms?**

Tight distended abdomen, decreased urine output, increased airway pressure, **increased intra-abdominal pressure**

### **How to measure intra-abdominal pressure?**

Read intrabladder pressure (Foley catheter hooked up to manometry after instillation of 50 to 100 cc of water)

### **What is normal intra-abdominal pressure?**

<15 mm Hg

### **What intra-abdominal pressure indicates need for treatment?**

≥25 mm Hg, especially if there are signs of compromise

### **What is the treatment?**

Release the pressure by decompressive laparotomy (leaving fascia open)

## ■ Urinary Retention

### **What is it?**

Enlarged urinary bladder resulting from medications or spinal anesthesia

**How is it diagnosed?**

Physical exam (palpable bladder), bladder residual volume upon placement of a Foley catheter

**What is the treatment?**

Foley catheter

**With massive bladder distention, how much urine can be drained immediately?**

Most would clamp after 1 L and then drain the rest over time to avoid a vasovagal reaction

**What is the classic sign of urinary retention in an elderly patient?**

Confusion

## Pseudomembranous Colitis

**What are the signs/symptoms?**

**Diarrhea**, fever, hypotension/tachycardia

**How is it diagnosed?**

*Clostridium difficile* toxin in stool, fecal WBC, flex sig (mucous pseudomembrane visible in the lumen of the colon = hence the name)

**What is the treatment?**

- . Flagyl® (PO or IV)
- . PO vancomycin if refractory to Flagyl®

**What is the indication for emergent colectomy?**

Toxic megacolon

## RAPID FIRE REVIEW

**What is the correct diagnosis?**

**During placement of a central line, a 42-year-old woman with breast cancer becomes acutely short of breath. Her breath sounds are decreased on the ipsilateral side of the line placement**

Pneumothorax

**56-year-old woman s/p gastrojejunostomy for duodenal trauma (pyloric exclusion) now presents 1 year post op with tachycardia, dizziness, and abdominal pain after eating**

Dumping syndrome

**28-year-old woman s/p spinal anesthesia for a tubal ligation develops back pain, fever, and increased WBCs on POD #3**

Epidural abscess

**65-year-old smoker with severe COPD treated intermittently with antibiotics, prednisone, and albuterol undergoes a colectomy. Postoperatively the patient develops hypotension, dizziness, and fever with normal hematocrit and abdominal exam**

Adrenal crisis—adrenal insufficiency

**59-year-old female smoker POD #4 from AAA repair develops hypotension and tachycardia with multiple PVCs**

Myocardial infarction

**56-year-old alcoholic woman receives D5 1/2 NS IV bolus in the ER; she develops confusion, ataxia, and inability of gaze laterally**

Wernicke's encephalopathy

# Chapter 22 Common Causes of Ward Emergencies

## **What can cause hypotension?**

Hypovolemia (iatrogenic, hemorrhage), sepsis, MI, cardiac dysrhythmia, hypoxia, false reading (e.g., wrong cuff/arterial line twist or clot), pneumothorax, PE, cardiac tamponade, medications (e.g., morphine)

## **How do you act?**

ABCs, examine, recheck BP, IV access, IV bolus, labs (e.g., HCT), EKG, pulse ox/vital signs monitoring, CXR, supplemental oxygen, check medications/history, give IV antibiotics “stat” if sepsis likely, compress all bleeding sites

## **What are the common causes of postoperative hypertension?**

**Pain** (from catecholamine release), anxiety, hypercapnia, hypoxia (which may also cause hypotension), preexisting condition, bladder distention

## **What can cause hypoxia/shortness of breath?**

Atelectasis, pneumonia, mucous plug, pneumothorax, **PE**, MI/dysrhythmia, venous blood in ABG syringe, sat% machine malfunction/probe malposition, iatrogenic (wrong ventilator settings), severe anemia/hypovolemia, low cardiac output, CHF, ARDS, fluid overload

## **How do you act?**

ABCs, physical exam, vital signs/pulse oximetry monitoring, supplemental oxygen, IV access, ABG, EKG, CXR

## **What can cause mental status change?**

**Hypoxia** until ruled out, hypotension (e.g., cardiogenic shock), hypovolemia, iatrogenic (narcotics/benzodiazepines), drug reaction, alcohol withdrawal, drug withdrawal, seizure, ICU psychosis, CVA, sepsis, metabolic derangements,

intracranial bleeding, **urinary retention in the elderly**

### **What are the signs of alcohol withdrawal?**

**Confusion**, tachycardia/autonomic instability, seizure, hallucinations

### **What are the causes of tachycardia?**

Hypovolemia/third-spacing, pain, alcohol withdrawal, anxiety/agitation, urinary retention, cardiac dysrhythmia (e.g., sinoventricular tachycardia, atrial fibrillation with rapid rate), MI, PE,  $\beta$ -blocker withdrawal, anastomotic leak

### **What are the causes of decreased urine output?**

Hypovolemia, urinary retention, Foley catheter malfunction, cardiac failure, MI, acute tubular necrosis (ATN), ureteral/urethral injury, abdominal compartment syndrome, sepsis

### **How do you act initially in a case of decreased urine output?**

Examine, vital signs, check or place Foley catheter, irrigate Foley catheter, IV fluid bolus

## **RAPID FIRE REVIEW**

### **What is the correct diagnosis?**

**57-year-old man develops confusion and wide swings in heart rate and systolic blood pressure POD #2 after an appendectomy for a perforated appendix; sats = 99%, HCT stable, electrolytes normal, chest x-ray normal**

Alcohol withdrawal

**34-year-old in the ICU s/p laparotomy with fascia closed, decreased urine output, increased peak airway pressure, decreased CVP, normal chest x-ray, normal EKG**

Abdominal compartment syndrome

**A 77-year-old man s/p laparoscopic cholecystomy returns to the clinic with a palpable lower abdominal mass, confusion, and weak**

**urine stream**

Urinary retention

**Name the diagnostic modality:**

**74-year-old female s/p ex lap now POD #4 with acute onset of shortness of breath; ABG reveals hypoxia and hypocapnia**

Chest CTA to rule out pulmonary embolism

# Chapter 23 Surgical Respiratory Care

**What is the most common cause of fever in the first 48 hours postoperatively?**

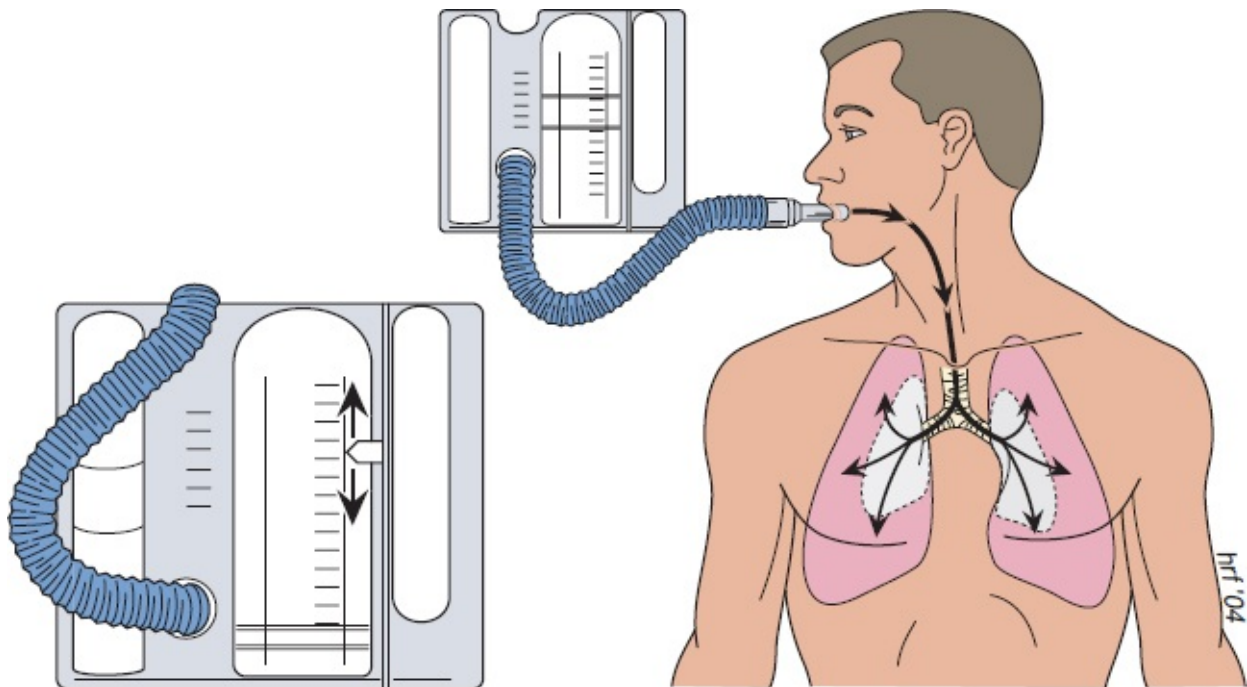
Atelectasis

**What is absorption atelectasis?**

Elevated inhaled oxygen replaces the nitrogen in the alveoli resulting in collapse of the air sac (atelectasis); nitrogen keeps alveoli open by “stenting” them

**What is incentive spirometry?**

Patient can document tidal volume and will have an “incentive” to increase it



**What is oxygen-induced hypoventilation?**

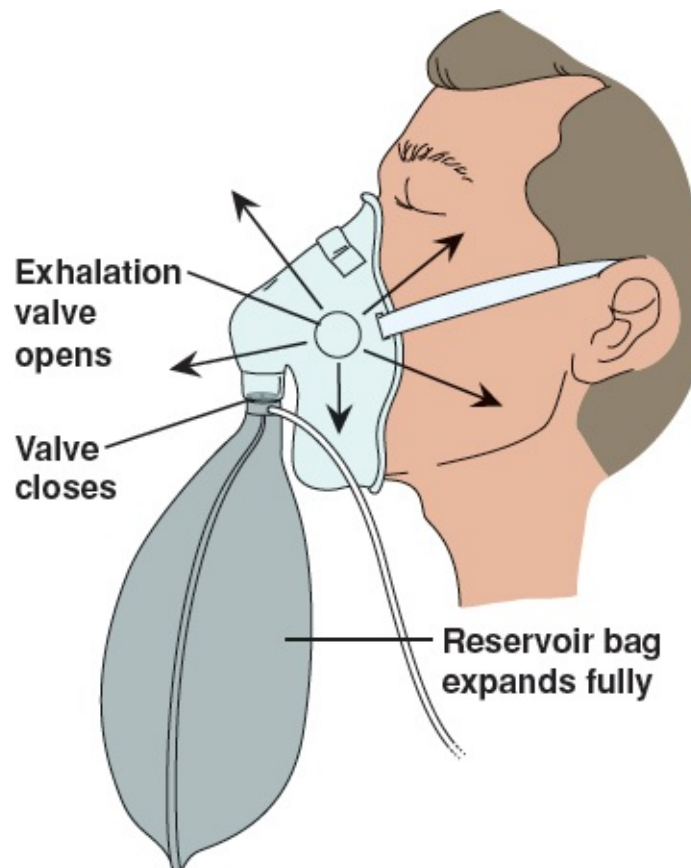
Some patients with COPD have low oxygen as the main stimulus for the respiratory drive; if given supplemental oxygen, they will have a decreased respiratory drive and hypoventilation

### **Why give supplemental oxygen to a patient with a pneumothorax?**

Pneumothorax is almost completely nitrogen—thus increasing the oxygen in the alveoli increases the nitrogen gradient and results in faster absorption of the pneumothorax!

### **What is a nonrebreather mask?**

100% oxygen with a reservoir bag



### **How do you figure out the $\text{PaO}_2$ from an $\text{O}_2$ sat?**

$\text{PaO}_2$  of 40, 50, 60 roughly equals 70, 80, 90 in sats

### **How much do you increase the $\text{FiO}_2$ by each liter added to the nasal cannula?**

≈3%

**RAPID FIRE REVIEW**

**Name the most likely diagnosis:**

**POD #1 after bariatric gastric bypass a 34-year-old woman develops fever and crackles on chest auscultation**

Atelectasis

**18-year-old male with necrotizing fasciitis now with acute onset of respiratory failure,  $\text{PaO}_2$  to  $\text{FiO}_2$  ratio of 145, normal heart echo, bilateral pulmonary edema on CXR**

Moderate ARDS

# Chapter 24 Surgical Nutrition

**What is the motto of surgical nutrition?**

“If the gut works, use it”

**What are the normal daily dietary requirements for adults of the following:**

**Protein?**

1 g/kg/day

**Calories?**

30 kcal/kg/day

**What is the calorie content of the following substances:**

**Fat?**

9 kcal/g

**Protein?**

4 kcal/g

**Carbohydrate?**

4 kcal/g

**What is the formula for converting nitrogen requirement/loss to protein requirement/loss?**

$\text{Nitrogen} \times 6.25 = \text{protein}$

**What is RQ?**

Respiratory Quotient; ratio of CO<sub>2</sub> produced to O<sub>2</sub> consumed

**What is the normal RQ?**

0.8

**What can be done to decrease the RQ?**

More fat, less carbohydrates

**What dietary change can be made to decrease CO<sub>2</sub> production in a patient in whom CO<sub>2</sub> retention is a concern?**

Decrease carbohydrate calories and increase calories from **fat**

**What lab tests are used to monitor nutritional status?**

Blood levels of:

**Prealbumin** ( $t_{1/2} \approx 2$  to 3 days)—acute change determination

Transferrin ( $t_{1/2} \approx 8$  to 9 days)

Albumin ( $t_{1/2} \approx 14$  to 20 days)—more chronic determination

Total lymphocyte count

Anergy

Retinol-binding protein ( $t_{1/2} \approx 12$  hours)

**Where is iron absorbed?**

Duodenum (some in proximal jejunum)

**Where is vitamin B12 absorbed?**

Terminal ileum

**What are the surgical causes of vitamin B12 deficiency?**

Gastrectomy, excision of terminal ileum, blind loop syndrome

**Where are bile salts absorbed?**

Terminal ileum

**Where are fat-soluble vitamins absorbed?**

Terminal ileum

**Which vitamins are fat soluble?**

**K, A, D, E** (“KADE”)

**What are the signs of the following disorders:**

**Vitamin A deficiency**

Poor wound healing

**Vitamin B12/folate deficiency**

Megaloblastic anemia

**Vitamin C deficiency**

Poor wound healing, bleeding gums

**Vitamin K deficiency**

Decrease in vitamin K–dependent clotting factors (II, VII, IX, and X); bleeding; elevated PT

**Chromium deficiency**

Diabetic state

**Zinc deficiency**

Poor wound healing, alopecia, dermatitis, taste disorder

**Fatty acid deficiency**

Dry, flaky skin; alopecia

**What vitamin increases the PO absorption of iron?**

PO vitamin C (ascorbic acid)

**What vitamin lessens the deleterious effects of steroids on wound healing?**

Vitamin A

**What are the common indications for total parenteral nutrition (TPN)?**

NPO >7 days

Enterocutaneous fistulas

Short bowel syndrome

Prolonged ileus

**What is TPN?**

**Total Parenteral Nutrition** = IV nutrition

**What is the major nutrient of the gut (small bowel)?**

Glutamine

**What is “refeeding syndrome”?**

Decreased serum **potassium, magnesium, and phosphate** after refeeding (via TPN or enterally) a starving patient

**What are the vitamin K–dependent clotting factors?**

2, 7, 9, 10 (Think: 2 + 7 = 9, and then 10)

**What is an elemental tube feed?**

Very low residue tube feed in which almost all the tube feed is absorbed

**Where is calcium absorbed?**

Duodenum (actively)

Jejunum (passively)

**What is the major nutrient of the colon?**

**Butyrate** (and other short-chain fatty acids)

**What must bind B12 for absorption?**

Intrinsic factor from the gastric parietal cells

**What sedative medication has caloric value?**

Propofol delivers 1 kcal/cc in the form of lipid!

**Why may all the insulin placed in a TPN bag not get to the patient?**

Insulin will bind to the IV tubing

**How can serum bicarbonate be increased in patients on TPN?**

Increase acetate (which is metabolized into bicarbonate)

**What are “trophic” tube feeds?**

Very low rate of tube feeds (usually 10 to 25 cc/hr), which are thought to keep mucosa alive and healthy

**What is the best lab to check adequacy of nutritional status?**

Prealbumin

# Chapter 25 Shock

## **What is the definition of shock?**

Inadequate tissue perfusion

## **What are the different types (5)?**

- . Hypovolemic
- . Septic
- . Cardiogenic
- . Neurogenic
- . Anaphylactic

## **What are the signs of shock?**

Pale, diaphoretic, cool skin

Hypotension, tachycardia, tachypnea

Decreased mental status and pulse pressure

Poor capillary refill

Poor urine output

## **What are the best indicators of tissue perfusion?**

Urine output, mental status

## **What lab tests help assess tissue perfusion?**

Lactic acid (elevated with inadequate tissue perfusion), base deficit, pH from ABG (acidosis associated with inadequate tissue perfusion)

## **HYPOVOLEMIC SHOCK**

## **What is the definition?**

Decreased intravascular volume

## **What are the common causes?**

Hemorrhage  
Burns  
Bowel obstruction  
Crush injury  
Pancreatitis

### **What are the signs?**

**Early**—Orthostatic hypotension, mild tachycardia, anxiety, diaphoresis, vasoconstriction (decreased pulse pressure with increased diastolic pressure)

**Late**—Changed mental status, decreased BP, marked tachycardia

### **What are the signs/symptoms with:**

#### **Class I hemorrhage (<15% or 750 cc blood loss)?**

Mild anxiety, normal vital signs

#### **Class II hemorrhage (15% to 30% or 750 to 1500 cc blood loss)?**

Normal systolic BP with decreased pulse pressure, tachycardia, tachypnea, anxiety

#### **Class III hemorrhage (30% to 40% or 1500 to 2000 cc blood loss)?**

Tachycardia (heart rate >120), tachypnea (respiratory rate >30), **decreased systolic BP**, decreased pulse pressure, confusion

#### **Class IV hemorrhage (>40% or >2000 cc blood loss)?**

Decreased systolic BP, tachycardia (heart rate >140), tachypnea (respiratory rate >35), decreased pulse pressure, confused and lethargic, no urine output

### **What is the treatment?**

- . Stop the bleeding
- . Volume: IVF (isotonic LR) then blood products as needed

### **How is the effectiveness of treatment evaluated:**

#### **Bedside indicator?**

Urine output, BP, heart rate, mental status, extremity warmth, capillary refill, body temperature

## **Labs?**

pH, base deficit, and lactate level

## **Why does decreased pulse pressure occur with early hypovolemic shock?**

Pulse pressure (systolic–diastolic BP) decreases because of vasoconstriction, resulting in an elevated diastolic BP

## **What is the most common vital sign change associated with early hypovolemic shock?**

Tachycardia

## **What type of patient does not mount a normal tachycardic response to hypovolemic shock?**

Patients on  $\beta$ -blockers, spinal shock (loss of sympathetic tone), endurance athletes

## **Should vasopressors be used to treat hypovolemic shock?**

No

# **SEPTIC SHOCK**

## **What is the definition?**

Documented infection and hypotension

## **What are the signs/symptoms?**

Initial—vasodilation, resulting in warm skin and full pulses; normal urine output  
Delayed—vasoconstriction and poor urine output; mental status changes; hypotension

## **What percentage of blood cultures is positive in patients with bacterial septic shock?**

Only  $\approx 50\%$ !

## **What are the associated findings?**

Fever, hyperventilation, tachycardia

### **What is the treatment?**

- . Volume (IVF)
- . Antibiotics (empiric, then by cultures)
- . Drainage of infection
- . Pressors PRN

## **CARDIOGENIC SHOCK**

### **What is the definition?**

Cardiac insufficiency; left ventricular failure (usually), resulting in inadequate tissue perfusion

### **What are the causes?**

MI, papillary muscle dysfunction, massive cardiac contusion, cardiac tamponade, tension pneumothorax, cardiac valve failure

## **NEUROGENIC SHOCK**

### **What is the definition?**

Inadequate tissue perfusion from loss of sympathetic vasoconstrictive tone

### **What are the common causes?**

Spinal cord injury:

- Complete transection of spinal cord
- Partial cord injury with spinal shock
- Spinal anesthesia

### **What are the signs/symptoms?**

**Hypotension** and **bradycardia**, neurologic deficit

### **Why are heart rate and BP decreased?**

Loss of sympathetic tone (but hypovolemia [e.g., hemoperitoneum] must be ruled out)

### **What are the associated findings?**

Neurologic deficits suggesting cord injury

**What MUST be ruled out in any patient where neurogenic shock is suspected?**

Hemorrhagic shock!

**What is the treatment?**

**IV fluids** (vasopressors reserved for hypotension refractory to fluid resuscitation)

**What is spinal shock?**

Complete flaccid paralysis immediately following spinal cord injury; may or may not be associated with circulatory shock

**What is the lowest reflex available to the examiner?**

Bulbocavernous reflex: checking for contraction of the anal sphincter upon compression of the glans penis or clitoris

**What is the lowest level voluntary muscle?**

External anal sphincter

**What are the classic findings associated with neurogenic shock?**

Hypotension

Bradycardia or lack of compensatory tachycardia

## MISCELLANEOUS

**What is the acronym for treatment options for anaphylactic shock?**

**“BASE”:**

Benadryl

Aminophylline

Steroids

Epinephrine

## RAPID FIRE REVIEW

**What is the treatment?**

**15-year-old s/p trampoline injury with tetraplegia (a.k.a. “quadriplegia”) with hypotension. No other injuries on CT scans**

Neurogenic shock; treat with IV fluids and then vasopressors as needed

# Chapter 26 Surgical Infection

## Define:

### **Bacteremia**

Bacteria in the blood

### **SIRS**

Systemic Inflammatory Response Syndrome (fever, tachycardia, tachypnea, leukocytosis)

### **Define SIRS criteria**

2 or more of the following:

Temperature  $<36^{\circ}\text{C}$  or  $>38^{\circ}\text{C}$

Tachypnea  $>20$  bpm

Heart rate  $>90$  bpm

Leukocytes  $<4\text{k}$  or  $>12\text{k}$

### **Sepsis**

Documented infection and SIRS

### **Septic shock**

Sepsis and hypotension

### **Cellulitis**

**Blanching erythema** from superficial dermal/epidermal infection (usually strep more than staph)

### **Abscess**

Collection of pus within a cavity

### **Superinfection**

New infection arising while a patient is receiving antibiotics for the original

infection at a different site (e.g., *Clostridium difficile* colitis)

### **Nosocomial infection**

Infection originating in the hospital

### **Empiric**

Use of antibiotic based on previous sensitivity information or previous experience awaiting culture results in an established infection

### **Prophylactic**

Antibiotics used to prevent an infection

### **What is the most common nosocomial infection?**

Urinary tract infection (UTI)

### **What is the most common nosocomial infection causing death?**

Respiratory tract infection (pneumonia)

## **URINARY TRACT INFECTION (UTI)**

### **What diagnostic tests are used?**

Urinalysis, culture, urine microscopy for WBC

### **What constitutes a POSITIVE urine analysis?**

Positive nitrite (from bacteria)

Positive leukocyte esterase (from WBC) >10 WBC/HPF

Presence of bacteria (supportive)

### **What number of colony-forming units (CFU) confirms the diagnosis of UTI?**

On urine culture, classically 100,000 or 10<sup>5</sup> CFU

### **What are the common organisms?**

*Escherichia coli*, *Klebsiella*, *Proteus* (*Enterococcus*, *Staphylococcus aureus*)

### **What is the treatment?**

Antibiotics with gram-negative spectrum (e.g., sulfamethoxazole/trimethoprim)

[Bactrim™], gentamicin, ciprofloxacin, aztreonam); use antibiogram then check culture and sensitivity

### **What is the treatment of bladder candidiasis?**

- . Remove or change Foley catheter
- . Administer systemic fluconazole or amphotericin bladder washings

## **CENTRAL LINE INFECTIONS**

### **What are the signs of a central line infection?**

**Unexplained hyperglycemia**, fever, mental status change, hypotension, tachycardia → **shock**, pus, and erythema at central line site

### **What is a central line–associated bloodstream infection (CLABSI)?**

- . Central line in place >2 days
- . +Blood culture
- . No other source of infection

### **What is the most common cause of “catheter-related bloodstream infections”?**

Coagulase-negative *staphylococci* (33%), followed by enterococci, *S. aureus*, gram-negative rods

### **When should central lines be changed?**

When they are infected; there is NO advantage to changing them every 7 days in nonburn patients

### **What central line infusion increases the risk of infection?**

Hyperal (TPN)

### **What is the treatment for central line infection?**

- . Remove central line (send for culture) ± IV antibiotics
- . Place NEW central line in a different site

### **When should peripheral IV short angiocatheters be changed?**

Every 72 to 96 hours

# WOUND INFECTION (SURGICAL SITE INFECTION)

## What is it?

Infection in an operative wound

## When do these infections arise?

Classically, PODs #5 to #7

## What are the signs/symptoms?

**Pain** at incision site, erythema, drainage, induration, warm skin, fever

## What is the treatment?

Remove skin sutures/staples, rule out fascial dehiscence, pack wound open, send wound culture, administer antibiotics

## What are the most common bacteria found in postoperative wound infections?

*S. aureus* (20%)

*E. coli* (10%)

*Enterococcus* (10%)

Other causes: *Staphylococcus epidermidis*, *Pseudomonas*, anaerobes, other gram-negative organisms, *Streptococcus*

## Which bacteria causes fever and wound infection in the first 24 hours after surgery?

- . *Streptococcus*
- . *Clostridium* (bronze-brown weeping tender wound)

## ■ Classification of Operative Wounds

### What is a “clean” wound?

Elective, nontraumatic wound without acute inflammation; usually closed primarily without the use of drains

**What is the infection rate of a clean wound?**

<1.5%

**What is a clean-contaminated wound?**

Operation on the GI or respiratory tract without unusual contamination or entry into the biliary or urinary tract

**Without infection present, what is the infection rate of a clean-contaminated wound?**

<3%

**What is a contaminated wound?**

Acute inflammation, traumatic wound, GI tract spillage, or a major break in sterile technique

**What is the infection rate of a contaminated wound?**

≈5%

**What is a dirty wound?**

Pus present, perforated viscus, or dirty traumatic wound

**What is the infection rate of a dirty wound?**

≈33%

**What factors influence the development of infections?**

Foreign body (e.g., suture, drains, grafts)

Decreased blood flow (poor delivery of PMNs and antibiotics)

Strangulation of tissues with excessively tight sutures

Necrotic tissue or excessive local tissue destruction (e.g., too much Bovie)

Long operations (>2 hrs)

Hypothermia in O.R.

Hematomas or seromas

Dead space that prevents the delivery of phagocytic cells to bacterial foci

Poor approximation of tissues

**What is the treatment?**

Incision and drainage—an abscess must be drained (**Note:** fluctuation is a sign of a *subcutaneous* abscess; most abdominal abscesses are drained percutaneously)

Antibiotics for deep abscesses

**What are the indications for antibiotics after drainage of a subcutaneous abscess?**

Diabetes mellitus, surrounding cellulitis, prosthetic heart valve, or an immunocompromised state

## ■ Peritoneal Abscess

**What is a peritoneal abscess?**

Abscess within the peritoneal cavity

**What are the causes?**

Postoperative status after a laparotomy, ruptured appendix, peritonitis, any inflammatory intraperitoneal process, anastomotic leak

**What are the signs/symptoms?**

Fever (classically spiking), abdominal pain, mass

**How is the diagnosis made?**

Abdominal CT scan (or ultrasound)

**When should an abdominal CT scan be obtained looking for a postoperative abscess?**

After POD #7 (otherwise, abscess will not be “organized” and will look like a normal postoperative fluid collection)

**What CT scan findings are associated with abscess?**

Fluid collection with fibrous rind, **gas** in fluid collection

**What is the treatment?**

Percutaneous CT-guided drainage

**What is an option for drainage of pelvic abscess?**

Transrectal drainage (or transvaginal)

**All abscesses must be drained except which type?**

Amebiasis!

## NECROTIZING FASCIITIS

**What is it?**

Bacterial infection of underlying fascia (spreads rapidly along fascial planes)

**What are the causative agents?**

Classically, group A *Streptococcus pyogenes*, but most often polymicrobial with anaerobes/gram-negative organisms

**What are the signs/symptoms?**

Fever, pain, crepitus, cellulitis, skin discoloration, blood blisters (hemorrhagic bullae), weeping skin, increased WBCs, subcutaneous air on x-ray, septic shock

**What is the LRINEC score for necrotizing fasciitis?**

Laboratory Risk Indicator for NECrotizing fasciitis

**What are the values for the LRINEC associated with necrotizing fasciitis?**

C-reactive protein >150, WBC >15, HGB <13.5, sodium <135, creatinine >1.6, glucose >180

**What is the treatment?**

IVF, IV antibiotics and aggressive early extensive surgical débridement, cultures, tetanus prophylaxis

**What antibiotics?**

Triple therapy: for example, Zosyn®, vancomycin, clindamycin

**Why clindamycin?**

Binds STAPH/STREP exotoxin

**Is necrotizing fasciitis an emergency?**

YES, patients must be taken to the O.R. immediately!

## CLOSTRIDIAL MYOSITIS

### **What is it?**

Clostridial muscle infection

### **What is another name for this condition?**

Gas gangrene

### **What is the most common causative organism?**

*Clostridium perfringens*

### **What are the signs/symptoms?**

Pain, fever, shock, crepitus, foul-smelling brown fluid, subcutaneous air on x-ray

### **What is the treatment?**

IV antibiotics, aggressive surgical débridement of involved muscle, tetanus prophylaxis

## HIDRADENITIS SUPPURATIVA

### **What is it?**

Infection/abscess formation in **apocrine** sweat glands

### **In what three locations does it occur?**

Perineum/buttocks, inguinal area, axillae (site of apocrine glands)

### **What is the most common causative organism?**

*S. aureus*

### **What is the treatment?**

Antibiotics

Incision and drainage (excision of skin with glands for chronic infections)

## PSEUDOMEMBRANOUS COLITIS

**What is it?**

Antibiotic-induced colonic overgrowth of *C. difficile*

**What are the signs/symptoms?**

**Diarrhea** (bloody in 10% of patients),  $\pm$  fever,  $\pm$  increased WBCs,  $\pm$  abdominal cramps,  $\pm$  abdominal distention

**What causes the diarrhea?**

Exotoxin released by *C. difficile*

**How is the diagnosis made?**

Assay stool for **exotoxin titer**

**What is the treatment?**

PO metronidazole (Flagyl®; 93% sensitive) or PO vancomycin (97% sensitive); discontinuation of causative agent

**Never** give antiperistaltics

## PROPHYLACTIC ANTIBIOTICS

**What must a prophylactic antibiotic cover for procedures on the large bowel/abdominal trauma/appendicitis?**

Anaerobes (and gram-negatives)

**When is the appropriate time to administer prophylactic antibiotics?**

Must be in adequate levels in the blood stream **prior to surgical incision!**

## PAROTITIS

**What is it?**

Infection of the parotid gland

**What is the most common causative organism?**

*Staphylococcus*

**What are the signs?**

Hot, red, tender parotid gland and increased WBCs

### **What is the treatment?**

Antibiotics, operative drainage as necessary

## **MISCELLANEOUS**

### **What is a “stitch” abscess?**

Subcutaneous abscess centered around a subcutaneous stitch, which is a “foreign body”; treat with drainage and stitch removal

### **Which bacteria can be found in the stool (colon)?**

Anaerobic—*Bacteroides fragilis*

Aerobic—*E. coli*

### **Which bacteria are found in infections from human bites?**

*Streptococcus viridans*, *S. aureus*, *Peptococcus*, *Eikenella* (treat with Augmentin®)

### **What are the most common ICU pneumonia bacteria?**

Gram-negative organisms

### **What is Fournier’s gangrene?**

Perineal infection starting classically in the scrotum in patients with diabetes; treat with triple antibiotics and wide débridement—a surgical emergency!

### **Does adding antibiotics to peritoneal lavage solution lower the risk of abscess formation?**

No (“Dilution is the solution to pollution”)

### **Which antibiotic is used to treat amoeba infection?**

Metronidazole (Flagyl®)

### **Which bacteria commonly infects prosthetic material and central lines?**

*S. epidermis*

**What is the antibiotic of choice for *Actinomyces*?**

Penicillin G (exquisitely sensitive)

**What is a furuncle?**

Staphylococcal abscess that forms in a hair follicle (Think: Follicle = Furuncle)

**What is a carbuncle?**

Subcutaneous staphylococcal abscess (usually an extension of a furuncle), most commonly seen in patients with diabetes (i.e., rule out diabetes)

**What is a felon?**

Infection of the finger pad (Think: Felon = Finger printing)

**What microscopic finding is associated with *Actinomyces*?**

Sulfur granules

**What organism causes tetanus?**

*Clostridium tetani*

**What are the signs of tetanus?**

Lockjaw, muscle spasm, laryngospasm, convulsions, respiratory failure

**What are the appropriate prophylactic steps in tetanus-prone (dirty) injury in the following patients:****Three previous immunizations?**

None (tetanus toxoid only if >5 years since last toxoid)

**Two previous immunizations?**

Tetanus toxoid

**One previous immunization?**

Tetanus immunoglobulin IM and tetanus toxoid IM (at different sites!)

**No previous immunizations?**

Tetanus immunoglobulin IM and tetanus toxoid IM (at different sites!)

**What is Fitz-Hugh–Curtis syndrome?**

RUQ pain from gonococcal perihepatitis in women

## RAPID FIRE REVIEW

**Name the most likely diagnosis:**

**Midline laparotomy wound that drains continuous straw-colored fluid**

Fascial dehiscence

**POD #1 with bright red wound infection**

Streptococcus infection

**POD #1 with painful wound and weeping bronze-colored fluid**

Clostridial wound infection

**67-year-old male POD #5 s/p AAA repair with bloody diarrhea**

Ischemic colitis

**80-year-old man s/p appendectomy with fever, right-sided face pain, and elevated WBCs**

Parotitis

# Chapter 27 Fever

## **Define postoperative fever**

Temperature  $>38.5^{\circ}\text{C}$  or  $101.5^{\circ}\text{F}$

## **What are the five classic W's of postoperative fever?**

- . **W**ind—atelectasis
- . **W**ater—urinary tract infection (UTI)
- . **W**ound—wound infection
- . **W**alking—DVT/thrombophlebitis
- . **W**onder drugs—drug fever

## **Give the classic postoperative timing for the following causes of postoperative fever:**

### **Atelectasis (Wind)**

First 24 to 48 hours

### **UTI (Water)**

Anytime after POD #3

### **Wound infection (Wound)**

Usually after POD #5 (but it can be anytime!)

### **DVT/PE/thrombophlebitis (Walking)**

PODs #7 to #10

### **Drug fever (Wonder drugs)**

Anytime

## **What is the most common cause of fever on PODs #1 to #2?**

Atelectasis (most likely cytokine release from tissue damage!)

**What is a “fever” workup?**

Physical exam (look at wound), CXR, urinalysis, blood cultures, CBC

**What causes fever before 24 postoperative hours?**

Atelectasis, cytokine release,  $\beta$ -hemolytic streptococcal or clostridial wound infections, anastomotic leak

**What causes fever from PODs #3 to #5?**

UTI, pneumonia, IV site infection, wound infection

**What is an anesthetic cause of fever INTRAoperatively?**

Malignant hyperthermia—treat with **dantrolene**

**What causes fever from PODs #5 to #10?**

Wound infection, pneumonia, abscess, infected hematoma, *Clostridium difficile* colitis, anastomotic leak

**DVT, peritoneal abscess, drug fever**

PE, abscess, parotitis

**What causes wound infection on PODs #1 to #2?**

*Streptococcus*

*Clostridia* (painful bronze-brown weeping wound)

**What can cause fever at any time?**

- . IV site infection
- . Central line infection
- . Medications

## RAPID FIRE REVIEW

**What is the correct diagnosis?**

**38-year-old female diabetic with cellulitis on broad-spectrum antibiotics for 2 weeks develops fever, massive diarrhea, and abdominal pain**

*C. difficile* colitis

**27-year-old woman who following menses develops rash, hypotension, and fever**

Toxic shock syndrome

## Chapter 28 Surgical Prophylaxis

**What medications provide protection from postoperative GI bleeding?**

H<sub>2</sub> blockers, PPI (proton-pump inhibitor)

**What measures provide protection from postoperative atelectasis/pneumonia?**

Incentive spirometry, coughing, **smoking cessation**, ambulation

**What treatments provide protection from postoperative DVT?**

Low-molecular-weight heparin (LMWH), subcutaneous low-dose unfractionated heparin, sequential compression device (SCD) for lower extremities, early ambulation

**What measures provide protection from wound infection?**

Shower the night before surgery with chlorhexidine scrub

**Never use a razor** for hair removal (electric shavers only)

Ensure adequate skin prep in O.R.

Do not close the skin in a contaminated case

Ensure preoperative antibiotics in the bloodstream **before incision**

**Why not use a razor to remove hair?**

Micro cuts are a nidus for bacteria and subsequent wound infection

**How long should “prophylactic antibiotics” be given?**

<24 hours

**What measures prevent ventilator-associated pneumonia (VAP)?**

Head of bed >30 degree, handwashing, patient oral hygiene, avoidance of gastric overdistention

**What treatment provides protection from Wernicke's**

## **encephalopathy?**

**Rally pack** (a.k.a. “banana bag” because the fluid is yellow with the vitamins in it); pack includes thiamine, folate, and magnesium

## **To avoid Wernicke’s encephalopathy in alcoholics, when do you give the glucose?**

AFTER thiamine administration!

## **What is Wernicke’s encephalopathy?**

Condition resulting from thiamine deficiency in patients with alcoholism, causing a **triad** of symptoms; think “**COA**”:

1. **C**onfusion
2. **O**phthalmoplegia
3. **A**taxia

## **What treatment decreases the risk of perioperative adrenal crisis in a patient on chronic steroids?**

“Stress-dose” steroids: 100 mg hydrocortisone administered preoperatively, continued postoperatively q8 hours, and then tapered off

# Chapter 29 Surgical Radiology

## CHEST

### **Which CXR is better: P-A or A-P?**

P-A, less magnification of the heart (heart is closer to the x-ray plate)

### **Classically, how much pleural fluid can the diaphragm hide on upright CXR?**

It is said that the diaphragm can overshadow up to 500 cc

### **How can CXR confirm that the last hole on a chest tube is in the pleural cavity?**

Last hole is through the radiopaque line on the chest tube; thus, look for the break in the radiopaque line to be within the rib cage/pleura

### **How can a loculated pleural effusion be distinguished from a free-flowing pleural effusion?**

Ipsilateral decubitus CXR; if fluid is not loculated (or contained), it will layer out

### **How do you recognize a pneumothorax on CXR?**

Air without lung markings is seen outside the white pleural line—best seen in the apices on an upright CXR

### **What x-ray should be obtained before feeding via a nasogastric or nasoduodenal tube?**

Low CXR to ensure the tube is in the GI tract and not in the lung

### **What C-spine views are used to rule out bony injury?**

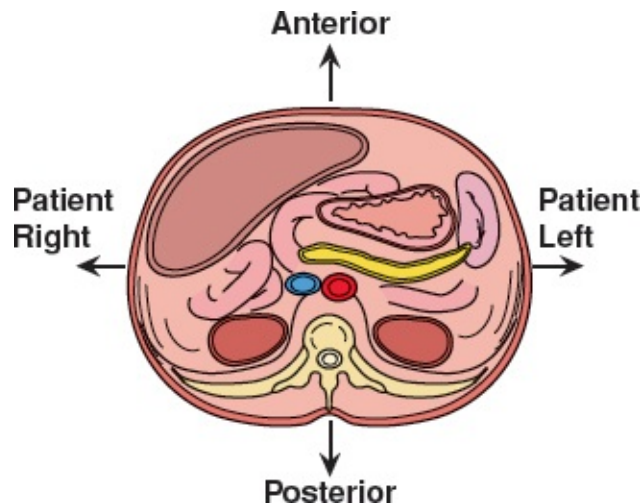
CT scan

## What is used to look for ligamentous C-spine injury?

Lateral flex and extension C-spine films, MRI

## How should a CT scan be read?

Cross section with the patient in supine position looking up from the feet



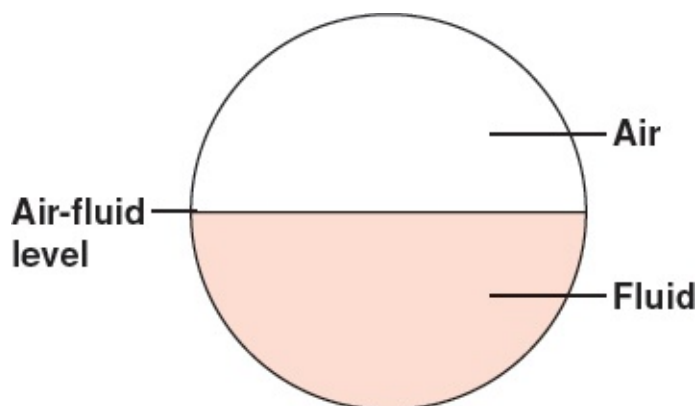
## ABDOMEN

### How can you tell the difference between a small bowel obstruction (SBO) and an ileus?

In SBO, there is a transition point (cut-off sign) between the distended proximal bowel and the distal bowel of normal caliber (may be gasless), whereas the bowel in ileus is *diffusely* distended

### What is the significance of an air-fluid level?

Seen in obstruction or ileus on an upright x-ray; intraluminal bowel diameter increases, allowing for separation of fluid and gas



**What are the normal calibers of the small bowel, transverse colon, and cecum?**

Use the “3, 6, 9 rule”:

Small bowel <3 cm

Transverse colon <6 cm

Cecum <9 cm

**What percentage of kidney stones are radiopaque?**

≈90%

**What percentage of gallstones are radiopaque?**

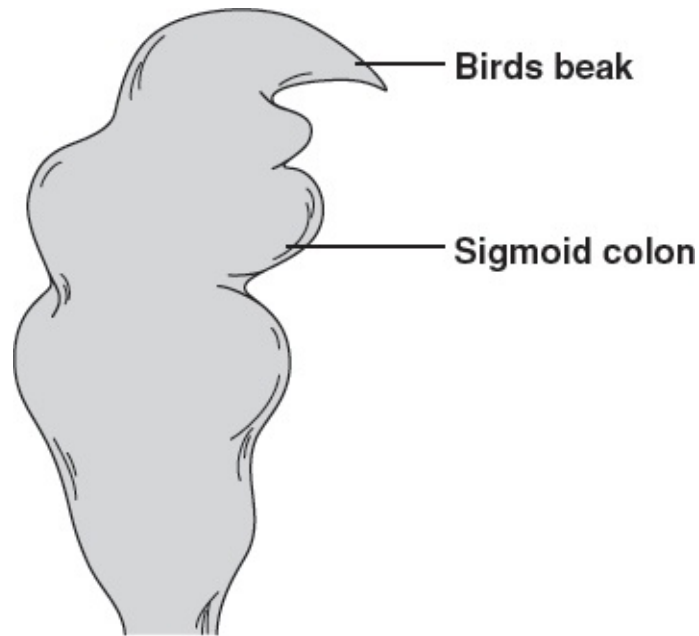
≈10%

**What percentage of patients with acute appendicitis have a radiopaque fecalith?**

≈5%

**What is the “parrot’s beak” or “bird’s beak” sign?**

Evidence of sigmoid volvulus on barium enema; evidence of achalasia on barium swallow



### **What is a “cut-off sign”?**

Seen in obstruction, bowel distention, and distended bowel that is “cut-off” from normal bowel

### **What are “sentinel loops”?**

Distention or air-fluid levels (or both) near a site of abdominal inflammation (e.g., seen in RLQ with appendicitis)

### **What is loss of the psoas shadow?**

Loss of the clearly defined borders of the psoas muscle on AXR; loss signifies inflammation or ascites

### **What is loss of the peritoneal fat stripe (a.k.a. “preperitoneal fat stripe”)?**

Loss of the lateral peritoneal/preperitoneal fat interface; implies inflammation

### **What is “thumbprinting”?**

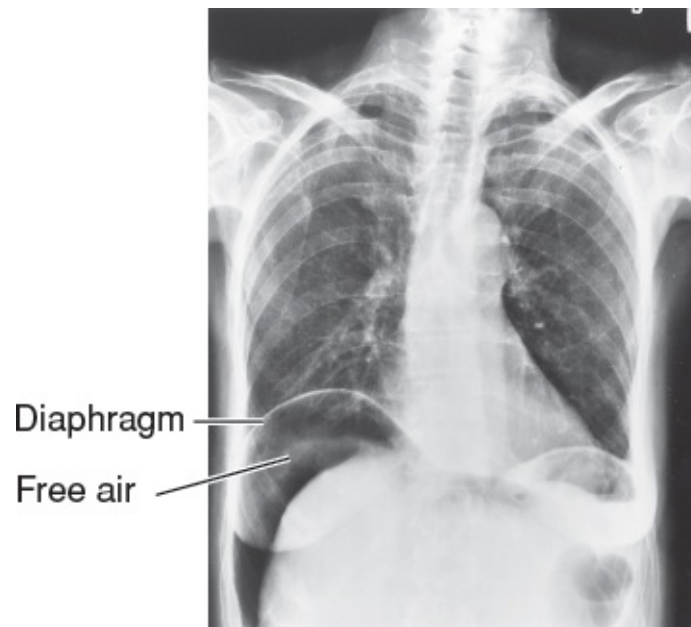
Nonspecific colonic mucosal edema resembling thumb indentations on AXR

### **What is pneumatosis intestinalis?**

Gas within the intestinal wall (usually means **dead gut**) that can be seen in patients with congenital variant or chronic steroids

### **What is free air?**

Air free within the peritoneal cavity (air or gas should be seen only within the bowel or stomach); results from bowel or stomach perforation



### **What is the best position for the detection of FREE AIR (free intraperitoneal air)?**

**Upright CXR**—air below the right diaphragm

### **If you cannot get an upright CXR, what is the second best plain x-ray for free air?**

Left lateral decubitus, because it prevents confusion with gastric air bubble; with free air **both** sides of the bowel wall can be seen; can detect as little as 1 cc of air

### **How long after a laparotomy can there be free air on AXR?**

Usually  $\leq 7$  days

### **What is Chilaiditi's sign?**

Transverse colon over the liver simulating free air on x-ray

### **When should a postoperative abdominal/pelvic CT scan for a peritoneal abscess be performed?**

POD #7 or later, to give time for the abscess to form

### **What is the best test to evaluate the biliary system and gallbladder?**

Ultrasound (U/S)

**What is the normal diameter of the common bile duct with gallbladder present?**

<4 mm until age 40, then add 1 mm per decade (e.g., 7 mm at age 70)

**What is the normal common bile duct diameter after removal of the gallbladder?**

8 to 10 mm

**What U/S findings are associated with acute cholecystitis?**

Gallstones, thickened gallbladder wall (>3 mm), distended gallbladder (>4 cm A-P), impacted stone in gallbladder neck, pericholecystic fluid

**What type of kidney stone is not seen on AXR?**

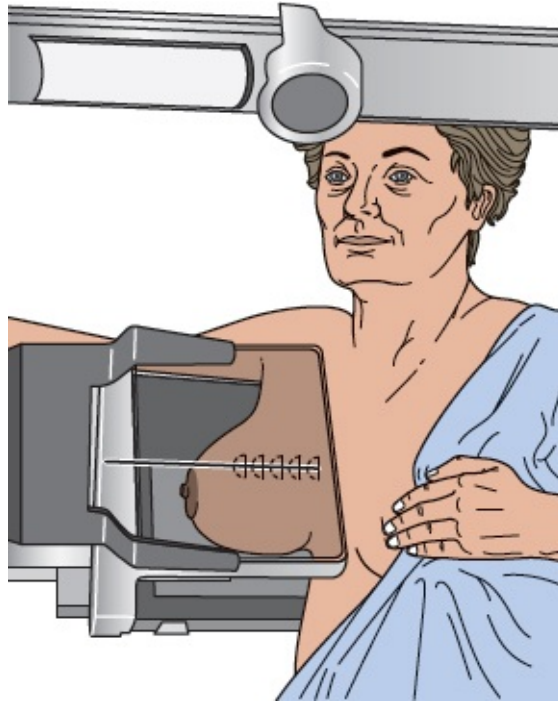
Uric acid (Think: Uric acid = Unseen)

**What is a C-C mammogram?**

Cranio-Caudal mammogram, in which the breast is compressed top to bottom

**What is an MLO mammogram?**

MedioLateral Oblique mammogram, in which the breast is compressed in a 45 degree angle from the axilla to the lower sternum



**What are the best studies to evaluate for a pulmonary embolus?**

Spiral thoracic CT scan, V/Q scan, pulmonary angiogram (gold standard)

## **RAPID FIRE REVIEW**

**Name the diagnostic modality:**

**40-year-old woman s/p MVC with pelvic fracture develops right lower extremity swelling**

Extremity duplex scan (duplex is ultrasound and Doppler ultrasound) to look for DVT

# Chapter 30 Anesthesia

**Define the following terms:**

**Local anesthesia**

Anesthesia of a small confined area of the body (e.g., lidocaine for an elbow laceration)

**Epidural anesthesia**

Anesthetic agents injected into the epidural space

**Spinal anesthesia**

Anesthetic agents injected into the thecal sac

**Regional anesthesia**

Anesthetic agents injected around from a **region** of the body (e.g., radial nerve block)

**General anesthesia**

Triad:

1. Unconsciousness/amnesia
2. Analgesia
3. Muscle relaxation

**GET or GETA**

General EndoTracheal Anesthesia

**Give examples of the following terms:**

**Local anesthetic**

Lidocaine, bupivacaine (Marcaine®)

**Regional anesthetic**

Lidocaine, bupivacaine (Marcaine®)

### **General anesthesia**

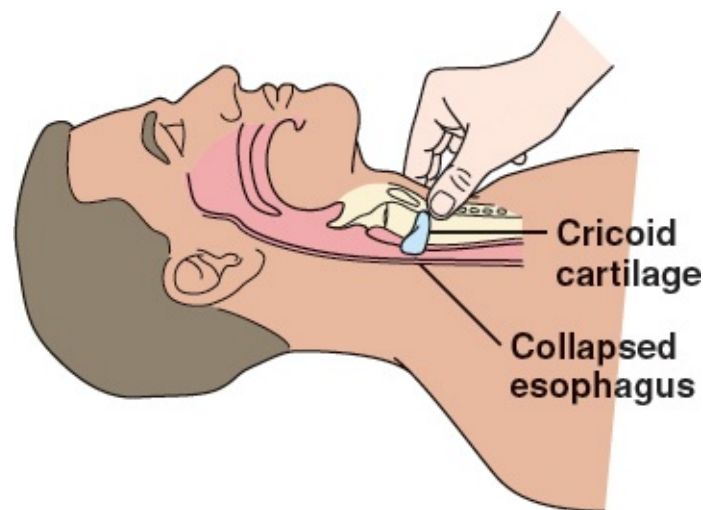
Isoflurane, sevoflurane, desflurane

### **Dissociative agent**

Ketamine

### **What is cricoid pressure?**

Manual pressure on cricoid cartilage occluding the esophagus and thus decreasing the chance of aspiration of gastric contents during intubation (a.k.a. “Sellick’s maneuver”)



### **What is “rapid-sequence” anesthesia induction?**

- . Oxygenation and short-acting induction agent
- . Paralytic
- . Cricoid pressure
- . Intubation
- . Inhalation anesthetic (rapid: boom, boom, boom → to lower the risk of aspiration during intubation)

### **Give examples of induction agents**

Propofol, etomidate, ketamine

### **What are contraindications of the depolarizing agent succinylcholine?**

Patients with burns, neuromuscular diseases/paraplegia, eye trauma, or increased ICP

**Why is succinylcholine contraindicated in these patients?**

Depolarization can result in life-threatening **hyperkalemia**

**Why doesn't lidocaine work in an abscess?**

Lidocaine does not work in an **acidic** environment

**What will reverse rocuronium?**

Sugammadex—a “selective relaxant binding agent”

**Why does lidocaine burn on injection and what can be done to decrease the burning sensation?**

Lidocaine is acidic, which causes the burning; add sodium bicarbonate to decrease the burning sensation

**Why does some lidocaine come with epinephrine?**

Epinephrine vasoconstricts the small vessels, resulting in a decrease in bleeding and blood flow in the area; this prolongs retention of lidocaine and its effects

**In what locations is lidocaine with epinephrine contraindicated?**

Fingers, toes, penis, etc., because of the possibility of ischemic injury/necrosis resulting from vasoconstriction

**What are the contraindications to nitrous oxide?**

Nitrous oxide is poorly soluble in serum and thus expands into any air-filled body pockets; avoid in patients with middle ear occlusions, **pneumothorax**, **small bowel obstruction**, etc.

**What is the feared side effect of bupivacaine (Marcaine®)?**

Cardiac dysrhythmia after intravascular injection leading to fatal refractory dysrhythmia

**What is the treatment of life-threatening respiratory depression with narcotics?**

IV Narcan® (naloxone)

### **What are the side effects of epidural analgesia?**

**Orthostatic hypotension**, decreased motor function, urinary retention (lumbar epidurals)

## **MALIGNANT HYPERTHERMIA (MH)**

### **What is it?**

Inherited predisposition to an anesthetic reaction, causing uncoupling of the excitation–contraction system in skeletal muscle, which in turn causes **malignant hyperthermia**; hypermetabolism is fatal if untreated

### **What is the incidence?**

Very rare

### **What are the causative agents?**

Volatile anesthetics, succinylcholine

### **What are the signs/symptoms?**

**Increased body temperature**; hypoxia; acidosis; tachycardia,  $\uparrow$   $\text{PCO}_2$  ( $\uparrow$  end tidal  $\text{CO}_2$ )

### **What is the earliest sign of MH?**

Rising end tidal  $\text{CO}_2$

### **What is the treatment?**

**IV dantrolene**, body cooling, discontinuation of volatile anesthetics

## **MISCELLANEOUS**

### **What are the antidotes to the nondepolarizing neuromuscular blocking agents?**

Neostigmine

### **What is the antidote to reverse succinylcholine?**

Time; endogenous blood pseudocholinesterase (patients deficient in this enzyme

may be paralyzed for hours!)

**What are the early signs of local anesthetic toxicity?**

Tinnitus, perioral/tongue numbness, metallic taste, blurred vision, muscle twitches, drowsiness

**What are the signs of local anesthetic toxicity with large overdose?**

Seizures, coma, respiratory arrest

Loss of consciousness

Apnea

**What is used to reverse narcotics?**

Naloxone (Narcan®)

**What is used to reverse benzodiazepines?**

Flumazenil

## RAPID FIRE REVIEW

**What is the correct diagnosis?**

**48-year-old woman undergoes a hysterectomy and develops an acute increase in end tidal CO<sub>2</sub> in the middle of the operation and then develops a very high fever, cardiac arrhythmia, acidosis, and hyperkalemia**

Malignant hyperthermia

# Chapter 31 Surgical Ulcers

**Define the following terms:**

**Peptic ulcer**

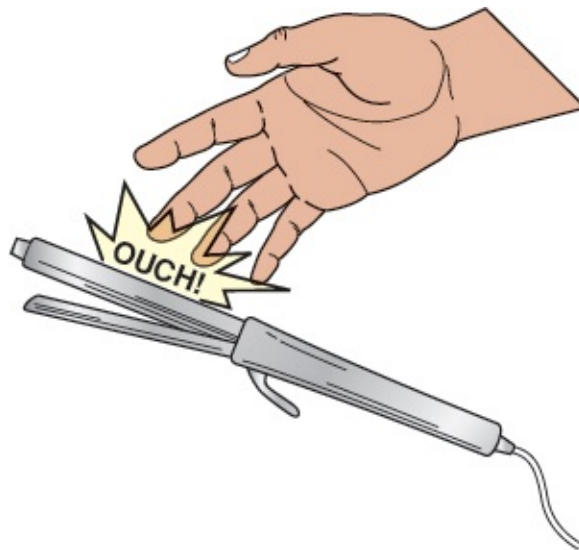
General term for gastric/duodenal ulcer disease

**Gastric ulcer**

Ulcer in the stomach

**Curling's ulcer**

Gastric ulcer after burn injury (Think: Curling's—curling iron burn—burn)



**Cushing's ulcer**

Peptic ulcer after neurologic insult (Think: Cushing—famous neurosurgeon)

**Dieulafoy's ulcer**

Pinpoint gastric mucosal defect bleeding from underlying arterial vessel malformation

**Marjolin's ulcer**

Squamous cell carcinoma ulceration overlying chronic osteomyelitis or burn scar

**Aphthous ulcer**

GI tract ulcer seen in Crohn's disease

**Marginal ulcer**

Mucosal ulcer seen at a site of GI tract anastomosis

**Decubitus ulcer**

Skin/subcutaneous ulceration from pressure necrosis, classically on the buttocks/sacrum

**Venous stasis ulcer**

Skin ulceration on **medial malleolus** caused by venous stasis of a lower extremity

**LE arterial insufficiency ulcer**

Skin ulcers usually located on the toes/feet

## RAPID FIRE REVIEW

**What is the correct diagnosis?**

**39-year-old woman 3 years s/p ("status post") Billroth II for perforated gastric ulcer presents with intermittent upper abdominal pain relieved by a large amount of bilious vomiting**

Afferent limb syndrome

**Name the most likely diagnosis:**

**45-year-old man with long-term left lower leg swelling develops a nonhealing sore over the left medial malleolus**

Venous stasis ulcer

# Chapter 32 Surgical Oncology

## Define:

### **Surgical oncology**

Surgical treatment of tumors

### **XRT**

Radiation therapy

### **In situ**

Not invading basement membrane

### **Benign**

Nonmalignant tumor—does not invade or metastasize

### **Malignant**

Tumors with anaplasia that invade and metastasize

### **Adjuvant RX**

Treatment that aids or assists surgical treatment = chemo or XRT

### **Neoadjuvant RX**

Chemo, XRT, or both BEFORE surgical resection

### **Brachytherapy**

XRT applied directly or very close to the target tissue (e.g., implantable radioactive seeds)

### **Metachronous tumors**

Tumors occurring at different times

### **Synchronous tumors**

Tumors occurring at the same time

**What do the T, M, and N stand for in TMN staging?**

**T**–Tumor size

**M**–Mets (distant)

**N**–Nodes

**What tumor marker is associated with colon cancer?**

CEA

**What tumor marker is associated with hepatoma?**

$\alpha$ -Fetoprotein

**What tumor marker is associated with pancreatic carcinoma?**

CA 19-9

**What is paraneoplastic syndrome?**

Syndrome of dysfunction not directly associated with tumor mass or metastasis (autoimmune or released substance)

**What are the most common cancers in women?**

- . Breast
- . Lung
- . Colorectal

**What are the most common cancers in men?**

- . Skin cancer
- . Prostrate
- . Lung
- . Colorectal

**What is the most common cancer causing death in both men and women?**

Lung!

# SECTION III

## **General Surgery**

# Chapter 33 GI Hormones and Physiology

## CHOLECYSTOKININ (CCK)

### **What is its source?**

Duodenal mucosal cells

### **What stimulates its release?**

Fat, protein, amino acids, HCl

### **What inhibits its release?**

Trypsin and chymotrypsin

### **What are its actions?**

Empties gallbladder

Opens ampulla of Vater

Slows gastric emptying

Stimulates pancreatic acinar cell growth and release of exocrine products

## SECRETIN

### **What is its source?**

Duodenal cells (specifically the argyrophilic S cells)

### **What stimulates its release?**

pH <4.5 (acid), fat in the duodenum

### **What inhibits its release?**

High pH in the duodenum

**What are its actions?**

Releases pancreatic bicarbonate/enzymes/H<sub>2</sub>O

Releases bile/bicarbonate

Decreases lower esophageal sphincter (LES) tone

Decreases release of gastric acid

## GASTRIN

**What is its source?**

Gastric antrum G cells

**What stimulates its release?**

Stomach peptides/amino acids

Vagal input

Calcium

**What inhibits its release?**

pH <3.0

Somatostatin

**What are its actions?**

Release of HCl from parietal cells

Trophic effect on mucosa of the stomach and small intestine

## SOMATOSTATIN

**What is its source?**

Pancreatic D cells

**What stimulates its release?**

Food

**What are its actions?**

Globally inhibits GI function

## MISCELLANEOUS

**What is the purpose of the colon?**

Reabsorption of H<sub>2</sub>O and storage of stool

**What is the main small bowel nutritional source?**

Glutamine

**What is the main nutritional source of the colon?**

Butyrate (short-chain fatty acid)

**Where is calcium absorbed?**

Duodenum actively, jejunum passively

**Where is iron absorbed?**

Duodenum

**Where is vitamin B12 absorbed?**

Terminal ileum

**Which hormone primarily controls gallbladder contraction?**

CCK

**What supplement does a patient need after removal of the terminal ileum or stomach?**

Vitamin B12

**What is the blood supply to the liver?**

75% from the portal vein, rich in products of digestion

25% from the hepatic artery, rich in O<sub>2</sub> (but each provide for 50% of oxygen)

## RAPID FIRE REVIEW

**What is the correct diagnosis?**

## **Necrotizing migratory erythema**

Glucagonoma

**Name the diagnostic modality:**

**30-year-old female with history of duodenal ulcers and jejunal ulcers refractory to PPI, watery diarrhea**

Gastric level and secretin stimulation test for gastrin, CT scan for work up for gastrinoma (Zollinger–Ellison syndrome)

# Chapter 34 Acute Abdomen and Referred Pain

## **What is an “acute abdomen”?**

Acute abdominal pain so severe that the patient seeks medical attention (**Note:** Not the same as a “surgical abdomen,” because most cases of acute abdominal pain do not require surgical treatment)

## **What are peritoneal signs?**

Signs of peritoneal irritation: extreme tenderness, percussion tenderness, rebound tenderness, voluntary guarding, motion pain, **involuntary** guarding/rigidity (late)

## **Define the following terms:**

### **Rebound tenderness**

Pain upon releasing the palpating hand pushing on the abdomen

### **Motion pain**

Abdominal pain upon moving, pelvic rocking, moving of stretcher, or heel strike

### **Voluntary guarding**

Abdominal muscle contraction with palpation of the abdomen

### **Involuntary guarding**

Rigid abdomen as the muscles “guard” involuntarily

### **Colic**

Intermittent severe pain (usually because of intermittent contraction of a hollow viscus against an obstruction)

**What conditions can mask abdominal pain?**

Steroids, diabetes, paraplegia

**What is the most common cause of acute abdominal surgery in the United States?**

Acute appendicitis (7% of the population will develop it sometime during their lives)

**What should the acute abdomen physical exam include?**

**Inspection** (e.g., surgical scars, distention)

**Auscultation** (e.g., bowel sounds, bruits)

**Palpation** (e.g., tenderness, R/O hernia, CVAT, rectal, pelvic exam, rebound, voluntary guard, motion tenderness)

**Percussion** (e.g., liver size, spleen size)

**What should go first, auscultation or palpation?**

Auscultation

**What is the best way to have a patient localize abdominal pain?**

“Point with **one** finger to where the pain is worse”

**What is the classic position of a patient with peritonitis?**

Motionless (often with knees flexed)

**What is the classic position of a patient with a kidney stone?**

Cannot stay still, restless, writhing in pain

**What is the best way to examine a scared child or histrionic adult's abdomen?**

Use stethoscope to palpate abdomen

**What lab tests are used to evaluate the patient with an acute abdomen?**

CBC with **differential**, chem-10, amylase, type and screen, urinalysis, LFTs

**What is a “left shift” on CBC differential?**

Sign of inflammatory response:

Immature neutrophils (bands)

**Note:** Many call >80% of WBCs as neutrophils a “left shift”

**What lab test should every woman of childbearing age with an acute abdomen receive?**

Human chorionic gonadotropin ( $\beta$ -hCG) to rule out pregnancy/ectopic pregnancy

**Which x-rays are used to evaluate the patient with an acute abdomen?**

Upright chest x-ray, upright abdominal film, supine abdominal x-ray (if patient cannot stand, left lateral decubitus abdominal film)

**How is free air ruled out if the patient cannot stand?**

Left lateral decubitus—free air collects over the liver and does not get confused with the gastric bubble

**What diagnosis must be considered in every patient with an acute abdomen?**

**Appendicitis!**

**What are the differential diagnoses by quadrant?**

**RUQ**

Cholecystitis, hepatitis, PUD, perforated ulcer, pancreatitis, liver tumors, gastritis, hepatic abscess, choledocholithiasis, cholangitis, pyelonephritis, nephrolithiasis, appendicitis (**especially during pregnancy**); thoracic causes (e.g., pleurisy/pneumonia), PE, pericarditis, MI (especially inferior MI)

**LUQ**

PUD, perforated ulcer, gastritis, splenic injury, abscess, reflux, dissecting aortic aneurysm, thoracic causes, pyelonephritis, nephrolithiasis, hiatal hernia (strangulated paraesophageal hernia), Boerhaave's syndrome, Mallory–Weiss tear, splenic artery aneurysm, colon disease

**LLQ**

**Diverticulitis**, sigmoid volvulus, perforated colon, colon cancer, urinary tract infection, small bowel obstruction, inflammatory bowel disease, nephrolithiasis, pyelonephritis, fluid accumulation from aneurysm or

perforation, referred hip pain, gynecologic causes, appendicitis (rare)

## **RLQ**

**Appendicitis!** And same as LLQ; also mesenteric lymphadenitis, cecal diverticulitis, Meckel's diverticulum, intussusception

## **What is the differential diagnosis of epigastric pain?**

PUD, gastritis, MI, pancreatitis, biliary colic, gastric volvulus, Mallory–Weiss tear

## **What are nonsurgical causes of abdominal pain?**

Gastroenteritis, DKA, sickle cell crisis, rectus sheath hematoma, acute porphyria, PID, kidney stone, pyelonephritis, hepatitis, pancreatitis, pneumonia, MI, *Clostridium difficile* colitis

## **What is the unique differential diagnosis for the patient with AIDS and abdominal pain?**

In addition to all common abdominal conditions:

CMV (most Common)

Kaposi's sarcoma

Lymphoma

TB

*Mycobacterium Avium* Intracellulare (MAI)

## **What causes pain limited to specific dermatomes?**

Early zoster before vesicles erupt

## **What is referred pain?**

Pain felt at a site distant from a disease process

## **Name the classic locations of referred pain:**

### **Cholecystitis**

Right subscapular pain (also epigastric)

### **Appendicitis**

Early: periumbilical

Rarely: testicular pain

**Diaphragmatic irritation (from spleen, perforated ulcer, or abscess)**

Shoulder pain (+ Kehr's sign on the left)

**Pancreatitis/cancer**

Back pain

**Rectal disease**

Pain in the small of the back

**Nephrolithiasis**

Testicular pain/flank pain

**Rectal pain**

Midline small of back pain

**Small bowel**

Periumbilical pain

**Uterine pain**

Midline small of back pain

**Give the classic diagnosis for the following cases:**

**“Abdominal pain out of proportion to exam”**

Rule out mesenteric ischemia

**Hypotension and pulsatile abdominal mass**

Ruptured AAA; go to the O.R.

**Fever, LLQ pain, and change in bowel habits**

Diverticulitis

**Classically, what endocrine problems can cause abdominal pain?**

- . Addisonian crisis
- . Diabetic KetoAcidosis (DKA)

## RAPID FIRE REVIEW

**Name the most likely diagnosis:**

**22-year-old woman with acute onset of lower abdominal pain, hypotension, tachycardia, adnexal mass, and free fluid on vaginal ultrasound**

Ectopic pregnancy rupture

**21-year-old woman with fever, leukocytosis, lower abdominal pain, + chandelier sign**

Pelvic Inflammatory Disease (PID)

**54-year-old male smoker with c/o right-sided abdominal pain, hematuria, and a mass in the right side of his abdomen**

Renal cell carcinoma

**Abdominal pain “out of proportion to exam”**

Mesenteric ischemia

**67-year-old man with hypotension, abdominal pain, and an abdominal mass that pulsates**

Ruptured abdominal aortic aneurysm

**67-year-old female smoker with a history of 25-pound weight loss over 3 months due to abdominal pain after eating; nontender abdomen on exam**

Chronic mesenteric ischemia

# Chapter 35 Hernias

## **What is hernia?**

(**L. *rupture***) Protrusion of a peritoneal sac through a musculoaponeurotic barrier (e.g., abdominal wall); a fascial defect

## **What is the incidence?**

5% to 10% lifetime; 50% are indirect inguinal, 25% are direct inguinal, and ≈5% are femoral

## **What are the precipitating factors?**

Increased intra-abdominal pressure: straining at defecation or urination (rectal cancer, colon cancer, prostatic enlargement, constipation), obesity, pregnancy, ascites, valsavagenic (coughing) COPD; an abnormal congenital anatomic route (i.e., patent processus vaginalis)

## **Why should hernias be repaired?**

To avoid complications of incarceration/strangulation, bowel necrosis, SBO, pain

## **What is more dangerous: a small or large hernia defect?**

Small defect is more dangerous because a tight defect is more likely to strangulate if incarcerated

## **Define the following descriptive terms:**

### **Reducible**

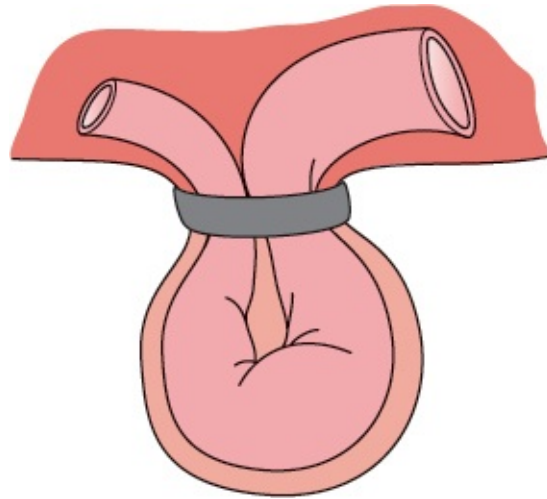
Ability to return the displaced organ or tissue/hernia contents to their usual anatomic site

### **Incarcerated**

Swollen or fixed within the hernia sac (incarcerated = imprisoned); may cause intestinal obstruction (i.e., an irreducible hernia)

## Strangulated

Incarcerated hernia with resulting ischemia; will result in signs and symptoms of ischemia and intestinal obstruction or bowel necrosis (Think: strangulated = choked)



## Complete

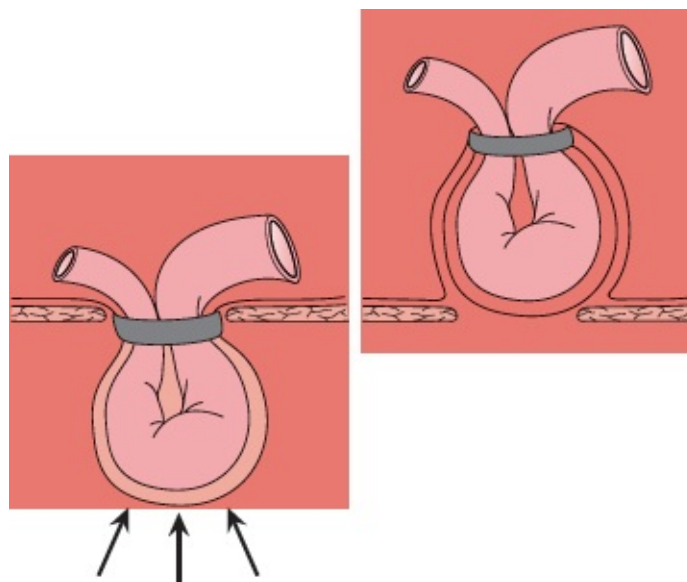
Hernia sac and its contents protrude all the way through the defect

## Incomplete

Defect present without sac or contents protruding completely through it

## What is reducing a hernia “en masse”?

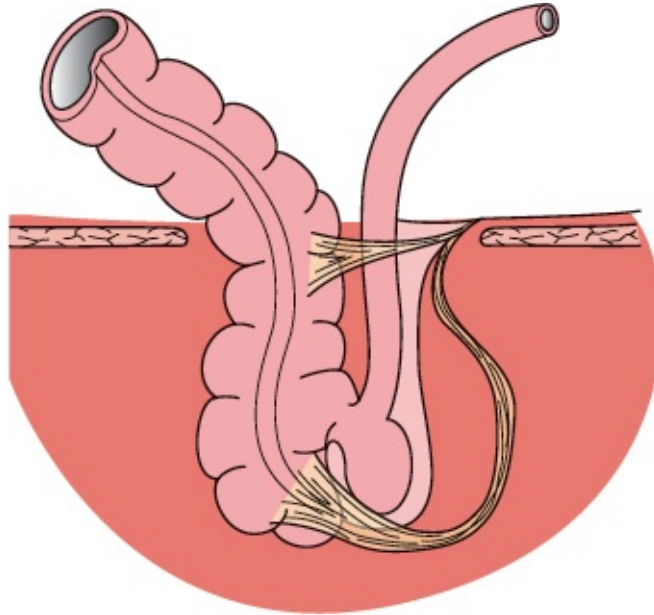
Reducing the hernia contents and hernia sac



## Define the following types of hernias:

### Sliding hernia

Hernia sac partially formed by the wall of a viscus (i.e., bladder/cecum)



### Littre's hernia

Hernia involving a Meckel's diverticulum (Think alphabetically: Littre's Meckel's = LM)

### Spigelian hernia

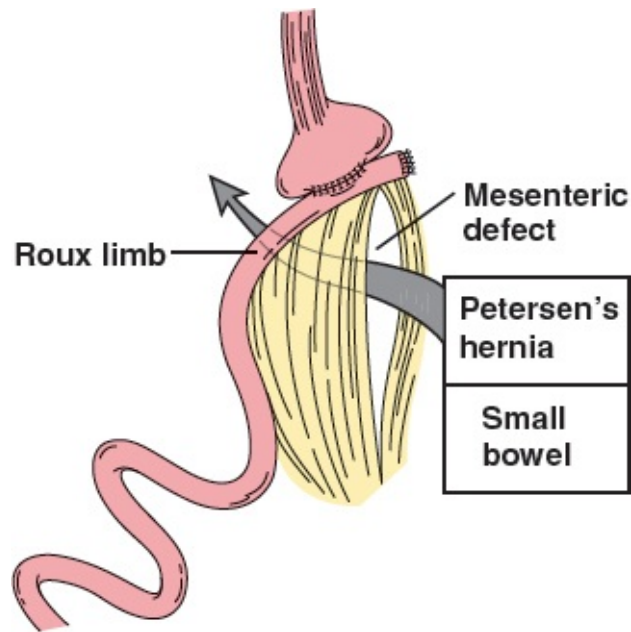
Hernia through the linea semilunaris (or spigelian fascia); also known as spontaneous lateral ventral hernia (Think: Spigelian = Semilunaris)

### Internal hernia

Hernia in or involving intra-abdominal structure

### Petersen's hernia

Seen after bariatric gastric bypass—internal herniation of small bowel through the mesenteric defect from the Roux limb

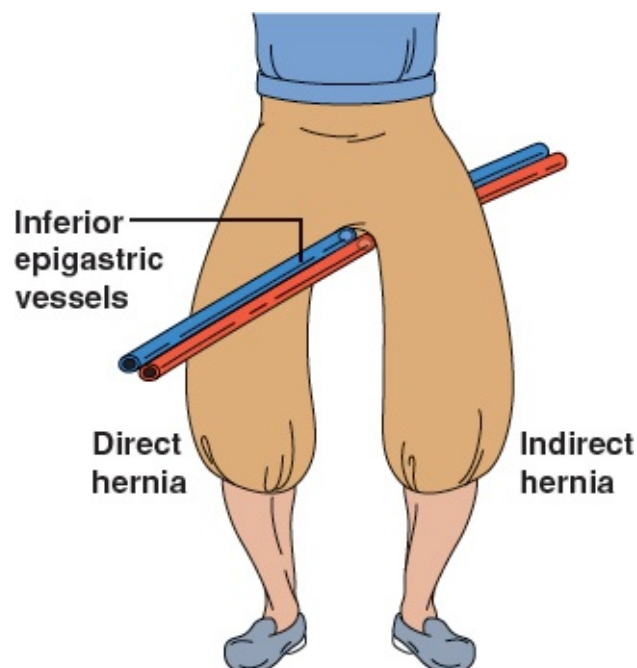


### Obturator hernia

Hernia through obturator canal (females > males)

### Pantaloon hernia

Hernia sac exists as **both a direct and indirect** hernia straddling the inferior epigastric vessels and protruding through the floor of the canal as well as the internal ring (two sacs separated by the inferior epigastric vessels [the pant crotch] like a pair of pantaloons)



### **Incisional hernia**

Hernia through an incisional site; most common cause is a wound infection

### **Ventral hernia**

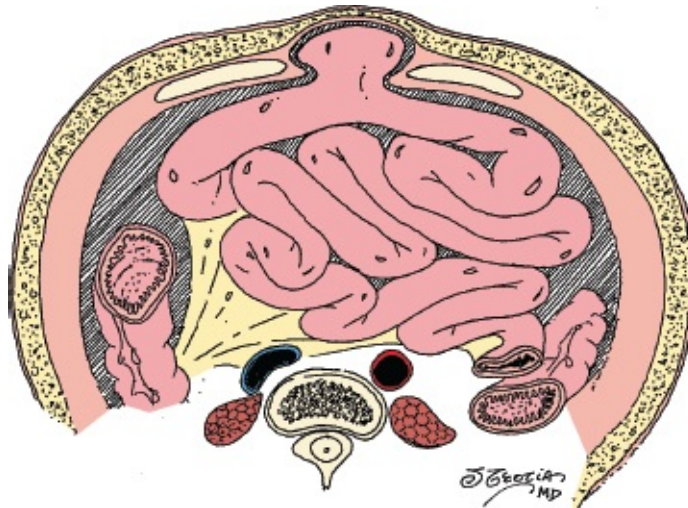
Incisional hernia in the ventral abdominal wall

### **Parastomal hernia**

Hernia adjacent to an ostomy (e.g., colostomy)

### **Richter's hernia**

Incarcerated or strangulated hernia involving only **one sidewall of the bowel**, which can spontaneously reduce, resulting in gangrenous bowel and perforation within the abdomen without signs of obstruction



### **Epigastric hernia**

Hernia through the linea alba above the umbilicus

### **Umbilical hernia**

Hernia through the umbilical ring, in adults associated with ascites, pregnancy, and obesity

### **Femoral hernia**

Hernia medial to femoral vessels (under inguinal ligament)

### **Indirect inguinal**

Inguinal hernia lateral to Hesselbach's triangle

### **Direct inguinal**

Inguinal hernia within Hesselbach's triangle

### **Hiatal hernia**

Hernia through esophageal hiatus

### **What are the boundaries of Hesselbach's triangle?**

- . Inferior epigastric vessels
- . Inguinal ligament (Poupart's)
- . Lateral border of the rectus sheath

Floor consists of internal oblique and the transversus abdominis muscle

### **What are the layers of the abdominal wall?**

Skin

Subcutaneous fat

Scarpa's fascia

External oblique

Internal oblique

Transversus abdominis

Transversalis fascia

Preperitoneal fat

Peritoneum

**Note:** All three muscle layer aponeuroses form the anterior rectus sheath, with the posterior rectus sheath being deficient below the arcuate line

### **What is the differential diagnosis for a mass in a healed C-section incision?**

Hernia, ENDOMETRIOMA

## **GROIN HERNIAS**

### **What is the differential diagnosis of a groin mass?**

Lymphadenopathy, hematoma, seroma, abscess, hydrocele, femoral artery aneurysm, EIC, undescended testicle, sarcoma, hernias, testicle torsion

## ■ Direct Inguinal Hernia

### **What is it?**

Hernia within the floor of Hesselbach's triangle, that is, the hernia sac does not traverse the internal ring (Think: **directly** through the abdominal wall)

### **What is the cause?**

Acquired defect from mechanical breakdown over the years

### **What is the incidence?**

≈1% of all men; frequency increases with advanced age

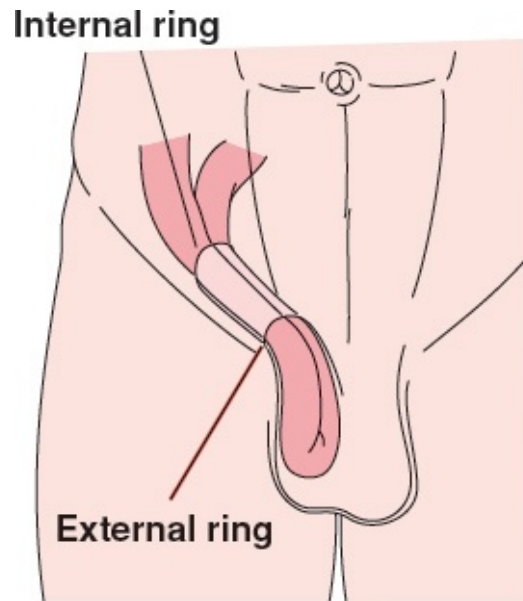
### **What nerve runs with the spermatic cord in the inguinal canal?**

Ilioinguinal nerve

## ■ Indirect Inguinal Hernia

### **What is it?**

Hernia through the internal ring of the inguinal canal, traveling down toward the external ring; it may enter the scrotum upon exiting the external ring (i.e., if complete); think of the hernia sac traveling indirectly through the abdominal wall from the internal ring to the external ring



### **What is the cause?**

Patent processus vaginalis (i.e., congenital)

### **What is the incidence?**

≈5% of all men; most common hernia in both men **and** women

### **How is an inguinal hernia diagnosed?**

Relies mainly on history and physical exam with index finger invaginated into the external ring and palpation of hernia; examine the patient standing up if diagnosis is not obvious

(**Note:** if swelling occurs below the inguinal ligament, it is possibly a femoral hernia)

### **What is the differential diagnosis of an inguinal hernia?**

Lymphadenopathy, psoas abscess, ectopic testis, hydrocele of the cord, saphenous varix, lipoma, varicocele, testicular torsion, femoral artery aneurysm, abscess

### **What is the risk of strangulation?**

Higher with indirect than direct inguinal hernia, but highest in femoral hernias

### **What is the treatment?**

Emergent herniorrhaphy is indicated if strangulation is suspected or acute incarceration is present; otherwise, elective herniorrhaphy is indicated to prevent

the chance of incarceration/strangulation

## ■ Inguinal Hernia Repairs

**Define the following procedures:**

### **Bassini**

**Sutures** approximate reflection of inguinal ligament (Poupart's) to the transversus abdominis aponeurosis/conjoint tendon

### **McVay**

**Cooper's** ligament sutured to transversus abdominis aponeurosis/conjoint tendon

### **Lichtenstein**

"Tension-free repair" using mesh

### **Plug and patch**

Placing a plug of mesh in hernia defect and then overlaying a patch of mesh over inguinal floor (requires few if any sutures in mesh!)

### **High ligation**

Ligation and transection of indirect hernia sac without repair of inguinal floor (used only in **children**)

### **TAPP procedure**

Trans**A**bdominal **P**re**P**eritoneal inguinal hernia repair

### **TEPA procedure**

Totally **E**xtra**P**eritoneal **A**pproach

**What are the indications for laparoscopic inguinal hernia repair?**

- . Bilateral inguinal hernias
- . Recurring hernia
- . Need to resume full activity as soon as possible

## ■ Classic Intraoperative Inguinal Hernia Questions

**What is the first identifiable subcutaneous named layer?**

Scarpa's fascia (thin in adults)

**What is the name of the subcutaneous vein that is ligated?**

Superficial epigastric vein

**What happens if you cut the ilioinguinal nerve?**

Numbness of inner thigh or lateral scrotum; usually goes away in 6 months

**From what abdominal muscle layer is the cremaster muscle derived?**

Internal oblique muscle

**From what abdominal muscle layer is the inguinal ligament (a.k.a. "Poupart's ligament") derived?**

External oblique muscle aponeurosis

**To what does the inguinal (Poupart's) ligament attach?**

Anterior-superior iliac spine to the pubic tubercle

**Which nerve travels on the spermatic cord?**

Ilioinguinal nerve

**Why do some surgeons deliberately cut the ilioinguinal nerve?**

First they obtain preoperative consent and cut so as to remove the risk of entrapment and postoperative pain

**What is in the spermatic cord (6)?**

- . Cremasteric muscle fibers
- . Vas deferens
- . Testicular artery
- . Testicular pampiniform venous plexus
- . ± Hernia sac

. Genital branch of the genitofemoral nerve

**What is the hernia sac made of?**

Peritoneum (direct) or a patent processus vaginalis (indirect)

**What attaches the testicle to the scrotum?**

Gubernaculum

**What is the most common organ in an inguinal hernia sac in men?**

Small intestine

**What is the most common organ in an inguinal hernia sac in women?**

Ovary/fallopian tube

**What lies in the inguinal canal in females instead of the VAS?**

Round ligament

**Where in the inguinal canal does the hernia sac lie in relation to the other structures?**

Anteromedially

**What is a “cord lipoma”?**

Preperitoneal fat on the cord structures (pushed in by the hernia sac); not a real lipoma; remove surgically, if feasible

**What is a small outpouching of testicular tissue off the testicle?**

Testicular appendage (a.k.a. “the appendix testes”); remove with electrocautery

**What action should be taken if a suture is placed through the femoral artery or vein during an inguinal herniorrhaphy?**

Remove the suture as soon as possible and apply pressure (i.e., do not tie the suture down!)

**What nerve is found on top of the spermatic cord?**

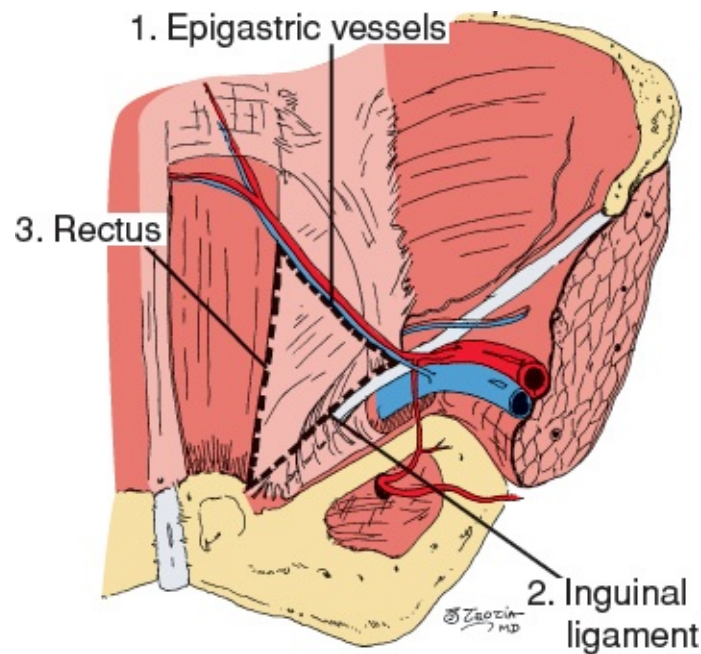
Ilioinguinal nerve

**What nerve travels within the spermatic cord?**

Genital branch of the genitofemoral nerve

### **What are the borders of Hesselbach's triangle?**

- . Epigastric vessels
- . Inguinal ligament
- . Lateral border of the rectus



### **What type of hernia goes through Hesselbach's triangle?**

Direct hernia due to a weak abdominal floor

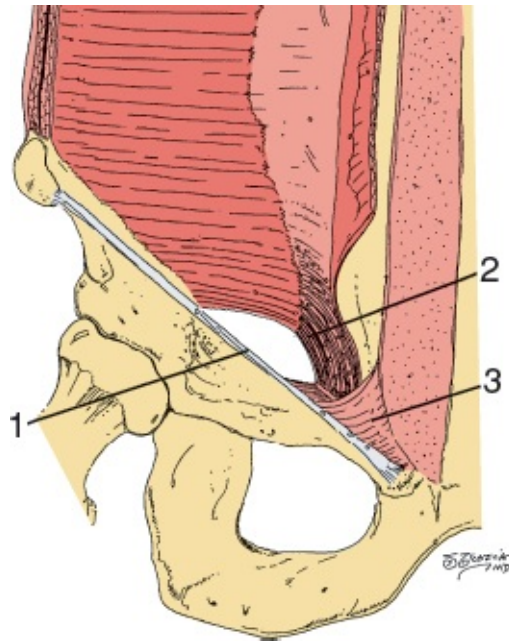
### **What is a “relaxing incision”?**

Incision(s) in the rectus sheath to relax the conjoint tendon so that it can be approximated to the reflection of the inguinal ligament without tension

### **What is a conjoint tendon?**

Aponeurotic attachments of the “conjoining” of the internal oblique and transversus abdominis to the pubic tubercle

### **Define inguinal anatomy**



- . Inguinal ligament (Poupart's ligament)
- . Transversus aponeurosis
- . Conjoint tendon

### **How tight should the new internal inguinal ring be?**

Should allow entrance of the tip of a Kelly clamp but not a finger (the new external inguinal ring should not be tight and should allow entrance of a finger)

### **What percentage of the strength of an inguinal floor repair does an external oblique aponeurosis represent?**

ZERO

## **Femoral Hernia**

### **What is it?**

Hernia traveling beneath the inguinal ligament down the femoral canal medial to the femoral vessels (Think: **FM** radio, or **F**emoral hernia = **M**edial)

### **What are the boundaries of the femoral canal?**

- . Cooper's ligament posteriorly
- . Inguinal ligament anteriorly

- . Femoral vein laterally
- . Lacunar ligament medially

**What factors are associated with femoral hernias?**

Women, pregnancy, and exertion

**What percentage of all hernias are femoral?**

5%

**What percentage of patients with a femoral hernia are female?**

85%!

**What are the complications?**

Approximately one third incarcerate (due to narrow, unforgiving neck)

**What is the most common hernia in women?**

Indirect inguinal hernia

**What is the repair of a femoral hernia?**

McVay (Cooper's ligament repair), mesh plug repair

## ESOPHAGEAL HIATAL HERNIAS

**Define type I and type II hiatal hernias.**

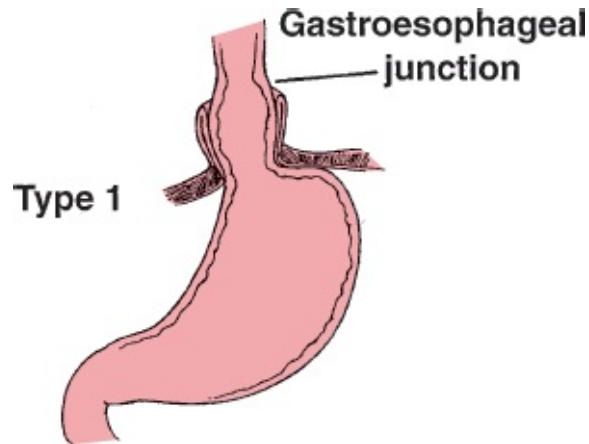
Type I = sliding

Type II = paraesophageal

### ■ Sliding Esophageal Hiatal Hernia

**What is it?**

Both the stomach and GE junction herniate into the thorax via the esophageal hiatus; also known as type I hiatal hernia



### **What is the incidence?**

>90% of all hiatal hernias

### **What are the symptoms?**

Most patients are asymptomatic, but the condition can cause reflux, dysphagia (from inflammatory edema), esophagitis, and pulmonary problems secondary to aspiration

### **How is it diagnosed?**

UGI series, manometry, esophagogastroduodenoscopy (EGD) with biopsy for esophagitis

### **What is the treatment?**

85% of cases treated medically with antacids, H<sub>2</sub> blockers/PPIs, head elevation after meals, small meals, and no food prior to sleeping; 15% of cases require surgery for persistent symptoms despite adequate medical treatment

### **What is the surgical treatment?**

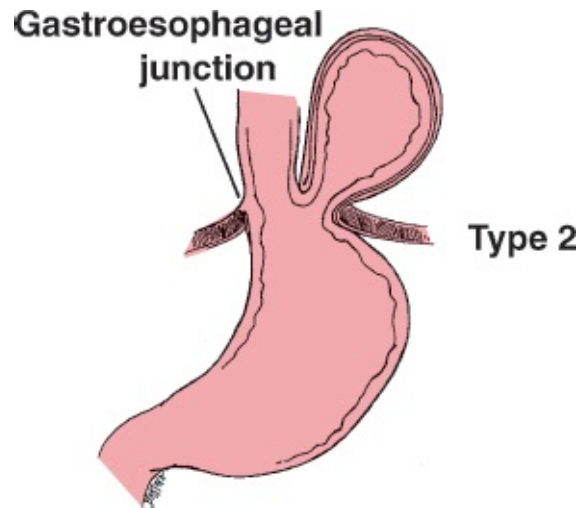
Laparoscopic Nissen fundoplication (LAP NISSEN) involves wrapping the fundus around the LES and suturing it in place

## **■ Paraesophageal Hiatal Hernia**

### **What is it?**

Herniation of all or part of the stomach through the esophageal hiatus into

**the thorax without displacement of the gastroesophageal junction; also known as type II hiatal hernia**



**What are the complications?**

Hemorrhage, incarceration, obstruction, and strangulation

**What is the treatment?**

Surgical, because of frequency and severity of potential complications

## **RAPID FIRE REVIEW**

**Name the most likely diagnosis:**

**28-year-old man with groin mass, vomiting, air-fluid levels on abdominal x-ray**

Incarcerated inguinal hernia

**29-year-old woman with a mass below inguinal ligament**

Femoral hernia

# Chapter 36 Laparoscopy

## **What is laparoscopy?**

Minimally invasive surgical technique using gas to insufflate the peritoneum and instruments manipulated through ports introduced through small incisions with video camera guidance

## **What gas is used and why?**

CO<sub>2</sub> because of better solubility in blood and, thus, less risk of gas embolism; noncombustible

## **What are the classic findings with a CO<sub>2</sub> gas embolus?**

Triad:

1. Hypotension
2. Decreased end tidal CO<sub>2</sub> (low flow to lung)
3. Mill-wheel murmur

## **What prophylactic measure should every patient get when they are going to have a laparoscopic procedure?**

SCD boots—Sequential Compression Device (and most add an OGT to decompress the stomach; Foley catheter is usually used for pelvic procedures)

## **What are the cardiovascular effects of a pneumoperitoneum?**

**Increased afterload** and **decreased preload** (but the CVP and PCWP are deceptively elevated!)

## **What is the effect of CO<sub>2</sub> insufflation on end tidal CO<sub>2</sub> levels?**

Increased as a result of absorption of CO<sub>2</sub> into the bloodstream; the body compensates with increased ventilation and blows the extra CO<sub>2</sub> off and thus there is no acidosis

## **What are the advantages over laparotomy?**

Shorter hospitalization, less pain and scarring, lower cost, decreased ileus

**What is the Veress needle?**

Needle with spring-loaded, retractable, blunt inner-protective tube that protrudes from the needle end when it enters peritoneal cavity; used for blind entrance and then insufflation of CO<sub>2</sub> through the Veress needle

**How can it be verified that the Veress needle is in the peritoneum?**

Syringe of saline; saline should flow freely without pressure through the needle “drop test”

**What is the Hasson technique?**

No Veress needle—cut down and place trocar under **direct visualization**

**What is the cause of postlaparoscopic shoulder pain?**

Referred pain from CO<sub>2</sub> on diaphragm and diaphragm stretch

**What is FRED®?**

**Fog Reduction Elimination Device:** sponge with antifog solution used to coat the camera lens

**How do you get the spleen out through a trocar site after a laparoscopic splenectomy?**

Morcellation in a bag, then remove piecemeal

# Chapter 37 Trauma

## What widely accepted protocol does trauma care in the United States follow?

Advanced Trauma Life Support (ATLS) precepts of the American College of Surgeons

## What are the three main elements of the ATLS protocol?

- . Primary survey/resuscitation
- . Secondary survey
- . Definitive care

## How and when should the patient history be obtained?

It should be obtained while completing the primary survey; often the rescue squad, witnesses, and family members must be relied upon

## PRIMARY SURVEY

## What are the five steps of the primary survey?

Think: “**ABCDEs**”:

**A**irway (and C spine stabilization)

**B**reathing

**C**irculation

**D**isability

**E**xposure and **E**nvironment

## What principles are followed in completing the primary survey?

Life threatening problems discovered during the primary survey are **always** addressed **before** proceeding to the next step

## **Airway**

### **What are the goals during assessment of the airway?**

Securing the airway and protecting the spinal cord

### **In addition to the airway, what MUST be considered during the airway step?**

Spinal immobilization

### **What comprises spinal immobilization?**

Use of a full backboard and rigid cervical collar

### **In an alert patient, what is the quickest test for an adequate airway?**

Ask a question: If the patient can speak, the airway is intact

### **What is the first maneuver used to establish an airway?**

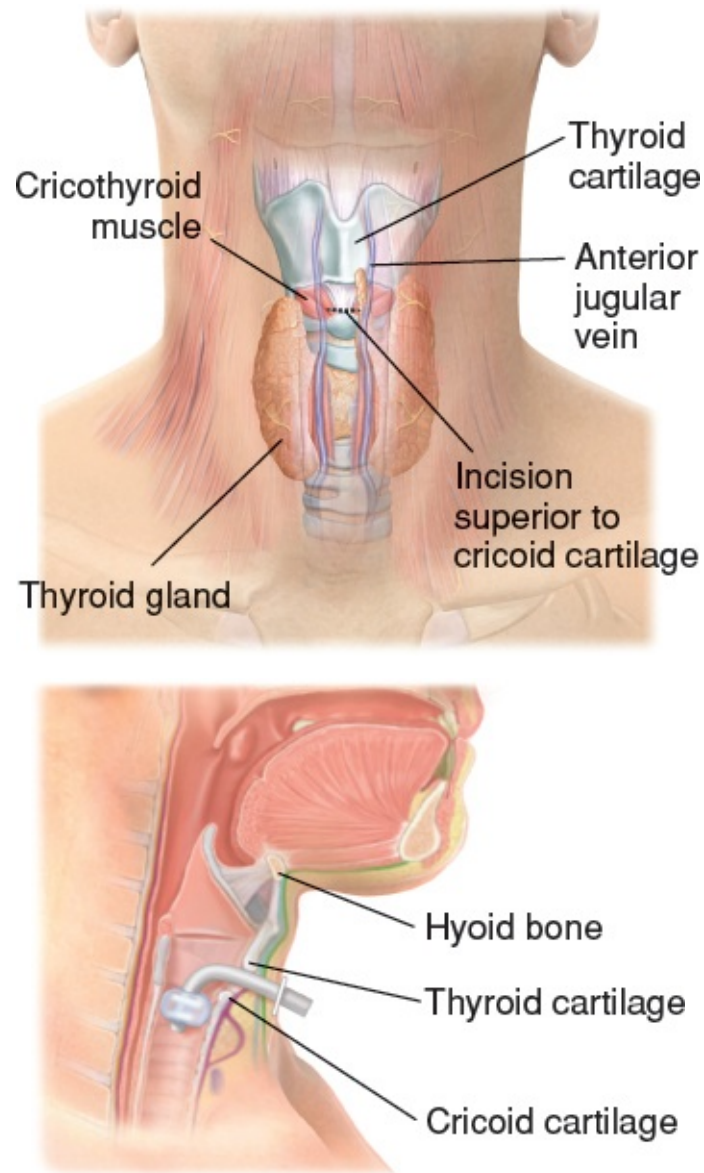
Chin lift, jaw thrust, or both; if successful, often an oral or nasal airway can be used to temporarily maintain the airway

### **If these methods are unsuccessful, what is the next maneuver used to establish an airway?**

Endotracheal intubation

### **If all other methods are unsuccessful, what is the definitive airway?**

Cricothyroidotomy, a.k.a. “surgical airway”: Incise the cricothyroid membrane between the cricoid cartilage inferiorly and the thyroid cartilage superiorly and place an endotracheal or tracheostomy tube into the trachea



### **What must always be kept in mind during difficult attempts to establish an airway?**

Spinal immobilization and adequate oxygenation; if at all possible, patients must be adequately ventilated with 100% oxygen using a bag and mask before any attempt to establish an airway

## **■ Breathing**

**What are the goals in assessing breathing?**

Securing oxygenation and ventilation  
Treating life-threatening thoracic injuries

### **What comprises adequate assessment of breathing?**

Inspection—for air movement, respiratory rate, cyanosis, tracheal shift, jugular venous distention (JVD), asymmetric chest expansion, use of accessory muscles of respiration, open chest wounds

Auscultation—for breath sounds

Percussion—for hyperresonance or dullness over either lung field

Palpation—for presence of subcutaneous emphysema, flail segments

### **What are the life-threatening conditions that MUST be diagnosed and treated during the breathing step?**

Tension pneumothorax, open pneumothorax, massive hemothorax

## *Pneumothorax*

### **What is it?**

Injury to the lung, resulting in release of air into the pleural space between the normally apposed parietal and visceral pleura

### **How is it diagnosed?**

**Tension pneumothorax is a clinical diagnosis:** dyspnea, JVD, tachypnea, anxiety, pleuritic chest pain, unilateral decreased or absent breath sounds, tracheal shift away from the affected side, hyperresonance on the affected side

### **What is the treatment of a tension pneumothorax?**

Rapid thoracostomy incision or **immediate** decompression by **needle thoracostomy** in the second intercostal space midclavicular line, followed by **tube thoracostomy** placed in the anterior/midaxillary line in the fourth intercostal space (level of the nipple in men)

### **What is the medical term for a “sucking chest wound”?**

Open pneumothorax

### **What is a tube thoracostomy?**

“Chest tube”

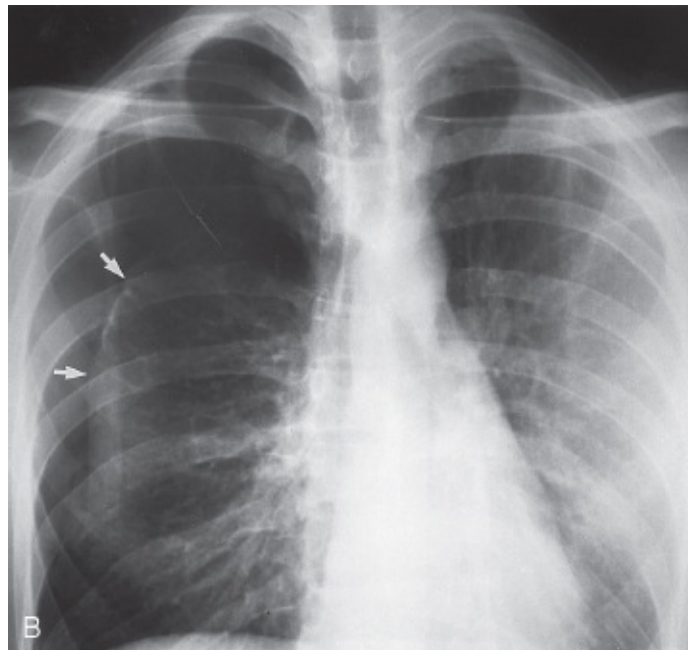
## How is an open pneumothorax diagnosed and treated?

**Diagnosis:** usually obvious, with air movement through a chest wall defect and pneumothorax on CXR

**Treatment in the ER:** tube thoracostomy (chest tube), occlusive dressing over chest wall defect

## What does a pneumothorax look like on chest x-ray (CXR)?

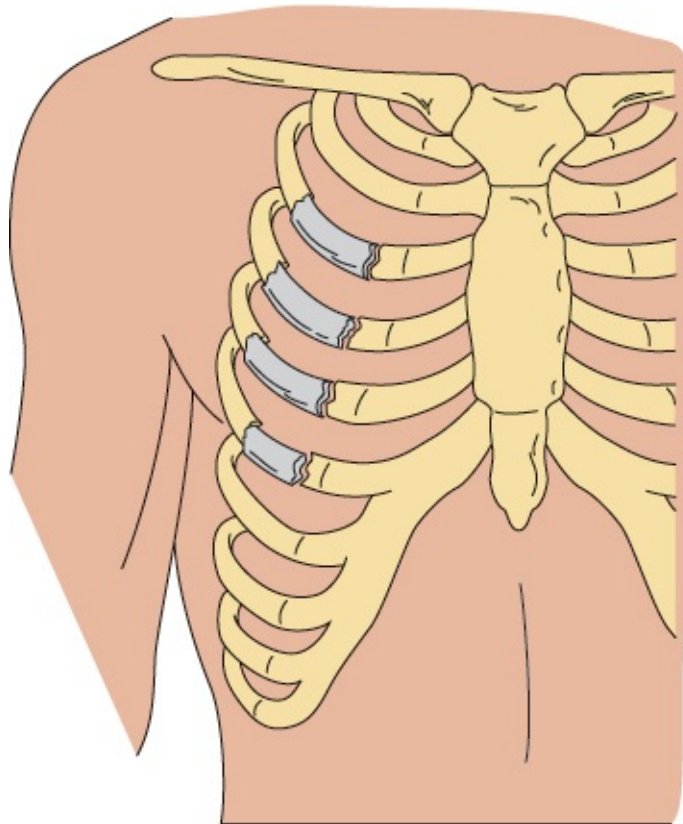
Loss of lung markings (figure shows a right-sided pneumothorax; arrows point out edge of lung–air interface)



## ► Flail Chest

### What is it?

Two separate fractures in three or more consecutive ribs



### **How is it diagnosed?**

Flail segment of chest wall that moves **paradoxically** (sucks in with inspiration and pushes out with expiration opposite the rest of the chest wall)

### **What is the major cause of respiratory compromise with flail chest?**

Underlying pulmonary contusion!

### **What is the treatment?**

**Intubation** with positive pressure ventilation and PEEP PRN (let ribs heal on their own)

## **► Cardiac Tamponade**

### **What is it?**

Bleeding into the pericardial sac, resulting in constriction of heart, decreasing inflow and resulting in decreased cardiac output (the pericardium does not stretch!)

## What are the signs and symptoms?

Tachycardia/shock with **Beck's triad**, pulsus paradoxus, Kussmaul's sign

## Define the following:

### **Beck's triad**

- . Hypotension
- . Muffled heart sounds
- . JVD

### **Kussmaul's sign**

JVD with inspiration

### **How is cardiac tamponade diagnosed?**

Ultrasound (echocardiogram)

## What is the treatment?

Pericardial window—if blood returns then median sternotomy to rule out and treat cardiac injury

## ► *Massive Hemothorax*

### **How is it diagnosed?**

Unilaterally decreased or absent breath sounds; dullness to percussion; CXR, CT scan, chest tube output

### **What is the treatment?**

Volume replacement

#### **Tube thoracostomy** (chest tube)

Removal of the blood (which will allow apposition of the parietal and visceral pleura, sealing the defect and slowing the bleeding)

### **What are indications for emergent thoracotomy for hemothorax?**

Massive hemothorax =

1. >1500 cc of blood on initial placement of chest tube
2. Persistent >200 cc of bleeding via chest tube per hour × 4 hours

## ■ Circulation

### **What are the goals in assessing circulation?**

Securing adequate tissue perfusion; treatment of external bleeding

### **What is the initial test for adequate circulation?**

Palpation of pulses: As a rough guide, if a radial pulse is palpable, then systolic pressure is at least 80 mm Hg; if a femoral or carotid pulse is palpable, then systolic pressure is at least 60 mm Hg

### **What comprises adequate assessment of circulation?**

Heart rate, blood pressure, peripheral perfusion, urinary output, mental status, capillary refill (normal <2 seconds), exam of skin: cold, clammy = hypovolemia

### **Who can be hypovolemic with normal blood pressure?**

Young patients; autonomic tone can maintain blood pressure until cardiovascular collapse is imminent

### **Which patients may not mount a tachycardic response to hypovolemic shock?**

Those with concomitant spinal cord injuries

Those on  $\beta$ -blockers

Well-conditioned athletes

### **How are sites of external bleeding treated?**

By direct pressure;  $\pm$  tourniquets

### **What is the best and preferred intravenous (IV) access in the trauma patient?**

“Two large-bore IVs” (14 to 16 gauge), IV catheters in the upper extremities (peripheral IV access)

### **For a femoral vein catheter, how can the anatomy of the right groin be remembered?**

Lateral to medial “NAVEL”:

Nerve

Artery

Vein

Empty space

Lymphatics

Thus, the vein is medial to the femoral artery pulse (Or, Think: “venous close to penis”)

### **What is the trauma resuscitation fluid of choice?**

Lactated Ringer’s (LR) solution (isotonic, and the lactate helps buffer the hypovolemia-induced metabolic acidosis)

### **What types of decompression do trauma patients receive?**

Gastric decompression with an NGT and Foley catheter bladder decompression after **normal rectal exam** and no indication of urethral injury

### **What are the contraindications to placement of a Foley?**

Signs of urethral injury:

- Severe pelvic fracture in men

- Blood at the urethral meatus (penile opening)

- “High-riding,” “ballotable” prostate (loss of urethral tethering)

- Scrotal/perineal injury/ecchymosis

### **What test should be obtained prior to placing a Foley catheter if urethral injury is suspected?**

**Retrograde UrethroGram (RUG):** dye in penis retrograde to the bladder and x-ray looking for extravasation of dye

### **How is gastric decompression achieved with a maxillofacial fracture?**

**Not** with an NGT because the tube may perforate through the cribriform plate into the brain; place an **oral**-gastric tube (OGT), not an NGT

## **Disability**

### **What are the goals in assessing disability?**

Determination of neurologic injury (Think: neurologic disability)

## **What comprises adequate assessment of disability?**

Mental status—Glasgow Coma Scale (GCS)

Pupils—a blown pupil suggests ipsilateral brain mass (blood) as herniation of the brain compresses CN III

Motor/sensory—screening exam for lateralizing extremity movement, sensory deficits

## **Describe the GCS scoring system**

### **Eye opening (E)**

(Think: Verbal = “Jackson 5”)

4—Opens spontaneously

3—Opens to voice (command)

2—Opens to painful stimulus

1—Does not open eyes

(Think: Eyes = “four eyes”)

### **Motor response (M)**

6—Obeys commands

5—Localizes painful stimulus

4—Withdraws from pain

3—Decorticate posture

2—Decerebrate posture

1—No movement

(Think: Motor = “6-cylinder motor”)

### **Verbal response (V)**

5—Appropriate and oriented

4—Confused

3—Inappropriate words

2—Incomprehensible sounds

1—No sounds

## **What is a normal human GCS?**

GCS 15

## **What is the GCS score for a dead man?**

GCS 3

## **What is the GCS score for a patient in a “coma”?**

GCS  $\leq 8$

### **GCS indication for intubation?**

$\leq 8$

### **How does scoring differ if the patient is intubated?**

Verbal evaluation is omitted and replaced with a “T”; thus, the highest score for an intubated patient is 11 T

## **■ Exposure and Environment**

### **What are the goals in obtaining adequate exposure?**

Complete disrobing to allow a thorough visual inspection and digital palpation of the patient during the secondary survey

### **What is the “environment” of the E in ABCDEs?**

Keep a warm environment (i.e., keep the patient warm; a hypothermic patient can become coagulopathic)

## **SECONDARY SURVEY**

### **What principle is followed in completing the secondary survey?**

Complete physical exam, including all orifices: ears, nose, mouth, vagina, rectum

### **Why look in the ears?**

Hemotympanum is a sign of basilar skull fracture; otorrhea is a sign of basilar skull fracture

### **Examination of what part of the trauma patient’s body is often forgotten?**

Patient’s back (logroll the patient and examine!)

### **What are typical signs of basilar skull fracture?**

Raccoon eyes, Battle’s sign, clear otorrhea or rhinorrhea, hemotympanum

**What diagnosis in the anterior chamber must not be missed on the eye exam?**

Traumatic hyphema = blood in the anterior chamber of the eye

**What potentially destructive lesion must not be missed on the nasal exam?**

Nasal septal hematoma: Hematoma must be evacuated; if not, it can result in pressure necrosis of the septum!

**What is the best indication of a mandibular fracture?**

Dental malocclusion: Tell the patient to “bite down” and ask, “Does that feel normal to you?”

**What signs of thoracic trauma are often found on the neck exam?**

Crepitus or subcutaneous emphysema from tracheobronchial disruption/PTX; tracheal deviation from tension pneumothorax; JVD from cardiac tamponade; carotid bruit heard with seatbelt neck injury resulting in carotid artery injury

**What is the best physical exam for broken ribs or sternum?**

Lateral and anterior–posterior compression of the thorax to elicit pain/instability

**What physical signs are diagnostic for thoracic great vessel injury?**

None: Diagnosis of great vessel injury requires a high index of suspicion based on the mechanism of injury, associated injuries, and CXR/radiographic findings (e.g., widened mediastinum)

**What is the best way to diagnose or rule out aortic injury?**

CT angiogram (CTA)

**What must be considered in every penetrating injury of the thorax at or below the level of the nipple?**

Concomitant injury to the abdomen (Remember, the diaphragm extends to the level of the nipples in the male on full expiration)

**What is the significance of subcutaneous air?**

Indicates PTX, until proven otherwise

**What is the physical exam technique for examining the thoracic and**

**lumbar spine?**

Logrolling the patient to allow complete visualization of the back and palpation of the spine to elicit pain over fractures, step off (spine deformity)

**What conditions must exist to pronounce an abdominal physical exam negative?**

Alert patient without any evidence of head/spinal cord injury or drug/EtOH intoxication (even then, the abdominal exam is not 100% accurate)

**What physical signs may indicate intra-abdominal injury?**

Tenderness; guarding; peritoneal signs; progressive distention (always use a gastric tube for decompression of air); seatbelt sign

**What is the seatbelt sign?**

Ecchymosis on lower abdomen from wearing a seatbelt ( $\approx 10\%$  of patients with this sign have a small bowel perforation!)

**What must be documented from the rectal exam?**

Sphincter tone (as an indication of spinal cord function); presence of blood (as an indication of colon or rectal injury); prostate position (as an indication of urethral injury)

**What is the best physical exam technique to test for pelvic fractures?**

Lateral compression of the iliac crests and greater trochanters and anterior-posterior compression of the symphysis pubis to elicit pain/instability

**What is the “halo” sign?**

Cerebrospinal fluid from nose/ear will form a clear “halo” around the blood on a cloth

**What physical signs indicate possible urethral injury, thus contraindicating placement of a Foley catheter?**

**High-riding, ballotable prostate** on rectal exam; presence of blood at the meatus; scrotal or perineal ecchymosis

**What must be documented from the extremity exam?**

Any fractures or joint injuries; any open wounds; motor and sensory exam,

particularly distal to any fractures; distal pulses; peripheral perfusion

**What complication after prolonged ischemia to the lower extremity must be treated immediately?**

Compartment syndrome

**What is the treatment for this condition?**

Fasciotomy (four compartments below the knee)

**What injuries must be suspected in a trauma patient with a progressive decline in mental status?**

Epidural hematoma, subdural hematoma, brain swelling with rising intracranial pressure (ICP). But **hypoxia/hypotension must be ruled out!**

## TRAUMA STUDIES

**What are the classic blunt trauma ER x-rays?**

- . AP (anterior–posterior) chest film
- . AP pelvis film

**What are the common trauma labs?**

Blood for complete blood count, chemistries, amylase, liver function tests (LFTs), lactic acid, coagulation studies, and **type and crossmatch**; urine for urinalysis

**How can a C-spine be evaluated?**

- . Clinically by physical exam
- . Radiographically

**What patients can have their C-spines cleared by a physical exam?**

No neck pain on palpation with full range of motion (FROM) with no neurologic injury (GCS 15), no EtOH/drugs, no distracting injury, no pain meds

**How do you rule out a C-spine bony fracture?**

With a CT scan of the C-spine

**What do you do if no bony C-spine fracture is apparent on CT scan**

**and you cannot obtain an MRI in a COMATOSE patient?**

This is controversial, but most centers remove the c-collar

**Which x-rays are used for evaluation of cervical spine**

**LIGAMENTOUS injury?**

MRI (lateral flexion and extension C-spine films also used but infrequently)

**What study is used to rule out thoracic aortic injury?**

CT scan of mediastinum looking for mediastinal hematoma with CTA

**What is the most common site of thoracic aortic traumatic tear?**

Just distal to the take-off of the left subclavian artery

**What studies are available to evaluate for intra-abdominal injury?**

FAST, CT scan, DPL

**What is a FAST exam?**

Ultrasound: **F**ocused **A**ssessment with **S**onography for **T**rauma = **FAST**

**What does the FAST exam look for?**

Blood in the peritoneal cavity looking at Morison's pouch, bladder, spleen, and pericardial sac

**What does DPL stand for?**

**D**iagnostic **P**eritoneal **L**avage

**What diagnostic test is the test of choice for evaluation of the unstable patient with blunt abdominal trauma?**

FAST

**What is the indication for abdominal CT scan in blunt trauma?**

Normal vital signs with abdominal pain/tenderness/mechanism

**What is the indication for FAST in blunt trauma?**

Unstable vital signs (hypotension)

**What injuries does CT scan miss?**

Small bowel injuries and diaphragm injuries

**What study is used to evaluate the urethra in cases of possible disruption due to blunt trauma?**

Retrograde UrethroGram (RUG)

**What are the most emergent orthopedic injuries?**

- . Hip dislocation—must be reduced immediately
- . Exsanguinating pelvic fracture (binder or external fixator)

**What is the treatment of a gunshot wound to the belly?**

Exploratory laparotomy

**What is the evaluation of a stab wound to the belly?**

If there are peritoneal signs, heavy bleeding, shock, perform exploratory laparotomy; otherwise, many surgeons perform a CT scan and/or observe

## PENETRATING NECK INJURIES

**What depth of neck injury must be further evaluated?**

Penetrating injury through the platysma

**Define the anatomy of the neck by trauma zones:**

### **Zone III**

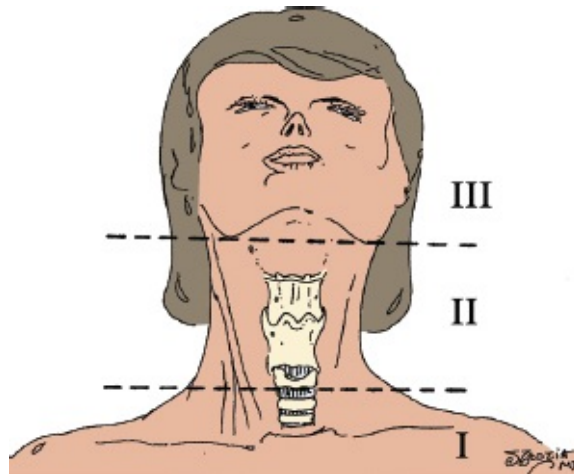
Angle of the mandible and up

### **Zone II**

Angle of the mandible to the cricoid cartilage

### **Zone I**

Below the cricoid cartilage



**How do most surgeons treat penetrating neck injuries (those that penetrate the platysma) by neck zone:**

**Zone III**

Selective exploration

**Zone II**

Surgical exploration versus selective exploration

**Zone I**

Selective exploration

**What is selective exploration?**

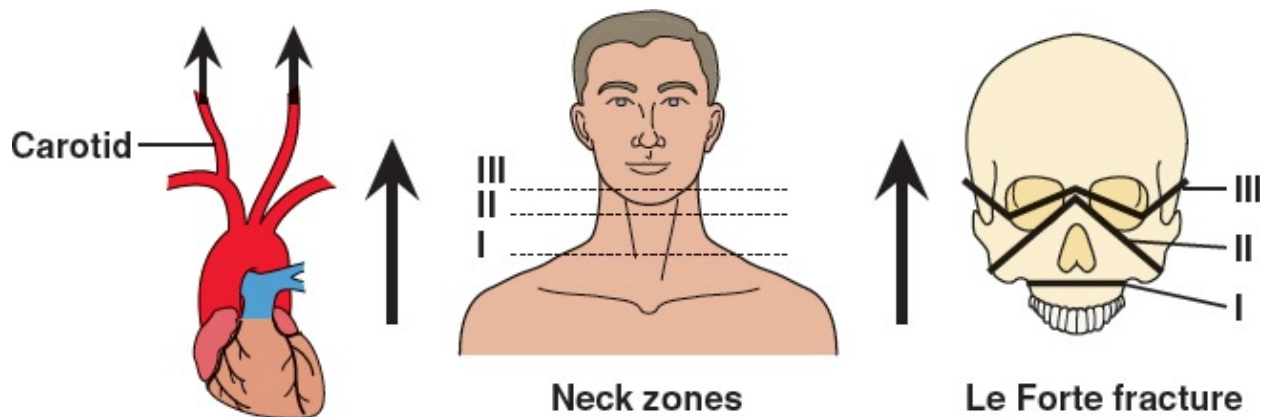
Selective exploration is based on diagnostic studies that include A-gram or CT A-gram, bronchoscopy, esophagoscopy

**What are the indications for surgical exploration in all penetrating neck wounds (zones I, II, III)?**

“**Hard** signs” of significant neck damage: **shock**, exsanguinating hemorrhage, expanding hematoma, pulsatile hematoma, neurologic injury, subQ emphysema

**How can you remember the order of the neck trauma zones and Le Forte fractures?**

In the direction of carotid blood flow



## MISCELLANEOUS TRAUMA FACTS

**What is the minimal urine output for an adult trauma patient?**

50 mL/hr

**How much blood can be lost into the thigh with a closed femur fracture?**

Up to 1.5 L of blood

**Can an adult lose enough blood in the “closed” skull from a brain injury to cause hypovolemic shock?**

Absolutely not! But infants can lose enough blood from a brain injury to cause shock

**Can a patient be hypotensive after an isolated head injury?**

Yes, but rule out hemorrhagic shock!

**What is the brief ATLS history?**

“AMPLE” history:

Allergies

Medications

PMH

Last meal (when)

Events (of injury, etc.)

**In what population is a surgical cricothyroidotomy not recommended?**

Any patient age <12 years; instead perform needle cricothyroidotomy

**What are the signs of a laryngeal fracture?**

Subcutaneous emphysema in neck

Altered voice

Palpable laryngeal fracture

**What is the treatment of rectal penetrating injury?**

**Diverting proximal colostomy**; closure of perforation (if easy, and definitely if intraperitoneal); and presacral drainage

**What is the treatment of EXTRAperitoneal minor bladder rupture?**

“Bladder catheter” (Foley) drainage and observation; intraperitoneal or large bladder rupture requires operative closure

**What intra-abdominal injury is associated with seatbelt use?**

Small bowel injuries (L2 fracture, pancreatic injury)

**What is the treatment of a pelvic fracture?**

± pelvic binder until the external fixator is placed; IVF/blood; ± A-gram to embolize bleeding pelvic vessels

**Bleeding from pelvic fractures is most commonly caused by arterial or venous bleeding?**

Venous (≈85%)

**If a patient has a laceration through an eyebrow, should you shave the eyebrow prior to suturing it closed?**

No—20% of the time, the eyebrow will not grow back if shaved!

**What is the treatment of extensive irreparable biliary, duodenal, and pancreatic head injury?**

Trauma Whipple

**What is the most common intra-abdominal organ injured with penetrating trauma?**

Small bowel

**How high up do the diaphragms go?**

To the nipples (intercostal space #4); thus, intra-abdominal injury with penetrating injury below the nipples must be ruled out

**Classic trauma question: “If you have only one vial of blood from a trauma victim to send to the lab, what test should be ordered?”**

Type and cross (for blood transfusion)

**What is the treatment of penetrating injury to the colon?**

If the patient is in shock, resection and colostomy

If the patient is stable, the trend is primary anastomosis/repair

**What is the treatment of small bowel injury?**

Primary closure or resection and primary anastomosis

**What is the treatment of minor pancreatic injury?**

Drainage (e.g., JP drains)

**What is the most commonly injured abdominal organ with blunt trauma?**

Liver (in recent studies)

**What is the treatment for significant duodenal injury?**

Pyloric exclusion:

1. Close duodenal injury
2. Staple off pylorus
3. Gastrojejunostomy

**What is the treatment for massive tail of pancreas injury?**

Distal pancreatectomy (usually perform splenectomy also)

**What is “damage control” surgery?**

Stop major hemorrhage and GI soilage

Pack and get out of the O.R. ASAP to bring the patient to the ICU to warm, correct coags, and resuscitate

Return patient to O.R. when stable, warm, and not acidotic

**What is the “lethal triad”?**

“ACH”:

1. **A**cidosis
2. **C**oagulopathy
3. **H**ypothermia

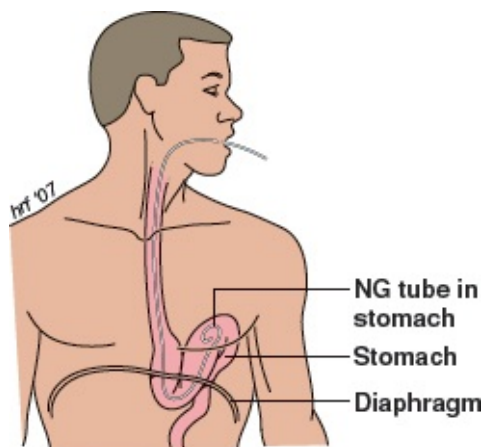
(Think: **ACH**e = **A**cidosis, **C**oagulopathy, **H**ypothermia)

**What comprises the workup/treatment of a stable parasternal chest gunshot/stab wound?**

- . CXR
- . FAST, chest tube, ± O.R. for subxiphoid window; if blood returns, then sternotomy to assess for cardiac injury

**What is the diagnosis with NGT in chest on CXR?**

Ruptured diaphragm with stomach in pleural cavity (go to ex lap)

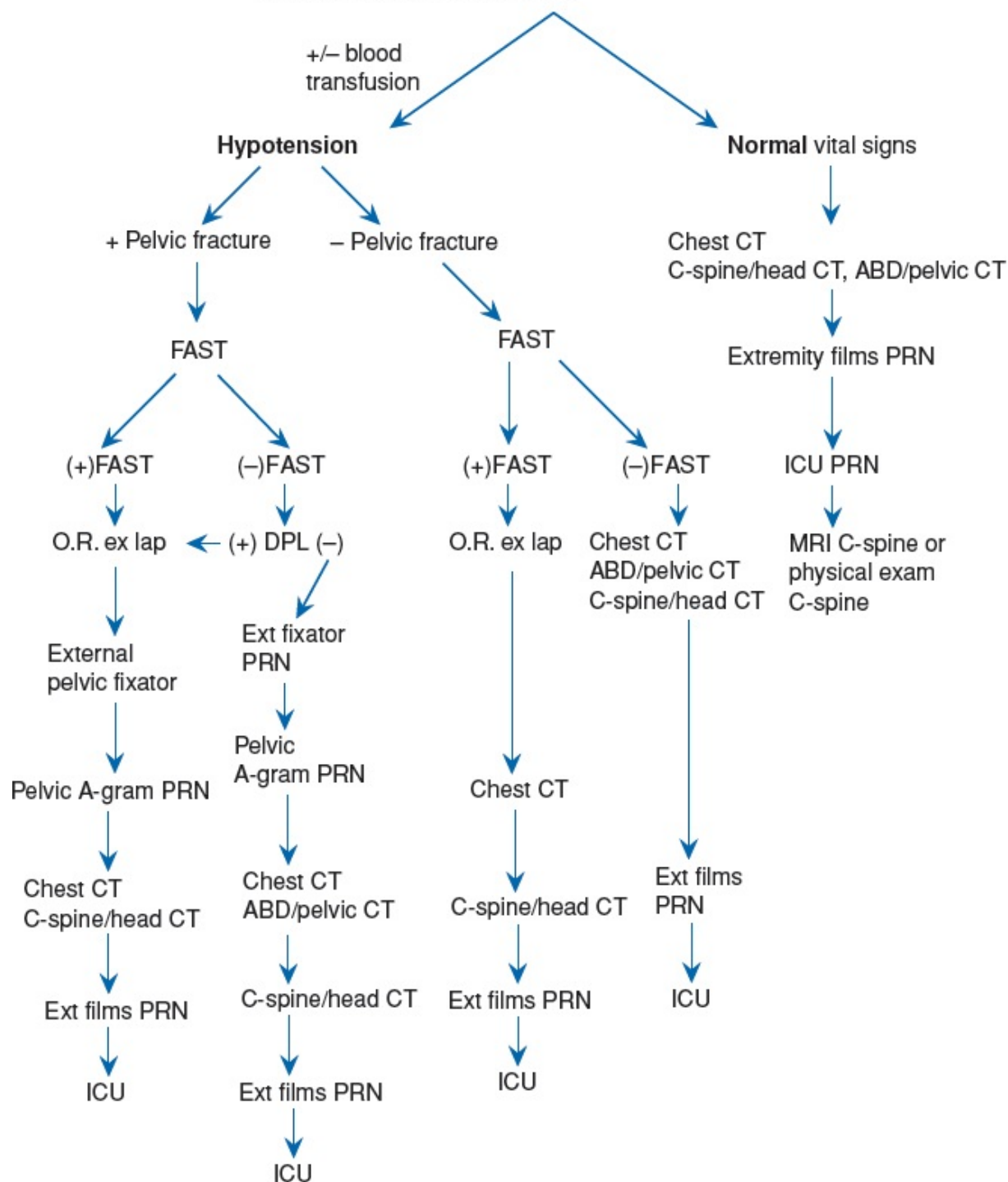


**What films are typically obtained to evaluate extremity fractures?**

Complete views of the involved extremity, including the joints above and below the fracture

# Outline basic workup for a victim of severe blunt trauma

In ER: Airway, physical exam. IV X 2, labs, type and cross,  
OGT/NGT, Foley, chest tube PRN  
X-rays: CXR, pelvic, femur  
(if femur fracture is suspected)



[Note: AP = anteroposterior; Ext = extremity; OGT = orogastric tube;  
FAST = Focused Assessment Sonogram for Trauma; lat = lateral; C = cervical.]

**What finding on ABD/pelvic CT scan requires ex lap in the blunt trauma patient with normal vital signs?**

Free air; also strongly consider in the patient with no solid organ injury but lots of free fluid = both to rule out hollow viscus injury

**Can you rely on a negative FAST in the unstable patient with a pelvic fracture?**

No—perform DPL (above umbilicus)

**Which lab tests are used to look for intra-abdominal injury in children?**

LFTs =  $\uparrow$  AST/ALT

**What is the treatment for human and dog bites?**

Leave wound open, irrigation, antibiotics

**What percentage of pelvic fracture bleeding is exclusively venous?**

85%

**What is sympathetic ophthalmia?**

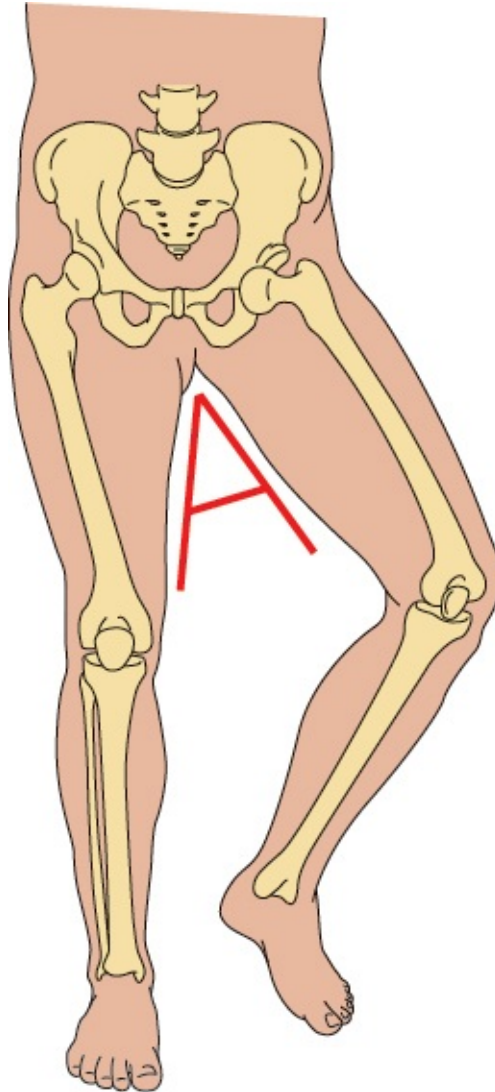
Blindness in one eye that results in subsequent blindness in the contralateral eye (autoimmune)

**What can present after blunt trauma with neurologic deficits and a normal brain CT scan?**

Diffuse Axonal Injury (DAI), carotid artery injury

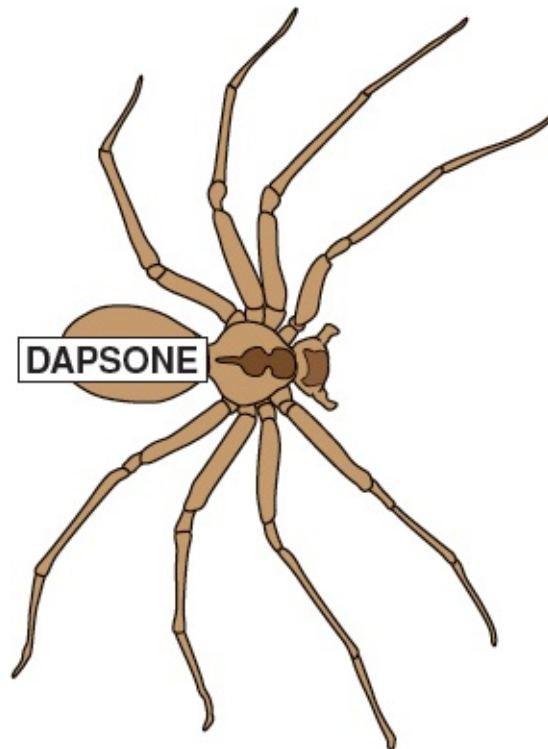
**What is the usual presentation of an anterior hip dislocation?**

Externally rotated with anterior hip fullness (Think: **A** for **A**nterior)



**What drug is used to treat a brown recluse spider bite?**

Dapsone



## RAPID FIRE REVIEW

**What is the correct diagnosis?**

**Coiled NGT in the left pleural cavity after blunt trauma**

Diaphragm rupture

**Blunt trauma patient with GCS <8 and otorrhea**

Basilar fracture

**20-year-old male s/p baseball bat to his head, arrives in a coma; CT scan reveals a lens shaped (lenticular) hematoma next to inner table of skull**

Epidural hematoma

**44-year-old male s/p fall from a ladder presents with GCS of 5; CT scan reveals a crescent-shaped hematoma next to inner table of the skull**

Subdural hematoma

**Trauma patient with increasing JVD with inspiration**

Cardiac tamponade (Kussmaul's sign)

**Trauma patient with hypertension and bradycardia**

Cushing's response to increased ICP

**Trauma patient with hypotension and bradycardia**

Spinal cord injury

**Name the most likely diagnosis:**

**28-year-old woman involved in a high-speed, side-impact motor vehicle collision (MVC); stable vital signs; CXR reveals widened mediastinum**

Thoracic aortic injury

**21-year-old man involved in high-speed MVC with obvious unstable pelvis, gross blood from the urethral meatus, high-riding prostate on rectal exam**

Urethral injury

**45-year-old woman involved in high-speed MVC complains of abdominal pain and shortness of breath; decreased breath sounds on the left; CXR reveals the NGT coiled up in the left chest**

Ruptured left diaphragm

**56-year-old involved in a high-speed motorcycle collision complains of severe shortness of breath; on exam, the left chest wall moves inwards not outwards on inhalation**

Flail chest—"paradoxical respirations"

**67-year-old involved in a high-speed MVC presents with a GCS of 5, bilateral periorbital ecchymosis, left mastoid ecchymosis, and clear fluid draining from the left ear**

Basilar skull fracture—Battle's and raccoon signs

**50-year-old female s/p high speed MVC with rib fractures and flail chest develops hypoxia 12 hours later in the ICU; CXR shows no**

**pneumo- or hemothorax but reveals pulmonary infiltrates/congestion**

Pulmonary contusion

**29-year-old s/p MVC arrives with hypotension, sats of 83%, JVD, decreased breath sounds on left**

Tension pneumothorax

**55-year-old male s/p 3-story fall reveals the NGT coiled up in chest on CXR**

Diaphragm injury

**22-year-old man s/p MVC with transection of right optic nerve; progresses to blindness in the contralateral left eye 3 weeks later**

Sympathetic ophthalmia

**8-year-old male s/p bicycle accident with handle bar to abdomen with duodenal hematoma**

NGT, TPN, and observe; may take weeks to open up

**30-year-old male involved in a skiing collision with a tree, arrives in the ER awake (GCS of 15) but then gets confused and next goes unresponsive (GCS of 3)**

“Lucid interval” of an epidural hematoma

**Name the diagnostic modality:**

**47-year-old female s/p MVC with a seatbelt sign (ecchymosis) on the left neck**

CTA of cervical vessels

**22-year-old male s/p gunshot wound to umbilicus; bullet is in the spine on x-rays**

Exploratory laparotomy

# Chapter 38 Burns

## Define:

### **TBSA**

Total Body Surface Area

### **STSG**

Split-Thickness Skin Graft

## **Are acid or alkali chemical burns more serious?**

In general, **ALKALI** burns are more serious because the body cannot buffer the alkali, thus allowing them to burn for much longer

## **How is myoglobinuria treated?**

To avoid renal injury, think “**HAM**”:

**H**ydration with IV fluids

**A**lkalization of urine with IV bicarbonate

**M**annitol diuresis

## **Define level of burn injury:**

### **Superficial (previously known as first-degree) burns**

Epidermis only

### **Partial-thickness (previously known as second-degree) burns**

Epidermis and varying levels of dermis

### **Full-thickness (previously known as third-degree) burns**

All layers of the skin including the entire dermis

## **How do superficial burns present?**

Painful, dry, red areas that do not form blisters (think of sunburn)

### **How do partial-thickness burns present?**

Painful, hypersensitive, swollen, mottled areas with **blisters** and open weeping surfaces

### **How do full-thickness burns present?**

Painless, insensate, swollen, dry, mottled white, and charred areas; often described as dried leather

### **What is the major clinical difference between partial- and full-thickness burns?**

Full-thickness burns are painless, and partial-thickness burns are painful

### **By which measure is burn severity determined?**

Depth of burn and TBSA affected by partial- and full-thickness burns

TBSA is calculated by the “rule of nines” in adults and by a modified rule in children to account for the disproportionate size of the head and trunk

### **What is the “rule of nines”?**

In an adult, the total body surface area that is burned can be estimated by the following:

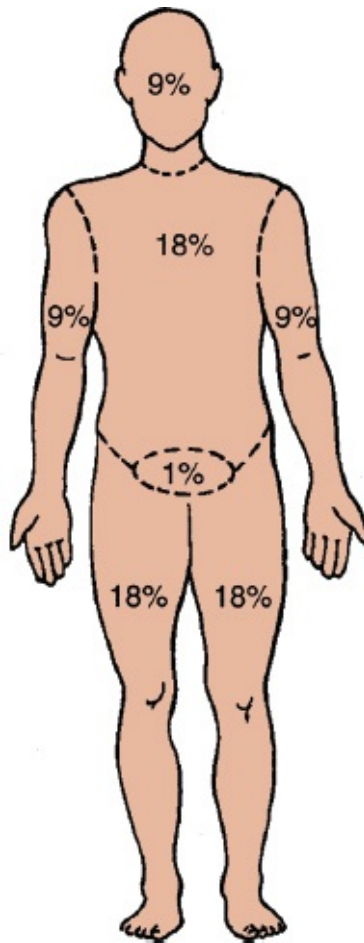
Each upper limb = 9%

Each lower limb = 18%

Anterior and posterior trunk = 18% each

Head and neck = 9%

Perineum and genitalia = 1%



### **What is the “rule of the palm”?**

Surface area of the patient’s palm is  $\approx 1\%$  of the TBSA used for estimating size of small burns

### **What is the burn center referral criteria for the following?**

#### **Partial-thickness burns**

>20% TBSA

#### **Full-thickness burns**

>5% TBSA

Partial thickness >10% TBSA in children and the elderly

Any burns involving the face, hands, feet, or perineum

Any burns with inhalation injury

Any burns with associated trauma

Any electrical burns

**What is the treatment of superficial burns?**

Keep clean, ± Neosporin®, pain meds

**What is the treatment of partial-thickness burns?**

Remove blisters; apply antibiotic ointment (usually Silvadene®) and dressing; pain meds; some use silver bandages

Most partial-thickness burns do not require skin grafting (epidermis grows from hair follicles and from margins)

**What is the treatment of full-thickness burns?**

Early excision of eschar (within first week postburn) and STSG

**How can you decrease bleeding during excision?**

Tourniquets as possible, topical epinephrine, topical thrombin

**What is an autograft STSG?**

STSG from the patient's own skin

**What is an allograft STSG?**

STSG from a cadaver (temporary coverage)

**What thickness is the STSG?**

10/1000 to 15/1000 of an inch (down to the dermal layer)

**What prophylaxis should the burn patient get in the ER?**

Tetanus

**What is used to evaluate the eyes after a full-thickness burn?**

Fluorescein

**What principles guide the initial assessment and resuscitation of the burn patient?**

ABCDEs, then urine output; check for eschar and compartment syndromes

**What are the signs of smoke inhalation?**

Smoke and soot in sputum/mouth/nose, nasal/facial hair burns, throat/mouth erythema, history of loss of consciousness/explosion/fire in small enclosed area, dyspnea, low O<sub>2</sub> saturation, confusion, headache, coma

## **What diagnostic imaging is used for smoke inhalation?**

Bronchoscopy

## **What lab value assesses smoke inhalation?**

**Carboxyhemoglobin** level (carboxyhemoglobin level >60% is associated with a 50% mortality); treat with 100% O<sub>2</sub> and time

## **How should the airway be managed in the burn patient with an inhalational injury?**

With a low threshold for **intubation**; oropharyngeal swelling may occlude the airway so that intubation is impossible; 100% oxygen should be administered immediately and continued until significant carboxyhemoglobin is ruled out

## **What is “burn shock”?**

**Burn shock** describes the loss of fluid from the intravascular space as a result of burn injury, which causes “leaking capillaries” that require crystalloid infusion

## **What is the “Parkland formula”?**

$V = \text{TBSA Burn (\%)} \times \text{Weight (kg)} \times 4$

Formula widely used to estimate the volume (V) of crystalloid necessary for the initial resuscitation of the burn patient; half of the calculated volume is given in the **first 8 hours**, the rest in the next 16 hours

## **What burns qualify for the Parkland formula?**

≥20% TBSA partial- and full-thickness burns only

## **What is the Brooke formula for burn resuscitation?**

Replace 2 cc for the 4 cc in the Parkland formula

## **What is the rule of 10’s?**

For determining hourly IVF rate:  $\text{TBSA} \times 10$  (patients 40 to 80 kg)

## **How is the crystalloid given?**

Through two large-bore peripheral venous catheters

## **Can you place an IV or central line through burned skin?**

YES

**What is the adult urine output goal?**

30 to 50 cc (titrate IVF)

**Why is glucose-containing IVF contraindicated in burn patients in the first 24 hours postburn?**

Patient's serum glucose will be elevated on its own because of the stress response

**What fluid is used after the first 24 hours postburn?**

Colloid; use D5W **and** 5% albumin at 0.5 cc/kg/% burn surface area

**Why should D5W IV be administered after 24 hours postburn?**

Because of the massive sodium load in the first 24 hours of LR infusion and because of the massive evaporation of H<sub>2</sub>O from the burn injury, the patient will need free water; after 24 hours, the capillaries begin to work and then the patient can usually benefit from **albumin** and D5W

**What is the minimal urine output for burn patients?**

Adults 30 cc; children 1 to 2 cc/kg/hr

**What is most important for volume status monitoring in the burn patient?**

Urine output

**Why do most severely burned patients require nasogastric decompression?**

Patients with >20% TBSA burns usually develop a paralytic ileus → vomiting  
→ aspiration risk → pneumonia

**What stress prophylaxis must be given to the burn patient?**

PPI to prevent burn stress ulcer (Curling's ulcer)

**What are the signs of burn wound infection?**

Increased WBC with left shift, **discoloration of burn eschar** (most common sign), green pigment, necrotic skin lesion in unburned skin, edema, ecchymosis tissue below eschar, partial-thickness burns that turn into full-thickness burns, hypotension

**Is fever a good sign of infection in burn patients?**

NO

**What are the common organisms found in burn wound infections?**

*Staphylococcus aureus*, *Pseudomonas*, *Streptococcus*, *Candida albicans*

**How is a burn wound infection diagnosed?**

Send burned tissue in question to the laboratory for quantitative burn wound bacterial count; if the count is  $>10^5$ /gram, infection is present and IV antibiotics should be administered

**Why are systemic IV antibiotics contraindicated in fresh burns?**

Bacteria live in the eschar, which is avascular (the systemic antibiotic will not be delivered to the eschar); thus, apply topical antimicrobial agents

**Note some advantages and disadvantages of the following topical antibiotic agents:**

**Silver sulfadiazine (Silvadene®)**

Painless, but little eschar penetration, misses *Pseudomonas*, and has idiosyncratic **neutropenia**; sulfa allergy is a contraindication

**Mafenide acetate (Sulfamylon®)**

Penetrates eschars, broad spectrum (but misses *Staphylococcus*), causes pain on application; triggers allergic reaction in 7% of patients; may cause **acid-base imbalances** (Think: **M**afenide **AC**etate = **M**etabolic **AC**idosis); agent of choice for ear burns

**Polysporin®**

Polymyxin B sulfate; painless, clear, used for facial burns; does not have a wide antimicrobial spectrum

**Are prophylactic systemic antibiotics administered to burn patients?**

No—prophylactic antibiotics have not been shown to reduce the incidence of sepsis, but rather have been shown to select for resistant organisms; IV antibiotics are reserved for established wound infections, pneumonia, urinary

tract infections, etc.

**Circumferential, full-thickness burns to the extremities are at risk for what complication?**

Distal neurovascular impairment

**How is it treated?**

Escharotomy: full-thickness longitudinal incision through the eschar with scalpel or electrocautery

**Is tetanus prophylaxis required in the burn patient?**

Yes, it is mandatory in all patients except those actively immunized within the past 12 months (with incomplete immunization: toxoid  $\times$  3)

**Can infection convert a partial-thickness injury into a full-thickness injury?**

Yes!

**How is carbon monoxide inhalation overdose treated?**

100% O<sub>2</sub> ( $\pm$  hyperbaric O<sub>2</sub>)

**Which electrolyte must be closely followed acutely after a burn?**

Na<sup>+</sup> (sodium)

**What is the name of the gastric/duodenal ulcer associated with burn injury?**

Curling's ulcer (Think: **CURLING** iron burn = **CURLING**'s burn ulcer)

**How are STSGs nourished in the first 24 hours?**

IMBIBITION (fed from wound bed exudate)

## **RAPID FIRE REVIEW**

**What is the treatment?**

**30-year-old female involved in a house fire with circumferential**

**burns to both upper extremities with no palpable distal pulses**

Escharotomies (cut burn scar releasing tourniquet effect)

**55-year-old female s/p house fire with elevated  
carboxyhemoglobin**

100% oxygen

# Chapter 39 Upper GI Bleeding

## **What is it?**

Bleeding into the lumen of the proximal GI tract, proximal to the ligament of Treitz

## **What are the signs/symptoms?**

Hematemesis, melena, syncope, shock, fatigue, coffee-ground emesis, hematochezia, epigastric discomfort, epigastric tenderness, signs of hypovolemia, guaiac-positive stools

## **Why is it possible to have hematochezia?**

Blood is a cathartic, and hematochezia usually indicates a vigorous rate of bleeding from the UGI source

## **Are stools melenic or melanotic?**

Melenic (melanotic is incorrect)

## **What is the most common cause of significant UGI bleeding?**

PUD—duodenal and gastric ulcers (50%)

## **What is the *common* differential diagnosis of UGI bleeding?**

- . Acute gastritis
- . Duodenal ulcer
- . Esophageal varices
- . Gastric ulcer
- . Esophageal
- . Mallory–Weiss tear

## **What is the diagnostic test of choice with UGI bleeding?**

EGD (>95% diagnosis rate)

## **What are the treatment options with the endoscope during an EGD?**

Coagulation, injection of epinephrine (for vasoconstriction), injection of sclerosing agents (varices), variceal ligation (banding)

### **Which lab tests should be performed?**

Chem-7, bilirubin, LFTs, CBC, **type and cross**, PT/PTT, amylase

### **Why is BUN elevated?**

Because of absorption of blood by the GI tract

### **What is the initial treatment?**

- . **IVFs** (16 G or larger peripheral IVS × 2), **Foley** catheter (monitor fluid status)
- . **NGT** suction (determine rate and amount of blood)
- . Water lavage (use warm H<sup>2</sup>O—will remove clots)
- . **EGD**: endoscopy (determine etiology/location of bleeding and possible treatment—coagulate bleeders)

### **Why irrigate in an upper GI (UGI) bleed?**

To remove the blood clot so you can see the mucosa

### **What test may help identify the site of MASSIVE UGI bleeding when EGD fails to diagnose cause and blood continues per NGT?**

Selective mesenteric angiography

### **What are the indications for surgical intervention in UGI bleeding?**

Refractory or recurrent bleeding and site known, >3 unit PRBCs to stabilize or >6 unit PRBCs overall

### **What percentage of patients require surgery?**

≈10%

### **What percentage of patients spontaneously stop bleeding?**

≈80% to 85%

### **What is the mortality of acute UGI bleeding?**

Overall 10%, age 60 to 80 years 15%, age >80 years 25%

### **What are the risk factors for death following UGI bleed?**

Age >60 years

Shock  
>5 units of PRBC transfusion  
Concomitant health problems

## PEPTIC ULCER DISEASE (PUD)

### What is it?

Gastric and duodenal ulcers

### What is the incidence in the United States?

≈10% of the population will suffer from PUD during their lifetime!

### What are the possible consequences of PUD?

Pain, hemorrhage, perforation, obstruction

### What percentage of patients with PUD develops bleeding from the ulcer?

≈20%

### Which bacteria are associated with PUD?

*Helicobacter pylori*

### What is the treatment for *H. pylori*?

Treat *H. pylori* with MOC or ACO 2-week antibiotic regimens:

**MOC:** Metronidazole, Omeprazole, Clarithromycin (Think: **MOCK**)

or

**ACO:** Ampicillin, Clarithromycin, Omeprazole

### What is the name of the sign with RLQ pain/peritonitis as a result of succus collecting from a perforated peptic ulcer?

Valentino's sign

## DUODENAL ULCERS

### In which age group are these ulcers most common?

40 to 65 years of age (younger than patients with gastric ulcer)

**What is the ratio of male to female patients?**

Men > women (3:1)

**What is the most common location?**

Most are within 2 cm of the pylorus in the duodenal bulb

**What is the classic pain response to food intake?**

Food classically relieves duodenal ulcer pain (Think: Duodenum = **D**ecreased with food)

**What is the cause?**

Increased production of gastric acid

**What syndrome must you always think of with a duodenal ulcer?**

Zollinger–Ellison syndrome (ZES)

**What are the major symptoms?**

Epigastric pain

Bleeding

**What are the signs?**

Tenderness in epigastric area (possibly), guaiac-positive stool, melena, hematochezia, hematemesis

**What is the differential diagnosis?**

Acute abdomen, pancreatitis, cholecystitis, **all causes of UGI bleeding**, ZES, gastritis, MI, gastric ulcer, reflux

**How is the diagnosis made?**

History, PE, EGD, UGI series (**if patient is not actively bleeding**)

**When is surgery indicated with a bleeding duodenal ulcer?**

Most surgeons use: >6 unit PRBC transfusions, >3 unit PRBCs needed to stabilize, or for significant rebleed

**What is the medical treatment?**

Proton-pump inhibitors (PPIs) or H<sub>2</sub> receptor antagonists—heals ulcers in 4 to 6 weeks in most cases

Treatment for *H. pylori*

### **When is surgery indicated?**

The acronym “**I HOP**”:

**I**ntractability

**H**emorrhage (massive or relentless)

**O**bstuction (gastric outlet obstruction)

**P**erforation

### **How is a bleeding duodenal ulcer surgically corrected?**

Opening of the duodenum through the pylorus

Oversewing of the bleeding vessel

### **What artery is involved with bleeding duodenal ulcers?**

Gastroduodenal artery

### **What are the common surgical options for the following conditions:**

#### **Truncal vagotomy?**

Pyloroplasty

#### **Duodenal perforation?**

Graham patch (poor candidates, shock, prolonged perforation)

Truncal vagotomy and pyloroplasty incorporating ulcer

Graham patch and highly selective vagotomy

Truncal vagotomy and antrectomy (higher mortality rate, but lowest recurrence rate)

#### **Duodenal ulcer intractability?**

PGV (highly selective vagotomy)

Vagotomy and pyloroplasty

## **GASTRIC ULCERS**

### **In which age group are these ulcers most common?**

40 to 70 years old (older than the duodenal ulcer population)

Rare in patients age <40 years

### **How does the incidence in men compare with that of women?**

Men > women

### **Which is more common overall: gastric or duodenal ulcers?**

Duodenal ulcers are more than twice as common as gastric ulcers (Think: Duodenal = Double rate)

### **What is the classic pain response to food?**

Food classically increases gastric ulcer pain

### **What is the cause?**

**Decreased cytoprotection** or gastric protection (i.e., decreased bicarbonate/mucous production)

### **Is gastric acid production high or low?**

Gastric acid production is normal or low!

### **What are the associated risk factors?**

Smoking, alcohol, burns, trauma, CNS tumor/trauma, NSAIDs, steroids, shock, severe illness, male gender, advanced age

### **What are the symptoms?**

Epigastric pain  
± Vomiting, anorexia, and nausea

### **How is the diagnosis made?**

History, PE, EGD with multiple biopsies (looking for gastric cancer)

### **What is the most common location?**

≈70% are on the lesser curvature; 5% are on the greater curvature

### **When and why should biopsy be performed?**

With all gastric ulcers, to rule out gastric cancer  
If the ulcer does not heal in 6 weeks after medical treatment, **rebiopsy** (always biopsy in O.R. also) must be performed

### **What is the medical treatment?**

Similar to that of duodenal ulcer—PPIs or H<sub>2</sub> blockers, *H. pylori* treatment

## **When do patients with gastric ulcers need to have an EGD?**

- . For diagnosis with biopsies
- . 6 weeks postdiagnosis to confirm healing and rule out gastric cancer!

## **What are the indications for surgery?**

The acronym **“I CHOP”**:

Intractability

Cancer (rule out)

Hemorrhage (massive or relentless)

Obstruction (gastric outlet obstruction)

Perforation

(**Note:** Surgery is indicated if gastric cancer cannot be ruled out)

## **What is the common operation for hemorrhage, obstruction, and perforation?**

Distal gastrectomy with excision of the ulcer **without** vagotomy unless there is duodenal disease (i.e., BI or BII)

## **What is a common option for a poor operative candidate with a perforated gastric ulcer?**

Graham patch

## **What must be performed in every operation for gastric ulcers?**

Biopsy looking for gastric cancer

# **PERFORATED PEPTIC ULCER**

## **What are the symptoms?**

**Acute** onset of upper abdominal pain

## **What is the differential diagnosis?**

Acute pancreatitis, acute cholecystitis, perforated acute appendicitis, colonic diverticulitis, MI, any perforated viscus

## **Which diagnostic tests are indicated?**

X-ray: free air under diaphragm or in lesser sac in an upright CXR

**What is the initial treatment?**

NPO: NGT (↓ contamination of the peritoneal cavity)

IVF/Foley catheter

Antibiotics/PPIs

Surgery

**What is a Graham patch?**

Piece of omentum incorporated into the suture closure of perforation

**What type of perforated ulcer may present just like acute pancreatitis?**

Posterior perforated duodenal ulcer into the pancreas (i.e., epigastric pain radiating to the back; high serum amylase)

**What is the classic difference between duodenal and gastric ulcer symptoms as related to food ingestion?**

Duodenal = decreased pain

Gastric = increased pain

(Think: **D**uodenal = **D**ecreased pain)

## TYPES OF SURGERIES

**Define the following terms:****Graham patch**

Place viable omentum over perforation and tack into place with sutures



### **Truncal vagotomy**

Resection of a 1- to 2-cm segment of each vagal **trunk** as it enters the abdomen on the distal esophagus, decreasing gastric acid secretion

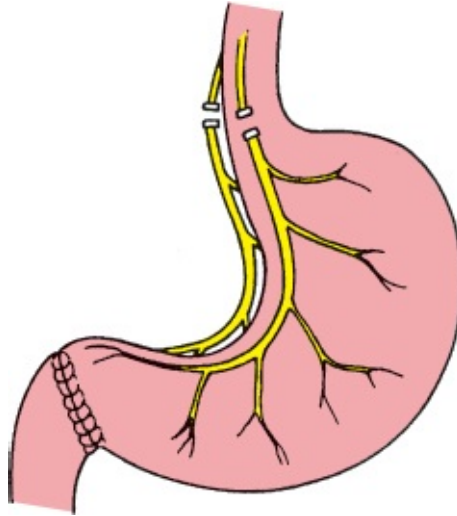
### **What other procedure must be performed along with a truncal vagotomy?**

“Drainage procedure” (pyloroplasty, antrectomy, or gastrojejunostomy), because vagal fibers provide relaxation of the pylorus, and, if you cut them, the pylorus will not open

### **Define the following terms:**

#### **Vagotomy and pyloroplasty**

Pyloroplasty performed with vagotomy to compensate for decreased gastric emptying

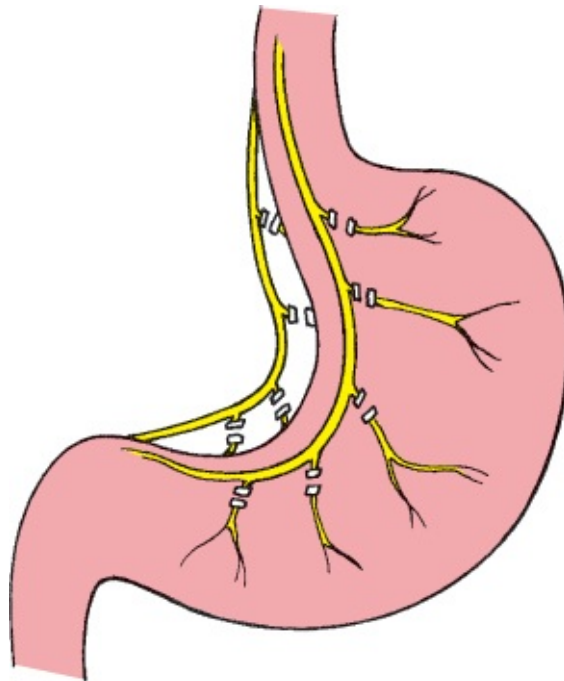


### **Vagotomy and antrectomy**

Remove antrum and pylorus in addition to vagotomy; reconstruct as a Billroth I or II

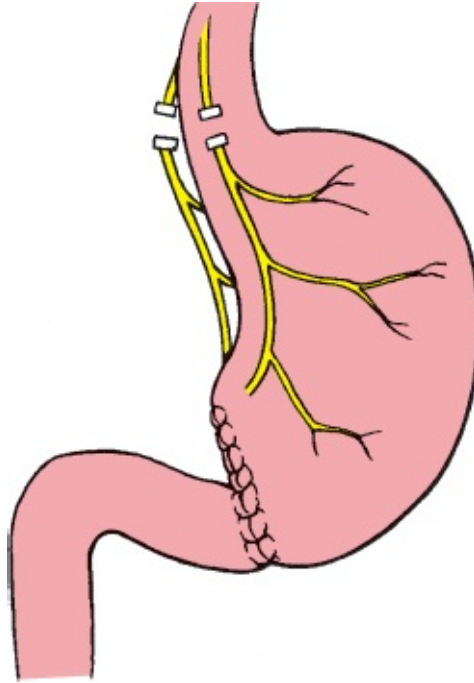
### **What is the advantage of proximal gastric vagotomy (highly selective vagotomy)?**

No drainage procedure is needed; vagal fibers to the pylorus are preserved; rate of dumping syndrome is low



### **What is a Billroth I (BI)?**

Truncal vagotomy, antrectomy, and gastroduodenostomy (Think: **BI** = **ONE** limb off of the stomach remnant)

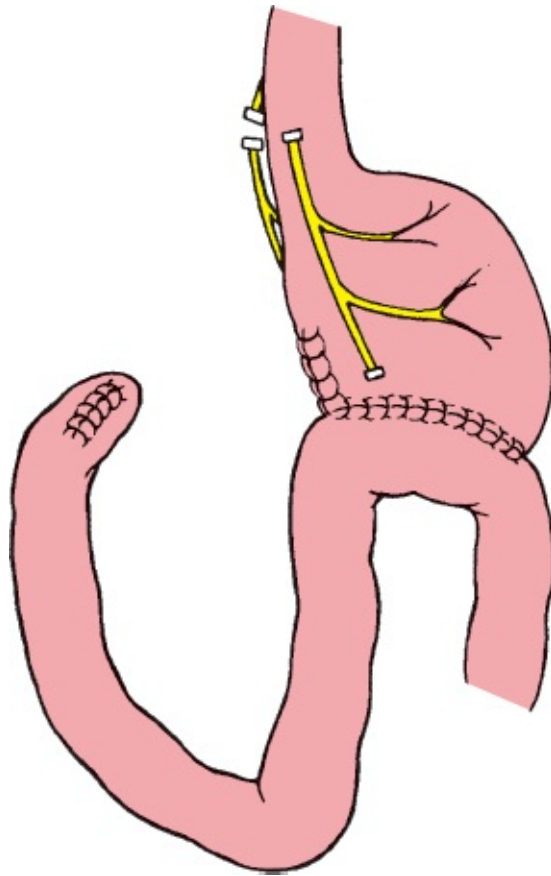


**What are the contraindications for a Billroth I?**

Gastric cancer or suspicion of gastric cancer

**What is a Billroth II (BII)?**

Truncal vagotomy, antrectomy, and gastrojejunostomy (Think: **BII** = **TWO** limbs off of the stomach remnant)



## STRESS GASTRITIS

### **What is it?**

**Superficial** mucosal erosions in the stressed patient

### **What are the risk factors?**

Sepsis, intubation, trauma, shock, burn, brain injury

### **What is the prophylactic treatment?**

H<sub>2</sub> blockers, PPIs, antacids, sucralfate

### **What are the signs/symptoms?**

NGT blood (usually), painless (usually)

### **How is it diagnosed?**

EGD, if bleeding is significant

**What is the treatment for gastritis?**

LAVAGE out blood clots, give a maximum dose of PPI in a 24-hour IV drip

## **MALLORY–WEISS SYNDROME**

**What is it?**

Postretching, postemesis longitudinal tear (submucosa and mucosa) of the stomach near the GE junction; approximately three fourths are in the stomach

**For what percentage of all UGI bleeds does this syndrome account?**

≈10%

**What are the causes of a tear?**

Increased gastric pressure, often aggravated by hiatal hernia

**What are the risk factors?**

Retching, alcoholism (50%), >50% of patients have hiatal hernia

**What are the symptoms?**

Epigastric pain, thoracic substernal pain, emesis, hematemesis

**What percentage of patients will have hematemesis?**

85%

**How is the diagnosis made?**

EGD

**What is the “classic” history?**

Alcoholic patient after binge drinking—first, vomit food and gastric contents, followed by forceful retching and bloody vomitus

**What is the treatment?**

Room temperature water lavage (90% of patients stop bleeding), electrocautery, arterial embolization, or surgery for refractory bleeding

**When is surgery indicated?**

When medical/endoscopic treatment fails

# ESOPHAGEAL VARICEAL BLEEDING

## **What is it?**

Bleeding from formation of esophageal varices from back up of portal pressure via the coronary vein to the submucosal esophageal venous plexuses secondary to portal hypertension from liver cirrhosis

## **What is the “rule of two thirds” of esophageal variceal hemorrhage?**

Two thirds of patients with portal hypertension develop esophageal varices  
Two thirds of patients with esophageal varices bleed

## **What are the signs/symptoms?**

Liver disease, portal hypertension, hematemesis, caput medusa, ascites

## **How is the diagnosis made?**

EGD (very important because only 50% of UGI bleeding in patients with known esophageal varices are bleeding from the varices; the other 50% have bleeding from ulcers, etc.)

## **What is the acute medical treatment?**

Lower portal pressure with octreotide or vasopressin

## **What are the treatment options?**

Sclerotherapy or band ligation via endoscope, TIPS, liver transplant

## **What is the problem with shunts?**

Decreased portal pressure, but increased encephalopathy

# BOERHAAVE'S SYNDROME

## **What is it?**

Postemetic esophageal rupture

## **Who was Dr. Boerhaave?**

Dutch physician who first described the syndrome in the Dutch Grand Admiral Van Wassenaer in 1724

## **Why is the esophagus susceptible to perforation and more likely to break down an anastomosis?**

No serosa

## **What is the most common location?**

Posterolateral aspect of the esophagus the left), 3 to 5 cm above the GE junction

## **What is the cause of rupture?**

Increased intraluminal pressure, usually caused by violent retching and vomiting

## **What is the associated risk factor?**

Esophageal reflux disease (50%)

## **What are the symptoms?**

Pain postemesis (may radiate to the back, dysphagia) (Think Boerhaave's = Boer HEAVES)

## **What are the signs?**

Left pneumothorax, Hamman's sign, left pleural effusion, subcutaneous/mediastinal emphysema, fever, tachypnea, tachycardia, signs of infection by 24 hours, neck crepitus, widened mediastinum on CXR

## **What is Mackler's triad?**

- . Emesis
- . Lower chest pain
- . Cervical emphysema (subQ air)

## **What is Hamman's sign?**

"Mediastinal crunch or clicking" produced by the heart beating against air-filled tissues

## **How is the diagnosis made?**

History, physical examination, CXR, esophagram with water-soluble contrast

## **What is the treatment?**

Surgery within 24 hours to drain the mediastinum and surgically close the perforation and placement of pleural patch; broad-spectrum antibiotics

**What is the mortality rate if >24 hours until surgery for perforated esophagus?**

≈33%

**Overall, what is the most common cause of esophageal perforation?**

Iatrogenic (most commonly cervical esophagus)

## **RAPID FIRE REVIEW**

**Name the diagnostic modality:**

**45-year-old male with dark blood per rectum, NGT returns clear fluid and no bile**

EGD to rule out UGI source

**What is the correct diagnosis?**

**40-year-old s/p MVC with severe liver injury on hospital day 3 develops significant UGI bleed; EGD reveals no ulcer or gastritis**

Hemobilia

# Chapter 40 Stomach

## GASTRIC PHYSIOLOGY

**Define the products of the following stomach cells:**

**Gastric parietal cells**

HCl

Intrinsic factor

**Chief cells**

PEPsinogen (Think: “a PEPpy chief”)

**Mucous neck cells**

Bicarbonate

Mucus

**G cells**

Gastrin (Think: G cells = Gastrin)

**Where are G cells located?**

Antrum

**What is pepsin?**

Proteolytic enzyme that hydrolyzes peptide bonds

**What is intrinsic factor?**

Protein secreted by the parietal cells that combines with vitamin B12 and allows for absorption in the terminal ileum

## GASTROESOPHAGEAL REFLUX DISEASE

## (GERD)

### **What is it?**

Excessive reflux of gastric contents into the esophagus, “heartburn”

### **What are the causes?**

Decreased lower esophageal sphincter (LES) tone (>50% of cases)

Decreased esophageal motility to clear refluxed fluid

Gastric outlet obstruction

Hiatal hernia in ≈50% of patients

### **What are the signs/symptoms?**

Heartburn, regurgitation, respiratory problems/pneumonia from aspiration of refluxed gastric contents; substernal pain

### **What tests are included in the workup?**

EGD

UGI contrast study with esophagogram

24-hour acid analysis (pH probe in esophagus)

Manometry, EKG, CXR

### **What is the medical treatment?**

Small meals

PPIs (proton-pump inhibitors) or H<sub>2</sub> blockers

Elevation of head at night and no meals prior to sleeping

### **What are the indications for surgery?**

Intractability (failure of medical treatment)

Respiratory problems as a result of reflux and aspiration of gastric contents (e.g., pneumonia)

Severe esophageal injury (e.g., ulcers, hemorrhage, stricture, ± Barrett's esophagus)

### **What is Barrett's esophagus?**

Columnar metaplasia from the normal squamous epithelium as a result of chronic irritation from reflux

**What is the major concern with Barrett's esophagus?**

Developing cancer

**What type of cancer develops in Barrett's esophagus?**

Adenocarcinoma

**What percentage of patients with GERD develops Barrett's esophagus?**

10%

**What percentage of patients with Barrett's esophagus will develop adenocarcinoma?**

7% lifetime (5% to 10%)

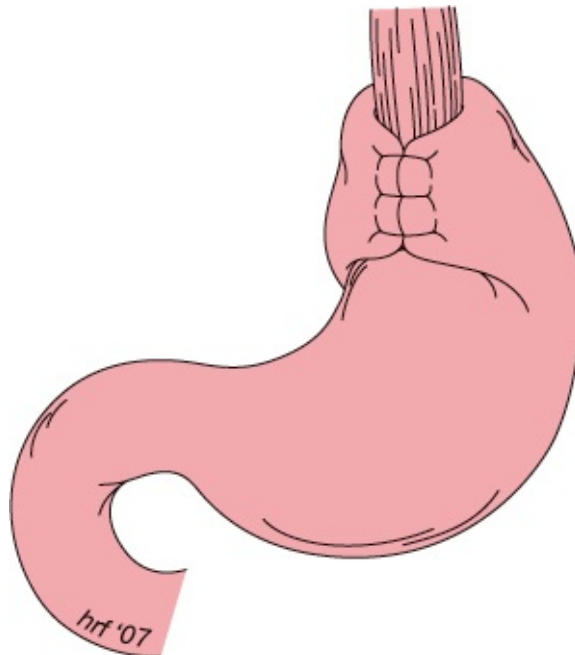
**What is the treatment of Barrett's esophagus with dysplasia?**

Nonsurgical: endoscopic mucosal resection and photodynamic therapy; other options include radiofrequency ablation, cryoablation (these methods are also often used for mucosal adenocarcinoma)

**Define the following surgical options for severe GERD:**

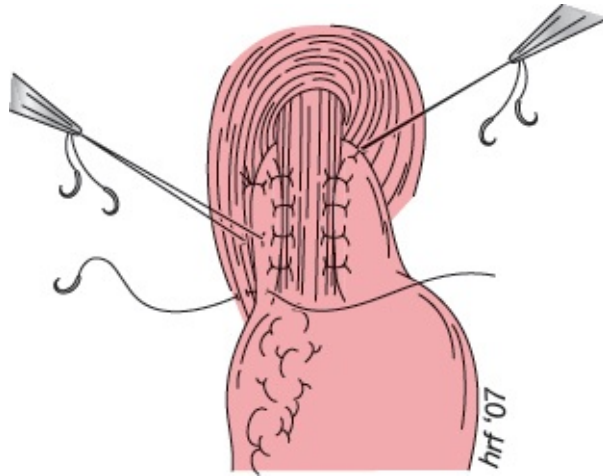
**Laparoscopic nissen fundoplication**

360-degree fundoplication—2 cm long (laparoscopically)



## Toupet

Incomplete ( $\approx 200$  degree) posterior wrap (laparoscopic) often used with severe decreased esophageal motility



## How does the Nissen wrap work?

Thought to work by improving the LES:

1. Increasing LES tone
2. Elongating LES  $\approx 3$  cm
3. Returning LES into abdominal cavity

## In what percentage of patients does Lap Nissen work?

85% (70% to 95%)

## What are the postoperative complications of Lap Nissen?

- . Gas bloat syndrome
- . Stricture
- . Dysphagia
- . Spleen injury requiring splenectomy
- . Esophageal perforation
- . Pneumothorax

## What is gas bloat syndrome?

Inability to burp or vomit

**GASTRIC CANCER**

**What are the associated risk factors?**

Diet—smoked meats, high nitrates, low fruits and vegetables, alcohol, tobacco

Environment—raised in high-risk area, poor socioeconomic status, atrophic gastritis, male gender, blood type A, previous partial gastrectomy, pernicious anemia, polyps, *Helicobacter pylori*

**Which blood type is associated with gastric cancer?**

Blood type A (Think: there is an “A” in gastric but no “O” or “B” = gastric = type “A”)

**What are the symptoms?**

The acronym “WEAPON”:

Weight loss

Emesis

Anorexia

Pain/epigastric discomfort

Obstruction

Nausea

**What is a Blumer’s shelf?**

Solid peritoneal deposit anterior to the rectum, forming a “shelf,” palpated on rectal examination

**What is a Virchow’s node?**

Metastatic gastric cancer to the nodes in the left supraclavicular fossa

**What is a surveillance laboratory finding?**

CEA elevated in 30% of cases (if +, useful for postoperative surveillance)

**What is the initial workup?**

EGD with biopsy, endoscopic U/S to evaluate the level of invasion, CT scan of abdomen/pelvis for metastasis, CXR, labs

**What is the histology?**

Adenocarcinoma

**What is the differential diagnosis for gastric tumors?**

Adenocarcinoma, leiomyoma, leiomyosarcoma, lymphoma, carcinoid, ectopic

pancreatic tissue, gastrinoma, benign gastric ulcer, polyp

**Which morphologic type is named after a “leather bottle”?**

Linitis plastica—the entire stomach is involved and looks thickened (10% of cancers)

**Which patients with gastric cancer are NONoperative?**

- . Distant metastasis (e.g., liver metastasis)
- . Peritoneal implants

**What is the role of laparoscopy?**

To rule out peritoneal implants and to evaluate for liver metastasis

**What is the genetic alteration seen in >50% of patients with gastric cancer?**

P53

**How can you remember P53 for gastric cancer?**

Gastric Cancer = GC = P53; or, think: “GCP ... 53”—it sings!

**What is the treatment?**

Surgical resection with wide (>5 cm checked by frozen section) margins and lymph node dissection

**What operation is performed for tumor in the:**

**Antrum?**

Distal subtotal gastrectomy

**Midbody?**

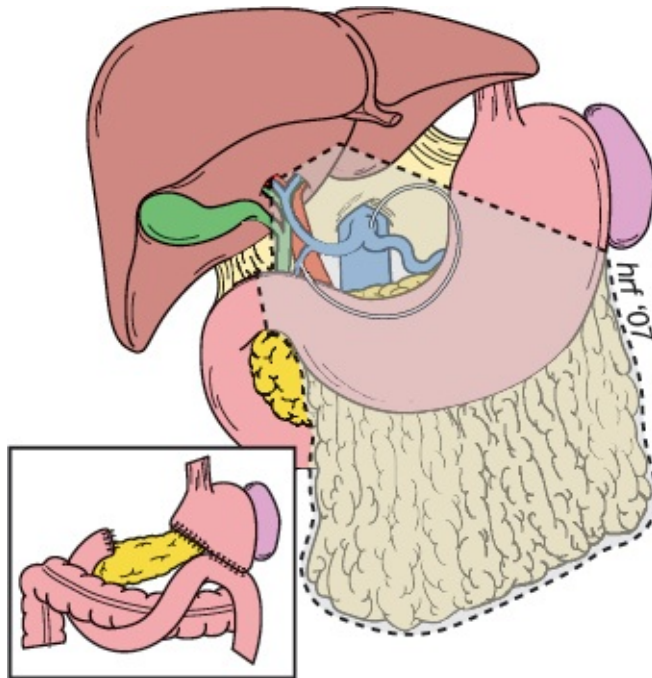
Total gastrectomy

**Proximal?**

Total gastrectomy

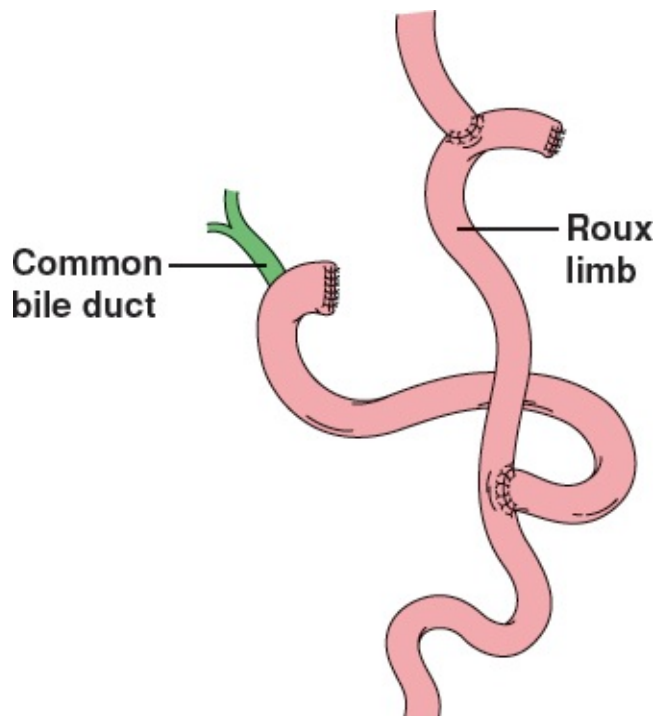
**What is a subtotal gastrectomy?**

Subtotal gastrectomy = 75% of stomach removed



### **What is a total gastrectomy?**

Stomach is removed and a Roux-en-Y limb is sewn to the esophagus



### **When should splenectomy be performed?**

When the tumor directly invades the spleen/splenic hilum or with splenic hilar adenopathy

## **What is the adjuvant treatment?**

Stages II and III: postoperative chemotherapy and radiation

# **GIST**

## **What is it?**

GastroIntestinal Stromal Tumor

## **What was it previously known as?**

Leiomyosarcoma

## **What is the cell of origin?**

CAJAL, interstitial cells of Cajal

## **Where is it found?**

GI tract—"esophagus to rectum"—most commonly found in **stomach** (60%), small bowel (30%), duodenum (5%), rectum (3%), colon (2%), esophagus (1%)

## **What are the symptoms?**

GI bleed, occult GI bleed, abdominal pain, abdominal mass, nausea, distention

## **How is it diagnosed?**

CT scan, EGD, colonoscopy

## **How are distant metastases diagnosed?**

PET scan

## **What is the tumor marker?**

C-KIT (CD117 antigen)

## **What is the prognosis?**

Local spread, distant metastases

Poor long-term prognosis: size >5 cm, mitotic rate >5 per 50 hpf (high-power field)

## **What is the treatment?**

Resect with negative margins, ± chemotherapy

**Is there a need for lymph node dissection?**

NO

**What is the chemotherapy for metastatic or advanced disease?**

Imatinib—tyrosine kinase inhibitor

## MALTOMA

**What is it?**

Mucosal-Associated Lymphoproliferative Tissue

**What is the most common site?**

Stomach (70%)

**What is the causative agent?**

*H. pylori*

**What is the medical treatment?**

Nonsurgical—treat for *H. pylori* with triple therapy and chemotherapy/XRT in refractory cases

## GASTRIC VOLVULUS

**What is it?**

Twisting of the stomach

**What are the symptoms?**

Borchardt's triad:

1. Distention of epigastrium
2. Cannot pass an NGT
3. Emesis followed by inability to vomit

**What is the treatment?**

Exploratory laparotomy to untwist, and gastropexy

## RAPID FIRE REVIEW

**Name the most likely diagnosis:**

**54-year-old woman with reflux disease and columnar epithelium on distal esophageal biopsy**

Barrett's esophagus

# Chapter 41 Bariatric Surgery

## What is it?

Weight reduction surgery for the morbidly obese

## Define morbid obesity

- . BMI  $>40$  (basically,  $>100$  pounds above ideal body weight) or
- . BMI  $>35$  with a medical problem related to morbid obesity

## What is BMI?

Body Mass Index

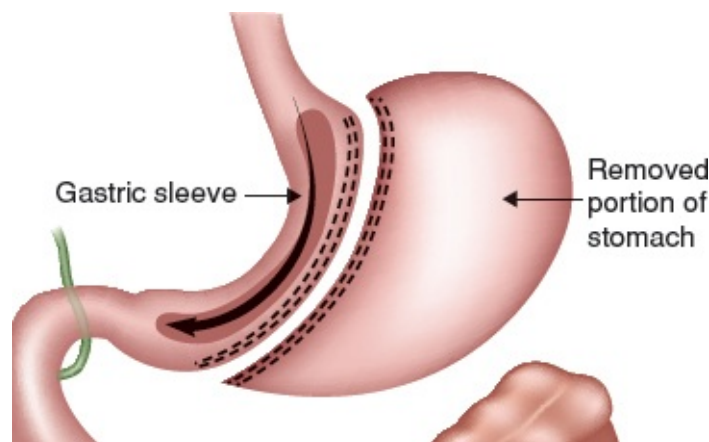
## What medical conditions are associated with morbid obesity?

Sleep apnea, coronary artery disease, pulmonary disease, diabetes mellitus, venous stasis ulcers, arthritis, infections, sex-hormone abnormalities, hypertension, breast cancer, colon cancer

## What are the current best options for surgery?

- . Sleeve gastrectomy
- . Gastric bypass (malabsorptive)
- . Vertical-banded gastroplasty

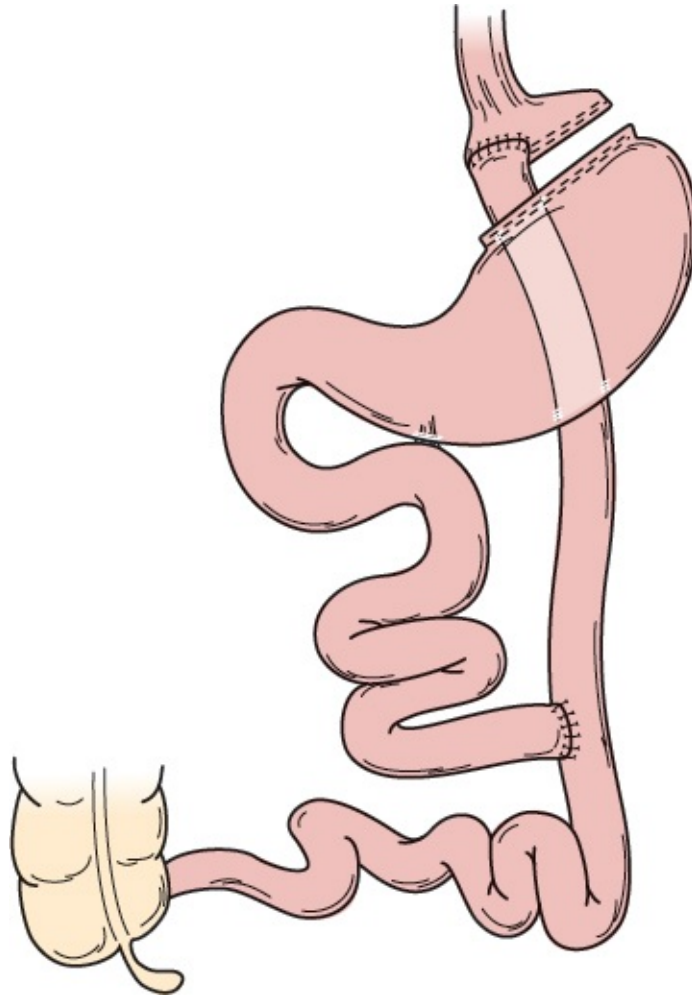
## Define sleeve gastrectomy



## **Define gastric bypass**

Stapling off of small gastric pouch (restrictive)

Roux-en-Y limb to gastric pouch (bypass)



## **How does gastric bypass work?**

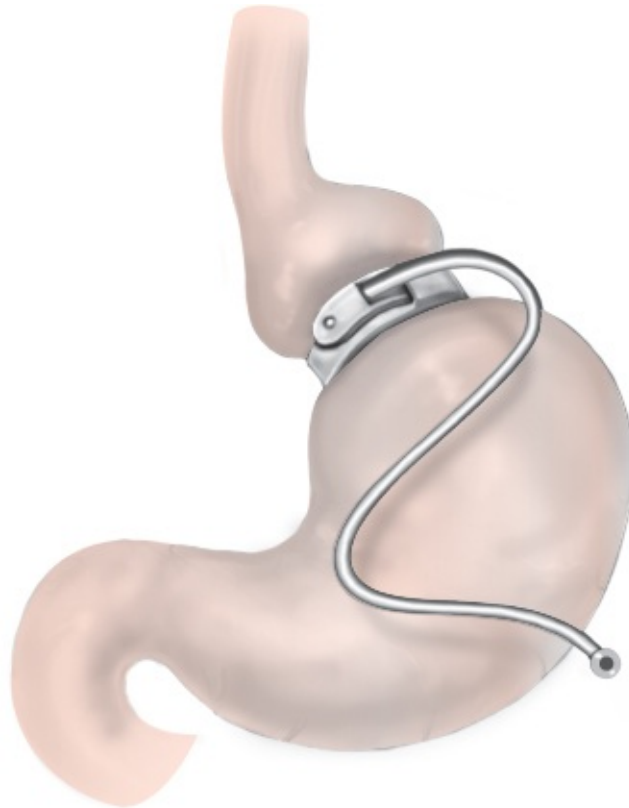- . Creates a small gastric reservoir
- . Causes dumping symptoms when a patient eats too much food or high-calorie foods; the food is “dumped” into the Roux-en-Y limb
- . Bypass of small bowel by Roux-en-Y limb

## **What is the most common sign of an anastomotic leak after a gastric bypass?**

Tachycardia

## **What is a LAP-BAND®?**

**L**aparoscopically placed **band** around stomach with a subcutaneous port to adjust constriction; results in smaller gastric reservoir



### **What is a Petersen's hernia?**

Seen after bariatric gastric bypass—internal herniation of small bowel through the mesenteric defect from the Roux-en-Y limb

## **RAPID FIRE REVIEW**

**Name the most likely diagnosis:**

**34 year old woman POD #2 gastric bypass with tachycardia and vague abdominal discomfort**

Anastomotic leak

**What is the correct diagnosis?**

**POD #2 s/p open gastric bypass for morbid obesity, patient becomes tachypneic and short of breath; sats = 86%, ABG PO<sub>2</sub> = 52, CO<sub>2</sub> = 30, EKG normal, chest x-ray normal**

Pulmonary embolus

# Chapter 42 Ostomies

**Define the following terms:**

## **Ostomy**

Operation that connects the GI tract to abdominal wall skin or the lumen of another hollow organ; a man-made fistula

## **Stoma**

Opening of the ostomy (Greek *mouth*)

## **Gastrostomy**

G-tube through the abdominal wall to the stomach for drainage or feeding

## **Jejunostomy**

J-tube through the abdominal wall to the jejunum for feeding

## **Colostomy**

Connection of colon mucosa to the abdominal wall skin for stool drainage

## **End colostomy**

Proximal end of colon brought to the skin for stool drainage

## **Mucous fistula**

Distal end of transected colon brought to the skin for decompression; the mucosa produces mucus, an ostomy is a fistula, and, hence, the term **mucous fistula** (proximal colon brought up as a colostomy or, if the proximal colon is removed, an ileostomy)

## **Hartmann's pouch**

Distal end of transected colon stapled and dropped back into the peritoneal cavity, resulting in a blind pouch; mucus is decompressed through the anus (proximal colon is brought up as an end colostomy or, if proximal colon is

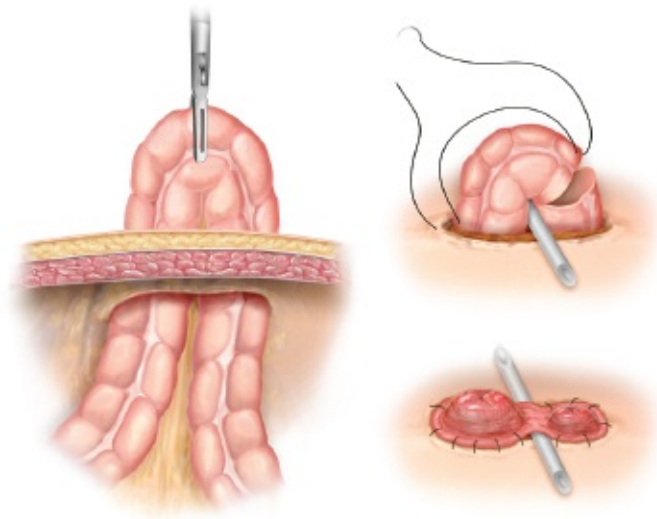
removed, an end ileostomy)

### **Double-barrel colostomy**

End colostomy and a mucous fistula (i.e., two barrels brought up to the skin)

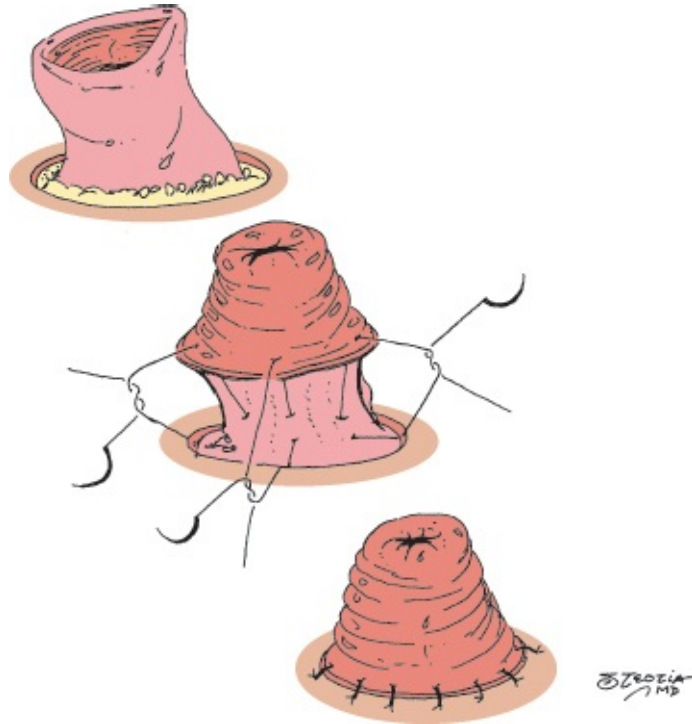
### **Loop colostomy**

Loop of large bowel is brought up to the abdominal wall skin and a plastic rod is placed underneath the loop; the colon is then opened and sewn to the abdominal wall skin as a colostomy



### **Brooke ileostomy**

Ileostomy folded over itself to provide clearance from skin



### **Why doesn't an ileostomy or colostomy close?**

Epithelialization (mucosa to skin) from the acronym FRIEND

### **Why doesn't a gastrostomy close?**

Foreign body (the plastic tube) from the acronym FRIEND

### **If the plastic tube, G-tube, or J-tube is removed, how fast can the hole to the stomach or jejunum close?**

In a matter of hours! (Therefore, if it comes out inadvertently from a well-established tract, it must be replaced immediately)

### **What is a "tube check"?**

Gastrografin contrast study to confirm that a G-tube or J-tube is within the lumen of the stomach or jejunum, respectively

## **RAPID FIRE REVIEW**

**Name the most likely diagnosis:**

**S/P gastrojejunostomy with postprandial tachycardia, diarrhea,  
and abdominal pain**

Dumping syndrome

# Chapter 43 Small Intestine

## SMALL BOWEL

### Anatomy

**What comprises the small bowel?**

Duodenum, jejunum, and ileum

**How long is the duodenum?**

≈12 inches—thus the name: duodenum!

**What marks the end of the duodenum and the start of the jejunum?**

Ligament of Treitz

**What is the length of the entire small bowel?**

≈6 meters (20 feet)

**What are the plicae circulares?**

*Plicae* means “folds,” *circulares* means “circular”; thus, circular folds of mucosa (a.k.a. “valvulae conniventes”) in small bowel lumen

**What does the terminal ileum absorb?**

B12, fatty acids, bile salts

### Small Bowel Obstruction

**What is small bowel obstruction (SBO)?**

Mechanical obstruction to the passage of intraluminal contents

**What are the signs/symptoms?**

Abdominal discomfort, cramping, nausea, abdominal distention, emesis, high-pitched bowel sounds

**What lab tests are performed with SBO?**

Electrolytes, CBC, type and screen, urinalysis

**What are classic electrolyte/acid–base findings with proximal obstruction?**

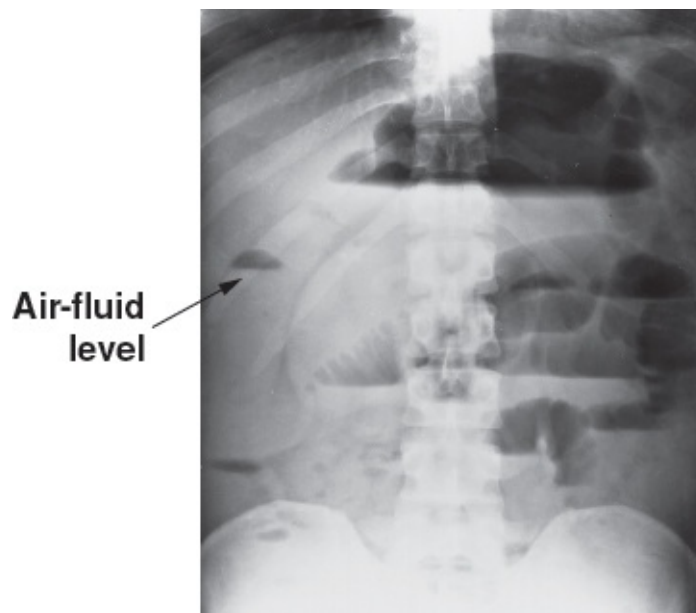
Hypovolemic, hypochloremic, hypokalemia, alkalosis

**What must be ruled out on physical exam in patients with SBO?**

Incarcerated hernia (also look for surgical scars)

**What major AXR findings are associated with SBO?**

Distended loops of small bowel air-fluid levels on upright film

**Define complete SBO**

Complete obstruction of the lumen

**What is the danger of complete SBO?**

Closed loop strangulation of the bowel leading to bowel necrosis

**Define partial SBO**

Incomplete SBO

**What is initial management of all patients with SBO?**

NPO, NGT, IVE, Foley

**What tests can differentiate partial from complete bowel obstruction?**

CT scan with oral contrast

**What are the ABCs of SBO?**

Causes of SBO:

1. Adhesions
2. Bulge (hernias)
3. Cancer and tumors

**What is superior mesenteric artery (SMA) syndrome?**

Seen with weight loss—SMA compresses duodenum, causing obstruction

**What is the treatment of complete SBO?**

Laparotomy and lysis of adhesions

**What is the treatment of incomplete SBO?**

Initially, conservative treatment with close observation plus NGT decompression

**Intraoperatively, how can the level of obstruction be determined in patients with SBO?**

Transition from dilated bowel proximal to the decompressed bowel distal to the obstruction

**What is the most common indication for abdominal surgery in patients with Crohn's disease?**

SBO due to strictures

**Can a patient have complete SBO and bowel movements and flatus?**

Yes; the bowel distal to the obstruction can clear out gas and stool

**After a small bowel resection, why should the mesenteric defect**

**always be closed?**

To prevent an internal hernia

**What may cause SBO if patient is on Coumadin®?**

Bowel wall hematoma

**What is the #1 cause of SBO in adults (industrialized nations)?**

Postoperative adhesions

**What is the #1 cause of SBO around the world?**

Hernias

**What is the #1 cause of SBO in children?**

Hernias

**What are the signs of strangulated bowel with SBO?**

**Fever**, severe/continuous pain, hematemesis, **shock**, gas in the bowel wall or portal vein, abdominal free air, **peritoneal signs**, **acidosis** (increased lactic acid)

**What are the clinical parameters that will lower the threshold to operate on a partial SBO?**

Increasing **WBC**

**Fever**

**Tachycardia**/tachypnea

**Abdominal pain**

**What is an absolute indication for operation with partial SBO?**

Peritoneal signs, free air on AXR

**What classic saying is associated with complete SBO?**

“Never let the sun set or rise on complete SBO”

**What condition commonly mimics SBO?**

Paralytic ileus (AXR reveals gas distention throughout, including the colon)

**What is the differential diagnosis of paralytic (nonobstructive) ileus?**

Postoperative ileus after abdominal surgery (normally resolves in 3 to 5 days)

Electrolyte abnormalities (hypokalemia is most common)  
Medications (anticholinergic, narcotics)  
Inflammatory intra-abdominal process  
Sepsis/shock  
Spine injury/spinal cord injury  
Retroperitoneal hemorrhage

**What tumor classically causes SBO due to “mesenteric fibrosis”?**

Carcinoid tumor

## ■ Small Bowel Tumors

**What is the differential diagnosis of benign tumors of the small intestine?**

Leiomyoma, lipoma, lymphangioma, fibroma, adenomas, hemangiomas

**What are the signs and symptoms of small bowel tumors?**

Abdominal pain, weight loss, obstruction (SBO), and perforation

**What is the most common benign small bowel tumor?**

Leiomyoma

**What is the most common malignant small bowel tumor?**

Adenocarcinoma

**What is the differential diagnosis of malignant tumors of the small intestine?**

- . Adenocarcinoma (50%)
- . Carcinoid (25%)
- . Lymphoma (20%)
- . Sarcomas (<5%)

**What is the workup of a small bowel tumor?**

UGI with small bowel follow-through, enteroclysis, CT scan, enteroscopy

**What is the treatment for malignant small bowel tumor?**

Resection and removal of mesenteric draining lymph nodes

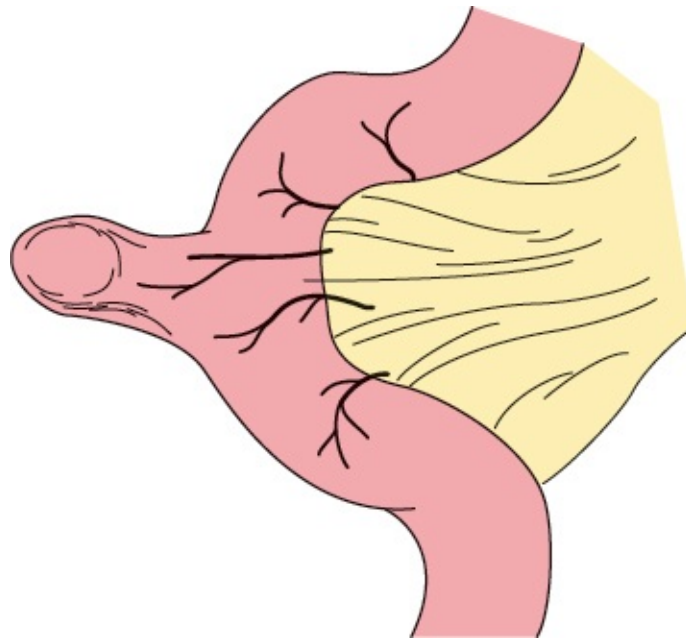
**What malignancy is classically associated with metastasis to the small bowel?**

Melanoma

## ■ Meckel's Diverticulum

**What is it?**

Remnant of the omphalomesenteric duct/vitelline duct, which connects the yolk sac with the primitive midgut in the embryo



**What is the usual location?**

Within  $\approx 2$  feet of the ileocecal valve on the **antimesenteric** border of the bowel

**What is the major differential diagnosis?**

Appendicitis

**Is it a true diverticulum?**

**Yes;** all layers of the intestine are found in the wall

**What is the incidence?**

≈2% of the population at autopsy

### **What is the gender ratio?**

Twice as common in **men**

### **What is the average age at onset of symptoms?**

Most frequently in the first **2 years of life**, but can occur at any age

### **What are the possible complications?**

**Intestinal hemorrhage** (painless)—50%; accounts for half of all lower GI bleeding in patients younger than 2 years

Bleeding results from ectopic gastric mucosa secreting acid → ulcer → bleeding

**Intestinal obstruction**—25%; most common complication in adults; includes volvulus and intussusception

**Inflammation** (± perforations)—20%

### **What are the signs/symptoms?**

Lower GI bleeding, abdominal pain, SBO

### **What is the most common complication of Meckel's diverticulum in adults?**

Intestinal obstruction

### **In what percentage of cases is heterotopic tissue found in the diverticulum?**

>50%

### **What heterotopic tissue type is most often found?**

**Gastric mucosa** (60%), but duodenal, pancreatic, and colonic mucosa are also found

### **What is the “rule of 2s”?**

2% of patients are **symptomatic**

Found ≈2 feet from the ileocecal valve

Found in 2% of the population

Most symptoms occur before age 2 years

Ectopic tissue found in 1 of 2 patients

Most diverticula are ≈2 inches long

2:1 male-to-female ratio

**What is the role of incidental Meckel's diverticulectomy (surgical removal upon finding asymptomatic diverticulum)?**

- . Most would remove in all children
- . Adults:
  - Ectopic tissue (fullness) or
  - Mesodiverticular band

**What is a Meckel's scan?**

Scan for ectopic gastric mucosa in Meckel's diverticulum; uses **technetium pertechnetate** IV, which is preferentially taken up by gastric mucosa

**What is the treatment of a Meckel's diverticulum that is causing bleeding and obstruction?**

Surgical resection, with small bowel resection as the actual ulcer is usually on the mesenteric wall opposite the diverticulum!

## RAPID FIRE REVIEW

**Name the diagnostic modality:**

**25-year-old female with history of several abdominal surgeries now with 2-day history of abdominal distention, vomiting, and no gas or bowel movements**

Abd/pelvis CT scan with oral contrast to rule out SBO (small bowel obstruction)

**52 year old male alcoholic with history of blood in vomit**  
EGD

**What is the treatment?**

**67-year-old female with history of several abdominal surgeries presents with several days of crampy abdominal pain and vomiting, and x-ray reveals air fluid levels; normal WBC afebrile,**

**nl lactic acid level, pH is normal, mild tenderness on exam**

CT scan with oral contrast and NGT decompression, IVF, serial and exams for SBO (oral contrast is thought to be therapeutic!)

**What is the correct diagnosis?**

**Jejunal ulcers**

Zollinger–Ellison syndrome

**17-year-old s/p MVC with abdominal pain, seatbelt sign across abd, free fluid without solid organ injury on abd CT scan**

Small bowel injury

**Name the radiographic test for localizing the following:**

**Meckel's diverticulum**

Technetium-99m sodium pertechnetate scan

## Chapter 44 Appendix

### **What vessel provides blood supply to the appendix?**

Appendiceal artery—branch of the ileocolic artery

### **Name the mesentery of the appendix**

Mesoappendix (contains the appendiceal artery)

### **How can the appendix be located if the cecum has been identified?**

Follow the teniae coli down to the appendix; the teniae converge on the appendix

## APPENDICITIS

### **What is it?**

Inflammation of the appendix caused by **obstruction** of the appendiceal lumen, producing a closed loop with resultant inflammation that can lead to necrosis and perforation

### **What are the causes?**

Lymphoid hyperplasia, fecalith (a.k.a. “appendicolith”)

### **What is the lifetime incidence of acute appendicitis in the United States?**

≈7%!

### **What is the most common cause of emergent abdominal surgery in the United States?**

Acute appendicitis

### **How does appendicitis classically present?**

Classic chronologic order:

1. Periumbilical pain (intermittent and crampy)

2. Nausea/vomiting
3. Anorexia
4. Pain migrates to RLQ (constant and intense pain), usually in <24 hours

### **Why does periumbilical pain occur?**

Referred pain

### **Why does RLQ pain occur?**

Peritoneal irritation

### **What are the signs/symptoms?**

Signs of peritoneal irritation may be present: guarding, muscle spasm, rebound tenderness, obturator and psoas signs, low-grade fever (high grade if perforation occurs), RLQ hyperesthesia

### **Define the following terms:**

#### **Obturator sign**

Pain upon internal rotation of the leg with the hip and knee flexed; seen in patients with pelvic appendicitis

#### **Psoas sign**

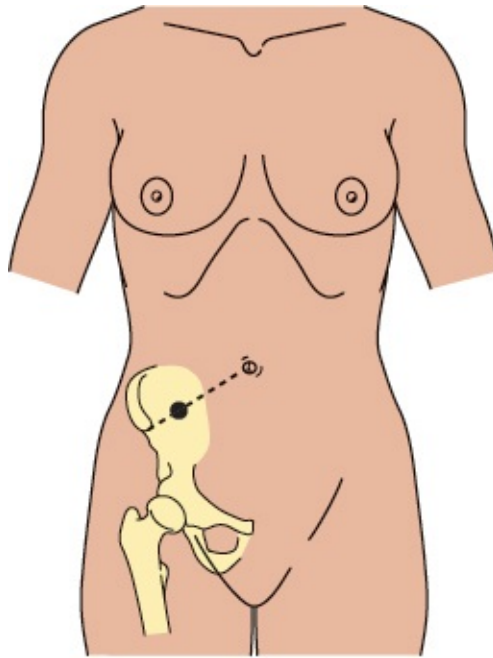
Pain elicited by extending the hip with the knee in full extension or by flexing the hip against resistance; seen classically in retrocecal appendicitis

#### **Rovsing's sign**

Palpation or rebound pressure of the LLQ results in pain in the RLQ; seen in appendicitis

#### **McBurney's point**

Point one third from the anterior superior iliac spine to the umbilicus (often the point of maximal tenderness)



**What is the differential diagnosis for:**

**Everyone?**

Meckel's diverticulum, Crohn's disease, perforated ulcer, pancreatitis, mesenteric lymphadenitis, constipation, gastroenteritis, intussusception, volvulus, tumors, UTI (e.g., cystitis), pyelonephritis, torsed epiploicae, cholecystitis, cecal tumor, diverticulitis (floppy sigmoid)

**Females?**

Ovarian cyst, ovarian torsion, tuboovarian abscess, mittelschmerz, pelvic inflammatory disease (PID), ectopic pregnancy, ruptured pregnancy

**What lab tests should be performed?**

CBC: increased WBC ( $>10,000$  per  $\text{mm}^3$  in  $>90\%$  of cases), most often with a "left shift"

Urinalysis: to evaluate for pyelonephritis or renal calculus

**Can you have an abnormal urinalysis with appendicitis?**

Yes; mild hematuria and pyuria are common in appendicitis with pelvic inflammation, resulting in inflammation of the ureter

**What additional tests can be performed if the diagnosis is not clear?**

Spiral CT scan, U/S (may see a large, noncompressible appendix or fecalith)

### **In acute appendicitis, what classically precedes vomiting?**

Pain (in gastroenteritis, the pain classically follows vomiting)

### **What radiographic studies are often performed?**

CXR: to rule out RML or RLL pneumonia, free air

AXR: abdominal films are usually nonspecific, but calcified fecalith present in ≈5% of cases

### **What are the CT scan findings with acute appendicitis?**

Periappendiceal fat stranding, appendiceal diameter >6 mm, periappendiceal fluid, fecalith

### **What are the preoperative medications/preparation?**

- . Rehydration with **IV fluids** (LR)
- . Preoperative **antibiotics** with anaerobic coverage (appendix is considered part of the colon)

### **What is a lap appy?**

Laparoscopic appendectomy; used in most cases in women (can see adnexa) or if patient has a need to quickly return to physical activity, or is obese

### **What is the treatment for *nonperforated* acute appendicitis?**

Nonperforated—prompt appendectomy (prevents perforation), 24 hours of antibiotics, discharge home usually on POD #1

### **What is the treatment for *perforated* acute appendicitis?**

Perforated—IV fluid resuscitation and prompt appendectomy; all pus is drained with postoperative antibiotics continued for 3 to 7 days; wound is left open in most cases of perforation after closing the fascia (heals by secondary intention or delayed primary closure)

### **How is an appendiceal abscess that is diagnosed preoperatively treated?**

**Percutaneous** drainage of the abscess, antibiotic administration, and elective appendectomy ≈6 weeks later (a.k.a. “interval appendectomy”)

**If a normal appendix is found upon exploration, should you take out the normal appendix?**

Yes

**How long after removal of a NONRUPTURED appendix should antibiotics continue postoperatively?**

For 24 hours

**Which antibiotic is used for NONPERFORATED appendicitis?**

Anaerobic coverage: Cefoxitin®, Cefotetan®, Unasyn®, Cipro®, and Flagyl®

**What antibiotic is used for a PERFORATED appendix?**

**Broad-spectrum antibiotics** (e.g., amp/Cipro®/clinda or a penicillin such as Zosyn®)

**How long do you give antibiotics for perforated appendicitis?**

Until the patient has a normal WBC count and is afebrile, ambulating, and eating a regular diet (usually 3 to 7 days)

**What is the risk of perforation?**

≈25% by 24 hours from onset of symptoms, ≈50% by 36 hours, and ≈75% by 48 hours

**What is the most common general surgical abdominal emergency in pregnancy?**

Appendicitis (about 1/1750; appendix may be in the RUQ because of the enlarged uterus)

**What are the possible complications of appendicitis?**

Pelvic abscess, liver abscess, free perforation, portal pylethrombophlebitis (very rare)

**What percentage of negative appendectomies is acceptable?**

Up to 20%; taking out some normal appendixes is better than missing a case of acute appendicitis that eventually ruptures

**Who is at risk of dying from acute appendicitis?**

Very old and very young patients

**What bacteria are associated with “mesenteric adenitis” that can closely mimic acute appendicitis?**

*Yersinia enterocolitica*

## CLASSIC INTRAOPERATIVE QUESTIONS

**What are the layers of the abdominal wall during a McBurney incision?**

- . Skin
- . Subcutaneous fat
- . Scarpa’s fascia
- . External oblique
- . Internal oblique
- . Transversus muscle
- . Transversalis fascia
- . Preperitoneal fat
- . Peritoneum

**How can you find the appendix after identifying the cecum?**

Follow the teniae down to where they converge on the appendix

**If you find Crohn’s disease in the terminal ileum, will you remove the appendix?**

Yes, if the cecal/appendiceal base is not involved

**If the appendix is normal what do you inspect intraoperatively?**

Terminal ileum: Meckel’s diverticulum, Crohn’s disease, intussusception

Gynecologic: Cysts, torsion, etc.

Groin: hernia, rectus sheath hematoma, adenopathy (adenitis)

## APPENDICEAL TUMORS

**What is the most common appendiceal tumor?**

Carcinoid tumor

**What is the treatment of appendiceal carcinoid <1.5 cm?**

Appendectomy (if not through the bowel wall)

**What is the treatment of appendiceal carcinoid >1.5 cm?**

Right hemicolectomy

**What percentage of appendiceal carcinoids are malignant?**

<5%

**What is the differential diagnosis of appendiceal tumor?**

Carcinoid, adenocarcinoma, malignant mucoid adenocarcinoma

**What type of appendiceal tumor can cause the dreaded pseudomyxoma peritonei if the appendix ruptures?**

Malignant mucoid adenocarcinoma

## RAPID FIRE REVIEW

**Name the diagnostic modality:**

**8-year-old with history of RLQ pain, s/p appendectomy**

Technetium 99m pertechnetate Meckel's scan looking for a Meckel's diverticulum

# Chapter 45 Carcinoid Tumors

## What is a carcinoid tumor?

Tumor arising from neuroendocrine cells (APUDomas), a.k.a. “**Kulchitsky cells**”; basically, a tumor that secretes **serotonin**

## Why is it called “carcinoid”?

Suffix “-oid” means “resembling”; thus, carcinoid resembles a carcinoma but is clinically and histologically less aggressive than most GI carcinomas

## How can you remember that Kulchitsky cells are found in carcinoid tumors?

Think: “COOL CAR” or KULchitsky CARcinoid

## What are the common sites of occurrence?

Think “**AIR**”:

1. **A**ppendix (most common)
2. **I**leum
3. **R**ectum
4. **B**ronchus

Other sites: jejunum, stomach, duodenum, colon, ovary, testicle, pancreas, thymus

## What are the signs/symptoms?

Depends on location; most cases are asymptomatic; also SBO, abdominal pain, bleeding, weight loss, diaphoresis, **pellagra skin changes**, intussusception, carcinoid syndrome, wheezing

## Why SBO with carcinoid?

Classically = severe mesenteric fibrosis

## What are the pellagra-like symptoms?

Think “**3D**”:

1. **D**ermatitis
2. **D**iarrhea
3. **D**ementia

### **What causes pellagra in carcinoid patients?**

Decreased **niacin** production

### **What is carcinoid syndrome?**

Syndrome of symptoms caused by release of substances from a carcinoid tumor

### **What are the symptoms of carcinoid syndrome?**

Remember the acronym “**B FDR**”:

**B**ronchospasm

**F**lushing (skin)

**D**iarrhea

**R**ight-sided heart failure (from valve failure)

### **What is a complete memory aid for carcinoid?**


Think: “**Be FDR** in a **cool CAR**” (COOL = **KUL**chitsky cells),

FDR = Flush

Diarrhea

Right-sided heart failure,

CAR = **CAR**cinoid



### **Why does right-sided heart failure develop but not left-sided heart failure?**

Lungs act as a filter (just like the liver); thus, the left heart doesn't see all the

vasoactive compounds

**Classic cardiac complication with carcinoid syndrome?**

**Tips:** Tricuspid Insufficiency Pulmonary Stenosis

**What is the incidence of carcinoid SYNDROME in patients who have a carcinoid TUMOR?**

≈10%

**What released substances cause carcinoid syndrome?**

**Serotonin** and vasoactive peptides

**What is the medical treatment for carcinoid syndrome?**

Octreotide IV

**What is the medical treatment of diarrhea alone?**

Odansetron (Zofran<sup>®</sup>)—serotonin antagonist

**How does the liver prevent carcinoid syndrome?**

By degradation of serotonin and the other vasoactive peptides when the **tumor drains into the portal vein**

**Why does carcinoid syndrome occur in some tumors and not in others?**

Occurs when **venous drainage from the tumor gains access to the systemic circulation** by avoiding hepatic degradation of the vasoactive substances

**What tumors can produce carcinoid syndrome?**

**Liver metastases**

Retroperitoneal disease draining into paravertebral veins

Primary tumor outside the GI tract, portal venous drainage (e.g., ovary, **testicular**, bronchus)

**What does the liver break down serotonin into?**

5-hydroxyindoleacetic acid (**5-HIAA**)

**What percentage of patients with a carcinoid have an elevated urine 5-HIAA level?**

50%

**What are the associated diagnostic lab findings?**

**Elevated urine 5-HIAA** as well as elevated urine and blood **serotonin** levels

**How do you remember 5-HIAA for carcinoid?**

Think of a **5-HIGH CAR** pileup = **5-HIAA CARcinoid**



**What stimulation test can often elevate serotonin levels and cause symptoms of carcinoid syndrome?**

Pentagastrin stimulation

**How do you localize a GI carcinoid?**

Barium enema, upper GI series with small bowel follow-through, colonoscopy, enteroscopy, enteroclysis, EGD, radiology tests

**What are the special radiologic (scintigraphy) localization tests?**

<sup>131</sup>I-MIBG (131 metaiodobenzylguanidine)

<sup>111</sup>In-octreotide

PET scan utilizing <sup>11</sup>C-labeled HTP

**What is the surgical treatment?**

Excision of the primary tumor and single or feasible metastasis in the liver (liver transplant is an option with unresectable liver metastasis); chemotherapy for

advanced disease

### **What is the medical treatment?**

Medical therapy for palliation of the carcinoid syndrome (serotonin antagonists, somatostatin analogue [**octreotide**])

### **How effective is octreotide?**

It relieves diarrhea and flushing in more than 85% of cases and may shrink tumor in 10% to 20% of cases

### **What is a common antiserotonin drug?**

**Cyproheptadine**

### **What is the overall prognosis?**

Two thirds of patients are alive at 5 years

### **What is the prognosis of patients with liver metastasis or carcinoid syndrome?**

50% are alive at 3 years

### **What does carcinoid tumor look like?**

Usually intramural bowel mass; appears as **yellowish** tumor upon incision

### **For appendiceal carcinoid, when is a right hemicolectomy indicated versus an appendectomy?**

If the tumor is **>1.5 cm**, right **hemicolectomy** is indicated; if there are no signs of serosal or cecal involvement and tumor is **<1.5 cm**, **appendectomy** should be performed

### **Which primary site has the highest rate of metastasis?**

Ileal primary tumor

### **Can a carcinoid tumor be confirmed malignant by looking at the histology?**

No, metastasis must be present to diagnose malignancy

### **What is the correlation between tumor size and malignancy potential?**

Vast majority of tumors <2 cm are benign; in tumors >2 cm, malignancy potential is significant

**What treatments might you use for the patient with unresectable liver metastasis that is refractory to medical treatment?**

Chemoembolization or radiofrequency ablation

## **RAPID FIRE REVIEW**

**Name the diagnostic modality:**

**50-year-old male with history of flushing, diarrhea, JVD with echo revealing right-sided heart failure**

24-hour urinary 5-HIAA (5-hydroxyindoleacetic acid) level to work up carcinoid syndrome

# Chapter 46 Fistulas

## What is a fistula?

Abnormal **communication** between two hollow organs or a hollow organ and the skin (i.e., two epithelial cell layers)

## What are the predisposing factors and conditions that maintain patency of a fistula?

The acronym “**HIS FRIEND**”:

**H**igh output fistula (>500 cc/day)

**I**ntestinal destruction (>50% of circumference)

**S**hort-segment fistula <2.5 cm

**F**oreign body (e.g., G-tube)

**R**adiation

**I**nfection

**E**pithelialization (e.g., colostomy)

**N**eoplasm

**D**istal obstruction

## SPECIFIC TYPES OF FISTULAS

### ■ Enterocutaneous

#### What is it?

Fistula from GI tract to skin (enterocutaneous = **bowel to skin**)

#### What are the causes?

Anastomotic leak, trauma/injury to the bowel/colon, Crohn's disease, abscess, diverticulitis, inflammation/infection, inadvertent suture through bowel

### **What is the workup?**

- . CT scan to rule out abscess/inflammatory process
- . Fistulagram

### **What are the possible complications?**

High-output fistulas, malnutrition, skin breakdown

### **What is the treatment?**

NPO; TPN; drain abscesses, rule out and correct underlying causes; may feed distally (or if fistula is distal, feed elemental diet proximally); half will close spontaneously, but the other half require operation and resection of the involved bowel segment

### **Which enterocutaneous fistula closes faster: short or long?**

Long fistula (may be counterintuitive—but true)

## **Colonic Fistulas**

### **What are they?**

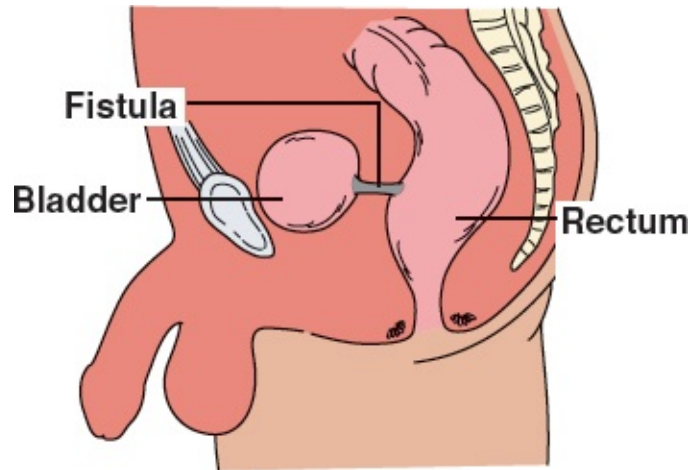
Include colovesical, colocutaneous, colovaginal, and coloenteric fistulas

### **What are the most common causes?**

**Diverticulitis** (most common cause), cancer, IBD, foreign body, and irradiation

### **What is the most common type?**

**Colovesical fistula**, which often presents with recurrent urinary tract infections; other signs include pneumaturia, dysuria, and fecaluria



### **How is the diagnosis made?**

Via barium enema (BE) and cystoscopy

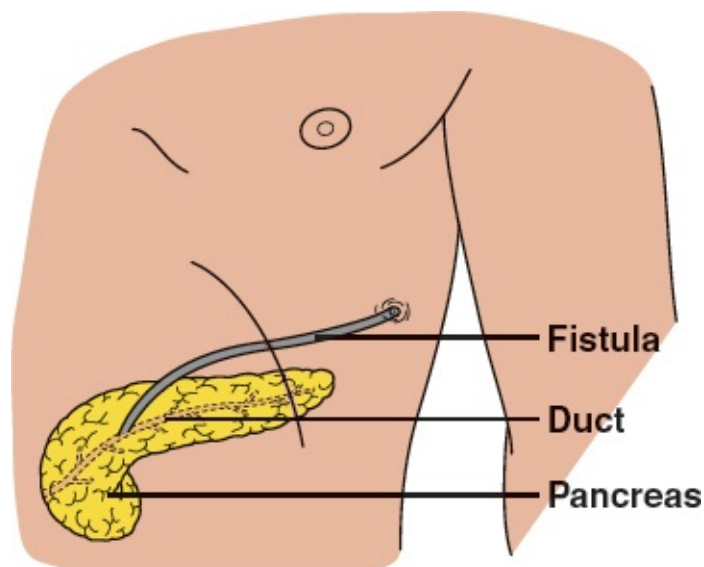
### **What is the treatment?**

Surgery: segmental colon resection and primary anastomosis; repair/resection of the involved organ

## **External Pancreatic Fistula**

### **What is it?**

Pancreaticocutaneous fistula; drainage of pancreatic exocrine secretions through to abdominal skin (usually through drain tract/wound)



**What is the treatment?**

NPO, TPN, skin protection, **octreotide**

**What is a “refractory” pancreatic fistula?**

Pancreaticocutaneous fistula that does not resolve with conservative medical management (the minority of cases)

**What is the diagnostic test for “refractory” pancreatic fistulas?**

ERCP to define site of fistula tract (i.e., tail versus head of pancreas)

**How is refractory tail of a pancreas fistula treated?**

Resection of the tail of the pancreas and the fistula

**How is refractory head of a pancreas fistula treated?**

Pancreaticojejunostomy

## **RAPID FIRE REVIEW**

**Name the diagnostic modality:**

**40-year-old male with history of passing air with his urine**

CT scan looking for colocystic fistula usually from diverticulitis

**What is the correct diagnosis**

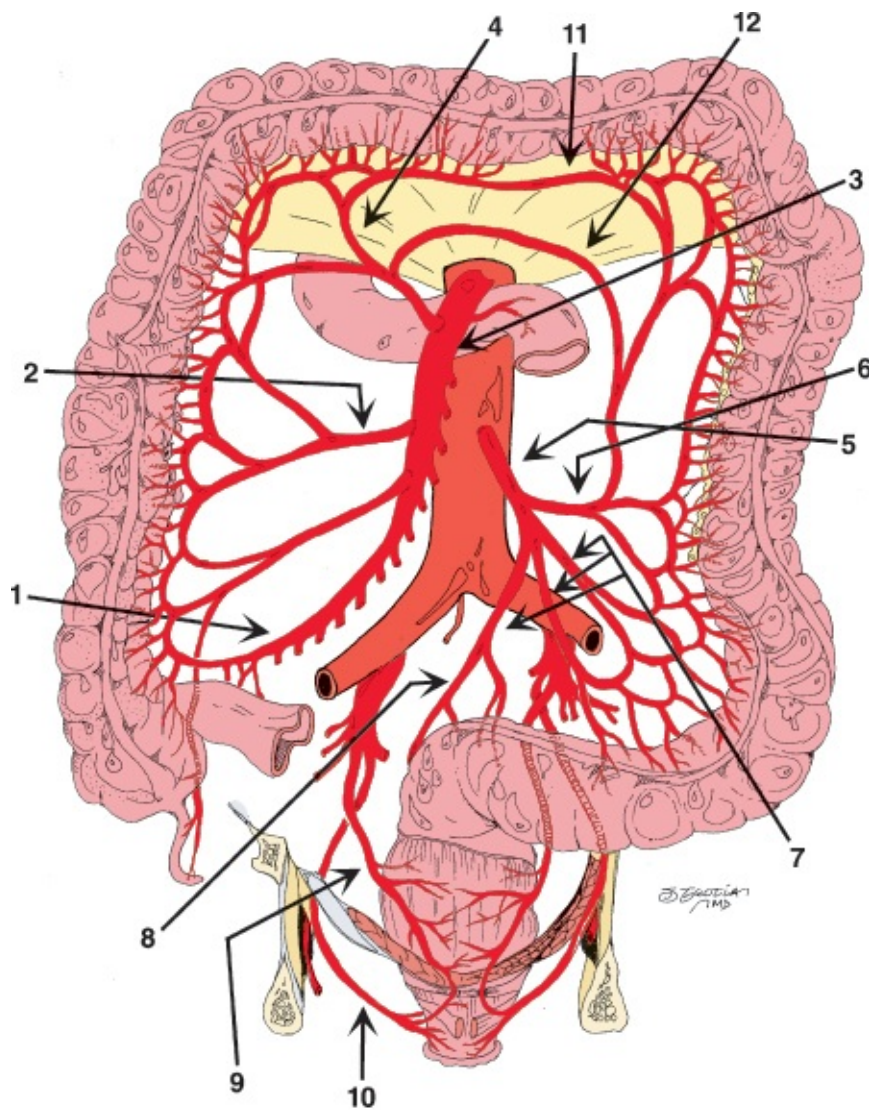
**21-year-old s/p GSW to abdomen with small bowel resections develops tachycardia, fever, and green bilious wound drainage**

Anastomotic leak and enterocutaneous fistula

# Chapter 47 Colon and Rectum

## ANATOMY

**Identify the arterial blood supply to the colon:**



1. Ileocolic artery
2. Right colic artery
3. Superior mesenteric artery (SMA)
4. Middle colic artery
5. Inferior mesenteric artery (IMA)
6. Left colic artery
7. Sigmoidal artery
8. Superior hemorrhoidal artery (superior rectal)
9. Middle hemorrhoidal artery
10. Inferior hemorrhoidal artery
11. Marginal artery of Drummond
12. Meandering artery of Gonzalez

**What are the white lines of Toldt?**

Lateral peritoneal reflections of the ascending and descending colon

**What parts of the GI tract do not have a serosa?**

Esophagus, middle and distal **rectum**

**What are the major anatomic differences between the colon and the small bowel?**

Colon has teniae coli, haustra, and appendices epiploicae (fat appendages), whereas the small intestine is smooth

**What is the blood supply to the rectum:****Proximal?**

Superior hemorrhoidal (or superior rectal) from the IMA

**Middle?**

Middle hemorrhoidal (or middle rectal) from the hypogastric (internal iliac)

**Distal?**

Inferior hemorrhoidal (or inferior rectal) from the pudendal artery (a branch of the hypogastric artery)

**What is the venous drainage of the rectum:****Proximal?**

Via the IMV to the splenic vein, then **to the portal vein**

**Middle?**

Via the iliac vein to the **IVC**

**Distal?**

Via the iliac vein to the **IVC**

## COLORECTAL CARCINOMA

**What is it?**

Adenocarcinoma of the colon or rectum

**What is the incidence?**

Most common GI cancer

Second most common cancer in the United States

Incidence increases with age starting at 40 and peaks at 70 to 80 years

**How common is it as a cause of cancer deaths?**

Second most common cause of cancer deaths

**What is the lifetime risk of colorectal cancer?**

6%

**What is the male-to-female ratio?**

≈1:1

**What are the risk factors?**

**Dietary:** Low-fiber, high-fat diets correlate with increased rates

**Genetic:** Family history is important when taking history

FAP, Lynch's syndrome

**IBD:** Ulcerative colitis > Crohn's disease, age, previous colon cancer

**What is Lynch's syndrome?**

**HNPPC = Hereditary NonPolyposis Colon Cancer**—autosomal-dominant inheritance of high risk for development of colon cancer

**What are current ACS recommendations for polyp/colorectal screening in asymptomatic patients without family (first-degree) history of colorectal cancer?**

Starting at age 50, at least one of the following test regimens is recommended:

Colonoscopy q10 yrs

Double contrast barium enema (DCBE) q5 yrs

Flex sigmoidoscopy q5 yrs

CT colonography q5 yrs

**What are the current recommendations for colorectal cancer screening if there is a history of colorectal cancer in a first-degree relative <60 years old?**

Colonoscopy at age 40, or 10 years before the age at diagnosis of the youngest first-degree relative, and every 5 years thereafter

### **What signs/symptoms are associated with the following conditions:**

#### **Right-sided lesions?**

Right side of bowel has a large luminal diameter, so a tumor may attain a large size before causing problems

Microcytic anemia, occult/melena more than hematochezia PR, postprandial discomfort, fatigue

#### **Left-sided lesions?**

Left side of bowel has smaller lumen and semisolid contents

Change in bowel habits (small-caliber stools), colicky pain, signs of obstruction, abdominal mass, heme(+) or gross red blood

Nausea, vomiting, constipation

### **What is the incidence of rectal cancer?**

Comprises 20% to 30% of all colorectal cancer

### **What are the signs/symptoms of rectal cancer?**

Most common symptom is hematochezia (passage of red blood  $\pm$  stool) or mucus; also tenesmus, feeling of incomplete evacuation of stool (because of the mass), and rectal mass

### **What is the differential diagnosis of a colon tumor/mass?**

Adenocarcinoma, carcinoid tumor, lipoma, liposarcoma, leiomyoma, leiomyosarcoma, lymphoma, diverticular disease, ulcerative colitis, Crohn's disease, polyps

### **Which diagnostic tests are helpful?**

History and physical exam (**Note:  $\approx$ 10% of cancers are palpable on rectal exam**), heme occult, CBC, barium enema, colonoscopy

### **What disease does microcytic anemia signify until proven otherwise in a man or postmenopausal woman?**

Colon cancer

**What tests help find metastases?**

CXR (lung metastases), LFTs (liver metastases), abdominal CT scan (liver metastases), other tests based on history and physical exam (e.g., head CT scan for left arm weakness looking for brain metastasis)

**What is the preoperative workup for colorectal cancer?**

History, physical exam, LFTs, CEA, CBC, Chem 10, PT/PTT, type and cross 2 units PRBCs, CXR, U/A, abdominopelvic CT scan

**By what means does the cancer spread?**

Direct extension: circumferentially and then through bowel wall to later invade other abdominoperineal organs

Hematogenous: portal circulation to liver; lumbar/vertebral veins to lungs

Lymphogenous: regional lymph nodes (LNs)

Transperitoneal

Intraluminal

**Is CEA useful?**

Not for initial screening but for baseline and recurrence surveillance (but offers no proven survival benefit)

**What unique diagnostic test is helpful in patients with rectal cancer?**

Endorectal ultrasound (probe is placed transanally and depth of invasion and nodes are evaluated)

**How are tumors staged?**

TMN staging system

**Explain the TNM stages:****Stage I**

Invades submucosa or muscularis propria (T1–2, N0, M0)

**Stage II**

Invades through muscularis propria or surrounding structures but with negative nodes (T3–4, N0, M0)

### **Stage III**

**Positive nodes**, no distant metastasis (any T, N1–3, M0)

### **Stage IV**

Positive **distant metastasis** (any T, any N, M1)

**What is the approximate 5-year survival by stage:**

#### **Stage I?**

**90%**

#### **Stage II?**

**70%**

#### **Stage III?**

**50%**

#### **Stage IV?**

**10%**

**What percentage of patients with colorectal cancer have liver metastases on diagnosis?**

**≈20%**

**What are the common preoperative IV antibiotics?**

Cefoxitin (Mefoxin®), carbapenem

**If the patient is allergic (hives, swelling), what antibiotics should be prescribed?**

IV Cipro® (ciprofloxacin) and Flagyl® (metronidazole)

**What are the treatment options?**

Resection: wide surgical resection of lesion and its regional lymphatic drainage

**What decides low anterior resection (LAR) versus abdominal perineal resection (APR)?**

Distance from the anal verge, pelvis size

**What do all rectal cancer operations include?**

Total mesorectal excision—remove the rectal mesentery, including the LNs

**What is the minimal surgical margin for rectal cancer?**

2 cm

**How many LNs should be resected with a colon cancer mass?**

12 LNs minimum = for staging, and may improve prognosis

**What is the adjuvant treatment of stage III colon cancer?**

5-FU and leucovorin (or levamisole) chemotherapy (if there is nodal metastasis postoperatively)

**What is the adjuvant treatment for T3–T4 rectal cancer?**

**Preoperative radiation therapy** and 5-FU chemotherapy as a “radiosensitizer”

**What is the most common site of distant (hematogenous) metastasis from colorectal cancer?**

Liver

**What is the treatment of liver metastases from colorectal cancer?**

Resect with  $\geq 1$  cm margins and administer chemotherapy if feasible

**What is the surveillance regimen?**

Physical exam, stool guaiac, CBC, CEA, LFTs (every 3 months for 3 years, then every 6 months for 2 years), CXR every 6 months for 2 years and then yearly, colonoscopy at years 1 and 3 postoperatively, CT scans directed by exam

**Why is follow-up so important the first 3 postoperative years?**

≈90% of colorectal recurrences are within 3 years of surgery

**What are the most common causes of colonic obstruction in the adult population?**

Colon cancer, diverticular disease, colonic volvulus

**What is the 5-year survival rate after liver resection with clean margins for colon cancer liver metastasis?**

≈33% (28% to 50%)

**What is the 5-year survival rate after diagnosis of unresectable colon cancer liver metastasis?**

0%

## COLONIC AND RECTAL POLYPS

**What are they?**

Tissue growth into bowel lumen, usually consisting of mucosa, submucosa, or both

**How are they anatomically classified?**

Sessile (flat)

Pedunculated (on a stalk)

**What are the histologic classifications of the following types:**

**Inflammatory (pseudopolyp)?**

As in Crohn's disease or ulcerative colitis

**Hamartomatous?**

Normal tissue in abnormal configuration

**Hyperplastic?**

Benign—normal cells—no malignant potential

**Neoplastic?**

Proliferation of undifferentiated cells; premalignant or malignant cells

**What are the subtypes of neoplastic polyps?**

Tubular adenomas (usually pedunculated)

Tubulovillous adenomas

Villous adenomas (usually sessile and look like broccoli heads)

**What determines malignant potential of an adenomatous polyp?**

Size

Histologic type

Atypia of cells

**What is the correlation between size and malignancy?**

Polyps >2 cm have a high risk of carcinoma (33% to 55%)

**What about histology and cancer potential of an adenomatous polyp?**

Villous > tubovillous > tubular (Think: **VILL**ous = **VILL**ain)

**What is the approximate percentage of carcinomas found in the following polyps overall:**

**Tubular adenoma?**

5%

**Tubulovillous adenoma?**

20%

**Villous adenoma?**

40%

**Where are most polyps found?**

Rectosigmoid (30%)

**What are the signs/symptoms?**

Bleeding (red or dark blood), change in bowel habits, mucus per rectum, electrolyte loss, totally asymptomatic

**What are the diagnostic tests?**

Colonoscopy

**What is the treatment?**

Endoscopic resection (snared) if polyps; large sessile villous adenomas should be removed with bowel resection and LN resection

## POLYPOSIS SYNDROMES

## ■ Familial Polyposis

**What is another name for this condition?**

Familial Adenomatous Polyposis (**FAP**)

**What are the characteristics?**

Hundreds of adenomatous polyps within the rectum and colon that begin developing at puberty; all undiagnosed; untreated patients develop cancer by ages 40 to 50

**What is the inheritance pattern?**

Autosomal dominant (i.e., 50% of offspring)

**What is the genetic defect?**

Adenomatous Polyposis Coli (APC) gene

**What is the treatment?**

Total proctocolectomy and ileostomy

Total colectomy and rectal mucosal removal (mucosal proctectomy) and ileoanal anastomosis

**With FAP, what other tumor must be looked for?**

Duodenal tumors

## ■ Gardner's Syndrome

**What are the characteristics?**

Neoplastic polyps of the **small bowel** and **colon**; cancer by age 40 in 100% of undiagnosed patients, as in FAP

**What are the other associated findings?**

**Desmoid** tumors (in abdominal wall or cavity), **osteomas** of skull (seen on x-ray), **sebaceous** cysts, adrenal and thyroid tumors, retroperitoneal fibrosis, duodenal and periampullary tumors

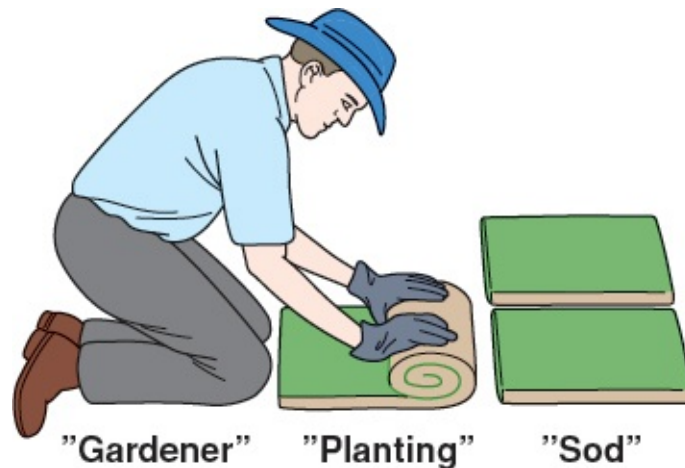## How can the findings associated with Gardner's syndrome be remembered?

Think of a gardener planting "SOD":

Sebaceous cysts

Osteomas

Desmoid tumors



## What is a desmoid tumor?

Tumor of the musculoaponeurotic sheath, usually of the abdominal wall; benign, but grows locally; treated by wide resection

## What medications may slow the growth of a desmoid tumor?

Tamoxifen, sulindac, steroids

## What is the inheritance pattern?

Varying degree of penetrance from an autosomal-dominant gene

## What is the treatment of colon polyps in patients with Gardner's syndrome?

Total proctocolectomy and ileostomy

Total colectomy and rectal mucosal removal (mucosal proctectomy) and ileoanal anastomosis

## ■ Peutz–Jeghers' Syndrome

**What are the characteristics?**

Hamartomas throughout the GI tract (jejunum/ileum > colon > stomach)

**What is the associated cancer risk from polyps?**

Increased

**What is the associated cancer risk for women with Peutz–Jeghers’?**

Ovarian cancer (granulosa cell tumor is most common)

**What is the inheritance pattern?**

Autosomal dominant

**What are the other signs?**

Melanotic pigmentation (black/brown) of buccal mucosa (mouth), lips, digits, palms, feet (soles)

(Think: **P**eutz = **P**igmented)

**What is the treatment?**

Removal of polyps, if symptomatic (i.e., bleeding, intussusception, or obstruction) or large (>1.5 cm)

**What are juvenile polyps?**

Benign hamartomas in the small bowel and colon; not premalignant (a.k.a. “retention polyps”)

**What is Cronkhite–Canada syndrome?**

Diffuse GI hamartoma polyps (i.e., no cancer potential) associated with malabsorption/weight loss, diarrhea, and **loss of electrolytes/protein**; signs include alopecia, nail atrophy, skin pigmentation

**What is Turcot’s syndrome?**

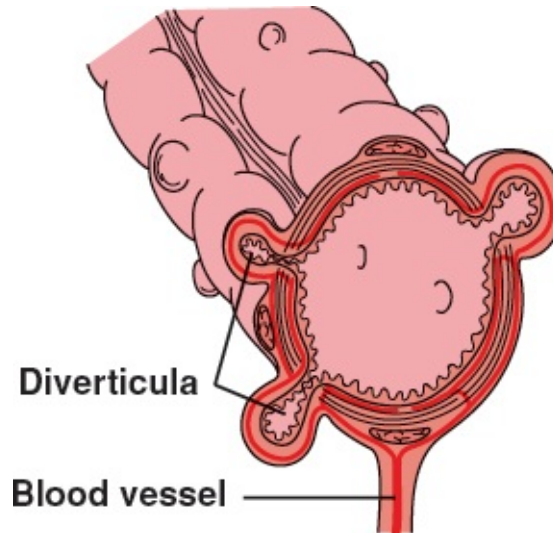
Colon polyps with malignant **CNS tumors** (glioblastoma multiforme)

## DIVERTICULAR DISEASE OF THE COLON

### ■ Diverticulosis

## What is diverticulosis?

Condition in which diverticula can be found within the colon, especially the sigmoid; diverticula are actually **false diverticula** in that only mucosa and submucosa herniate through the bowel musculature; true diverticula involve all layers of the bowel wall and are rare in the colon



## Describe the pathophysiology

**Weakness** in the bowel wall develops at points where nutrient **blood vessels** enter between antimesenteric and mesenteric teniae; increase intraluminal pressures then cause herniation through these areas

## What is the incidence?

≈50% to 60% in the United States by age 60, with only 10% to 20% becoming symptomatic

## What is the most common site?

95% of people with diverticulosis have **sigmoid** colon involvement

## Who is at risk?

People with **low-fiber diets**, chronic constipation, and a positive family history; incidence increases with age

## What are the symptoms/complications?

**Bleeding:** may be massive

Diverticulitis, asymptomatic (80% of cases)

## **What is the diagnostic approach:**

### **Bleeding?**

Without signs of inflammation: colonoscopy

### **Pain and signs of inflammation?**

Abdominal/pelvic CT scan

## **What is the treatment of diverticulosis?**

High-fiber diet is recommended

## **What are the indications for operation with diverticulosis?**

Complications of diverticulitis (e.g., fistula, obstruction, stricture); recurrent episodes; hemorrhage; suspected carcinoma; prolonged symptoms; abscess not drainable by percutaneous approach

## **When is it safe to get a colonoscopy or barium enema/sigmoidoscopy?**

Due to risk of perforation, this is performed 6 weeks after inflammation resolves to rule out colon cancer

## **Diverticulitis**

### **What is it?**

Infection or perforation of a diverticulum

### **What is the pathophysiology?**

**Obstruction** of diverticulum by a fecalith leading to inflammation and microperforation

### **What are the signs/symptoms?**

LLQ pain (cramping or steady), change in bowel habits (**diarrhea**), fever, chills, anorexia, LLQ mass, nausea/vomiting, dysuria

### **What are the associated lab findings?**

Increased WBCs

**What are the associated radiographic findings?**

On x-ray: ileus, partially obstructed colon, air-fluid levels, free air if perforated

On abdominal/pelvic CT scan: swollen, edematous bowel wall; particularly helpful in diagnosing an abscess

**What are the associated barium enema findings?**

Barium enema should be avoided in acute cases

**Is colonoscopy safe in an acute setting?**

No, there is increased risk of perforation

**What are the possible complications?**

Abscess, diffuse peritonitis, fistula, obstruction, perforation, stricture

**What is the most common fistula with diverticulitis?**

Colovesical fistula (to bladder)

**What is the best test for diverticulitis?**

CT scan

**What is the initial therapy?**

IV fluids, NPO, broad-spectrum antibiotics with anaerobic coverage, NG suction (as needed for emesis/ileus)

**When is surgery warranted?**

Obstruction, fistula, free perforation, abscess not amenable to percutaneous drainage, sepsis, deterioration with initial conservative treatment

**What is the lifelong risk of recurrence after:****First episode?**

33%

**Second episode?**

50%

**What are the indications for elective resection?**

Case by case decisions, but usually after two episodes of diverticulitis; should be

considered after the **first** episode in a young, diabetic, or immunosuppressed patient or to rule out cancer

**What surgery is usually performed ELECTIVELY for recurrent bouts?**

One-stage operation: resection of involved segment and primary anastomosis (with preoperative bowel prep)

**What type of surgery is usually performed for an acute case of diverticulitis with a complication?**

- . **Hartmann's procedure:** resection of involved segment with an end colostomy and stapled rectal stump
- . Resection, primary anastomosis loop ileostomy

**What is the treatment of diverticular abscess?**

Percutaneous drainage; if abscess is not amenable to percutaneous drainage, then surgical approach for drainage is necessary

**How common is massive lower GI bleeding with diverticulitis?**

Very **rare!** Massive lower GI bleeding is seen with diverticulosis, not diverticulitis

**What are the most common causes of massive lower GI bleeding in adults?**

Diverticulosis (especially right sided), vascular ectasia

**What must you rule out in any patient with diverticulitis/diverticulosis?**

Colon cancer

## ■ Colonic Volvulus

**What is it?**

**Twisting of colon on itself** about its mesentery, resulting in obstruction and, if complete, vascular compromise with potential necrosis, perforation, or both

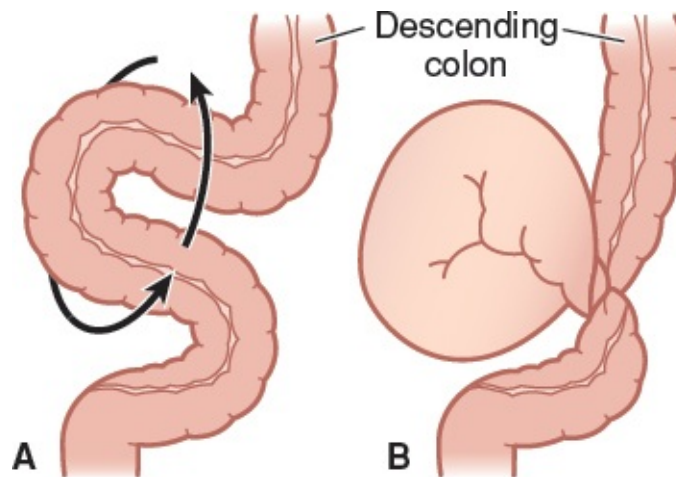
## What is the most common type of colonic volvulus?

Sigmoid volvulus (makes sense because the sigmoid is a redundant/“floppy” structure!)

## ■ Sigmoid Volvulus

### What is it?

Volvulus or “twist” in the sigmoid colon



### What is the incidence?

≈75% of colonic volvulus cases (Think: Sigmoid = Superior)

### What are the etiologic factors?

High-residue diet resulting in bulky stools and tortuous, elongated colon; chronic constipation; laxative abuse; pregnancy; seen most commonly in bedridden elderly or institutionalized patients, many of whom have history of prior abdominal surgery or distal colonic obstruction

### What are the signs/symptoms?

Acute abdominal pain, progressive abdominal distention, anorexia, obstipation, cramps, nausea/vomiting

### What findings are evident on abdominal plain film?

Distended loop of sigmoid colon, often in the classic “bent inner tube” or “omega” sign with the loop aiming toward the RUQ

### **What are the signs of necrotic bowel in colonic volvulus?**

Free air, pneumatosis (air in bowel wall)

### **How is the diagnosis made?**

CT scan, sigmoidoscopy, or radiographic exam with Gastrografin® enema

### **Under what conditions is Gastrografin® enema useful?**

If sigmoidoscopy and plain films fail to confirm the diagnosis; “**bird’s beak**” is pathognomonic seen on enema contrast study as the contrast comes to a sharp end

### **What are the signs of strangulation?**

Discolored or hemorrhagic mucosa on sigmoidoscopy, bloody fluid in the rectum, frank ulceration or necrosis at the point of the twist, peritoneal signs, fever, hypotension, ↑ WBCs

### **What is the initial treatment?**

**Nonoperative:** If there is no strangulation, sigmoidoscopic reduction is successful in ≈85% of cases; enema study will occasionally reduce (5%)

### **What is the percentage of recurrence after nonoperative reduction of a sigmoid volvulus?**

≈40%!

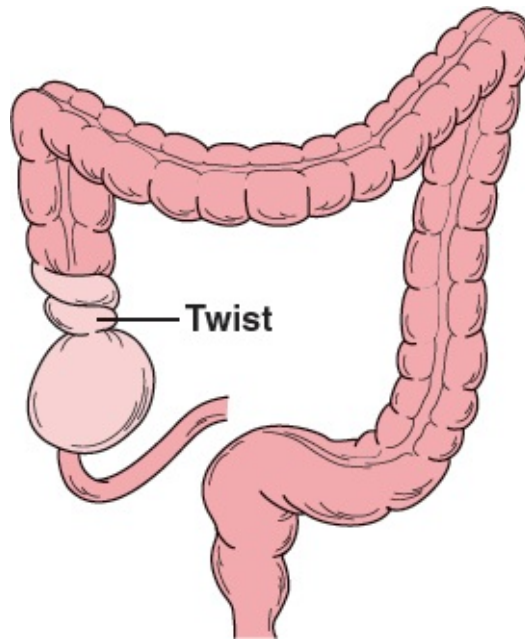
### **What are the indications for surgery?**

Emergently if strangulation is suspected or nonoperative reduction unsuccessful (Hartmann’s procedure); most patients should undergo resection during same hospitalization of redundant sigmoid after successful nonoperative reduction because of high recurrence rate (40%)

## **Cecal Volvulus**

### **What is it?**

Twisting of the cecum upon itself and the mesentery



### **What is a cecal “bascule” volvulus?**

Instead of the more common axial twist, the cecum folds upward (lies on the ascending colon)

### **What is the incidence?**

≈25% of colonic volvulus (i.e., much less common than sigmoid volvulus)

### **What is the etiology?**

Idiopathic, poor fixation of the right colon, many patients have history of abdominal surgery

### **What are the signs/symptoms?**

Acute onset of abdominal or colicky pain beginning in the RLQ and progressing to a constant pain, vomiting, obstipation, abdominal distention, and SBO; many patients will have had previous similar episodes

### **How is the diagnosis made?**

Abdominal plain film; dilated, ovoid colon with large air/fluid level in the RLQ often forming the classic “**coffee bean**” sign with the apex aiming toward the epigastrium or LUQ (must rule out gastric dilation with NG aspiration)

### **What diagnostic studies should be performed?**

Water-soluble contrast study (Gastrografin®), if diagnosis cannot be made by

AXR, CT scan

### **What is the treatment?**

Emergent surgery, right colectomy with primary anastomosis or ileostomy and mucous fistula (primary anastomosis may be performed in stable patients)

### **What are the major differences in the EMERGENT management of cecal volvulus versus sigmoid?**

Patients with cecal volvulus require **surgical** reduction, whereas the vast majority of patients with sigmoid volvulus undergo initial **endoscopic** reduction of the twist

## **RAPID FIRE REVIEW**

### **Name the most likely diagnosis:**

**67-year-old male smoker on Coumadin® for chronic DVT notices LLQ pain after a strenuous coughing spell; LLQ mass detected on physical exam**

Rectus sheath hematoma

### **What is the treatment?**

**60-year-old male with LLQ pain and “parrot’s beak” on x-ray c/w sigmoid volvulus**

Proctosigmoidoscopy to decompress initially

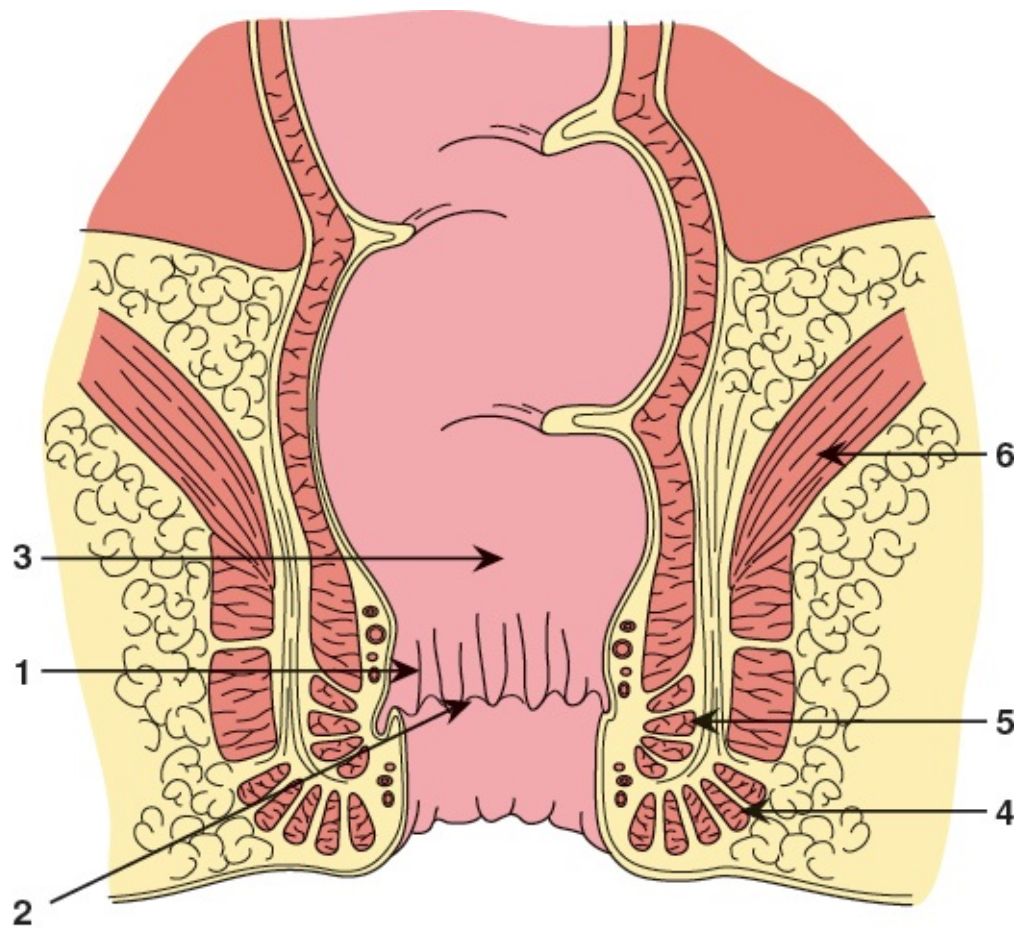
**78-year-old male with RLQ and “coffee bean” colonic dilation on x-ray c/w cecal volvulus**

Ex lap with resection with primary anastomosis or ileostomy

# Chapter 48 Anus

## ANATOMY

Identify the following:



1. Anal columns
2. Dentate line
3. Rectum
4. External sphincter
5. Internal sphincter
6. Levator ani muscle

# ANAL CANCER

## **What is the most common carcinoma of the anus?**

Squamous cell carcinoma (80%)

(Think: **ASS** = Anal Squamous Superior)

## **What cell types are found in carcinomas of the anus?**

- . Squamous cell carcinoma (80%)
- . Cloacogenic (transitional cell)
- . Adenocarcinoma/melanoma/mucoepidermal

## **What is the incidence of anal carcinoma?**

Rare (1% of colon cancers incidence)

## **What is anal Bowen's disease?**

Squamous cell carcinoma in situ

(Think: **B.S.** = Bowen Squamous)

## **How is Bowen's disease treated?**

With local wide excision

## **What is Paget's disease of the anus?**

Adenocarcinoma in situ of the anus

(Think: **P.A.** = Paget's Adenocarcinoma)

## **How is Paget's disease treated?**

With local wide excision

## **What are the risk factors for anal cancer?**

Human papilloma virus, condyloma, herpes, HIV, chronic inflammation (fistulae/Crohn's disease) immunosuppression, homosexuality in males, cervical/vaginal cancer, STDs, smoking

## **What is the most common symptom of anal carcinoma?**

Anal bleeding

## **What are the other signs/symptoms of anal carcinoma?**

Pain, mass, mucus per rectum, pruritus

**What percentage of patients with anal cancer is asymptomatic?**

≈25%

**To what locations do anal canal cancers metastasize?**

Lymph nodes, liver, bone, lung

**What is the lymphatic drainage below the dentate line?**

Below to inguinal lymph nodes (above to pelvic chains)

**Are most patients with anal cancer diagnosed early or late?**

Late (diagnosis is often missed)

**What is the workup of a patient with suspected anal carcinoma?**

History

Physical exam: digital rectal exam, proctoscopic exam, and colonoscopy

Biopsy of mass

Abdominal/pelvic CT scan, transanal U/S

CXR

LFTs

**Define:**

**Margin cancer**

Anal verge out 5 cm onto the perianal skin

**Canal cancer**

Proximal to anal verge up to the border of the internal sphincter

**How is an anal canal epidermal carcinoma treated?**

NIGRO protocol:

1. Chemotherapy (5-FU and mitomycin C)
2. Radiation
3. Postradiation therapy scar biopsy (6 to 8 weeks post radiation therapy [XRT])

**What percentage of patients have a “complete” response with the**

**NIGRO protocol?**

90%

**What is the 5-year survival with the NIGRO protocol?**

85%

**What is the treatment for local recurrence of anal cancer after the NIGRO protocol?**

May repeat chemotherapy/XRT or salvage Abdominoperineal resection (APR)

**How is a small (<5 cm) anal margin cancer treated?**

Surgical excision with 1-cm margins

**How is a large (>5 cm) anal margin cancer treated?**

Chemoradiation

**What is the treatment of anal melanoma?**

Wide excision or APR (especially if tumor is large) ± XRT, chemotherapy, postoperatively

**What is the 5-year survival rate with anal melanoma?**

<10%

**How many patients with anal melanoma have an amelanotic anal tumor?**

Approximately one third, thus making diagnosis difficult without pathology

**What is the prognosis of anal melanoma?**

<5% 5-year survival rate

## **Fistula in Ano**

**What is it?**

Anal fistula, from rectum to perianal skin

**What are the causes?**

Usually anal crypt/gland infection (usually perianal abscess)

### **What are the signs/symptoms?**

Perianal drainage, perirectal abscess, recurrent perirectal abscess, “diaper rash,” itching

### **What disease should be considered with fistula in ano?**

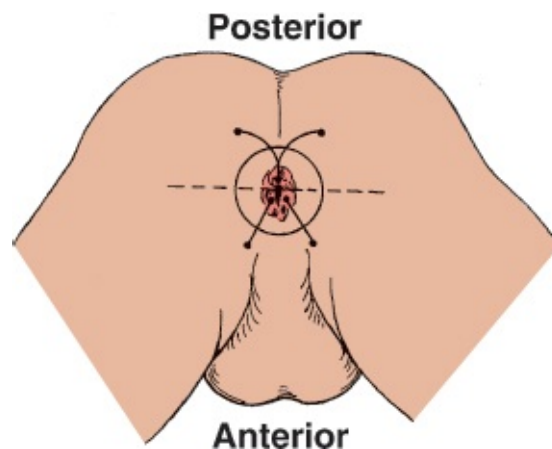
Crohn’s disease

### **How is the diagnosis made?**

Exam, proctoscope

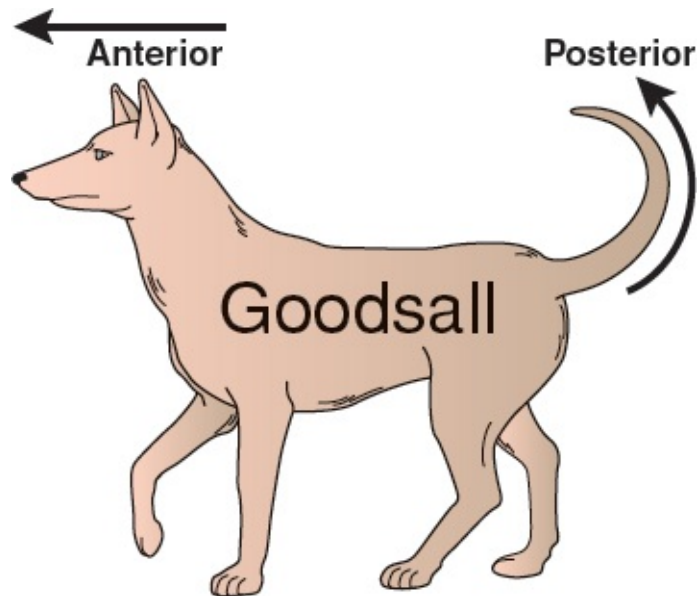
### **What is Goodsall’s rule?**

Fistulas originating **anterior** to a transverse line through the anus will course **straight** ahead and exit anteriorly, whereas those exiting **posteriorly** have a **curved** tract



### **How can Goodsall’s rule be remembered?**

Think of a dog with a **straight** nose (anterior) and **curved** tail (posterior)

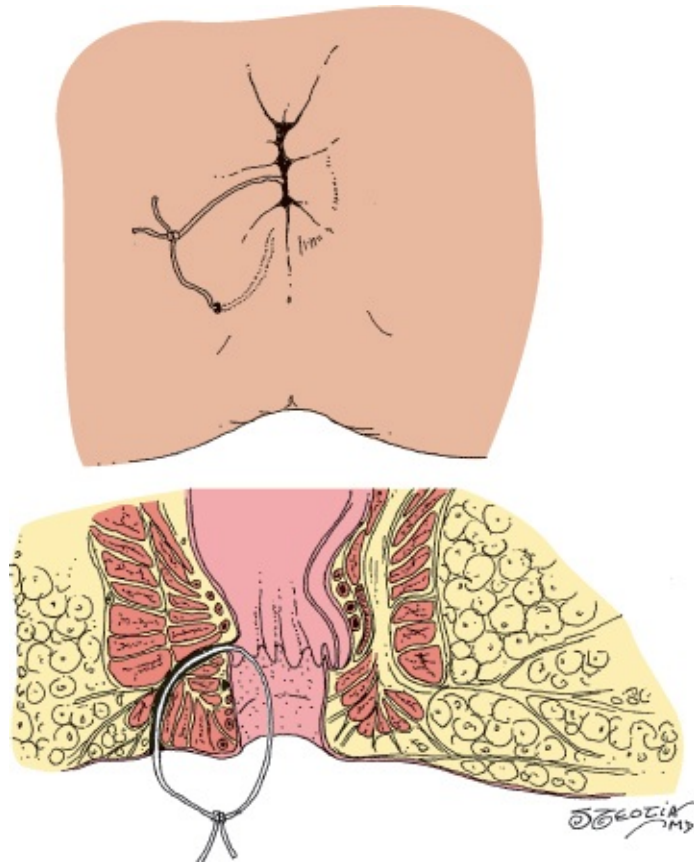


### **What is the management of anorectal fistulas?**

- . Define the anatomy
- . Marsupialization of fistula tract (i.e., fillet tract open)
- . Wound care: routine sitz baths and dressing changes
- . Seton placement if fistula is through the sphincter muscle

### **What is a seton?**

Thick suture placed through fistula tract to allow slow transection of sphincter muscle; scar tissue formed will hold the sphincter muscle in place and allow for continence after transection



**What percentage of patients with a perirectal abscess develop a fistula in ano after drainage?**

≈50%

**How do you find the internal rectal opening of an anorectal fistula in the O.R.?**

Inject  $H_2O_2$  (or methylene blue) in external opening—then look for bubbles (or blue dye) coming out of internal opening!

**What is a sitz bath?**

Sitting in a warm bath (usually done after bowel movement and TID)

## ■ Perirectal Abscess

**What is it?**

Abscess formation around the anus/rectum

**What are the signs/symptoms?**

Rectal pain, drainage of pus, fever, perianal mass

**How is the diagnosis made?**

Physical/digital exam reveals perianal/rectal submucosal mass/fluctuance

**What is the cause?**

Crypt abscess in dentate line with spread

**What is the treatment?**

As with all abscesses (except simple liver amebic abscess) **drainage**, sitz bath, anal hygiene, stool softeners

**What is the indication for postoperative IV antibiotics for drainage?**

Cellulitis, immunosuppression, diabetes, heart valve abnormality

**What percentage of patients develops a fistula in ano during the 6 months after surgery?**

≈50%

## Anal Fissure

**What is it?**

Tear or fissure in the anal epithelium

**What is the most common site?**

Posterior midline (comparatively low blood flow)

**What is the cause?**

Hard stool passage (constipation), hyperactive sphincter, disease process (e.g., Crohn's disease)

**What are the signs/symptoms?**

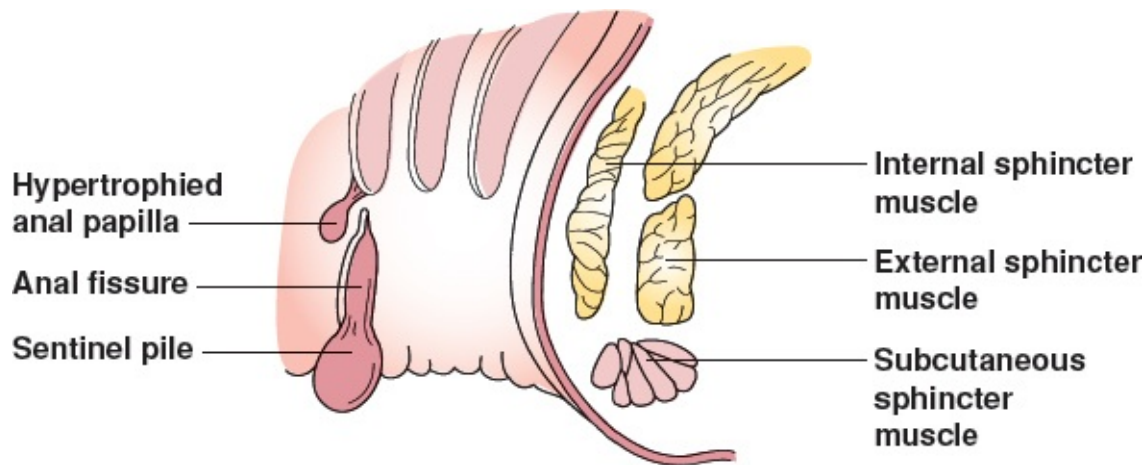
Pain in the anus, painful (can be excruciating) bowel movement, rectal bleeding, blood on toilet tissue after bowel movement, sentinel tag, tear in the anal skin, extremely painful rectal exam, sentinel pile, hypertrophic papilla

### **What is a sentinel pile?**

Thickened mucosa/skin at the distal end of an anal fissure that is often confused with a small hemorrhoid

### **What is the anal fissure triad for a chronic fissure?**

- . Fissure
- . Sentinel pile
- . Hypertrophied anal papilla



### **What is the conservative treatment?**

Sitz baths, stool softeners, high fiber diet, excellent anal hygiene, topical nifedipine, Botox®

### **What disease processes must be considered with a chronic anal fissure?**

Crohn's disease, anal cancer, sexually transmitted disease, ulcerative colitis, AIDS

### **What are the indications for surgery?**

Chronic fissure refractory to conservative treatment

### **What is one surgical option?**

Lateral internal sphincterotomy (LIS)—cut the internal sphincter to release it from spasm

### **What is the “rule of 90%” for anal fissures?**

90% occur posteriorly

90% heal with medical treatment alone  
90% of patients who undergo an LIS heal successfully

## ■ Perianal Warts

### **What are they?**

Warts around the anus/perineum

### **What is the cause?**

Condyloma acuminatum (human papillomavirus)

### **What is the major risk?**

Squamous cell carcinoma

### **What is the treatment if warts are small?**

Topical podophyllin, imiquimod (Aldara®)

### **What is the treatment if warts are large?**

Surgical resection or laser ablation

## ■ Hemorrhoids

### **What are they?**

Engorgement of the venous plexuses of the rectum, anus, or both; with protrusion of the mucosa, anal margin, or both

### **Why do we have “healthy” hemorrhoidal tissue?**

It is thought to be involved with fluid/air continence

### **What are the signs/symptoms?**

Anal mass/prolapse, bleeding, itching, pain

### **Which type, internal or external, is painful?**

External, below the dentate line

**If a patient has excruciating anal pain and history of hemorrhoids, what is the likely diagnosis?**

Thrombosed external hemorrhoid (treat by excision)

**What are the causes of hemorrhoids?**

Constipation/straining, portal hypertension, pregnancy

**What is an internal hemorrhoid?**

Hemorrhoid above the (proximal) dentate line

**What is an external hemorrhoid?**

Hemorrhoid below the dentate line

**What are the three “hemorrhoid quadrants”?**

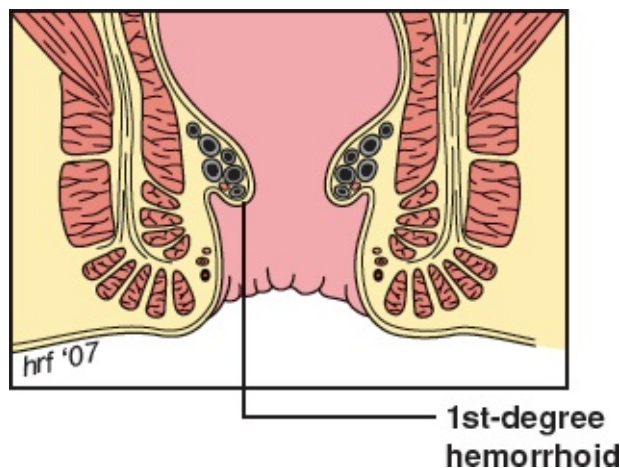
- . Left lateral
- . Right posterior
- . Right anterior

### ► *Classification by Degrees*

**Define the following terms for internal hemorrhoids:**

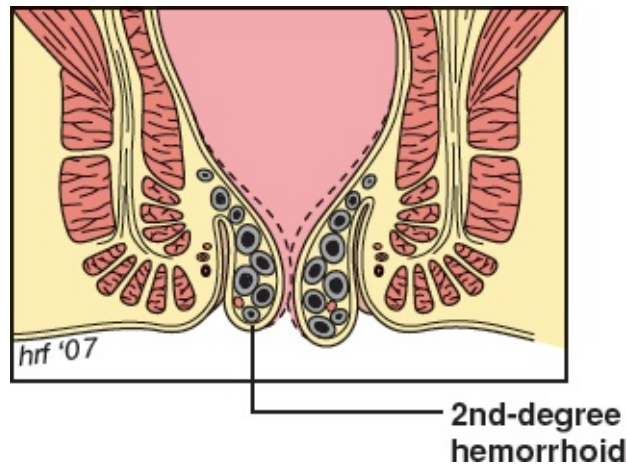
**First-degree hemorrhoid**

Hemorrhoid that does not prolapse



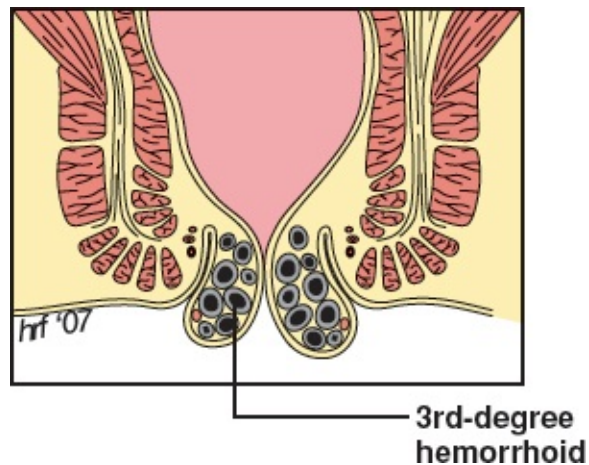
**Second-degree hemorrhoid**

Prolapses with defecation, but returns on its own



### Third-degree hemorrhoid

Prolapses with defecation or any type of Valsalva maneuver and requires active manual reduction (eat fiber!)



### Fourth-degree hemorrhoid

Prolapsed hemorrhoid that cannot be reduced

### What is the treatment?

High-fiber diet, anal hygiene, topical steroids, sitz baths

Rubber band ligation (in most cases anesthetic is not necessary for internal hemorrhoids)

Surgical resection for large refractory hemorrhoids, infrared coagulation, harmonic scalpel

### What is a “closed” versus an “open” hemorrhoidectomy?

Closed (Ferguson) “closes” the mucosa with sutures after hemorrhoid tissue removal

Open (Milligan–Morgan) leaves mucosa “open”

### **What are the dreaded complications of hemorrhoidectomy?**

Exsanguination (bleeding may pool proximally in lumen of colon without any signs of external bleeding)

Pelvic infection (may be extensive and potentially fatal)

Incontinence (injury to sphincter complex)

Anal stricture

### **What condition is a contraindication for hemorrhoidectomy?**

Crohn’s disease

### **Classically, what must be ruled out with lower GI bleeding believed to be caused by hemorrhoids?**

Colon cancer (colonoscopy)

## **RAPID FIRE REVIEW**

**Name the most likely diagnosis:**

**56-year-old woman with hemorrhoids that prolapse with defecation but then retract by themselves**

Second-degree internal hemorrhoids

**34-year-old woman with hemorrhoids that prolapse after defecation and that she has to “push back in”**

Third-degree internal hemorrhoids

**56-year-old woman with hemorrhoids that are “stuck out” after a bowel movement**

Fourth-degree internal hemorrhoid

**22-year-old female with bright red blood from her rectum with history of extremely painful bowel movements**

Anal fissure

# Chapter 49 Lower GI Bleeding

## **What is the definition of lower GI bleeding?**

Bleeding distal to the ligament of Treitz; vast majority occurs in the colon

## **What are the symptoms?**

**Hematochezia (bright red blood per rectum [BRBPR])**, with or without abdominal pain, melena, anorexia, fatigue, syncope, shortness of breath, shock

## **What are the signs?**

BRBPR, positive hemoccult, abdominal tenderness, hypovolemic shock, orthostasis

## **What are the causes?**

Diverticulosis (usually **right**-sided in severe hemorrhage), vascular ectasia, colon cancer, hemorrhoids, trauma, hereditary hemorrhagic telangiectasia, intussusception, volvulus, ischemic colitis, IBD (especially ulcerative colitis), anticoagulation, rectal cancer, Meckel's diverticulum (with ectopic gastric mucosa), stercoral ulcer (ulcer from hard stool), infectious colitis, aortoenteric fistula, chemotherapy, irradiation injury, infarcted bowel, strangulated hernia, anal fissure

## **What medicines should be looked for causally with a lower GI bleed?**

Coumadin®, aspirin, Plavix®

## **What are the most common causes of massive lower GI bleeding?**

- . Diverticulosis
- . Vascular ectasia

## **What lab tests should be performed?**

CBC, Chem-7, PT/PTT, type and cross

**What is the initial treatment?**

IVFs: Lactated Ringer's; packed red blood cells as needed, IV  $\times$  2, Foley catheter to follow urine output, discontinue aspirin, NGT

**What diagnostic tests should be performed for all lower GI bleeds?**

History, physical exam, NGT aspiration (to rule out UGI bleeding; bile or blood must be seen; otherwise, perform EGD), anoscopy/proctoscopic exam

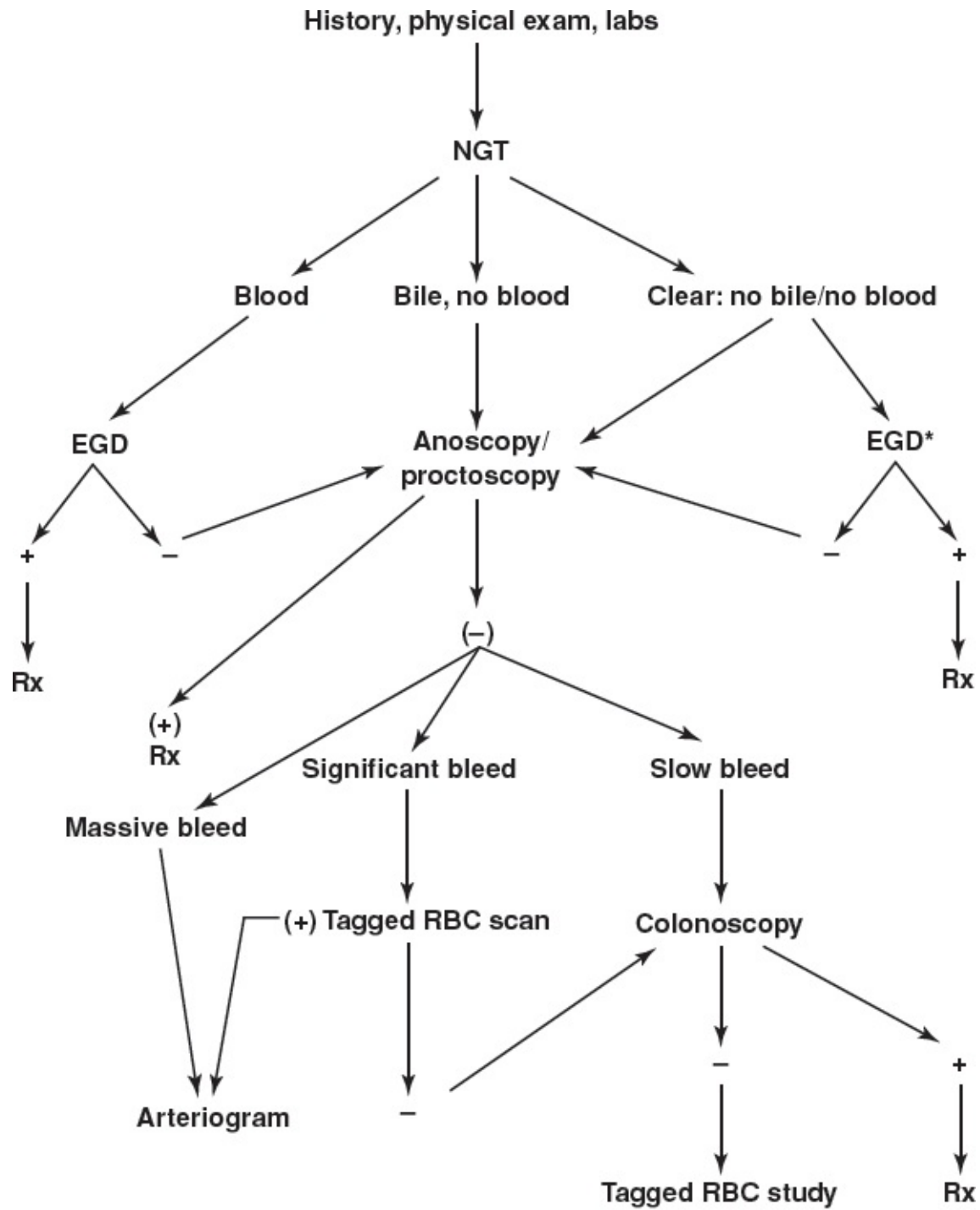
**What must be ruled out in patients with lower GI bleeding?**

**Upper GI bleeding!** Remember, NGT aspiration is not 100% accurate (even if you get bile without blood)

**How can you have a UGI bleed with only clear succus back in the NGT?**

Duodenal bleeding ulcer can bleed distal to the pylorus with the NGT sucking normal nonbloody gastric secretions! **If there is any question, perform EGD**

**What would an algorithm for diagnosing and treating lower GI bleeding look like?**



\*Based on clinical suspicion

**What is the diagnostic test of choice for localizing a slow to moderate lower GI bleeding source?**

Colonoscopy

**What test is performed to localize bleeding if there is too much active bleeding to see the source with a colonoscope?**

A-gram (mesenteric angiography)

**What is more sensitive for a slow, intermittent amount of blood loss: A-gram or tagged RBC study?**

Radiolabeled RBC scan is more sensitive for blood loss at a rate of  $\geq 0.5$  mL/min or intermittent blood loss because it has a longer half-life (for arteriography, bleeding rate must be  $\geq 1.0$  mL/min)

**What is the treatment if bleeding site is KNOWN and massive or recurrent lower GI bleeding continues?**

Segmental resection of the bowel

**What is the surgical treatment of massive lower GI bleeding WITHOUT localization?**

Exploratory laparotomy with intraoperative enteroscopy and total abdominal colectomy as last resort

**What percentage of cases spontaneously stop bleeding?**

80% to 90% stop bleeding with resuscitative measures only (at least temporarily)

**What percentage of patients require emergent surgery for lower GI bleeding?**

Only  $\approx 10\%$

**Does melena always signify active colonic bleeding?**

NO—the colon is very good at storing material and often will store melena/maroon stools and pass them days later (follow patient, UO, HCT, and vital signs)

**What is the therapeutic advantage of doing a colonoscopy?**

Options of injecting substance (epinephrine) or coagulating vessels is an advantage with C-scope to control bleeding

**What is the therapeutic advantage of doing an A-gram?**

Ability to inject vasopressin and/or embolization, with at least temporary control of bleeding in  $>85\%$

## RAPID FIRE REVIEW

**Name the diagnostic modality:**

**45-year-old male with dark blood per rectum**

NGT aspiration to evaluate for upper GI bleed (if blood, then EGD; if bile and no blood, then work up for lower GI bleed)

**45-year-old male with significant massive blood per rectum; NGT reveals bile and no blood**

Angiography to find lower GI source

# Chapter 50 Inflammatory Bowel Disease: Crohn's Disease and Ulcerative Colitis

## What is IBD?

Inflammatory **B**owel **D**isease, inflammatory disease of the GI tract

## What are the two inflammatory bowel diseases?

Crohn's disease and ulcerative colitis

## How can the extraintestinal manifestations be remembered?

Think of the acronym **"A PIE SACK"**:

Aphthous ulcers

Pyoderma gangrenosum

Iritis

Erythema nodosum

Sclerosing cholangitis

Arthritis, Ankylosing spondylitis

Clubbing of fingers

Kidney (amyloid deposits, nephrotic syndrome)

## COMPARISON OF CROHN'S DISEASE AND ULCERATIVE COLITIS

### ■ Incidence

Crohn's disease:

Incidence

3–6/100,000

**At-risk population**

High in the Jewish population, low in the African black population, similar rates between African American and U.S. white populations

**Sex?**

Female > male

**Distribution?**

Bimodal distribution (i.e., two peaks in incidence): peak incidence at 25 to 40 years of age; second bimodal distribution peak at 50 to 65 years of age

**Ulcerative colitis:**

**Incidence?**

10/100,000

**At-risk population**

High in the Jewish population, low in the African American population  
Positive family history in 20% of cases

**Sex?**

Male > female

**Distribution?**

Bimodal distribution at 20 to 35 and 50 to 65 years of age

## ■ Initial Symptoms

**Crohn's disease?**

Abdominal pain, diarrhea, fever, weight loss, anal disease

**Ulcerative colitis?**

Bloody diarrhea (hallmark), fever, weight loss

---

## ■ Anatomic Distribution

### **Crohn's disease?**

Classic phrasing “**mouth to anus**”

Small bowel only (20%)

Small bowel and colon (40%)

Colon only (30%)

### **Ulcerative colitis?**

Colon only (Think: ulcerative **COL**itis = **COL**on alone)

## ■ Route of Spread

### **Crohn's disease?**

Small bowel, colon, or both with “**skip areas**” of normal bowel; hence, the name “regional enteritis”

### **Ulcerative colitis?**

Almost always involves the rectum and spreads proximally always in a continuous route without “skip areas”

### **What is “backwash” ileitis?**

Mild inflammation of the terminal ileum in ulcerative colitis; thought to be “backwash” of inflammatory mediators from the colon into the terminal ileum

## ■ Bowel Wall Involvement

### **Crohn's disease?**

Full thickness (transmural involvement)

### **Ulcerative colitis?**

Mucosa/submucosa only

## ■ Anal Involvement

### **Crohn's disease?**

Common (fistulae, abscesses, fissures, ulcers)

### **Ulcerative colitis?**

Uncommon

## ■ Rectal Involvement

### **Crohn's disease?**

Rare

### **Ulcerative colitis?**

100%

## ■ Mucosal Findings

### **Crohn's disease (6)?**

- . Aphthoid ulcers
- . Granulomas
- . Linear ulcers
- . Transverse fissures
- . Swollen mucosa
- . **Full-thickness wall involvement**

### **Ulcerative colitis (5)?**

- . Granular, flat mucosa
- . Ulcers
- . **Crypt abscess**
- . Dilated mucosal vessels
- . **Pseudopolyps**

**How can ulcerative colitis and Crohn's anal and wall involvement be remembered?**

“CAT URP”:

Crohn's = **A**nal—**T**ransmural

UC = **R**ectum—**P**artial wall thickness

## ■ Diagnostic Tests

**Crohn's disease?**

Colonoscopy with biopsy, barium enema, UGI with small bowel follow through, stool cultures

**Ulcerative colitis?**

Colonoscopy, barium enema, UGI with small bowel follow through (to look for Crohn's disease), stool cultures

## ■ Complications

**Crohn's disease?**

**Anal** fistula/abscess, **fistula**, stricture, perforation, **abscesses**, toxic megacolon, colovesical fistula, enterovaginal fistula, hemorrhage, **obstruction**, cancer

**Ulcerative colitis?**

**Cancer**, **toxic megacolon**, **colonic perforation**, **hemorrhage**, strictures, obstruction, complications of surgery

## ■ Cancer Risk

**Crohn's disease?**

Overall increased risk, but about half that of ulcerative colitis

**Ulcerative colitis?**

≈5% risk of developing colon cancer at 10 years; then, risk increases ≈1% per year; thus, an incidence of ≈20% after 20 years of the disease (30% at 30 years)

## ■ Incidence of Toxic Megacolon

### **Crohn's disease?**

≈5%

### **Ulcerative colitis?**

≈10%

## ■ Indications for Surgery

### **Crohn's disease?**

Obstruction, massive bleeding, fistula, perforation, suspicion of cancer, abscess (refractory to medical treatment), toxic megacolon (refractory to medical treatment), strictures, dysplasia

### **Ulcerative colitis?**

Toxic megacolon (refractory to medical treatment); cancer prophylaxis; massive bleeding; failure of child to mature because of disease and steroids; perforation; suspicion of or documented cancer; acute severe symptoms refractory to medical treatment; inability to wean off of chronic steroids; obstruction; dysplasia; stricture

### **What are the common surgical options for ulcerative colitis?**

- . Total proctocolectomy, distal rectal mucosectomy, and ileoanal pull through
- . Total proctocolectomy and Brooke ileostomy

### **What is “toxic megacolon”?**

**Toxic patient:** sepsis, febrile, abdominal pain

**Megacolon:** acutely and massively distended colon

## ■ Medical Treatment of IBD

**What are the medication options for treating IBD?**

**Sulfasalazine**, mesalamine (5-aminosalicylic acid)

**Steroids**, metronidazole (Flagyl®), azathioprine, 6-mercaptopurine (6-mp),  
infliximab

**Which medications are used for Crohn's Disease but not ulcerative colitis?**

Methotrexate, Antibiotics (e.g., Flagyl®/Cipro®)

**What are infliximab, adalimumab, certolizumab, natalizumab?**

Monoclonal antibodies versus TNF- $\alpha$  (tumor necrosis factor-alpha)

## RAPID FIRE REVIEW

**Name the most likely diagnosis:**

**24-year-old man with ulcerative colitis receives Lomotil® for excessive diarrhea and develops fever, abdominal pain and tenderness, and a massively dilated colon on abdominal x-ray**

Toxic megacolon

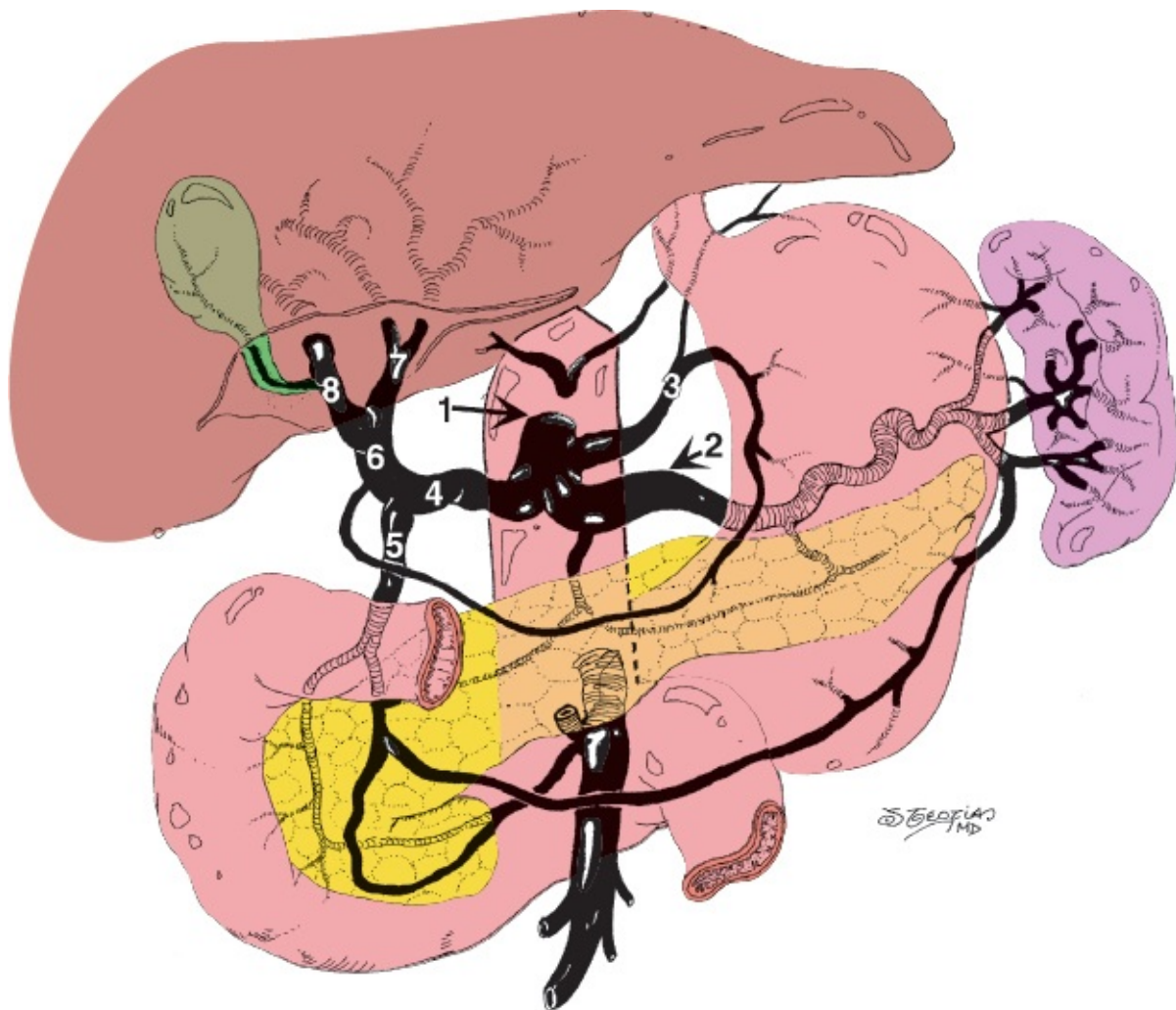
**28-year-old man with nonbloody diarrhea, low-grade fever, abdominal pain, perirectal abscesses, perianal fistulae**

Crohn's disease

# Chapter 51 Liver

## ANATOMY

Identify the arterial branches of the celiac trunk:



- . Celiac trunk
- . Splenic artery
- . Left gastric artery

- . Common hepatic artery
- . Gastroduodenal artery
- . Proper hepatic artery
- . Left hepatic artery
- . Right hepatic artery

### **What is the venous supply?**

**Portal vein** (formed from the splenic vein and the superior mesenteric vein)

### **What is the hepatic venous drainage?**

Via the hepatic veins, which drain into the IVC (three veins: left, middle, and right)

### **What sources provide oxygen to the liver?**

Portal vein blood—50%

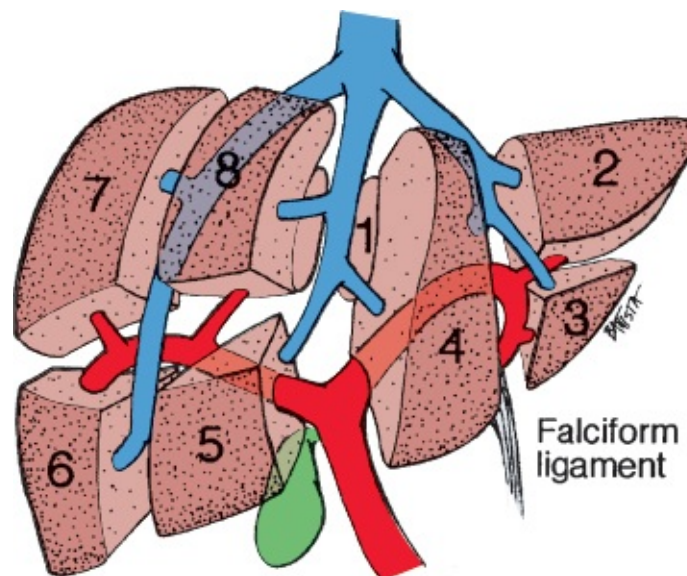
Hepatic artery blood—50%

### **From what sources does the liver receive blood?**

Portal system—75%

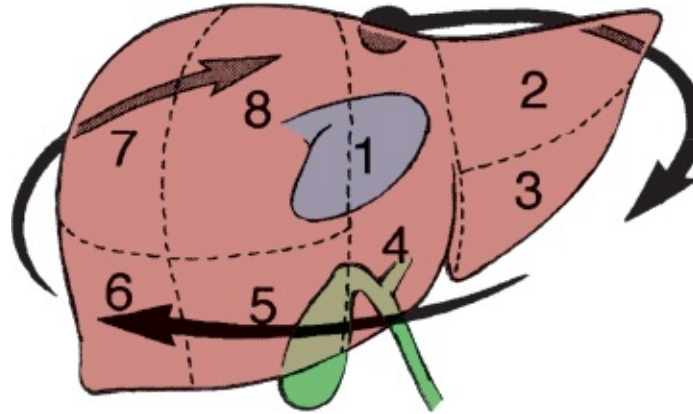
Hepatic artery system—25%

### **Identify the segments of the liver (French system)**



### **What is the overall arrangement of the segments in the liver?**

Clockwise, starting at segment 1



**What is the maximum amount of liver that can be resected while retaining adequate liver function?**

>80% (Remember Prometheus!)

**What is Child's class? (Child–Turcotte–Pugh)**

Classification system that estimates hepatic reserve in patients with hepatic failure and mortality

**How can the criteria comprising the modified Child's classification be remembered?**

Use the acronym: “A BEAP”:

Ascites

Bilirubin

Encephalopathy

Albumin

PT (prothrombin time)

**Define Child's classification:**

A

B

C

| <u>Ascites</u> | <u>Bili</u> | <u>Enceph</u> | <u>ALB</u> | <u>PT INR</u> |
|----------------|-------------|---------------|------------|---------------|
| none           | <2          | none          | >3.5       | <1.7          |
| controlled     | 2–3         | minimal       | 2.8–3.5    | 1.7–2.2       |
| uncontrolled   | >3          | severe        | <2.8       | >2.2          |

(Think: As in a letter grading system, A is better than B, B is better than C)

**What is the operative mortality for a portacaval shunt versus overall intraabdominal operations with cirrhosis in the following Child's classes:**

**A?**

<5% versus overall = 10%

**B?**

<15% versus overall = 30%

**C?**

≈33% versus overall = 75%

**What does the MELD score stand for?**

Model for End-stage Liver Disease

**What is measured in the MELD score?**

INR, total bilirubin, serum creatinine (SCR); find good MELD calculators online

**What is the mortality in cirrhotic patients for nonemergent nontransplant surgery?**

Increase in mortality by 1% per 1 point in the MELD score until 20, then 2% for each MELD point

**What is the mortality in cirrhotic patients for emergent nontransplant surgery?**

14% increase in mortality per 1 point of the MELD score

## Tumors of the Liver

**What is the most common liver cancer?**

**Metastatic disease** outnumber primary tumors 20:1; primary site is usually the GI tract

**What is the most common primary malignant liver tumor?**

Hepatocellular carcinoma (hepatoma)

**What is the most common primary benign liver tumor?**

Hemangioma

**What lab tests comprise the workup for liver metastasis?**

LFTs (AST and alkaline phosphatase are most useful), CEA for suspected primary colon cancer

**What are the associated imaging studies?**

CT scan, ultrasound, A-gram

**What is a right hepatic lobectomy?**

Removal of the right lobe of the liver (i.e., all tissue to the right of Cantle's line is removed)

**What is a left hepatic lobectomy?**

Removal of the left lobe of the liver (i.e., removal of all the liver tissue to the left of Cantle's line)

**What is a right trisegmentectomy?**

Removal of all the liver tissue to the right of the falciform ligament

**What chemical exposures are risk factors for angiosarcoma?**

**Vinyl chloride**, arsenic, thorotrast contrast

## **Hepatocellular Adenoma**

**What is it?**

Benign liver tumor

**Describe the histology**

Normal hepatocytes without bile ducts

**What are the associated risk factors?**

Women, birth control pills (Think: **ABC** = **A**denoma **B**irth **C**ontrol), anabolic steroids, glycogen storage disease

**What is the average age of occurrence?**

30 to 35 years of age

**What are the signs/symptoms?**

RUQ pain/mass, RUQ fullness, bleeding (rare)

### **What are the possible complications?**

Rupture with bleeding (33%), necrosis, pain, risk of hepatocellular carcinoma

### **How is the diagnosis made?**

CT scan, U/S,  $\pm$  biopsy (rule out hemangioma with RBC-tagged scan!)

### **What is the treatment:**

#### **Small?**

Stop birth control pills—it may regress; if not, surgical resection is necessary

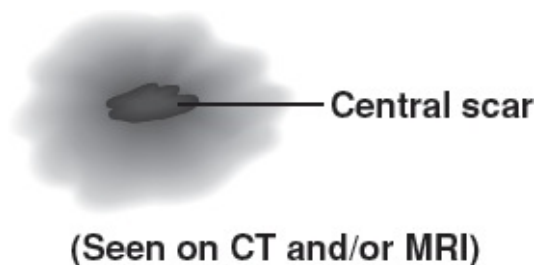
#### **Large (>5 cm), bleeding, painful, or ruptured?**

Surgical resection

## **■ Focal Nodular Hyperplasia (FNH)**

### **What is it?**

Benign liver tumor



### **Describe the histology**

Normal hepatocytes and bile ducts (adenoma has no bile ducts)

### **What is the average age of occurrence?**

$\approx$ 40 years

### **What are the associated risk factors?**

Female gender

### **Are the tumors associated with birth control pills?**

Yes, but not as clearly associated as with adenoma

### **How is the diagnosis made?**

Nuclear technetium-99 study, U/S, CT scan, A-gram, biopsy

### **What is the classic CT scan finding?**

Liver mass with “**central scar**”

(Think: focal = central)

### **Is there a cancer risk with FNH?**

No (there is a cancer risk with adenoma)

### **What is the treatment?**

Resection or **embolization** if patient is symptomatic; otherwise, follow if diagnosis is confirmed; stop birth control pills

## **Hepatic Hemangioma**

### **What is it?**

Benign vascular tumor of the liver

### **What is its claim to fame?**

Most common primary benign liver tumor (up to 7% of population)

### **What are the signs/symptoms?**

RUQ pain/mass, bruits

### **What are the possible complications?**

Pain, congestive heart failure, coagulopathy, obstructive jaundice, gastric outlet obstruction, Kasabach–Merritt syndrome, hemorrhage (rare)

### **Define Kasabach–Merritt syndrome?**

Hemangioma **and** thrombocytopenia and fibrinogenopenia

### **How is the diagnosis made?**

CT scan with IV contrast, tagged red blood scan, MRI, ultrasound

**Should biopsy be performed?**

No (risk of hemorrhage with biopsy)

**What is the treatment?**

**Observation** (>90%)

**What are the indications for resection?**

Symptoms, hemorrhage, cannot make a diagnosis

## **Hepatocellular Carcinoma**

**What is it?**

Most common primary malignancy of the liver

**By what name is it also known?**

Hepatoma

**What is its incidence?**

Accounts for 80% of all primary malignant liver tumors

**What are the associated risk factors?**

Hepatitis B virus, cirrhosis, aflatoxin

**What percentage of patients with cirrhosis will develop hepatocellular carcinoma?**

≈5%

**What are the signs/symptoms?**

Dull RUQ pain, hepatomegaly (classic presentation: **painful hepatomegaly**)

**What tests should be ordered?**

Ultrasound, CT scan, angiography, tumor marker elevation

**What is the tumor marker?**

Elevated  $\alpha$ -fetoprotein

**What is the most common way to get a tissue diagnosis?**

Needle biopsy with CT scan, ultrasound, or laparoscopic guidance

**What is the most common site of metastasis?**

Lungs

**What is the treatment of hepatocellular carcinoma?**

Surgical resection, if possible (e.g., lobectomy); liver transplant

**What are the treatment options if the patient is not a surgical candidate?**

Percutaneous ethanol tumor injection, cryotherapy, and intra-arterial chemotherapy

**What are the indications for liver transplantation?**

Cirrhosis and NO resection candidacy as well as no distant or lymph node metastases and no vascular invasion; the tumor must be single, <5-cm tumor or have three nodules, with none >3 cm

**What is the prognosis under the following conditions:**

**Unresectable?**

Almost none survive 1 year

**Resectable?**

≈35% are alive at 5 years

**Which subtype has the best prognosis?**

Fibrolamellar hepatoma (young adults)

## ABSCESSES OF THE LIVER

**What is a liver abscess?**

Abscess (collection of pus) in the liver parenchyma

### **What are the types of liver abscess?**

Pyogenic (bacterial), parasitic (amebic), fungal

### **What are the two most common types?**

**Bacterial** (most common in the United States) and amebic (most common worldwide)

## **Bacterial Liver Abscess**

### **What are the three most common bacterial organisms affecting the liver?**

Gram negatives: *E. coli*, *Klebsiella*, and *Proteus*

### **What are the most common sources/causes of bacterial liver abscesses?**

Cholangitis, diverticulitis, liver cancer, liver metastasis

### **What are the signs/symptoms?**

**Fever, chills, RUQ pain**, leukocytosis, increased liver function tests (LFTs), jaundice, sepsis, weight loss

### **What is the treatment?**

IV antibiotics (triple antibiotics with metronidazole), percutaneous drainage with CT scan or U/S guidance

### **What are the indications for operative drainage?**

Multiple/loculated abscesses or if multiple percutaneous attempts have failed

## **Amebic Liver Abscess**

### **What is the etiology?**

*Entamoeba histolytica* (typically reaches liver via portal vein from intestinal amebiasis)

**How does it spread?**

Fecal–oral transmission

**What are the risk factors?**

Patients from countries south of the U.S.–Mexican border, institutionalized patients, homosexual men, alcoholic patients

**What are the signs/symptoms?**

RUQ pain, fever, hepatomegaly, diarrhea

**Note:** chills are much less common with amebic abscesses than with pyogenic abscesses

**Classic description of abscess contents?**

“Anchovy paste” pus

**How is the diagnosis made?**

Lab tests, ultrasound, CT scan

**What lab tests should be performed?**

Indirect hemagglutination titers for *Entamoeba* antibodies elevated in >95% of cases, elevated LFTs

**What is the treatment?**

Metronidazole IV

**What are the indications for percutaneous surgical drainage?**

Refractory to metronidazole, bacterial coinfection, or peritoneal rupture

## ■ Hydatid Liver Cyst

**What is it?**

Usually a right lobe cyst filled with *Echinococcus granulosus*

**What are the risk factors?**

Travel; exposure to dogs, sheep, and cattle (carriers)

**What are the signs/symptoms?**

RUQ abdominal pain, jaundice, RUQ mass

**How is the diagnosis made?**

Indirect hemagglutination antibody test (serologic testing), Casoni skin test, ultrasound, CT scan, radiographic imaging

**What are the findings on AXR?**

Possible calcified outline of cyst

**What are the major risks?**

Erosion into the pleural cavity, pericardial sac, or biliary tree  
Rupture into the peritoneal cavity causing fatal anaphylaxis

**What is the risk of surgical removal of echinococcal (hydatid) cysts?**

Rupture or leakage of cyst contents into the abdomen may cause a fatal anaphylactic reaction

**When should percutaneous drainage be performed?**

Never; may cause leaking into the peritoneal cavity and anaphylaxis

**What is the treatment?**

Mebendazole, followed by surgical resection; large cysts can be drained and then injected with toxic irrigant (scolicide) into the cyst unless aspirate is bilious (which means there is a biliary connection) followed by cyst removal

**Which toxic irrigations are used?**

Hypertonic saline, ethanol, or cetrimide

## HEMOBILIA

**What is it?**

Blood draining via the common bile duct into the duodenum

**What is the diagnostic triad?**

Triad:

1. RUQ pain
2. Guaiac positive/upper GI bleeding
3. Jaundice

**What are the causes?**

Trauma with liver laceration, percutaneous transhepatic cholangiography (PTC), tumors

**How is the diagnosis made?**

EGD (blood out of the ampulla of Vater), A-gram

**What is the treatment?**

A-gram with embolization of the bleeding vessel

**What is bilhemia?**

Seen after trauma, connection of bile ducts and venous system, resulting in rapid and very elevated serum bilirubin

# Chapter 52 Portal Hypertension

## **Where does the portal vein begin?**

At the confluence of the splenic vein and the SMV

## **What are the six potential routes of portal–systemic collateral blood flow (as seen with portal hypertension)?**

- . Umbilical vein
- . Coronary vein to esophageal venous plexuses
- . Retroperitoneal veins (veins of Retzius)
- . Diaphragm veins (veins of Sappey)
- . Superior hemorrhoidal vein to middle and inferior hemorrhoidal veins and then to the iliac vein
- . Splenic veins to the short gastric veins

## **What is the pathophysiology of portal hypertension?**

Elevated portal pressure resulting from resistance to portal flow

## **What is the etiology?**

**Prehepatic**—Thrombosis of portal vein/atresia of portal vein

**Hepatic**—**Cirrhosis** (distortion of normal parenchyma by regenerating hepatic nodules), hepatocellular carcinoma, fibrosis

**Posthepatic**—Budd–Chiari syndrome: thrombosis of hepatic veins

## **What is the most common cause of portal hypertension in the United States?**

Cirrhosis (>90% of cases)

## **How many patients with alcoholism develop cirrhosis?**

Surprisingly, <1 in 5

## **What percentage of patients with cirrhosis develop esophageal varices?**

≈40%

**How many patients with cirrhosis develop portal hypertension?**

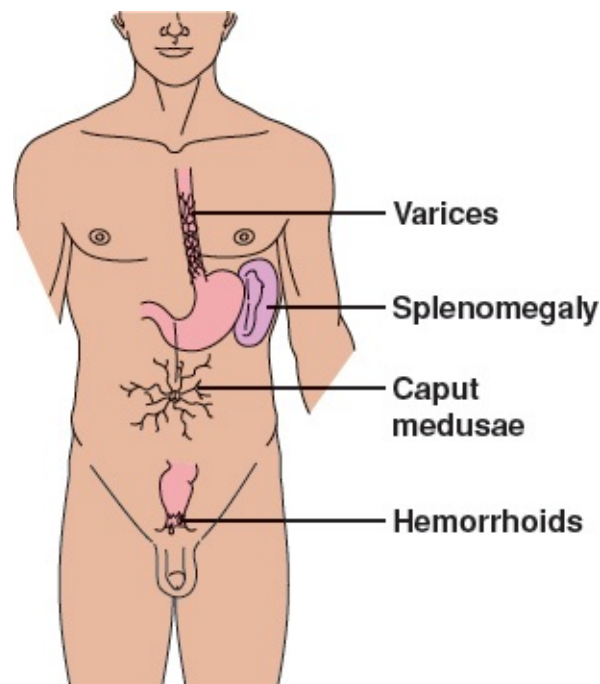
≈2/3

**What is the most common physical finding in patients with portal hypertension?**

Splenomegaly (spleen enlargement)

**What are the four associated CLINICAL findings in portal hypertension?**

- . Esophageal varices
- . Splenomegaly
- . Caput medusae (engorgement of periumbilical veins)
- . Hemorrhoids



**What other physical findings are associated with cirrhosis and portal hypertension?**

Spider angioma, palmar erythema, ascites, truncal obesity and peripheral wasting, encephalopathy, asterixis (liver flap), gynecomastia, jaundice

**What is the name of the periumbilical bruit heard with caput**

## **medusae?**

Cruveilhier–Baumgarten bruit

**What constitutes the portal–systemic collateral circulation in portal hypertension in the following conditions:**

### **Esophageal varices?**

Coronary vein backing up into the azygous system

### **Caput medusae?**

Umbilical vein (via falciform ligament) draining into the epigastric veins

### **Retroperitoneal varices?**

Small mesenteric veins (veins of Retzius) draining retroperitoneally into lumbar veins

### **Hemorrhoids?**

Superior hemorrhoidal vein (which normally drains into the inferior mesenteric vein) backing up into the middle and inferior hemorrhoidal veins

## **What is the etiology?**

**Cirrhosis (90%)**, schistosomiasis, hepatitis, Budd–Chiari syndrome, hemochromatosis, Wilson’s disease, portal vein thrombosis, tumors, splenic vein thrombosis

## **What is Budd–Chiari syndrome?**

Thrombosis of the hepatic veins

## **What is the most feared complication of portal hypertension?**

Bleeding from esophageal varices

## **What are esophageal varices?**

Engorgement of the esophageal venous plexuses secondary to increased collateral blood flow from the portal system as a result of portal hypertension

## **What is the “rule of 2/3” of portal hypertension?**

2/3 of patients with cirrhosis will develop portal hypertension

2/3 of patients with portal hypertension will develop esophageal varices

2/3 of patients with esophageal varices will bleed from the varices

**In patients with cirrhosis and known varices who are suffering from upper GI bleeding, how often does that bleeding result from varices?**

Only ≈50% of the time

**What are the signs/symptoms?**

Hematemesis, melena, hematochezia

**What is the initial treatment of variceal bleeding?**

As with all upper GI bleeding: large-bore IVs × 2, IV fluid, Foley catheter, type and cross blood, send labs, correct coagulopathy (vitamin K, fresh frozen plasma), ± intubation to protect from aspiration

**What is the diagnostic test of choice?**

**EGD (upper GI endoscopy)**

Remember, **bleeding** is the result of varices only half the time; must rule out ulcers, gastritis, etc.

**If esophageal varices cause bleeding, what are the EGD treatment options?**

- . **Emergent endoscopic sclerotherapy:** a sclerosing substance is injected into the esophageal varices under direct endoscopic vision
- . **Endoscopic band ligation:** elastic band ligation of varices

**What are the pharmacologic options?**

**Somatostatin** (octreotide) or **IV vasopressin** (and nitroglycerin, to avoid MI) to achieve vasoconstriction of the mesenteric vessels; if bleeding continues, consider balloon (**Sengstaken–Blakemore tube**) tamponade of the varices, β-blocker

**What is a Sengstaken–Blakemore tube?**

Tube with a gastric and esophageal balloon for tamponading an esophageal bleed

**What is the next therapy after the bleeding is controlled?**

Repeat endoscopic sclerotherapy/banding

**What are the options if sclerotherapy and conservative methods fail to stop the variceal bleeding or bleeding recurs?**

Repeat sclerotherapy/banding and treat conservatively

TIPS

Surgical shunt (selective or partial)

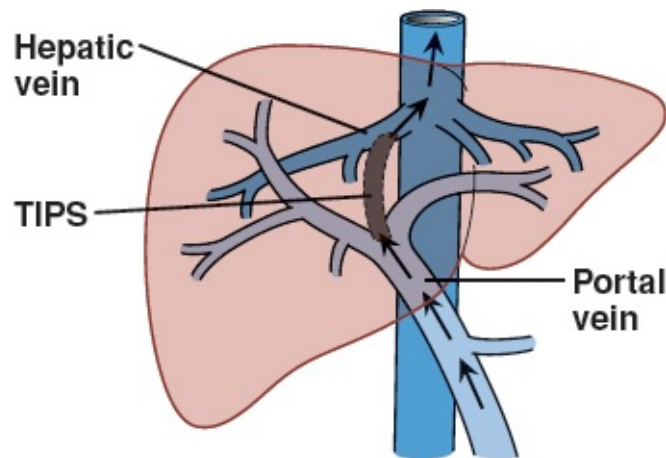
Liver transplantation

**What does the acronym TIPS stand for?**

Transjugular Intrahepatic Portosystemic Shunt

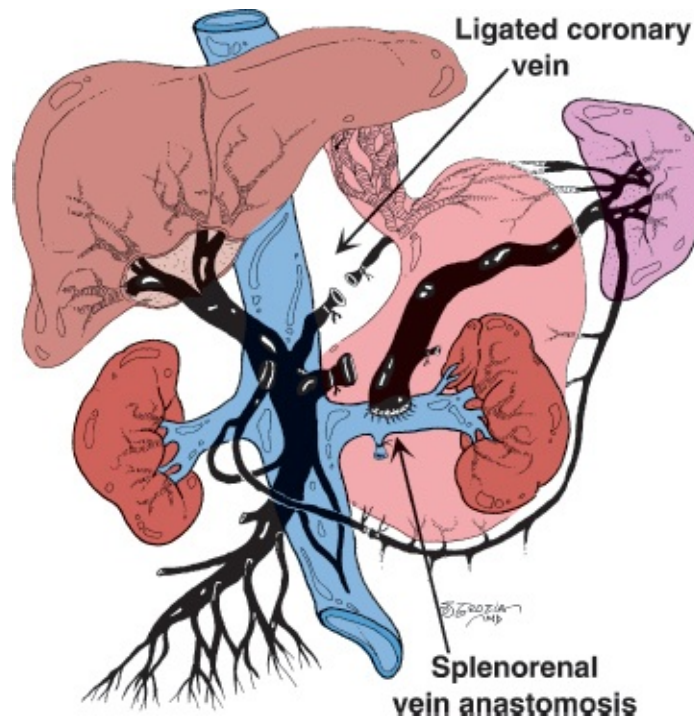
**What is a TIPS procedure?**

Angiographic radiologist places a small tube stent intrahepatically between the hepatic vein and a branch of the portal vein via a percutaneous jugular vein route



**What is a Warren shunt?**

Distal splenorenal shunt with ligation of the coronary vein—elective shunt procedure associated with low incidence of encephalopathy in patients postoperatively because only the splenic flow is diverted to decompress the varices



**What is the most common perioperative cause of death following shunt procedure?**

Hepatic failure, secondary to decreased blood flow (accounts for two thirds of deaths)

**What is the major postoperative morbidity after a shunt procedure?**

Increased incidence of hepatic encephalopathy because of decreased portal blood flow to the liver and decreased clearance of toxins/metabolites from the blood

**What medication is infused to counteract the coronary artery vasoconstriction of IV vasopressin?**

Nitroglycerin IV drip

**What lab value roughly correlates with degree of encephalopathy?**

Serum ammonia level (**Note:** Thought to correlate with but not cause encephalopathy)

**What medications are used to treat hepatic encephalopathy?**

Lactulose PO, with or without neomycin PO

**Rapid Fire Review**

---

**Name the most likely diagnosis:**

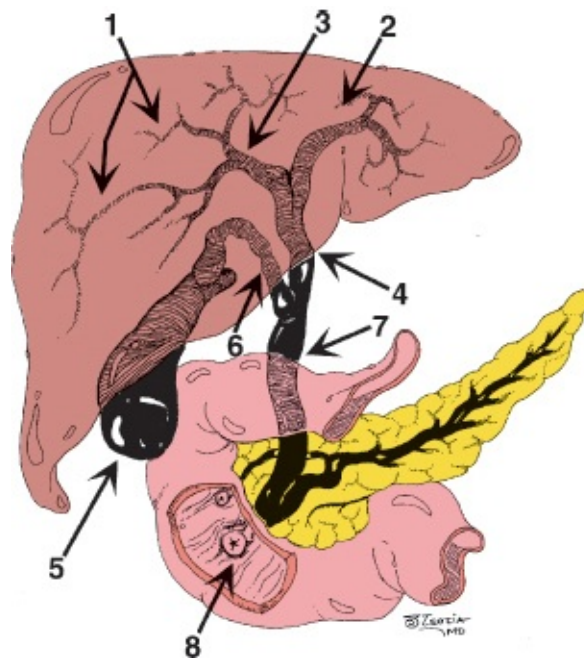
**39-year-old man with caput medusae, hemorrhoids, and splenomegaly**

Portal hypertension

# Chapter 53 Biliary Tract

## ANATOMY

Name structures 1 through 8 (below) of the biliary tract:



- . Intrahepatic ducts
- . Left hepatic duct
- . Right hepatic duct
- . Common hepatic duct
- . Gallbladder
- . Cystic duct
- . Common bile duct
- . Ampulla of Vater

**What is the name of the node in Calot's triangle?**

Calot's node

**What are the small ducts that drain bile directly into the gallbladder from the liver?**

Ducts of Luschka

**Which artery is susceptible to injury during cholecystectomy?**

Right hepatic artery, because of its proximity to the cystic artery and Calot's triangle

**Where is the infundibulum of the gallbladder?**

Near the cystic duct

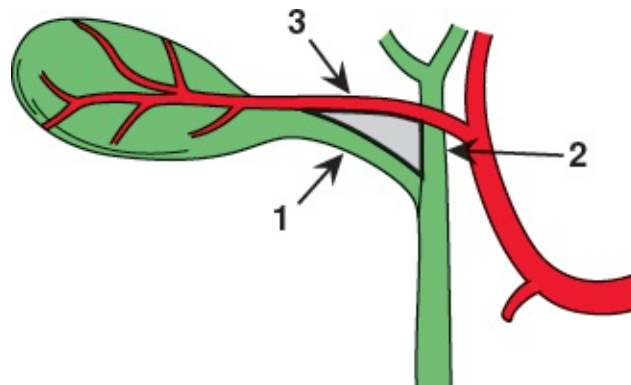
**Where is the fundus of the gallbladder?**

At the end of the gallbladder

**What are the boundaries of the triangle of Calot?**

**“Three C’s”:**

1. Cystic duct
2. Common hepatic duct
3. Cystic artery



**“Dr. Blackbourne, are you absolutely sure that the triangle of Calot includes the cystic artery and not the liver edge?”**

Yes, look up Gastroenterology, 2002; 123(5):1440

## PHYSIOLOGY

**What is the source of alkaline phosphatase?**

Bile duct epithelium; expect alkaline phosphatase to be elevated in bile duct

obstruction

**What is in bile?**

Cholesterol, lecithin (phospholipid), bile acids, and bilirubin

**What does bile do?**

Emulsifies fats

**What is the enterohepatic circulation?**

Circulation of bile acids from liver to gut and back to the liver

**Where are most of the bile acids absorbed?**

In the terminal ileum

**What stimulates gallbladder emptying?**

Cholecystokinin and vagal input

**What is the source of cholecystokinin?**

Duodenal mucosal cells

**What are its actions?**

Gallbladder emptying

Opening of ampulla of Vater

Slowing of gastric emptying

Pancreas acinar cell growth and release of exocrine products

## **PATHOPHYSIOLOGY**

**At what level of serum total bilirubin does one start to get jaundiced?**

2.5

**Classically, what is thought to be the anatomic location where one first finds evidence of jaundice?**

Under the tongue (ultraviolet light breaks down Bilirubin at other sites!)

**What are the signs and symptoms of obstructive jaundice?**

Jaundice  
Dark urine  
Clay-colored stools (acholic stools)  
Pruritus (itching)  
Loss of appetite  
Nausea

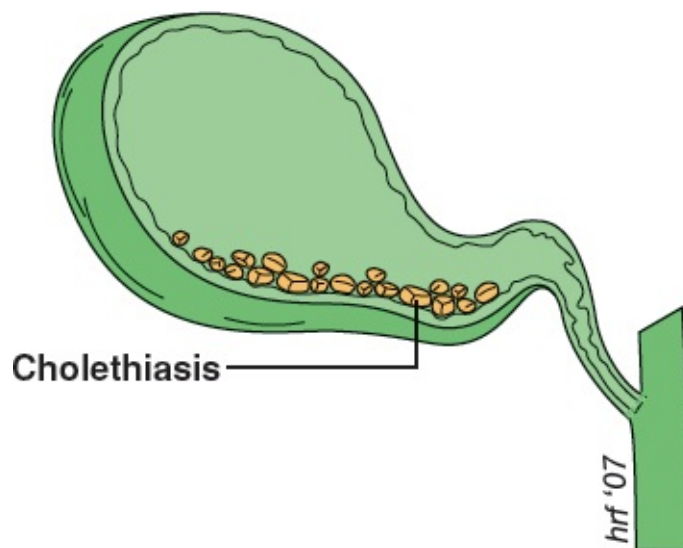
**What causes the itching in obstructive jaundice?**

Bile salts in the dermis (not bilirubin!)

**Define the following terms:**

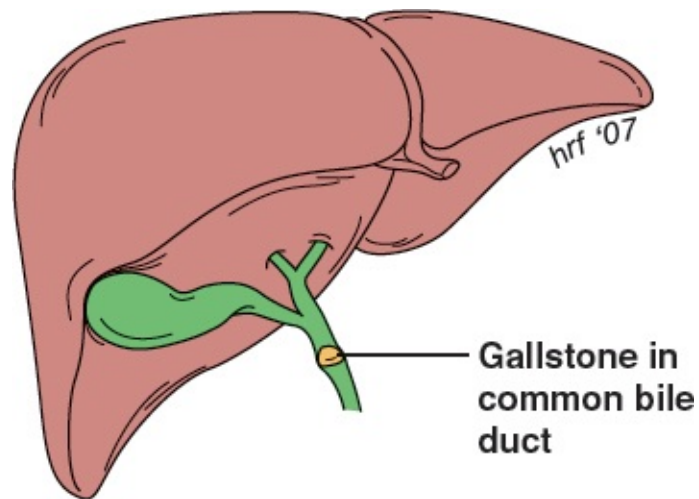
**Cholelithiasis**

Gallstones in gallbladder



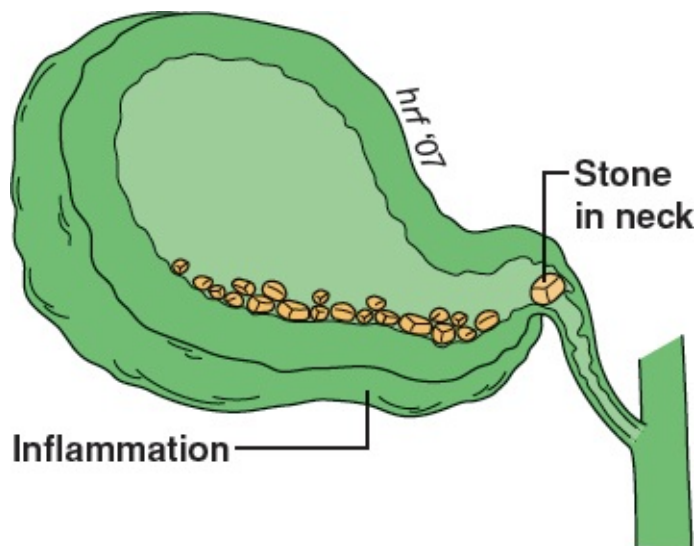
**Choledocholithiasis**

Gallstone in common bile duct



## **Cholecystitis**

Inflammation of gallbladder



## **Cholangitis**

Infection of biliary tract

## **Cholangiocarcinoma**

Adenocarcinoma of bile ducts

## **Klatskin's tumor**

Cholangiocarcinoma of bile duct at the junction of the right and left hepatic ducts

## **Biliary colic**

Pain from gallstones, usually from a stone at cystic duct

Pain is located in the RUQ, epigastrium, or right subscapular region of the back

Usually lasts minutes to hours but eventually goes away; it is often postprandial, especially after fatty foods

## **Biloma**

Intraperitoneal bile fluid collection

## **Choledochojejunostomy**

Anastomosis between common bile duct and jejunum

## **Hepaticojejunostomy**

Anastomosis of hepatic ducts or common hepatic duct to jejunum

# **DIAGNOSTIC STUDIES**

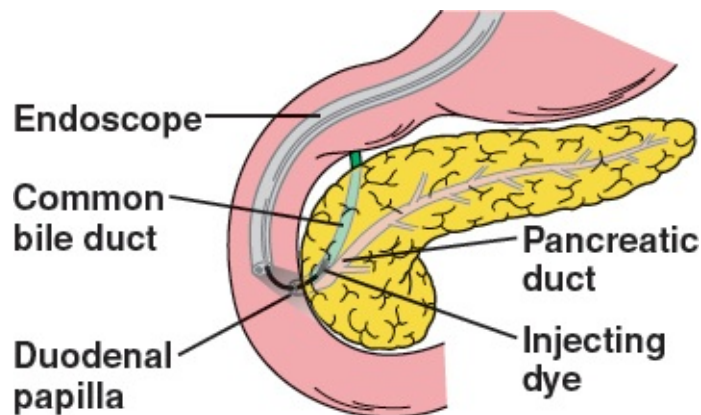
**What is the initial diagnostic study of choice for evaluation of the biliary tract/gallbladder/cholelithiasis?**

Ultrasound!

**Define the following diagnostic studies:**

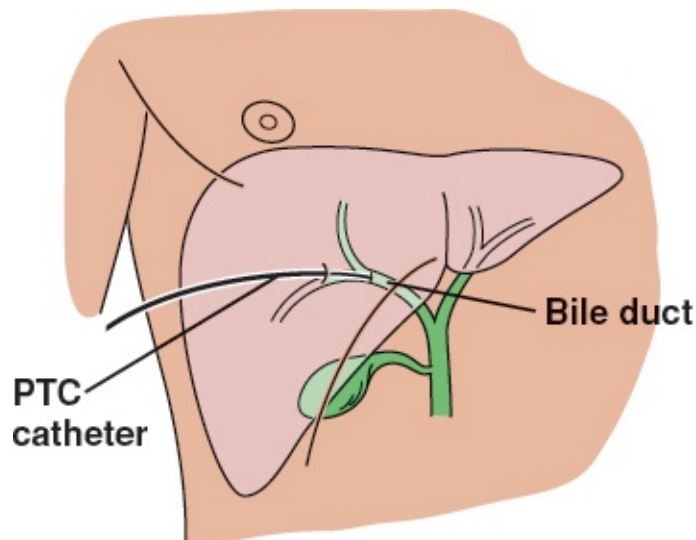
## **ERCP**

Endoscopic **R**etrograde **C**holangio**P**ancreatography



## **PTC**

**Percutaneous Transhepatic Cholangiogram**



## **IOC**

**IntraOperative Cholangiogram** (done laparoscopically or open to rule out choledocholithiasis)

## **HIDA/PRIDA scan**

Radioisotope study; isotope concentrated in liver and secreted into bile; will demonstrate cholecystitis, bile leak, or CBD obstruction

### **How does the HIDA scan reveal cholecystitis?**

Nonopacification of the gallbladder from obstruction of the cystic duct

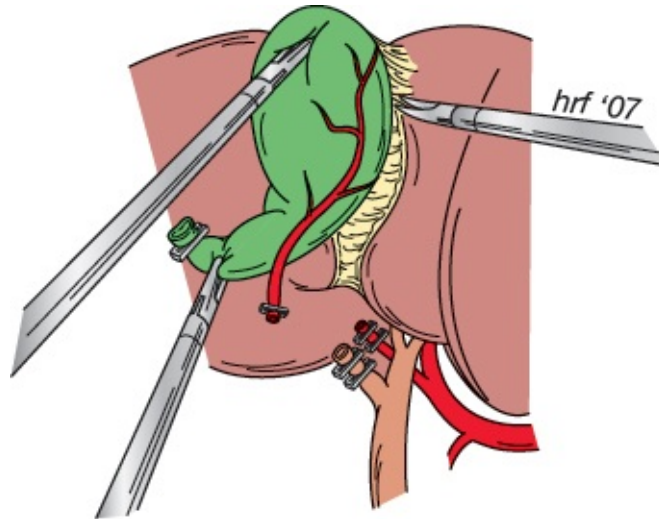
## **BILIARY SURGERY**

### **What is a cholecystectomy?**

Removal of the gallbladder laparoscopically or through a standard Kocher incision

### **What is a “lap chole”?**

**LAP**aroscopic **CHOLE**cystectomy



### **What is a sphincterotomy?**

Cut through sphincter of Oddi to allow passage of gallstones from the common bile duct; most often done at ERCP; a.k.a. “papillotomy”

### **How should postoperative biloma be treated after a lap chole?**

- . Percutaneous drain bile collection
- . ERCP with placement of biliary stent past leak (usually cystic duct remnant leak)

### **What is the treatment of major CBD injury after a lap chole?**

Choledochojejunostomy

## **OBSTRUCTIVE JAUNDICE**

### **What is it?**

Jaundice (hyperbilirubinemia  $>2.5$ ) from obstruction of bile flow to the duodenum

### **What is the differential diagnosis of *proximal* bile duct obstruction?**

Cholangiocarcinoma  
 Lymphadenopathy  
 Metastatic tumor  
 Gallbladder carcinoma  
 Sclerosing cholangitis

Gallstones  
Tumor embolus  
Parasites  
Postsurgical stricture  
Hepatoma  
Benign bile duct tumor

**What is the differential diagnosis of *distal* bile duct obstruction?**

Choledocholithiasis (**gallstones**)  
Pancreatic carcinoma  
Pancreatitis  
Ampullary carcinoma  
Lymphadenopathy  
Pseudocyst  
Postsurgical stricture  
Ampulla of Vater dysfunction/stricture  
Lymphoma  
Benign bile duct tumor  
Parasites

**What is the initial study of choice for obstructive jaundice?**

Ultrasound

**What lab results are associated with obstructive jaundice?**

Elevated alkaline phosphatase, elevated bilirubin with or without elevated LFTs

## CHOLELITHIASIS

**What is it?**

Formation of gallstones

**What is the incidence?**

≈10% of U.S. population will develop gallstones

**What are the “Big 4” risk factors?**

“Four Fs”:

Female

Fat

Forty

Fertile (multiparity)

### **What are the types of stones?**

Cholesterol stones (75%)

Pigment stones (25%)

### **What are the types of pigmented stones?**

Black stones (contain calcium bilirubinate)

Brown stones (associated with biliary tract infection)

### **What are the causes of black-pigmented stones?**

Cirrhosis, hemolysis

### **What is the pathogenesis of cholesterol stones?**

Secretion of bile **supersaturated** with cholesterol (relatively decreased amounts of lecithin and bile salts); then, cholesterol precipitates out and forms solid crystals, then gallstones

### **What are the signs and symptoms?**

Symptoms of: biliary colic, cholangitis, choledocholithiasis, gallstone, pancreatitis

### **Is biliary colic pain really “colic”?**

No, symptoms usually last for hours; therefore, colic is a misnomer!

### **What percentage of patients with gallstones are *asymptomatic*?**

80% of patients with cholelithiasis are asymptomatic!

### **What is thought to cause biliary colic?**

Gallbladder contraction against a stone temporarily at the gallbladder/cystic duct junction; a stone in the cystic duct; or a stone passing through the cystic duct

### **What are the five major complications of gallstones?**

- . Acute cholecystitis
- . Choledocholithiasis
- . Gallstone pancreatitis

- . Gallstone ileus
- . Cholangitis

### **How is cholelithiasis diagnosed?**

History

Physical examination

**Ultrasound**

### **How often does ultrasound detect choledocholithiasis?**

≈33% of the time ... not a very good study for choledocholithiasis!

### **How are symptomatic or complicated cases of cholelithiasis treated?**

By cholecystectomy

### **What are the possible complications of a lap chole?**

Common bile duct injury; right hepatic duct/artery injury; cystic duct leak; biloma (collection of bile)

### **What are the indications for cholecystectomy in the asymptomatic patient?**

Sickle-cell disease

Calcified gallbladder (porcelain gallbladder)

Patient is a child

### **What is choledocholithiasis?**

Gallstones in the common bile duct

### **What is the management of choledocholithiasis?**

- . ERCP with papillotomy and basket/balloon retrieval of stones (pre- or postoperatively)
- . Laparoscopic transcystic duct or trans common bile duct retrieval
- . Open common bile duct exploration

### **What medication may dissolve a cholesterol gallstone?**

Chenodeoxycholic acid, ursodeoxycholic acid (Actigall®); but, if medication is stopped, gallstones often recur

## **What is the major feared complication of ERCP?**

Pancreatitis

## **ACUTE CHOLECYSTITIS**

### **What is the pathogenesis of acute cholecystitis?**

Obstruction of cystic duct leads to inflammation of the gallbladder;  $\approx 95\%$  of cases result from calculi, and  $\approx 5\%$  from acalculous obstruction

### **What are the risk factors?**

Gallstones

### **What are the signs and symptoms?**

**Unrelenting** RUQ pain or tenderness

**Fever**

Nausea/vomiting

Painful palpable gallbladder in 33%

Positive Murphy's sign

Right subscapular pain (referred)

Epigastric discomfort (referred)

### **What is Murphy's sign?**

Acute pain and **inspiratory arrest** elicited by palpation of the RUQ during inspiration

### **What are the complications of acute cholecystitis?**

Abscess

Perforation

Choledocholithiasis

Cholecystenteric fistula formation

Gallstone ileus

### **What lab results are associated with acute cholecystitis?**

Increased WBC; may have:

Slight elevation in alkaline phosphatase, LFTs

Slight elevation in amylase, total bilirubin

## **What is the diagnostic test of choice for acute cholecystitis?**

Ultrasound

## **What are the signs of acute cholecystitis on ultrasound?**

Thickened gallbladder wall ( $>3$  mm)

Pericholecystic fluid

Distended gallbladder

Gallstones present/cystic duct stone

Sonographic Murphy's sign (pain on inspiration after placement of ultrasound probe over gallbladder)

## **What is the difference between acute cholecystitis and biliary colic?**

Biliary colic has temporary pain; acute cholecystitis has pain that does not resolve, usually with elevated WBCs, fever, and signs of acute inflammation on U/S

## **What is the treatment of acute cholecystitis?**

IVFs, antibiotics, and early cholecystectomy

# **ACUTE ACALCULOUS CHOLECYSTITIS**

## **What is it?**

Acute cholecystitis without evidence of stones

## **What is the pathogenesis?**

It is believed to result from sludge and gallbladder disuse and **biliary stasis**, perhaps secondary to absence of cholecystokinin stimulation (decreased contraction of gallbladder)

## **What are the risk factors?**

Prolonged fasting

TPN

Trauma

Multiple transfusions

Dehydration

Often occurs in prolonged postoperative or ICU setting

**What are the diagnostic tests of choice?**

**Ultrasound;** sludge and inflammation usually present with acute acalculous cholecystitis

HIDA scan

**What are the findings on HIDA scan?**

Nonfilling of the gallbladder

**What is the management of acute acalculous cholecystitis?**

Cholecystectomy, or cholecystostomy tube if the patient is unstable (placed percutaneously by radiology or open surgery)

## CHOLANGITIS

**What is it?**

Bacterial infection of the biliary tract from obstruction (either partial or complete); potentially life-threatening

**What are the common causes?****Choledocholithiasis**

Stricture (usually postoperative)

Neoplasm (usually ampullary carcinoma)

Extrinsic compression (pancreatic pseudocyst/pancreatitis)

Instrumentation of the bile ducts (e.g., PTC/ERCP)

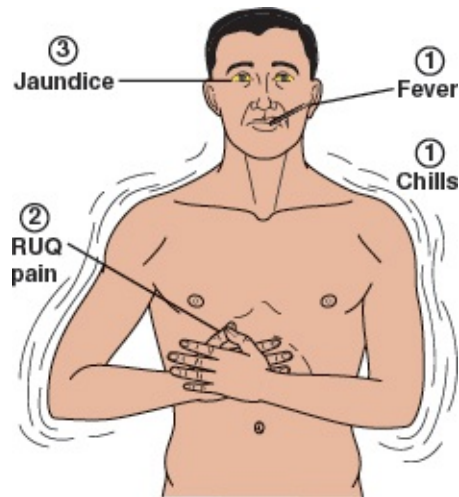
Biliary stent

**What is the most common cause of cholangitis?**

Gallstones in common bile duct (choledocholithiasis)

**What are the signs and symptoms?****Charcot's triad:**

1. Fever/chills
2. RUQ pain
3. Jaundice



### What is Reynold's pentad?

Charcot's triad PLUS

4. Mental status changes
5. Shock

### Which organisms are most commonly isolated with cholangitis?

Gram-negative organisms (*E. coli*, *Klebsiella*, *Pseudomonas*, *Enterobacter*, *Proteus*, *Serratia*) are the most common

### What are the diagnostic tests of choice?

Ultrasound and contrast study (e.g., ERCP or IOC) after patient has “cooled off” with IV antibiotics

### What is suppurative cholangitis?

Severe infection with sepsis—“pus under pressure”

### What is the management of cholangitis?

**Nonsuppurative:** IVF and antibiotics, with definitive treatment later (e.g., lap chole ± ERCP)

**Suppurative:** IVF, antibiotics, and decompression; decompression can be obtained by ERCP with papillotomy, PTC with catheter drainage, or laparotomy with T-tube placement

## SCLEROSING CHOLANGITIS

**What is it?**

Multiple inflammatory fibrous thickenings of bile duct walls resulting in biliary strictures

**What is its natural history?**

Progressive obstruction possibly leading to cirrhosis and liver failure; 10% of patients will develop cholangiocarcinoma

**What is the major risk factor?**

Inflammatory bowel disease

**What type of IBD is the most common risk factor?**

Ulcerative colitis (~66%)

**What are the signs and symptoms of sclerosing cholangitis?**

Same as those for obstructive jaundice:

- Jaundice

- Itching (pruritus)

- Dark urine

- Clay-colored stools

- Loss of energy

- Weight loss

- (Many patients are asymptomatic)

**How is it diagnosed?**

Elevated alkaline phosphatase, and PTC or ERCP revealing “beads on a string” appearance on contrast study

**What are the management options?**

Hepatoenteric anastomosis (if primarily extrahepatic ducts are involved) and resection of extrahepatic bile ducts because of the risk of cholangiocarcinoma

Transplant (if primarily intrahepatic disease or cirrhosis)

Endoscopic balloon dilations

## GALLSTONE ILEUS

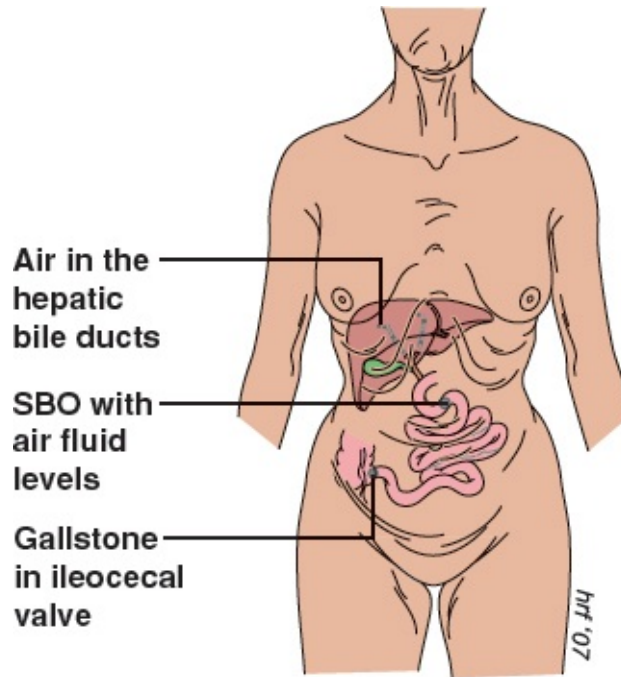
### What is it?

Small bowel obstruction from a large gallstone (>2.5 cm) that has eroded through the gallbladder and into the duodenum/small bowel

### What is the classic site of obstruction?

Ileocecal valve (but may cause obstruction in the duodenum, sigmoid colon)

### What are the classic findings of gallstone ileus?



### What is the population at risk?

Gallstone ileus is most commonly seen in **women >70 years**

### What are the signs/symptoms?

Symptoms of SBO: distention, vomiting, hypovolemia, RUQ pain

### Gallstone ileus causes what percentage of cases of SBO?

<1%

### What are the diagnostic tests of choice?

**Abdominal x-ray:** occasionally reveals radiopaque gallstone in the bowel; **40% of patients show air in the biliary tract**, small bowel distention, and air fluid levels secondary to ileus

UGI: used if diagnosis is in question; will show cholecystenteric fistula and the obstruction

**Abdominal CT scan:** reveals air in biliary tract, SBO  $\pm$  gallstone in intestine

### **What is the management?**

Surgery: enterotomy with removal of the stone  $\pm$  interval cholecystectomy (interval delayed)

## **CARCINOMA OF THE GALLBLADDER**

### **What is it?**

Malignant neoplasm arising in the gallbladder, vast majority are **adenocarcinoma (90%)**

### **What are the risk factors?**

Gallstones, porcelain gallbladder, cholecystenteric fistula

### **What is a porcelain gallbladder?**

Calcified gallbladder

### **What percentage of patients with a porcelain gallbladder will have gallbladder cancer?**

$\approx$ 50% (20% to 60%)

### **What is the incidence?**

$\approx$ 1% of all gallbladder specimens

### **What are the symptoms?**

Biliary colic, weight loss, anorexia; many patients are asymptomatic until late; may present as acute cholecystitis

### **What are the signs?**

Jaundice (from invasion of the common duct or compression by involved pericholedochal lymph nodes), RUQ mass, palpable gallbladder (advanced disease)

### **What are the diagnostic tests of choice?**

Ultrasound, abdominal CT scan, ERCP

### **What is the route of spread?**

Contiguous spread to the liver is most common

### **What is the management under the following conditions?**

#### **Confined to mucosa**

Cholecystectomy

#### **Confined to muscularis/serosa**

Radical cholecystectomy: cholecystectomy and wedge resection of overlying liver, and lymph node dissection ± chemotherapy/XRT

### **What is the main complication of a lap chole for gallbladder cancer?**

Trocar site tumor implants (**Note:** If known preoperatively, perform open cholecystectomy)

### **What is the prognosis for gallbladder cancer?**

Dismal overall: <5% 5-year survival as most are unresectable at diagnosis

T1 with cholecystectomy: 95% 5-year survival

## **CHOLANGIOCARCINOMA**

### **What is it?**

Malignancy of the extrahepatic or intrahepatic ducts—**primary bile duct cancer**

### **What is the histology?**

Almost all are adenocarcinomas

### **Average age at diagnosis?**

≈65 years, equally affects male/female

### **What are the signs and symptoms?**

Those of biliary obstruction: jaundice, pruritus, dark urine, clay-colored stools, cholangitis

**What is the most common location?**

Proximal bile duct

**What are the risk factors?**

Choledochal cysts

Ulcerative colitis

Thorotrast contrast dye (used in 1950s)

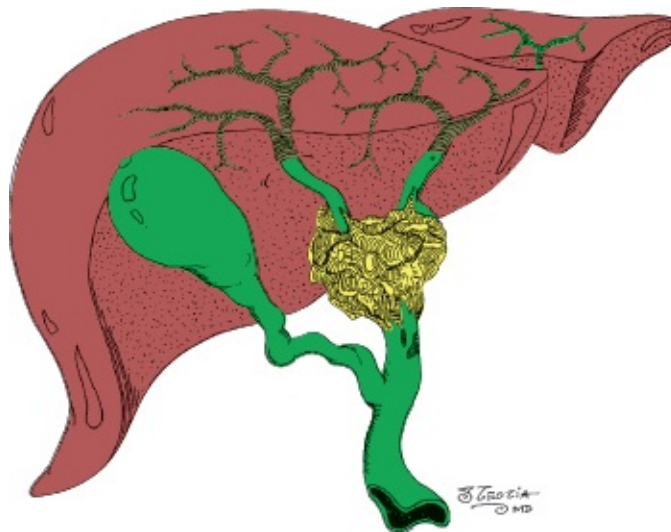
Sclerosing cholangitis

Liver flukes (clonorchiasis)

Toxin exposures (e.g., Agent Orange)

**What is a Klatskin tumor?**

Tumor that involves the junction of the right and left hepatic ducts

**What are the diagnostic tests of choice?**

Ultrasound, CT scan, ERCP/PTC with biopsy/brushings for cytology, MRCP

**What is an MRCP?**

MRI with visualization of pancreatic and bile ducts

**What is the management of proximal bile duct cholangiocarcinoma?**

Resection with Roux-en-Y hepaticojejunostomy (anastomose bile ducts to jejunum)  $\pm$  unilateral hepatic lobectomy

**What is the management of distal common bile duct cholangiocarcinoma?**

Whipple procedure

## MISCELLANEOUS CONDITIONS

### What is a porcelain gallbladder?

**Calcified gallbladder** seen on abdominal x-ray; results from chronic cholelithiasis/cholecystitis with calcified scar tissue in gallbladder wall; **cholecystectomy** required because of the strong association of **gallbladder carcinoma** with this condition

### What is hydrops of the gallbladder?

Complete obstruction of the cystic duct by a gallstone, with filling of the gallbladder with fluid (not bile) from the gallbladder mucosa

### What is Gilbert's syndrome?

Inborn error in liver bilirubin uptake and glucuronyl transferase resulting in hyperbilirubinemia (Think: **Gilbert's** = **G**lucuronyl)

### What is Courvoisier's gallbladder?

Palpable, **nontender** gallbladder (unlike gallstone disease) associated with cancer of the head of the pancreas; able to distend because it has not been "scarred down" by gallstones

### What is Mirizzi's syndrome?

Common hepatic duct obstruction as a result of **extrinsic** compression from a gallstone impacted in the cystic duct

## RAPID FIRE REVIEW

### What is the correct diagnosis?

**Elderly woman with small bowel obstruction and air in the biliary tract**

Gallstone ileus

**38-year-old female with progressively worse RUQ pain and ultrasound reveals a thickened gallbladder wall, pericholecystic fluid, and a sonographic Murphy's sign**

Acute cholecystitis

**Name the most likely diagnosis:**

**Lap chole POD #3, fever, RUQ fluid collection, no biliary dilation**

Biloma (most common cause = cystic duct leak)

**POD #7 following laparoscopic cholecystectomy—jaundice and dilated intrahepatic biliary ducts**

Clipping or transection of common bile duct

**33-year-old woman with jaundice, fever, RUQ pain, hypotension, and confusion**

Suppurative cholangitis

**43-year-old woman with RUQ pain and right subscapular pain for 2 hours intermittently over 4 months**

Biliary colic

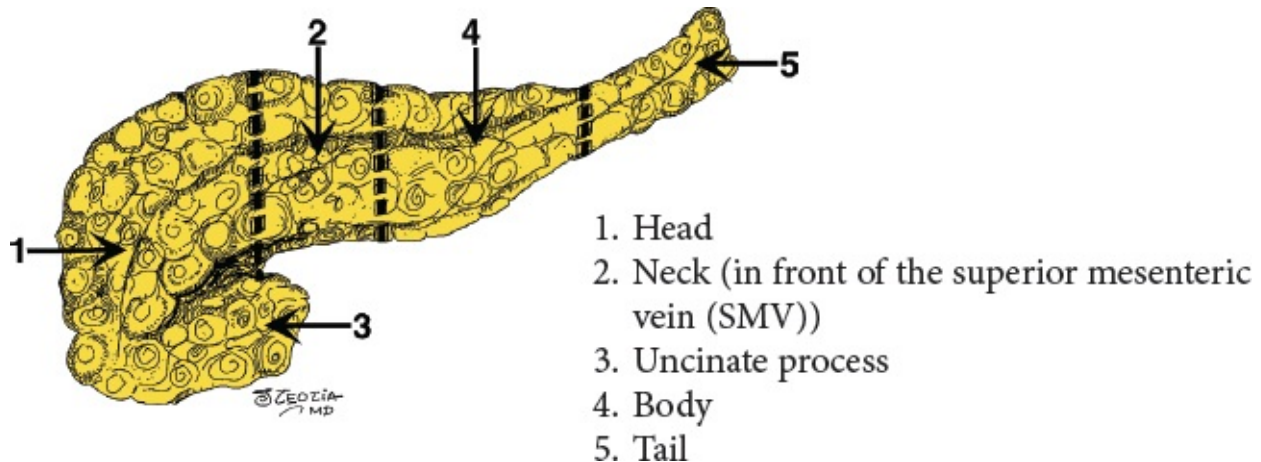
**Name the diagnostic modality:**

**22-year-old with RUQ pain with eating**

Ultrasound for cholelithiasis

## Chapter 54 Pancreas

Identify the regions of the pancreas:



**Why must the duodenum be removed if the head of the pancreas is removed?**

They share the same blood supply (gastroduodenal artery)

**What is the endocrine function of the pancreas?**

Islets of Langerhans:

$\alpha$ -cells: glucagon

$\beta$ -cells: insulin

**What is the exocrine function of the pancreas?**

Digestive enzymes: amylase, lipase, trypsin, chymotrypsin, carboxypeptidase

**What maneuver is used to mobilize the duodenum and pancreas and evaluate the entire pancreas?**

Kocher maneuver: Incise the lateral attachments of the duodenum and then lift the pancreas to examine the posterior surface

**PANCREATITIS**

## ■ Acute Pancreatitis

### **What is it?**

Inflammation of the pancreas

### **What are the most common etiologies in the United States?**

- . Alcohol abuse (50%)
- . Gallstones (30%)
- . Idiopathic (10%)

### **What is the acronym to remember all causes of pancreatitis?**

**“I GET SMASHED”:**

Idiopathic

Gallstones

Ethanol

Trauma

Scorpion bite

Mumps (viruses)

Autoimmune

Steroids

Hyperlipidemia/Hypercalcemia

ERCP

Drugs

### **What are the symptoms?**

Epigastric pain (frequently radiates to back); nausea and vomiting

### **What are the signs of pancreatitis?**

Epigastric tenderness

Diffuse abdominal tenderness

Decreased bowel sounds (adynamic ileus)

Fever

Dehydration/shock

### **What lab tests should be ordered?**

Amylase/lipase

**What are the associated diagnostic findings?**

Lab—High amylase, high lipase, high WBC

AXR—Sentinel loop, colon cutoff, possibly gallstones (only 10% visible on x-ray)

U/S—Phlegmon, cholelithiasis

CT—Phlegmon, pancreatic necrosis

**What is the most common sign of pancreatitis on AXR?**

Sentinel loop(s)

**What is the treatment?**

NPO

IVF

NGT if vomiting

Postpyloric tube feeds

H<sub>2</sub> blocker/PPI

Analgesia (not morphine)

Correction of coags/electrolytes

± Alcohol withdrawal prophylaxis

“Tincture of time”

**What are the possible complications?**

Pseudocyst

Abscess/infection

Pancreatic necrosis

Splenic/mesenteric/portal vessel rupture or thrombosis

Pancreatic ascites/pancreatic pleural effusion

Diabetes

ARDS/sepsis/MOF

Coagulopathy/DIC

Encephalopathy

Severe hypocalcemia

**What is the prognosis?**

Based on Ranson’s criteria

**Are postpyloric tube feeds safe in acute pancreatitis?**

**YES**

**What are Ranson's criteria for the following stages:**

**At presentation?**

- . Age >55
- . WBC >16,000
- . Glucose >200
- . AST >250
- . LDH >350

**During the initial 48 hours?**

- . Base deficit >4
- . BUN increase >5 mg/dL
- . Fluid sequestration >6 L
- . Serum  $\text{Ca}^{2+}$  <8
- . Hct decrease >10%
- .  $\text{PO}_2$  (ABG) <60 mm Hg

(Amylase value is NOT one of Ranson's criteria!)

**What is the mortality per positive criteria:**

**0 to 2?**

<5%

**3 to 4?**

≈15%

**5 to 6?**

≈40%

**7 to 8?**

≈100%

**How can the admission Ranson's criteria be remembered?**

**“GA LAW (Georgia law)”:**

Glucose >200

Age >55

LDH >350

AST >250

WBC >16,000

(“Don’t mess with the pancreas and don’t mess with the Georgia law”)

**How can Ranson’s criteria at less than 48 hours be remembered?**

“**C HOBBS** (Calvin and Hobbes)”:

Calcium <8 mg/dL

Hct drop of >10%

O<sub>2</sub> <60 (PaO<sub>2</sub>)

Base deficit >4

BUN >5 increase

Sequestration >6 L

**How can the AST versus LDH values in Ranson’s criteria be remembered?**

Alphabetically and numerically: A before L and 250 before 350

Therefore, AST >250 and LDH >350

**What is the etiology of hypocalcemia with pancreatitis?**

Fat saponification: fat necrosis binds to calcium

**What complication is associated with splenic vein thrombosis?**

Gastric varices (treatment with splenectomy)

**Can TPN with lipids be given to a patient with pancreatitis?**

Yes, if the patient does not suffer from hyperlipidemia (triglycerides >300)

**What is the least common cause of acute pancreatitis (and possibly the most commonly asked cause on rounds!)**

Scorpion bite (found on the island of Trinidad)

## ■ Chronic Pancreatitis

### **What is it?**

Chronic inflammation of the pancreas region causing destruction of the parenchyma, fibrosis, and calcification, resulting in loss of endocrine and exocrine tissue

### **What are the subtypes?**

- . Chronic calcific pancreatitis
- . Chronic obstructive pancreatitis (5%)

### **What are the causes?**

Alcohol abuse (most common; 70% of cases)

Idiopathic (15%)

Hypercalcemia (hyperparathyroidism)

Hyperlipidemia

Familial (found in families without any other risk factors)

Trauma

Iatrogenic

Gallstones

### **What are the symptoms?**

Epigastric and/or back pain, weight loss, steatorrhea

### **What are the associated signs?**

Type 1 diabetes mellitus (up to 1/3)

Steatorrhea (up to 1/4), weight loss

### **What are the signs of pancreatic exocrine insufficiency?**

Steatorrhea (fat malabsorption from lipase insufficiency—stools float in water)

Malnutrition

### **What are the signs of pancreatic endocrine insufficiency?**

Diabetes (glucose intolerance)

### **What are the common pain patterns?**

Unrelenting pain  
Recurrent pain

**What is the differential diagnosis?**

PUD, biliary tract disease, AAA, pancreatic cancer, angina

**What percentage of patients with chronic pancreatitis have or will develop pancreatic cancer?**

≈2%

**What are the appropriate lab tests?**

Amylase/lipase  
72-hour fecal fat analysis  
Glucose tolerance test (IDDM)

**Why may amylase/lipase be normal in a patient with chronic pancreatitis?**

Because of extensive pancreatic tissue loss (“burned-out pancreas”)

**What radiographic tests should be performed?**

CT scan—Has greatest sensitivity for gland enlargement/atrophy, calcifications, masses, pseudocysts  
KUB—Calcification in the pancreas  
ERCP—Ductal irregularities with dilation and stenosis (“chain of lakes”), pseudocysts

**What is the medical treatment?**

Discontinuation of alcohol use—can reduce attacks, though parenchymal damage continues secondary to ductal obstruction and fibrosis  
Insulin for type 1 diabetes mellitus  
Pancreatic enzyme replacement  
Narcotics for pain

**What is the surgical treatment?**

Puestow—longitudinal pancreaticojejunostomy (pancreatic duct **must be dilated**)  
Duval—distal pancreaticojejunostomy  
Near-total pancreatectomy

**What is the Frey procedure?**

Longitudinal pancreaticojejunostomy with core resection of the pancreatic head

**What is the indication for surgical treatment of chronic pancreatitis?**

Severe, prolonged/refractory pain

**What are the possible complications of chronic pancreatitis?**

Insulin dependent diabetes mellitus

Steatorrhea

Malnutrition

Biliary obstruction

Splenic vein thrombosis

Gastric varices

Pancreatic pseudocyst/abscess

Narcotic addiction

Pancreatic ascites/pleural effusion

Splenic artery aneurysm

## Gallstone Pancreatitis

**What is it?**

Acute pancreatitis from a gallstone in or passing through the ampulla of Vater (the exact mechanism is unknown)

**How is the diagnosis made?**

Acute pancreatitis and cholelithiasis and/or choledocholithiasis and no other cause of pancreatitis (e.g., no history of alcohol abuse)

**What radiologic tests should be performed?**

U/S to look for gallstones

CT scan to look at the pancreas, if symptoms are severe

**What is the treatment?**

Conservative measures and early interval cholecystectomy (laparoscopic cholecystectomy or open cholecystectomy) and intraoperative cholangiogram (IOC) in 3 to 5 days (after pancreatic inflammation resolves)

## Why should early interval cholecystectomy be performed on patients with gallstone pancreatitis?

Pancreatitis will recur in  $\approx 33\%$  of patients within 8 weeks (so always perform early interval cholecystectomy and IOC in 3 to 5 days when pancreatitis resolves)

## What is the role of ERCP?

- . Cholangitis
- . Refractory choledocholithiasis

## ■ Hemorrhagic Pancreatitis

### What is it?

Bleeding into the parenchyma and retroperitoneal structures with extensive pancreatic necrosis

### What are the signs?

Abdominal pain, shock/ARDS, Cullen's sign, Grey Turner's sign, Fox's sign

### Define the following terms:

#### Cullen's sign

**Bluish discoloration of the periumbilical area** from retroperitoneal hemorrhage tracking around to the anterior abdominal wall through fascial planes

#### Grey Turner's sign

**Ecchymosis or discoloration of the flank** in patients with retroperitoneal hemorrhage from dissecting blood from the retroperitoneum (Think: Grey **TURN**er = **TURN** side to side = flank [side] hematoma)

#### Fox's sign

**Ecchymosis of the inguinal ligament** from blood tracking from the retroperitoneum and collecting at the inguinal ligament

### What are the significant lab values?

Increased amylase/lipase  
Decreased Hct  
Decreased calcium levels

**What radiologic test should be performed?**

CT scan with IV contrast

## PANCREATIC ABSCESS

**What is it?**

Infected peripancreatic purulent fluid collection

**What are the signs/symptoms?**

Fever, unresolving pancreatitis, epigastric mass

**What radiographic tests should be performed?**

Abdominal CT scan with needle aspiration → send for Gram stain/culture

**What are the associated lab findings?**

Positive Gram stain and culture of bacteria

**Which organisms are found in pancreatic abscesses?**

Gram negative (most common): *Escherichia coli*, *Pseudomonas*, *Klebsiella*  
Gram positive: *Staphylococcus aureus*, *Candida*

**What is the treatment?**

Antibiotics and percutaneous drain placement or operative débridement and placement of drains

## PANCREATIC NECROSIS

**What is it?**

Dead pancreatic tissue, usually following acute pancreatitis

**How is the diagnosis made?**

Abdominal CT scan with IV contrast; dead pancreatic tissue does not take up IV

contrast and is not enhanced on CT scan (i.e., doesn't "light up")

### **What is the treatment:**

#### **Sterile?**

Medical management

#### **Suspicious of infection?**

CT-guided FNA

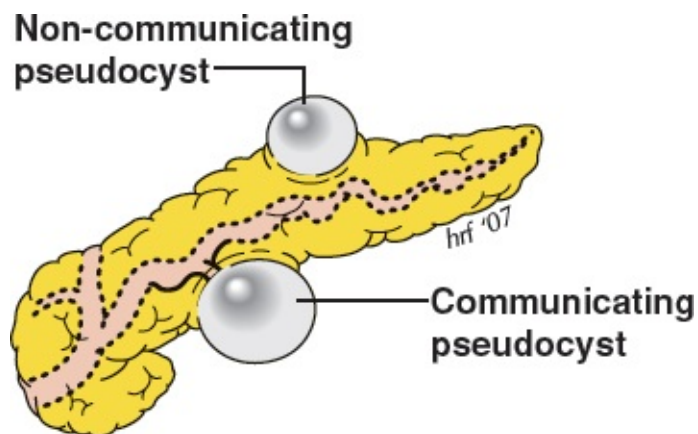
#### **Toxic, hypotensive?**

Operative débridement

## **PANCREATIC PSEUDOCYST**

### **What is it?**

Encapsulated collection of pancreatic fluid



### **What makes it a "pseudo" cyst?**

Wall is formed by inflammatory fibrosis, NOT epithelial cell lining

### **What is the incidence?**

≈1 in 10 after alcoholic pancreatitis

### **What are the associated risk factors?**

Acute pancreatitis < chronic pancreatitis from alcohol

## **What is the most common cause of pancreatic pseudocyst in the United States?**

Chronic alcoholic pancreatitis

## **What are the symptoms?**

Epigastric pain/mass

Emesis

Mild fever

Weight loss

**Note:** Should be suspected when a patient with acute pancreatitis fails to resolve pain

## **What are the signs?**

Palpable epigastric mass, tender epigastrium, ileus

## **What is the differential diagnosis of a pseudocyst?**

Cystadenocarcinoma, cystadenoma

## **What are the possible complications of a pancreatic pseudocyst?**

Infection, bleeding into the cyst, fistula, pancreatic ascites, gastric outlet obstruction, SBO, biliary obstruction

## **What is the treatment?**

Drainage of the cyst or observation

## **What is the waiting period before a pseudocyst should be drained?**

It takes 6 weeks for pseudocyst walls to “mature” or become firm enough to hold sutures, and most will resolve during this period if they are going to

## **What percentage of pseudocysts resolve spontaneously?**

≈50%

## **What is the treatment for pseudocyst with bleeding into cyst?**

Angiogram and embolization

## **What is the treatment for pseudocyst with infection?**

Percutaneous external drainage/IV antibiotics

## What size pseudocyst should be drained?

Most experts say:

- Pseudocysts >5 cm have a small chance of resolving and have a higher chance of complications
- Calcified cyst wall
- Thick cyst wall

## What are three treatment options for pancreatic pseudocyst?

- . Percutaneous aspiration/drain
- . Operative drainage
- . Transpapillary stent via ERCP (pseudocyst must communicate with pancreatic duct)

## What is an endoscopic option for drainage of a pseudocyst?

Endoscopic cystogastrostomy

## What must be done during a surgical drainage procedure for a pancreatic pseudocyst?

**Biopsy** of the cyst wall to rule out a cystic carcinoma (e.g., cystadenocarcinoma)

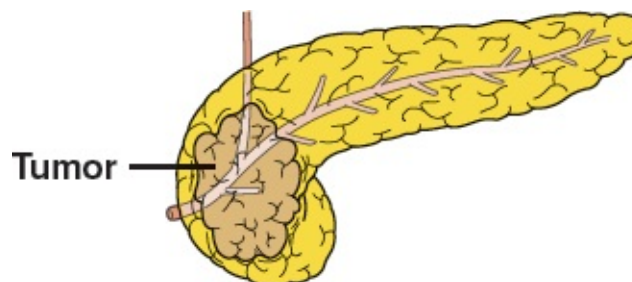
## What is the most common cause of death due to pancreatic pseudocyst?

Massive hemorrhage into the pseudocyst

# PANCREATIC CARCINOMA

## What is it?

Adenocarcinoma of the pancreas arising from duct cells



## What are the associated risk factors?

**Smoking 3× risk**, diabetes mellitus, heavy alcohol use, chronic pancreatitis, diet high in fried meats, previous gastrectomy

### **What is the average age?**

>60 years

### **What are the different types?**

>80% are duct cell adenocarcinomas; other types include cystadenocarcinoma and acinar cell carcinoma

### **What percentage arise in the pancreatic head?**

**66%** arise in the pancreatic **head**; **33%** arise in the **body and tail**

### **Why are most pancreatic cancers in the tail nonresectable?**

These tumors grow without symptoms until it is too late and they have already spread—head of the pancreas tumors draw attention earlier because of biliary obstruction

### **What are the signs/symptoms of tumors based on location:**

#### **Head of the pancreas?**

**Painless jaundice** from obstruction of common bile duct; weight loss; abdominal pain; back pain; weakness; **pruritus** from bile salts in skin; anorexia; **Courvoisier's sign**; acholic stools; dark urine; diabetes

#### **Body or tail?**

Weight loss and pain (90%); migratory thrombophlebitis (10%); jaundice (<10%); nausea and vomiting; fatigue

### **What are the most common symptoms of cancer of the pancreatic HEAD?**

- . Weight loss (90%)
- . Pain (75%)
- . Jaundice (70%)

### **What is “Courvoisier’s sign”?**

Palpable, nontender, distended gallbladder

**What is the classic presentation of pancreatic cancer in the head of the pancreas?**

Painless jaundice

**What are the associated lab findings?**

Increased direct bilirubin and alkaline phosphatase (as a result of biliary obstruction)

Increased LFTs

Elevated pancreatic tumor markers

**Which tumor markers are associated with pancreatic cancer?**

CA-19-9

**What does CA-19-9 stand for?**

Carbohydrate Antigen 19-9

**What diagnostic studies are performed?**

Abdominal CT scan, U/S, cholangiography (ERCP to rule out choledocholithiasis and cell brushings), endoscopic U/S with biopsy

**What is the treatment based on location:**

**Head of the pancreas?**

Whipple procedure (pancreaticoduodenectomy)

**Body or tail?**

Distal resection

**What factors signify inoperability?**

Vascular encasement (SMA, hepatic artery)

Liver metastasis

Peritoneal implants

Distant lymph node metastasis (periaortic/celiac nodes)

Distant metastasis

Malignant ascites

**Is portal vein or SMV involvement an absolute contraindication for resection?**

No—can be resected and reconstructed with vein interposition graft at some centers

### **Define the Whipple procedure (pancreaticoduodenectomy)**

Cholecystectomy

Truncal vagotomy

Antrectomy

Pancreaticoduodenectomy—removal of head of pancreas and duodenum

Choledochojejunostomy—anastomosis of common bile duct to jejunum

Pancreaticojejunostomy—anastomosis of distal pancreas remnant to jejunum

Gastrojejunostomy—anastomosis of stomach to jejunum

### **What mortality rate is associated with a Whipple procedure?**

<5% at busy high volume centers

### **What is the “pylorus-preserving Whipple”?**

No antrectomy; anastomose duodenum to jejunum

### **What are the possible post-Whipple complications?**

Delayed gastric emptying (if antrectomy is performed); **anastomotic leak** (from the bile duct or pancreatic anastomosis), causing pancreatic/biliary fistula; wound infection; postgastrectomy syndromes; sepsis; pancreatitis

### **Why must the duodenum be removed if the head of the pancreas is resected?**

They share the same blood supply

### **What is the postoperative adjuvant therapy?**

Chemotherapy ± XRT

### **What is the palliative treatment if the tumor is inoperable and biliary obstruction is present?**

Percutaneous transhepatic cholangiography (PTC) or ERCP and placement of stent across obstruction

### **What is the prognosis at 1 year after diagnosis?**

Dismal; 90% of patients die within 1 year of diagnosis

**What is the survival rate at 5 years after resection?**

20%

## MISCELLANEOUS

**What is an annular pancreas?**

Pancreas encircling the duodenum; if obstruction is present, bypass, **do not resect**

**What is pancreatic divisum?**

Failure of the two pancreatic ducts to fuse; the normally small duct (Small = Santorini) of Santorini acts as the main duct in pancreatic divisum (Think: the two pancreatic ducts are **D**ivided = **D**ivisum)

**What is heterotopic pancreatic tissue?**

Heterotopic pancreatic tissue usually found in the stomach, intestine, duodenum

**What is a Puestow procedure?**

Longitudinal filleting of the pancreas/pancreatic duct with a side-to-side anastomosis with the small bowel

**What medication decreases output from a pancreatic fistula?**

Somatostatin (GI-inhibitory hormone)

**Which has a longer half-life: amylase or lipase?**

Lipase; therefore, amylase may be normal and lipase will remain elevated longer

**What is the WDHA syndrome?**

Pancreatic **V**IPoma (**V**asoactive **I**ntestinal **P**olypeptide tumor)

Tumor secretes VIP, which causes:

**W**atery

**D**iarrhea

**H**ypokalemia

**A**chlorhydria (inhibits gastric acid secretion)

**What is the Whipple triad of pancreatic insulinoma?**

. Hypoglycemia (Glucose <50)

- . Symptoms of hypoglycemia: mental status changes/vasomotor instability
- . Relief of symptoms with administration of glucose

**What is the most common islet cell tumor?**

Insulinoma

**What pancreatic tumor is associated with gallstone formation?**

Somatostatinoma (inhibits gallbladder contraction)

**What is the triad found with pancreatic somatostatinoma tumor?**

- . Gallstones
- . Diabetes
- . Steatorrhea

**What are the two classic findings with pancreatic glucagonoma tumors?**

- . Diabetes
- . Dermatitis/rash (necrotizing migratory erythema)

## RAPID FIRE REVIEW

**Name the diagnostic modality:**

**40-year-old female with “migratory necrolytic dermatitis,” diabetes**

Glucagon assay (glucagon level), CT scan for glucagonoma

**What is the treatment?**

**2-year-old with annular pancreas**

Bypass obstruction

**40-year-old alcoholic with dead pancreatic tissue on CT scan develops hypotension and fever**

Operative pancreatic débridement

**What is the correct diagnosis?**

**28-year-old male with diarrhea, diabetes, and gallstones**

Somatostatinoma

**80-year-old with new onset of jaundice has a palpable, distended, nontender gallbladder on exam**

Courvoiser's sign for head of the pancreas cancer mass

# Chapter 55 Breast

## ANATOMY OF THE BREAST AND AXILLA

**What four nerves must the surgeon be aware of during an axillary dissection?**

- . Long thoracic nerve
- . Thoracodorsal nerve
- . Medial pectoral nerve
- . Lateral pectoral nerve

**Describe the location of these nerves and the muscle each innervates:**

### **Long thoracic nerve**

Courses along the lateral chest wall in midaxillary line on serratus anterior muscle; innervates serratus anterior muscle

### **Thoracodorsal nerve**

Courses lateral to long thoracic nerve on latissimus dorsi muscle; innervates latissimus dorsi muscle

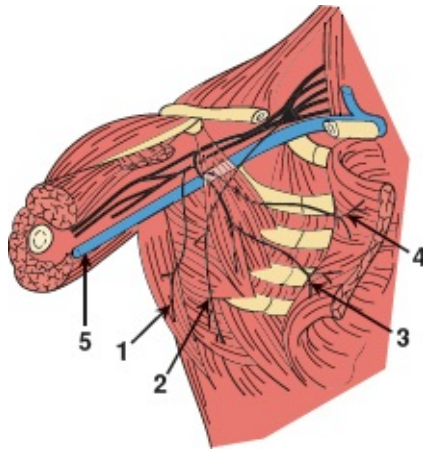
### **Medial pectoral nerve**

Runs **lateral** to or through the pectoral minor muscle, actually **lateral** to the lateral pectoral nerve; innervates the pectoral minor and pectoral major muscles

### **Lateral pectoral nerve**

Runs **medial** to the medial pectoral nerve (names describe orientation from the brachial plexus!); innervates the pectoral major

**Identify the nerves in the axilla on the illustration below:**



- . Thoracodorsal nerve
- . Long thoracic nerve
- . Medial pectoral nerve
- . Lateral pectoral nerve
- . Axillary vein

**What is the name of the deformity if you cut the long thoracic nerve in this area?**

“Winged scapula”

**What is the name of the CUTANEOUS nerve that crosses the axilla in a transverse fashion? (Many surgeons try to preserve this nerve)**

Intercostobrachial nerve

**What is the name of the large vein that marks the upper limit of the axilla?**

Axillary vein

**What is the lymphatic drainage of the breast?**

Lateral: axillary LNs

Medial: parasternal nodes that run with internal mammary artery

**What are the levels of axillary LNs?**

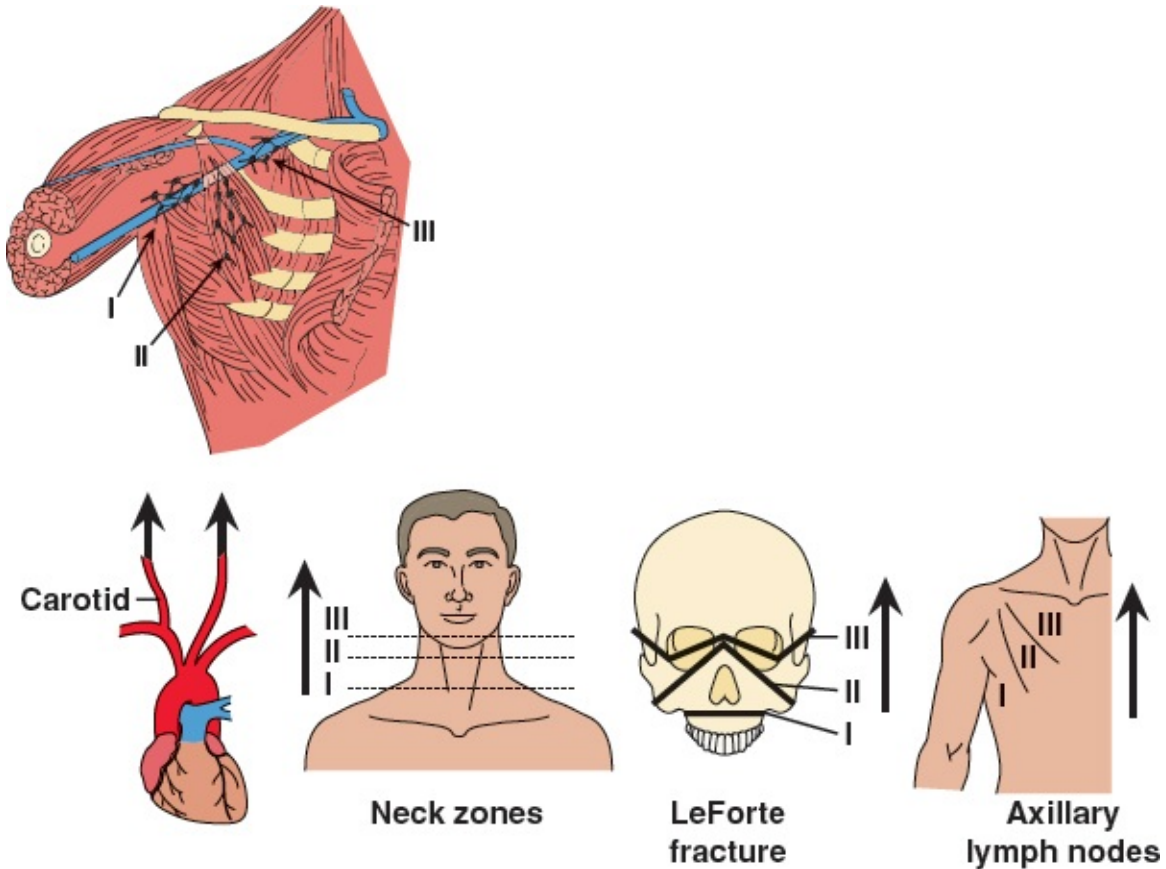
Level I (low): lateral to pectoral minor

Level II (middle): deep to pectoral minor

Level III (high): medial to pectoral minor

In breast cancer, a higher level of involvement has a worse prognosis, but the

level of involvement is less important than the number of positive nodes  
(Think: Levels I, II, and III are in the same inferior–superior anatomic order as the Le Fort facial fractures and the trauma neck zones; *I dare you to forget!*)



### What are Rotter's nodes?

Nodes between the pectoralis major and minor muscles; not usually removed unless they are enlarged or feel suspicious intraoperatively

### What are the suspensory breast ligaments called?

Cooper's ligaments

### Which hormone is mainly responsible for breast milk production?

Prolactin

## BREAST CANCER

**What is the incidence of breast cancer?**

**12% lifetime risk**

**What percentage of women with breast cancer have no known risk factor?**

**75%!**

**What percentage of all breast cancers occur in women younger than 30 years?**

**≈2%**

**What are the major breast cancer susceptibility genes?**

***BRCA1* and *BRCA2*** (easily remembered: **BR** = **B**Reast and **CA** = **C**Ancer)

**What option exists to decrease the risk of breast cancer in women with *BRCA*?**

Prophylactic bilateral mastectomy

**What is the most common motivation for medicolegal cases involving the breast?**

Failure to diagnose a breast carcinoma

**What is the “TRIAD OF ERROR” for misdiagnosed breast cancer?**

- . Age <45 years
- . Self-diagnosed mass
- . Negative mammogram

**Note:** >75% of cases of **MISDIAGNOSED** breast cancer have these three characteristics

**What are the history risk factors for breast cancer?**

**“NAACP”:**

Nulliparity

Age at menarche (<13 years)

Age at menopause (>55 years)

Cancer of the breast (in self or family)

Pregnancy with first child (>30 years)

**What are physical/anatomic risk factors for breast cancer?**

### **“CHAFED LIPS”:**

Cancer in the breast (3% synchronous contralateral cancer)

Hyperplasia (moderate/florid) (2× risk)

Atypical hyperplasia (4× risk)

Female (100× male risk)

Elderly

DCIS

LCIS

Inherited genes (BRCA I and II)

Papilloma (1.5×)

Sclerosing adenosis (1.5×)

### **Is “run of the mill” fibrocystic disease a risk factor for breast cancer?**

No

### **What are the possible symptoms of breast cancer?**

No symptoms

Mass in the breast

Pain (**most are painless**)

Nipple discharge

Local edema

Nipple retraction

Dimple

Nipple rash

### **Why does skin retraction occur?**

Tumor involvement of Cooper’s ligaments and subsequent traction on ligaments pull skin inward

### **What are the signs of breast cancer?**

Mass (1 cm is usually the smallest lesion that can be palpated on examination)

Dimple

Nipple rash

Edema

Axillary/supraclavicular nodes

**What is the most common site of breast cancer?**

≈50% of cancers develop in the upper outer quadrants

**What are the different types of invasive breast cancer?**

Infiltrating ductal carcinoma (≈75%)

Medullary carcinoma (≈15%)

Infiltrating lobular carcinoma (≈5%)

Tubular carcinoma (≈2%)

Mucinous carcinoma (colloid) (≈1%)

Inflammatory breast cancer (≈1%)

**What is the most common type of breast cancer?**

Infiltrating ductal carcinoma

**What is the differential diagnosis?**

Fibrocystic disease of the breast

Fibroadenoma

Intraductal papilloma

Duct ectasia

Fat necrosis

Abscess

Radial scar

Simple cyst

**Describe the appearance of the edema of the dermis in inflammatory carcinoma of the breast.**

Peau d'orange (orange peel)

**What are the screening recommendations for breast cancer:****Breast exam recommendations?**

Self-exam of breasts monthly

Ages 20 to 40 years: breast exam every 2 to 3 years by a physician

>40 years: annual breast exam by physician

**Mammograms?**

Mammogram every year or every other year after age 40

**When is the best time for breast self-exams?**

1 week after menstrual period

**Why is mammography a more useful diagnostic tool in older women than in younger?**

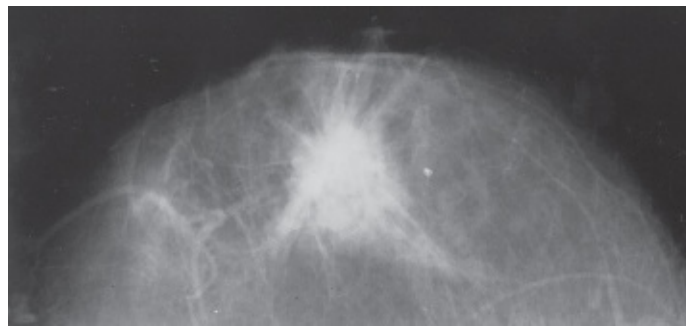
Breast tissue undergoes fatty replacement with age, making masses more visible; younger women have more fibrous tissue, which makes mammograms harder to interpret

**What are the radiographic tests for breast cancer?**

Mammography and breast ultrasound, MRI

**What is the classic picture of breast cancer on mammogram?**

Spiculated mass

**Which option is the best initial test to evaluate a breast mass in a woman <30 years?**

Breast ultrasound

**What are the methods for obtaining tissue for pathologic examination?**

Fine-needle aspiration (FNA), core biopsy (larger needle core sample), mammotome stereotactic biopsy, and open biopsy, which can be incisional (cutting a **piece** of the mass) or excisional (cutting out the **entire** mass)

**What are the indications for biopsy?**

Persistent mass after aspiration

Solid mass

Blood in cyst aspirate

Suspicious lesion by mammography/ultrasound/MRI

Bloody nipple discharge  
Ulcer or dermatitis of nipple  
Patient's concern of persistent breast abnormality

**What is the process for performing a biopsy when a nonpalpable mass is seen on mammogram?**

Stereotactic (mammotome) biopsy or needle localization biopsy

**What is a needle localization biopsy (NLB)?**

Needle localization by radiologist, followed by biopsy; removed breast tissue must be checked by mammogram to ensure all of the suspicious lesion has been excised

**What is a mammotome biopsy?**

Mammogram-guided computerized stereotatic core biopsies

**What is obtained first, the mammogram or the biopsy?**

Mammogram is obtained first; otherwise, tissue extraction (core or open) may alter the mammographic findings (fine needle aspiration may be done prior to the mammogram because the fine needle usually will not affect the mammographic findings)

**What would be suspicious mammographic findings?**

Mass, microcalcifications, stellate/spiculated mass

**What is a "radial scar" seen on mammogram?**

Spiculated mass with central lucency,  $\pm$  microcalcifications

**What tumor is associated with a radial scar?**

Tubular carcinoma; thus, biopsy is indicated

**What is the "workup" for a breast mass?**

- . Clinical breast exam
- . Mammogram or breast ultrasound
- . Fine needle aspiration, core biopsy, or open biopsy

**How do you proceed if the mass appears to be a cyst?**

Aspirate it with a needle

### **Is the fluid from a breast cyst sent for cytology?**

Not routinely; bloody fluid should be sent for cytology

### **When do you proceed to open biopsy for a breast cyst?**

- . In the case of a second cyst recurrence
- . Bloody fluid in the cyst
- . Palpable mass after aspiration

### **What is the preoperative staging workup in a patient with breast cancer?**

Bilateral mammogram (cancer in one breast is a risk factor for cancer in the contralateral breast!)

CXR (to check for lung metastasis)

LFTs (to check for liver metastasis)

Serum calcium level, alkaline phosphatase (if these tests indicate bone metastasis/“bone pain,” proceed to bone scan)

Other tests, depending on signs/symptoms (e.g., head CT scan if patient has focal neurologic deficit, to look for brain metastasis)

### **What hormone receptors must be checked for in the biopsy specimen?**

**Estrogen and progesterone receptors**—this is **key for determining adjuvant treatment**; this information must be obtained on all specimens (including fine-needle aspirates)

### **What staging system is used for breast cancer?**

**TMN: Tumor/Metastases/Nodes (AJCC)**

### **Describe the staging (simplified):**

#### **Stage I**

Tumor  $\leq 2$  cm in diameter without metastases, **no nodes**

#### **Stage IIA**

Tumor  $\leq 2$  cm in diameter with mobile axillary nodes **or**  
Tumor 2 to 5 cm in diameter, no nodes

#### **Stage IIB**

Tumor 2 to 5 cm in diameter with mobile axillary nodes **or**  
Tumor >5 cm with no nodes

### **Stage IIIA**

Tumor >5 cm with mobile axillary nodes **or**  
Any size tumor with **fixed** axillary nodes, no metastases

### **Stage IIIB**

Peau d'orange (skin edema) or  
Chest wall invasion/fixation or  
Inflammatory cancer or  
Breast skin ulceration or  
Breast skin satellite metastases or  
Any tumor and + ipsilateral **internal mammary** LNs

### **Stage IIIC**

Any size tumor, no distant metastases  
POSITIVE: supraclavicular, infraclavicular, or internal mammary LNs

### **Stage IV**

**Distant metastases** (including ipsilateral supraclavicular nodes)

### **What are the sites of metastases?**

LNs (most common)  
Lung/pleura  
Liver  
Bones  
Brain

### **What are the major treatments of breast cancer?**

Modified radical mastectomy  
Lumpectomy and radiation + sentinel LN dissection  
(Both treatments either ± postop chemotherapy/tamoxifen)

### **What are the indications for radiation therapy after a modified radical mastectomy?**

Stage IIIA  
Stage IIIB

Pectoral muscle/fascia invasion  
Positive internal mammary LN  
Positive surgical margins  
≥4 positive axillary LNs postmenopausal

### **What breast carcinomas are candidates for lumpectomy and radiation (breast-conserving therapy)?**

Stages I and II (tumors <5 cm)

### **What approach may allow a patient with stage IIIA cancer to have breast-conserving surgery?**

NEOadjuvant chemotherapy—if the preop chemo shrinks the tumor

### **What is the treatment of inflammatory carcinoma of the breast?** **Chemotherapy first!** Then often followed by radiation, mastectomy, or both

### **What is “lumpectomy and radiation”?**

Lumpectomy (segmental mastectomy: removal of a **part** of the breast); axillary node dissection; and a course of radiation therapy **after** operation, over a period of several weeks

### **What are other contraindications to lumpectomy and radiation?**

Previous radiation to the chest  
Positive margins  
Collagen vascular disease (e.g., scleroderma)  
Extensive DCIS (often seen as diffuse microcalcification)

#### **Relative contraindications:**

Lesion that cannot be seen on the mammograms (i.e., early recurrence will be missed on follow-up mammograms)  
Very small breast (no cosmetic advantage)

### **What is a modified radical mastectomy?**

Breast, axillary nodes (level II, I), and nipple–areolar complex are removed  
Pectoralis major and minor muscles are **not** removed (Auchincloss modification)  
Drains are placed to drain lymph fluid

### **Where are the drains placed with an MRM?**

. Axilla

. Chest wall (breast bed)

### **When should the drains be removed?**

<30 cc/day drainage

### **How can the long thoracic and thoracodorsal nerves be identified during an axillary dissection?**

Nerves can be stimulated with a forceps, which results in contraction of the latissimus dorsi (thoracodorsal nerve) or anterior serratus (long thoracic nerve)

### **What is a sentinel node biopsy?**

Instead of removing all the axillary LNs, the **primary** draining or “sentinel” LN is removed

### **How is the sentinel LN found?**

Inject blue dye and/or technetium-labeled sulfur colloid (best results with both)

### **What follows a positive sentinel node biopsy?**

Removal of the rest of the axillary LNs

### **What is now considered the standard of care for LN evaluation in women with T1 or T2 tumors (stages I and IIA) and clinically negative axillary LNs?**

Sentinel LN dissection

### **What do you do with a mammotome biopsy that returns as “atypical hyperplasia”?**

Open needle localization biopsy as many will have DCIS or invasive cancer

### **How does tamoxifen work?**

Binds estrogen receptors

### **What is the treatment for local recurrence in breast after lumpectomy and radiation?**

“Salvage” mastectomy

### **Can tamoxifen prevent breast cancer?**

**Yes.** In the Breast Cancer Prevention Trial of 13,000 women at increased risk of

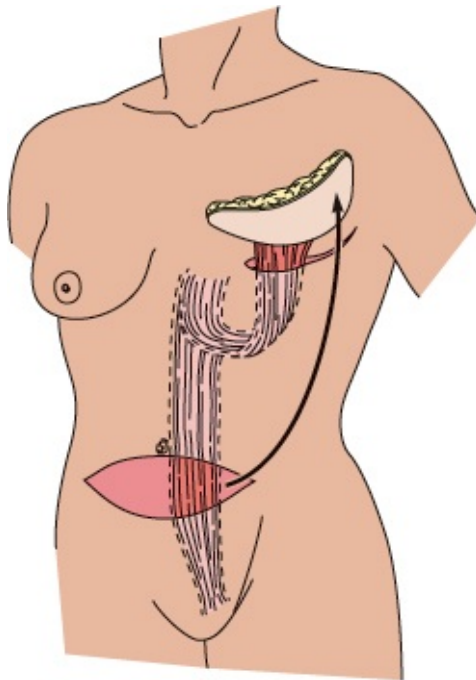
developing breast cancer, tamoxifen reduced risk by  $\approx 50\%$  across all ages

### **What are common options for breast reconstruction?**

TRAM flap, implant, latissimus dorsi flap

### **What is a TRAM flap?**

Transverse **R**ectus **A**bdominis **M**yocutaneous flap



### **What are side effects of tamoxifen?**

**Endometrial cancer** (2.5 $\times$  relative risk), DVT, pulmonary embolus, cataracts, hot flashes, mood swings

**Give the common adjuvant therapy for the following patients with breast cancer. (These are rough guidelines; check for current guidelines, as they are always changing.) (ER = estrogen receptor):**

**Premenopausal, node +, ER –**

Chemotherapy

**Premenopausal, node +, ER –**

Chemotherapy and tamoxifen

**Premenopausal, node –, ER +**

Tamoxifen and/or chemotherapy

**Postmenopausal, node +, ER +**

Tamoxifen, ± chemotherapy

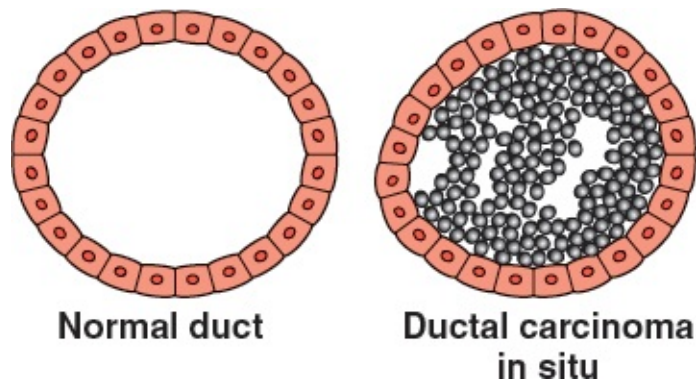
**Postmenopausal, node +, ER –**

Chemotherapy, ± tamoxifen

## DCIS

**What does DCIS stand for?**

Ductal Carcinoma In Situ



**What is DCIS also known as?**

Intraductal carcinoma

**Describe DCIS**

Cancer cells in the duct without invasion (in situ: cells do not penetrate the basement membrane)

**What are the signs/symptoms?**

Usually none; usually nonpalpable

**What are the mammographic findings?**

Microcalcifications

**How is the diagnosis made?**

Core or open biopsy

**What is the most aggressive histologic type?**

Comedo

**What is the risk of LN metastasis with DCIS?**

<2% (usually when microinvasion is seen)

**What is the major risk with DCIS?**

Subsequent development of infiltrating ductal carcinoma in the **same breast**

**What is the treatment for DCIS in the following cases:**

**Tumor <1 cm (low grade)?**

Remove with 1-cm margins and XRT

**Tumor >1 cm?**

Perform lumpectomy with 1-cm margins and radiation **or** total mastectomy  
(**no** axillary dissection)

**What is a total (simple) mastectomy?**

Removal of the breast and nipple without removal of the axillary nodes (always remove nodes with invasive cancer)

**When must a simple mastectomy be performed for DCIS?**

Diffuse breast involvement (e.g., diffuse microcalcifications), >1 cm and contraindication to radiation

**What is the role of axillary node dissection with DCIS?**

No role in true DCIS (i.e., without microinvasion); some perform a sentinel LN dissection for high-grade DCIS

**What is adjuvant Rx for DCIS?**

- . Tamoxifen if ER+
- . Postlumpectomy XRT

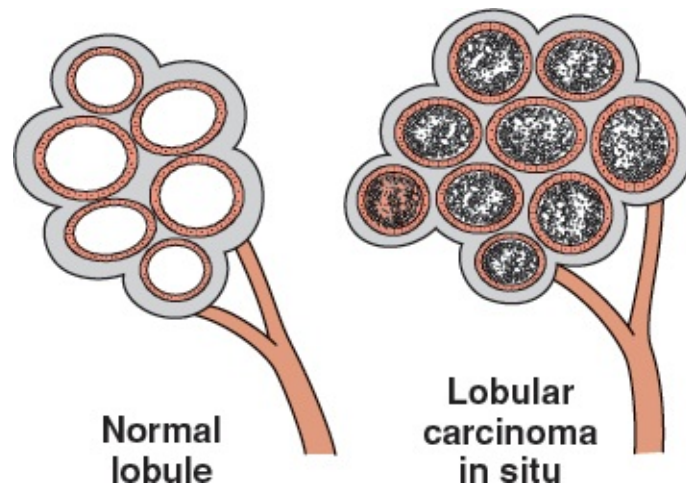
**What is a memory aid for the breast in which DCIS breast cancer arises?**

Cancer arises in the **same** breast as DCIS (Think: **DCIS** = **D**irectly in same breast)

## LCIS

### What is LCIS?

**Lobular Carcinoma In Situ** (carcinoma cells in the lobules of the breast without invasion)



### What are the signs/symptoms?

There are none

### What are the mammographic findings?

There are none

### How is the diagnosis made?

LCIS is found **incidentally** on biopsy

### What is the major risk?

Carcinoma of **either** breast

### Which breast is most at risk for developing an invasive carcinoma?

Equal risk in both breasts! (Think of LCIS as a **risk marker** for future development of cancer in either breast)

### What percentage of women with LCIS develop an invasive breast

**carcinoma?**

≈30% in the 20 years after diagnosis of LCIS!

**What type of invasive breast cancer do patients with LCIS develop?**

Most commonly, **infiltrating ductal carcinoma**, with **equal distribution** in the contralateral and ipsilateral breasts

**What medication may lower the risk of developing breast cancer in LCIS?**

Tamoxifen for 5 years will lower the risk up to 50%, but with an increased risk of endometrial cancer and clots; it must be an individual patient determination

**What is the treatment of LCIS?**

Close follow-up (or bilateral simple mastectomy in high-risk patients)

**What is the major difference in the subsequent development of invasive breast cancer with DCIS and LCIS?**

LCIS cancer develops in *either* breast; DCIS cancer develops in the ipsilateral breast

**How do you remember which breast is at risk for invasive cancers in patients with LCIS?**

Think: LCIS = **L**iberally in **e**ither breast

## MISCELLANEOUS

**What is the most common cause of bloody nipple discharge in a young woman?**

Intraductal papilloma

**What is the most common breast tumor in patients <30 years?**

Fibroadenoma

**What is Paget's disease of the breast?**

Scaling rash/dermatitis of the nipple caused by invasion of skin by cells from a ductal carcinoma

# MALE BREAST CANCER

## **What is the incidence of breast cancer in men?**

<1% of all breast cancer cases (1/150)

## **What is the average age at diagnosis?**

65 years of age

## **What are the risk factors?**

Increased estrogen

Radiation

Gynecomastia from increased estrogen

Estrogen therapy

Klinefelter's syndrome (XXY)

*BRCA2* carriers

## **Is benign gynecomastia a risk factor for male breast cancer?**

No

## **What type of breast cancer do men develop?**

Nearly 100% of cases are ductal carcinoma (men do not usually have breast lobules)

## **What are the signs/symptoms of breast cancer in men?**

Breast mass (most are painless), breast skin changes (ulcers, retraction), and nipple discharge (usually blood or a blood-tinged discharge)

## **What is the most common presentation?**

Painless breast mass

## **How is breast cancer in men diagnosed?**

Biopsy and mammogram

## **What is the treatment?**

- . Mastectomy
- . Sentinel LN dissection of clinically negative axilla
- . Axillary dissection if clinically positive axillary LN

## BENIGN BREAST DISEASE

**What is the most common cause of green, straw-colored, or brown nipple discharge?**

Fibrocystic disease

**What is the most common cause of breast mass after breast trauma?**

Fat necrosis

**What must be ruled out with spontaneous galactorrhea (+/- amenorrhea)?**

Prolactinoma (check pregnancy test and prolactin level)

## CYSTOSARCOMA PHYLLODES

**What is it?**

Mesenchymal tumor arising from breast lobular tissue; most are benign (**Note:** “Sarcoma” is a misnomer, as the vast majority are benign; 1% of breast cancers)

**What is the usual age of the patient with this tumor?**

35 to 55 years (usually older than the patient with fibroadenoma)

**What are the signs/symptoms?**

Mobile, smooth breast mass that resembles a fibroadenoma on exam, mammogram/ultrasound findings

**How is it diagnosed?**

Through core biopsy or excision

**What is the treatment?**

If benign, wide local excision; if malignant, simple total mastectomy

**What is the role of axillary dissection with cystosarcoma phyllodes tumor?**

Only if clinically palpable axillary nodes, as the malignant form rarely spreads to

nodes (most common site of metastasis is the lung)

### **Is there a role for chemotherapy with cystosarcoma phyllodes?**

Consider chemotherapy if large tumor >5 cm and “stromal overgrowth”

## **FIBROADENOMA**

### **What is it?**

Benign tumor of the breast consisting of stromal overgrowth, collagen arranged in “swirls”

### **What is the clinical presentation of a fibroadenoma?**

Solid, mobile, **well-circumscribed** round breast mass, usually <40 years of age

### **How is fibroadenoma diagnosed?**

Negative needle aspiration looking for fluid; ultrasound; core biopsy

### **What is the treatment?**

Surgical resection for large or growing lesions; small fibroadenomas can be observed closely

### **What is this tumor’s claim to fame?**

Most common breast tumor in women <30 years

## **FIBROCYSTIC DISEASE**

### **What is it?**

Common benign breast condition consisting of fibrous (rubbery) and cystic changes in the breast

### **What are the signs/symptoms?**

Breast pain or tenderness that varies with the menstrual cycle; cysts; and fibrous (“nodular”) fullness

### **How is it diagnosed?**

Through breast exam, history, and aspirated cysts (usually straw-colored or

green fluid)

### **What is the treatment for symptomatic fibrocystic disease?**

Stop caffeine

Pain medications (NSAIDs)

Vitamin E, evening primrose oil (danazol and OCP as last resort)

### **What is done if the patient has a breast cyst?**

Needle drainage: If aspirate is bloody or a palpable mass remains after aspiration, an open biopsy is performed

If the aspirate is straw colored or green, the patient is followed closely; then, if there is recurrence, a second aspiration is performed

Re-recurrence usually requires open biopsy

## **MASTITIS**

### **What is it?**

Superficial infection of the breast (cellulitis)

### **In what circumstance does it most often occur?**

Breastfeeding

### **What bacteria are most commonly the cause?**

*Staphylococcus aureus*

### **How is mastitis treated?**

Stop breastfeeding and use a breast pump instead; apply heat; administer antibiotics

### **Why must the patient with mastitis have close follow-up?**

To make sure that she does not have inflammatory breast cancer!

## **BREAST ABSCESS**

### **What are the causes?**

Mammary ductal ectasia (stenosis of breast duct) and mastitis

**What is the most common bacteria?**

Nursing = *S. aureus*

Nonlactating = mixed infection

**What is the treatment of breast abscess?**

Antibiotics (e.g., dicloxacillin)

Needle or open drainage with cultures taken

Resection of involved ducts if recurrent

Breast pump if breastfeeding

**What is lactational mastitis?**

Infection of the breast during breastfeeding—most commonly caused by *S. aureus*; treat with antibiotics and follow for abscess formation

**What must be ruled out with a breast abscess in a nonlactating woman?**

Breast cancer!

## MALE GYNECOMASTIA

**What is it?**

Enlargement of the male breast

**What are the causes?****Medications**

Drugs (marijuana)

Liver failure

Increased estrogen

Decreased testosterone

**What is the major differential diagnosis in the older patient?**

Male breast cancer

**What is the treatment?**

Stop or change medications; correct underlying cause if there is a hormonal imbalance; and perform biopsy or subcutaneous mastectomy (i.e., leave nipple) if refractory to conservative measures and time

## Rapid Fire Review

**Name the most likely diagnosis:**

**45-year-old woman with itching of the right nipple for 6 months and a right breast mass**

Paget's disease (infiltrating ductal carcinoma with spread to the nipple)

**60-year-old man with nipple discharge**

Male breast cancer

**36-year-old woman with a right breast mass after hitting her right breast on a door handle**

Fat necrosis

**39-year-old woman with bilateral milky breast discharge, decreased lateral vision fields, and pituitary mass**

Prolactinoma

**28-year-old woman with unilateral green-brown nipple discharge increasing immediately before menses?**

Fibrocystic disease

**25-year-old female with bloody nipple discharge**

Ductal papilloma

**56-year-old female with a red breast, no fever, no leukocytosis; on exam. the skin looks swollen like an orange**

Inflammatory breast cancer with peau d'orange (orange peel skin) on exam

**40-year-old female without a palpable breast mass has "microcalcifications" on mammogram**

Ductal Carcinoma In Situ (DCIS)

**2 weeks' s/p modified radical mastectomy a 45-year-old woman with infiltrating ductal cancer of the right breast returns to the**

**clinic and complains of her right scapula “sticking out”**

Winged scapula due to injury to the long thoracic nerve

**Name the diagnostic modality:**

**28-year-old female with history of bloody nipple discharge  
mammogram is negative**

Galactography to look for ductal papilloma

# Chapter 56 Endocrine

## ADRENAL GLAND

### ■ Anatomy

**Where is the drainage of the *left* adrenal vein?**

Left renal vein

**Where is the drainage of the *right* adrenal vein?**

Inferior vena cava (IVC)

### ■ Normal Adrenal Physiology

**What is CRH?**

**Corticotropin-Releasing Hormone:** released from anterior hypothalamus and causes release of ACTH from anterior pituitary

**What is ACTH?**

**AdrenoCorticoTropic Hormone:** released normally by anterior pituitary, which in turn causes adrenal gland to release cortisol

**What feeds back to inhibit ACTH secretion?**

Cortisol

### ■ Cushing's Syndrome

**What is Cushing's syndrome?**

Excessive **cortisol** production (Think: Cushing's = Cortisol)

### **What is the most common cause?**

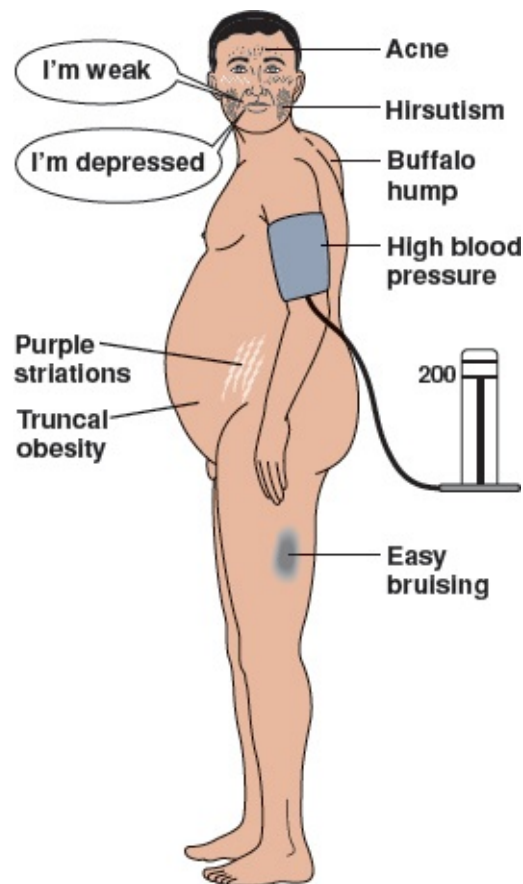
Iatrogenic (i.e., prescribed prednisone)

### **What is the second most common cause?**

Cushing's disease (most common noniatrogenic cause)

### **What is Cushing's disease?**

Cushing's syndrome caused by excess production of ACTH by anterior **pituitary**



### **What is an ectopic ACTH source?**

Tumor not found in the pituitary that secretes ACTH, which in turn causes adrenal gland to release cortisol without the normal negative feedback loop

### **What are the signs/symptoms of Cushing's syndrome?**

Truncal obesity, hirsutism, "moon" facies, acne, "buffalo hump," purple striae,

hypertension, diabetes, weakness, depression, easy bruising, myopathy

**How can cortisol levels be indirectly measured over a short duration?**

By measuring urine cortisol or the breakdown product of cortisol, 17 hydroxycorticosteroid (**17-OHCS**), in the urine

**What is a direct test of serum cortisol?**

Serum cortisol level (highest in the morning and lowest at night in healthy patients)

**What initial tests should be performed in Cushing's syndrome?**

Electrolytes

Serum cortisol

Urine-free cortisol, urine 17-OHCS

Low-dose dexamethasone-suppression test

**What is the low-dose dexamethasone suppression test?**

Dexamethasone is a synthetic cortisol that results in negative feedback on ACTH secretion and subsequent cortisol secretion in healthy patients; patients with **Cushing's syndrome** do **not** suppress their cortisol secretion

**After the dexamethasone test, what is next?**

Check ACTH levels

**In ACTH-dependent Cushing's syndrome, how do you differentiate between a pituitary versus an ectopic ACTH source?**

High-dose dexamethasone test:

**Pituitary source**—cortisol is suppressed

**Ectopic ACTH source**—no cortisol suppression

**What is the most common site of ectopic ACTH-producing tumor?**

>66% are oat cell tumors of the lung (#2 is carcinoid)

**How are the following tumors treated:**

**Adrenal adenoma?**

Adrenalectomy (almost always **unilateral**)

### **Adrenal carcinoma?**

Surgical excision (only 33% of cases are operable)

### **Ectopic ACTH-producing tumor?**

Surgical excision, if feasible

### **Cushing's *disease*?**

Transphenoidal adenomectomy

### **What is a complication of BILATERAL adrenalectomy?**

Nelson's syndrome—occurs in 10% of patients after bilateral adrenalectomy

### **What is Nelson's syndrome?**

Functional pituitary adenoma producing excessive ACTH and mass effect producing visual disturbances, hyperpigmentation, amenorrhea, with elevated ACTH levels (Think: Nelson = Nuclear reaction in the pituitary)

## **Adrenal Incidentaloma**

### **What is an incidentaloma?**

Tumor found in the adrenal gland **incidentally** on a CT scan performed for an unrelated reason

### **What is the incidence of incidentalomas?**

4% of all CT scans (9% of autopsies)

### **What is the most common cause of incidentaloma?**

Nonfunctioning adenoma (>75% of cases)

### **What is the risk factor for carcinoma?**

Solid tumor >6 cm in diameter

### **What is the treatment?**

Controversial for smaller/medium-sized tumors, but almost all surgeons would agree that resection is indicated for solid incidentalomas >6 cm in diameter because of risk of cancer

**What tumor must be ruled out prior to biopsy or surgery for any adrenal mass?**

Pheochromocytoma (24-hour urine for catecholamine, VMA, metanephrines)

## ■ Pheochromocytoma

**What is it?**

Tumor of the adrenal **MEDULLA** and sympathetic ganglion (from chromaffin cell lines) that produces **catecholamines** (norepinephrine > epinephrine)

**What is the incidence?**

Cause of hypertension in  $\approx 1/500$  hypertensive patients ( $\approx 10\%$  of U.S. population has hypertension)

**Which age group is most likely to be affected?**

Any age (children and adults); average age is 40 to 60 years

**What are the associated risk factors?**

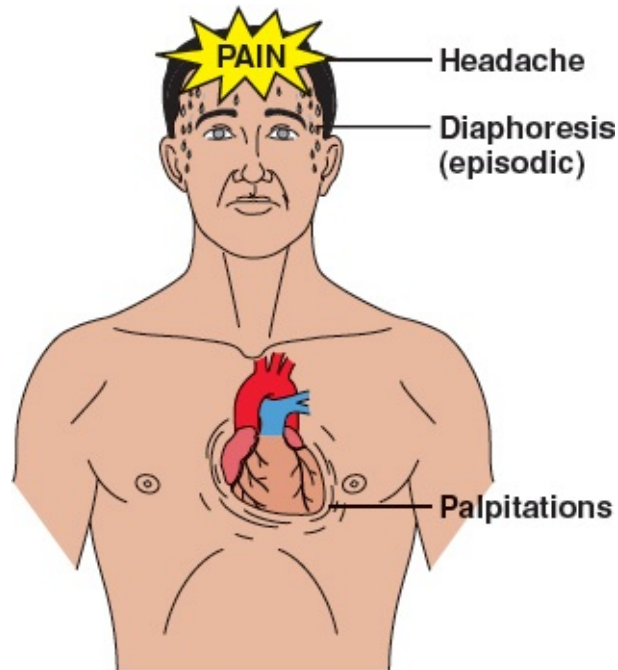
MEN-II, family history, von Recklinghausen disease, von Hippel–Lindau disease

**What are the signs/symptoms?**

“Classic” triad:

1. **Palpitations**
2. **Headache**
3. **Episodic diaphoresis**

Also, hypertension (50%), pallor → flushing, anxiety, weight loss, tachycardia, hyperglycemia



**How can the pheochromocytoma SYMPTOMS triad be remembered?**

Think of the first three letters in the word **PHE**ochromocytoma:

**P**alpitations

**H**eadache

**E**pisodic diaphoresis

**What is the most common sign of pheochromocytoma?**

Hypertension

**What diagnostic tests should be performed?**

Urine screen: **V**anillyl**M**andelic Acid (**VMA**), **metanephrine**, and normetanephrine (all breakdown products of the catechols)

Urine/serum epinephrine/norepinephrine levels

**What are the other common lab findings?**

Hyperglycemia (epinephrine increases glucose, norepinephrine decreases insulin)

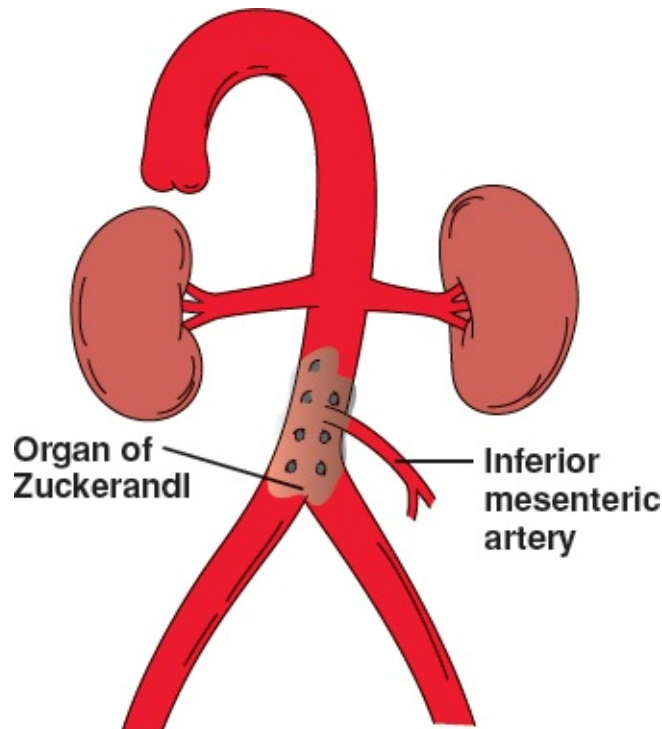
Polycythemia (resulting from intravascular volume depletion)

**What is the most common site of a pheochromocytoma?**

**Adrenal** >90%

## What are the other sites for pheochromocytoma?

Organ of Zuckerkandl, thorax (mediastinum), bladder, scrotum



## What are the tumor localization tests?

CT scan, MRI,  $^{131}\text{I}$ -MIBG, PET scan, OctreoScan ( $^{111}\text{In}$ -pentetreotide scan)

## What does $^{131}\text{I}$ -MIBG stand for?

Iodine $^{131}$  MetaIodoBenzylGuanidine

## How to remember MIBG and pheochromocytoma?

Think: MIBG = My Big = and thus “My Big Pheo” = MIBG Pheo

## How does the $^{131}\text{I}$ -MIBG scan work?

$^{131}\text{I}$ -MIBG is a norepinephrine analog that collects in adrenergic vesicles and, thus, in pheochromocytomas

## What is the role of PET scan?

Positron-Emission Tomography is helpful in localizing pheochromocytomas that do not accumulate MIBG

## What is the scan for imaging adrenal cortical pheochromocytoma?

NP-59 (cholesterol analog)

**What is the localizing option if a tumor is not seen on CT scan, MRI, or I-MIBG?**

IVC venous sampling for catecholamines (gradient will help localize the tumor)

**What is the tumor site if epinephrine is elevated?**

Must be adrenal or near the adrenal gland (e.g., organ of Zuckerkandl), because nonadrenal tumors lack the capability to methylate norepinephrine to epinephrine

**Can histology be used to determine malignancy?**

No; only distant metastasis or invasion can determine malignancy

**What is the classic pheochromocytoma “rule of 10’s”?**

**10% malignant**

**10% bilateral**

**10% in children**

**10% multiple tumors**

**10% extra-adrenal**

**What is the preoperative/medical treatment?**

**Increase intravascular volume** with  $\alpha$ -blockade (e.g., phenoxybenzamine or prazosin) to allow reduction in catecholamine-induced vasoconstriction and resulting volume depletion; treatment should start as soon as diagnosis is made  $\pm$   $\beta$ -blockers

**How can you remember phenoxybenzamine as a medical treatment of pheochromocytoma?**

**PHE**ochromocytoma = **PHE**noxybenzamine

**What is the surgical treatment?**

Tumor resection with early ligation of venous drainage (lower possibility of catecholamine release/crisis by tying off drainage) and minimal manipulation

**What are the possible perioperative complications?**

Anesthetic challenge: hypertensive crisis with manipulation (treat with nitroprusside), hypotension with total removal of the tumor, cardiac

dysrhythmias

**In the patient with pheochromocytoma, what must be ruled out?**

MEN type II (almost all cases are bilateral)

**What is the organ of Zuckerkandl?**

Body of embryonic chromaffin cells around the abdominal aorta (near the inferior mesenteric artery); normally atrophies during childhood, but is the most common site of extra-adrenal pheochromocytoma

## ■ Conn's Syndrome

**What is it?**

Primary hyperaldosteronism due to high aldosterone production

**How do you remember what Conn's syndrome is?**

CONN's disease = **HYPERAL**dosterone = “**CON HYPER AL**”



**What are the common sources?**

**Adrenal adenoma** or **adrenal hyperplasia**; aldosterone is abnormally secreted

by an adrenal adenoma (66%) > hyperplasia > carcinoma

### **What is the normal physiology for aldosterone secretion?**

BP in the renal afferent arteriole is low

Low sodium and hyperkalemia cause **renin** secretion from juxtaglomerular cells

Renin then converts angiotensinogen to angiotensin I

Angiotensin converting enzyme in the lung then converts angiotensin I to  
angiotensin II

Angiotensin II then causes the adrenal glomerulosa cells to secrete **aldosterone**

### **What is the normal physiologic effect of aldosterone?**

Aldosterone causes sodium retention for exchange of potassium in the kidney,  
resulting in fluid retention and increased BP

### **What are the signs/symptoms?**

**Hypertension**, headache, polyuria, weakness

### **What are the two classic clues of Conn's syndrome?**

- . Hypertension
- . Hypokalemia

### **What diagnostic tests should be ordered?**

- . Plasma aldosterone concentration
- . Plasma renin activity

### **What ratio of these diagnostic tests is associated with primary hyperaldosteronism?**

Aldosterone-to-renin ratio of >30

### **What diagnostic tests should be performed?**

CT scan, adrenal venous sampling for aldosterone levels, saline infusion

### **What is the saline infusion test?**

Saline infusion will decrease aldosterone levels in normal patients but not in  
Conn's syndrome

### **What is the preoperative treatment?**

Spirolactone, K<sup>+</sup> supplementation

**What is spironolactone?**

Antialdosterone medication (works at the kidney tubule)

**What are the causes of Conn's syndrome?**

Adrenal adenoma (66%)

Bilateral idiopathic adrenal hyperplasia (30%)

Adrenal cancer (<1%)

**What is the treatment of the following conditions:****Adenoma?**

Unilateral adrenalectomy (laparoscopic)

**Unilateral hyperplasia?**

Unilateral adrenalectomy (laparoscopic)

**Bilateral hyperplasia?**

Spironolactone (usually no surgery)

**What are the renin levels in patients with PRIMARY hyperaldosteronism?**

Normal or low (key point!)

## ADDISON'S DISEASE

**What is it?**

Acute adrenal insufficiency

**What are the electrolyte findings?**

HYPERkalemia, hyponatremia

**How do you remember what ADDISON's disease is?**

Think: **ADD**ison's disease = **AD**renal **D**own

## INSULINOMA

**What is it?**

Insulin-producing tumor arising from  $\beta$  cells

**What is the incidence?**

#1 islet cell neoplasm; half of  $\beta$ -cell tumors of the pancreas produce insulin

**What are the associated risks?**

Associated with MEN-I syndrome (**PPP** = **P**ituitary, **P**ancreas, **P**arathyroid tumors)

**What are the signs/symptoms?**

**Sympathetic nervous system symptoms resulting from hypoglycemia:**  
palpitations, diaphoresis, tremulousness, irritability, weakness

**What are the neurologic symptoms?**

Personality changes, confusion, obtundation, seizures, coma

**What is Whipple's triad?**

- . Hypoglycemic symptoms produced by fasting
- . Blood glucose  $<50$  mg/dL during symptomatic attack
- . Relief of symptoms by administration of glucose

**What lab tests should be performed?**

Glucose and insulin levels during fast; C-peptide and proinsulin levels (if self-injection of insulin is a concern, as insulin injections have **no** proinsulin or C-peptides)

**What diagnostic tests should be performed?**

Fasting hypoglycemia with inappropriately high levels of insulin

**72-hour fast**, then check glucose and insulin levels every 6 hours (monitor very closely because patient can develop hypoglycemic crisis)

**What is the diagnostic fasting insulin-to-glucose ratio?**

$>0.4$

**What localizing tests should be performed?**

CT scan, A-gram, endoscopic U/S, venous catheterization (to sample blood along portal and splenic veins to measure insulin and localize tumor),

intraoperative U/S

**What is the medical treatment?**

Diazoxide, to suppress insulin release

**What is the surgical treatment?**

Surgical resection

**What is the prognosis?**

≈80% of patients have a benign solitary adenoma that is cured by surgical resection

## GLUCAGONOMA

**What is it?**

Glucagon-producing tumor

**Where is it located?**

Pancreas (usually in the tail)

**What are the symptoms?**

**Necrotizing migratory erythema** (usually below the waist), glossitis, stomatitis, diabetes

**What are the skin findings?**

Necrotizing migratory erythema is a red, often psoriatic-appearing rash with serpiginous borders over the trunk and limbs

**What stimulation test is used for glucagonoma?**

Tolbutamide stimulation test: IV tolbutamide results in elevated glucagon levels

**What test is used for localization?**

CT scan

**What is the medical treatment of necrotizing migratory erythema?**

Somatostatin, IV amino acids

## What is the treatment?

Surgical resection

# SOMATOSTATINOMA

## What is it?

Pancreatic tumor that secretes somatostatin

## What is the diagnostic triad?

“DDD”:

1. Diabetes
2. Diarrhea (steatorrhea)
3. Dilation of the gallbladder with gallstones

## What is used to make the diagnosis?

CT scan and somatostatin level

## What is the treatment?

Resection (do not enucleate)

# ZOLLINGER–ELLISON SYNDROME (Z-E SYNDROME)

## What is it?

**Gastrinoma:** non- $\beta$  islet cell tumor of the pancreas (or other locale) that produces gastrin, causing gastric hypersecretion of HCl acid, resulting in GI ulcers

## What is the incidence?

1/1000 in patients with peptic ulcer disease, but nearly 2% in patients with recurrent ulcers

## What is the associated syndrome?

MEN-I syndrome

**What percentage of patients with Z-E syndrome have MEN-I syndrome?**

≈25% (75% of cases of Z-E syndrome are “sporadic”)

**What percentage of patients with MEN-I will have Z-E syndrome?**

≈50%

**With gastrinoma, what lab tests should be ordered to screen for MEN-I?**

- . Calcium level
- . Parathyroid hormone level

**What are the signs/symptoms?**

Peptic ulcers, diarrhea, weight loss, abdominal pain

**What causes the diarrhea?**

Massive acid hypersecretion and destruction of digestive enzymes

**What are the signs?**

**PUD** (epigastric pain, hematemesis, melena, hematochezia), GERD, diarrhea, **recurrent ulcers**, ulcers in unusual locations (e.g., proximal jejunum)

**What are the possible complications?**

GI hemorrhage/perforation, gastric outlet obstruction/stricture, metastatic disease

**Which patients should have a gastrin level checked?**

Those with recurrent ulcer; ulcer in unusual position (e.g., jejunum) or refractory to medical management; before any operation for ulcer

**What lab tests should be performed?**

Fasting gastrin level  
Postsecretin challenge gastrin level  
Calcium (screen for MEN-I)  
Chem 7

**What are the associated gastrin levels?**

NL fasting = 100 pg/mL  
Z-E syndrome fasting = 200 to 1000 pg/mL

### What is the secretin-stimulation test?

IV secretin is administered and the gastrin level is determined; patients with Z-E Syndrome have a paradoxical increase in gastrin

### What are the classic secretin stimulation results?

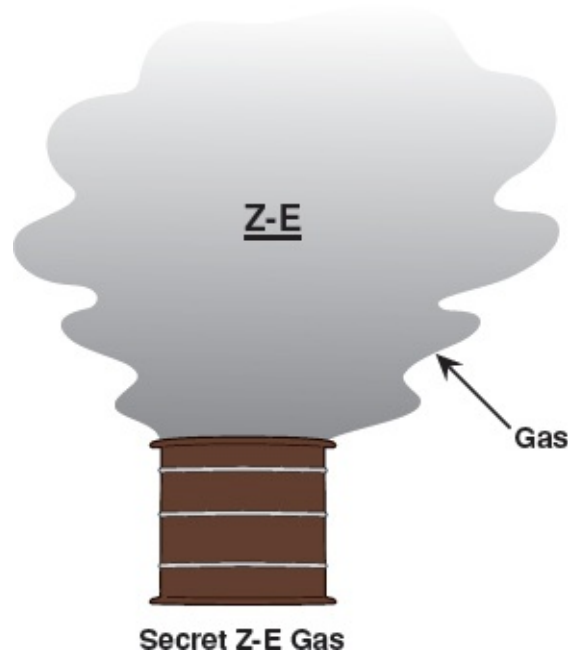
#### Lab results with secretin challenge:

NL—Decreased gastrin

Z-E syndrome—Increased gastrin (increased by  $>200$  pg/mL)

### How can you remember the diagnostic stimulation test for Z-E syndrome?

Think: “Secret Z-E GAS”: SECRETin = Z-E GAStrin



### What tests are used to evaluate ulcers?

EGD, UGI, or both

### What tests are used to localize the tumor?

**Octreotide scan** (somatostatin-receptor scan), abdominal CT scan, MRI, endoscopic ultrasonography (EUS)

### What is the most common site?

Pancreas

**What is the most common NONpancreatic site?**

Duodenum

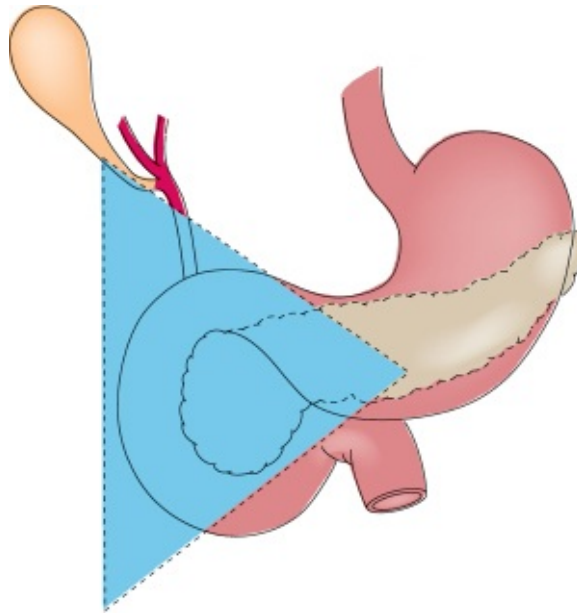
**What are some other sites?**

Stomach, lymph nodes, liver, kidney, ovary

**Define “Passaro’s triangle.”**

A.k.a. “gastrinoma triangle,” a triangle drawn from the following points:

1. Cystic duct/CBD junction
2. Junction of the second and third portions of the duodenum
3. Neck of the pancreas



**What percentage of gastrinomas are in Passaro’s triangle?**

≈80%

**What is the medical treatment?**

H<sub>2</sub> blockers, omeprazole, somatostatin

**What is the surgical treatment needed for each of the following:**

**Tumor in head of pancreas?**

- . Enucleation of tumor
- . Whipple procedure if main pancreatic duct is involved

**Tumor in body or tail of pancreas?**

Distal pancreatectomy

**Tumor in duodenum?**

Local resection

**Unresectable tumor?**

Highly selective vagotomy

**What percentage have malignant tumors?**

66%

**What is the most common site of metastasis?**

Liver

**What is the treatment of patients with liver metastasis?**

Excision, if technically feasible

**What is the prognosis with the following procedures:****Complete excision?**

90% 10-year survival

**Incomplete excision?**

25% 10-year survival

## **MULTIPLE ENDOCRINE NEOPLASIA**

**What is it also known as?**

MEN syndrome

**What is it?**

Inherited condition of propensity to develop multiple endocrine tumors

**How is it inherited?**

Autosomal dominant (but with a significant degree of variation in penetrance)

## Which patients should be screened for MEN?

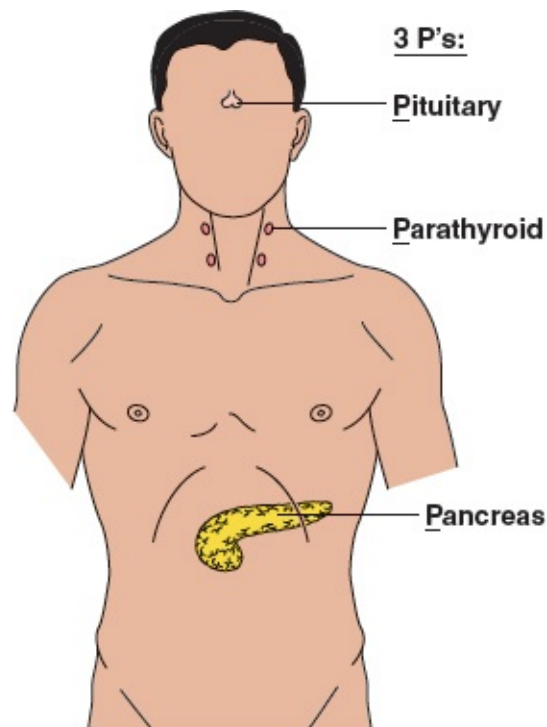
All family members of patients diagnosed with MEN

## MEN TYPE I

### What is the gene defect in MEN type I?

Chromosome 11 (Think: 11 = 1)

### What are the most common tumors and their incidences?



### “PPP”:

- P**arathyroid hyperplasia (≈90%)
- P**ancreatic islet cell tumors (≈66%)
- P**ancreas: Gastrinoma: ZE syndrome (50%)
- P**ituitary tumors (≈50%)

### How can tumors for MEN-I be remembered?

Think: type **1** = **P**arathyroid, **P**ancreas, **P**ituitary

### **How can the P's associated with MEN-I be remembered?**

All the P's are followed by a vowel: PA, PA, PI

### **What are the highest-yield screening lab tests for MEN-I?**

- . Calcium
- . PTH
- . Gastrin
- . Prolactin (in females)

### **What percentage of patients with MEN-I have parathyroid hyperplasia?**

≈90%

### **What percentage of patients with MEN-I have a gastrinoma?**

≈50%

### **What other tumors (in addition to PPP) are associated with MEN-I?**

Adrenal (30%) and thyroid (15%) adenomas

## **■ Men Type IIA**

### **What is the gene defect in MEN type IIA?**

RET (Think: reT = Two)

### **What are the most common tumors and their incidences?**

**“MPH”:**

**M**edullary thyroid carcinoma (100%); Calcitonin secreted

**P**heochromocytoma (>33%); Catecholamine excess

**H**yperparathyroidism (≈50%); Hypercalcemia

### **How can the tumors involved with MEN-IIa be remembered?**

Think: type 2 = 2 MPH or 2 Miles Per Hour = MPH = Medullary, Pheochromocytoma, Hyperparathyroid

### **How can the P of MPH be remembered?**

Followed by the consonant “H”—**PHEOCHROMOCYTOMA** (remember, the

P's of MEN-I are followed by vowels)

**What percentage of patients with MEN-IIa have medullary carcinoma of the thyroid?**

100%

**What are the best screening lab tests for MEN-II?**

- . Calcitonin level ( $\pm$  stimulation)
- . Calcium levels
- . PTH
- . Catecholamines and metabolites (metanephrine and normetanephrine)
- . RET gene testing

## ■ Men Type IIB

**What are the most common abnormalities, their incidences, and symptoms?**

**“MMMP”:**

**M**ucosal neuromas (100%)—in the nasopharynx, oropharynx, larynx, and conjunctiva

**M**edullary thyroid carcinoma ( $\approx$ 85%)—more aggressive than in MEN-IIa

**M**arfanoid body habitus (long/lanky)

**P**heochromocytoma ( $\approx$ 50%) and found bilaterally

**How can the features of MEN-IIb be remembered?**

**MMMP** (Think: **3M P**lastics)

**How can you remember that MEN-IIb is marfanoid habitus?**

Think: “**TO BE** marfanoid” = **II B** marfanoid

**What is the anatomic distribution of medullary thyroid carcinoma in MEN-II?**

**Almost always bilateral** (non–MEN-II cases are almost always **unilateral!**)

**What are the physical findings/signs of MEN-IIb?**

Mucosal neuromas (e.g., mouth, eyes)

Marfanoid body habitus

Pes cavus/planum (large arch of foot/flatfooted)

Constipation

### **What is the major difference between MEN-IIa and MEN-IIb?**

MEN-IIa = parathyroid hyperplasia

MEN-IIb = **no** parathyroid hyperplasia (and neuromas, marfanoid habitus, pes cavus [extensive arch of foot], etc.)

### **What type of parathyroid disease is associated with MEN-I and MEN-IIa?**

**Hyperplasia** (treat with removal of all parathyroid tissue with autotransplant of some of the parathyroid tissue to the forearm)

## **RAPID FIRE REVIEW**

### **Name the diagnostic stimulation test for the following:**

#### **Conn's disease**

Captopril (plasma aldosterone  $>15 \mu\text{g/dL}$ ) or high-sodium diet (no suppression of plasma renin activity)

#### **Insulinoma**

Fasting glucose

#### **Zollinger–Ellison syndrome**

Secretin

#### **Adrenal insufficiency**

ACTH stimulation test (corticotropin  $250 \mu\text{g}$ )

#### **Pituitary versus ectopic/adrenal source of hypercortisolism**

High-dose dexamethasone suppression test: most pituitary causes will suppress

Metypapone test: most pituitary causes will result in an increase in ACTH

**Name the diagnostic modality:**

**37-year-old with history of palpitations, episodic diaphoresis, and his blood pressure is 210/110**

MIBG (metaiodobenzylguanidine) scan, CT scan (and/or MRI), and urine VMA/metanephrines/catecholes for work up for pheochromocytoma

**What is the treatment?**

**39-year-old female with Cushing's disease**

Transsphenoidal adenomectomy

**44-year-old female develops headaches and cannot see right or left peripherally**

Pituitary prolactinoma

**Name the radiographic test for localizing the following:**

**Conn's disease**

CT scan, adrenal vein sampling for aldosterone and cortisol

**Pheochromocytoma**

MIBG

**Glucagonoma**

CT scan

**Carcinoid?**

<sup>111</sup>In-octreotide scintigraphy, MIBG

**Gastrinoma (Zollinger–Ellison syndrome)?**

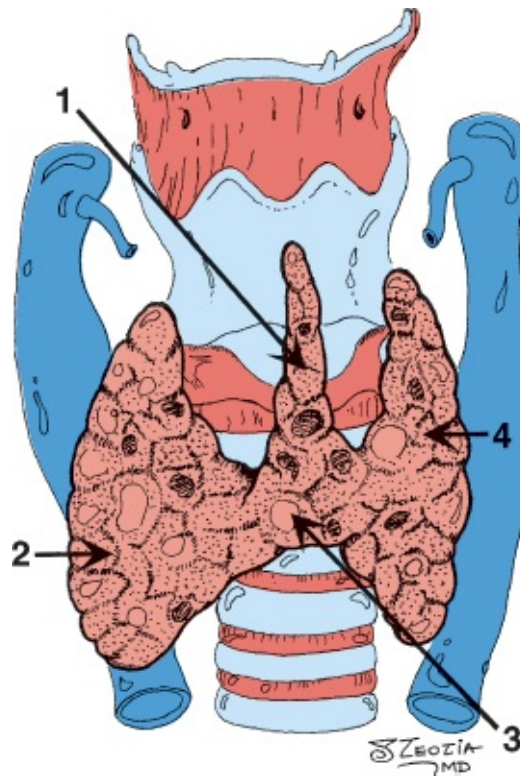
<sup>111</sup>In-octreotide scintigraphy, CT scan, endoscopic ultrasound, MRI

# Chapter 57 Thyroid Gland

## THYROID DISEASE

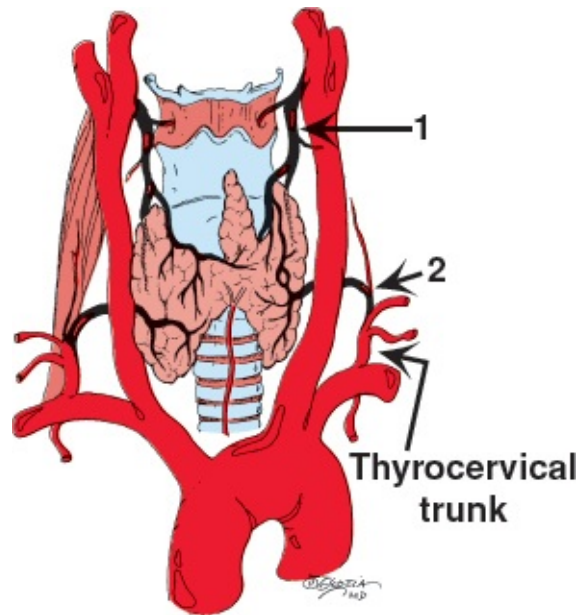
### Anatomy

Identify the following structures:



- . Pyramidal lobe
- . Right lobe
- . Isthmus
- . Left lobe

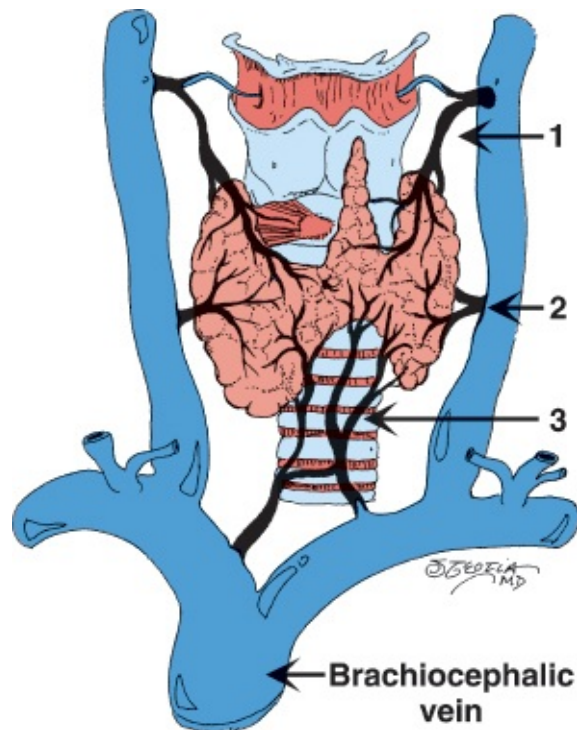
**Define the arterial blood supply to the thyroid**



### Two arteries:

1. Superior thyroid artery (first branch of the external carotid artery)
2. Inferior thyroid artery (branch of the thyrocervical trunk) (IMA artery rare)

### What is the venous drainage of the thyroid?



### Three veins:

1. Superior thyroid vein
2. **Middle** thyroid vein
3. Inferior thyroid vein

**Name the thyroid lobe appendage coursing toward the hyoid bone from around the thyroid isthmus**

Pyramidal lobe

**What percentage of patients have a pyramidal lobe?**

≈50%

**Name the lymph node (LN) group around the pyramidal thyroid lobe.**

Delphian LN group

**What is the thyroid isthmus?**

Midline tissue border between the left and right thyroid lobes

**Which ligament connects the thyroid to the trachea?**

Ligament of Berry

**Which paired nerves must be carefully identified during a thyroidectomy?**

**Recurrent laryngeal nerves**, which are found in the tracheoesophageal grooves and dive behind the cricothyroid muscle; damage to these nerves paralyzes laryngeal abductors and causes hoarseness if unilateral, and airway obstruction if bilateral

**What other nerve is at risk during a thyroidectomy and what are the symptoms?**

**Superior laryngeal nerve**; if damaged, patient will have a deeper and quieter voice (unable to hit high pitches)

**What is the name of the famous opera singer whose superior laryngeal nerve was injured during thyroidectomy?**

**Urban legend** has it that it was Amelita Galli-Curci, but no objective data support such a claim (*Ann Surg* 233:588, April 2001)

## ■ Physiology

### **What is TRH?**

**Thyrotropin-Releasing Hormone** released from the hypothalamus; causes release of TSH

### **What is TSH?**

**Thyroid-Stimulating Hormone** released by the anterior pituitary; causes release of thyroid hormone from the thyroid

### **What are the thyroid hormones?**

T3 and T4

### **What is the most active form of thyroid hormone?**

T3

### **What is a negative feedback loop?**

T3 and T4 feedback negatively on the anterior pituitary (causing decreased release of TSH in response to TRH)

### **What is Synthroid® (levothyroxine): T3 or T4?**

T4

### **What is the half-life of Synthroid® (levothyroxine)?**

7 days

### **What do parafollicular cells secrete?**

Calcitonin

## ■ Thyroid Nodule

### **What percentage of people have a thyroid nodule?**

≈5%

### **What is the differential diagnosis of a thyroid nodule?**

Multinodular goiter  
Adenoma  
Hyperfunctioning adenoma  
Cyst  
Thyroiditis  
Carcinoma/lymphoma  
Parathyroid carcinoma

### **Name three types of nonthyroidal neck masses**

- . Inflammatory lesions (e.g., abscess, lymphadenitis)
- . Congenital lesions (i.e., thyroglossal duct [midline], branchial cleft cyst [lateral])
- . Malignant lesions: lymphoma, metastases, squamous cell carcinoma

### **What studies can be used to evaluate a thyroid nodule?**

U/S—solid or cystic nodule  
**Fine-Needle Aspirate (FNA)** → cytology  
<sup>123</sup>I scintiscan—hot or cold nodule

### **What is the DIAGNOSTIC test of choice for thyroid nodule?**

FNA

### **What is the percentage of false negative results on FNA for thyroid nodule?**

≈5%

### **What is meant by a “hot” versus a “cold” nodule?**

Nodule uptake of IV <sup>131</sup>I or <sup>99m</sup>Tc

**Hot**—Increased <sup>123</sup>I uptake = functioning/hyperfunctioning nodule

**Cold**—Decreased <sup>123</sup>I uptake = nonfunctioning nodule

### **What are the indications for a <sup>123</sup>I scintiscan?**

- . Nodule with multiple “nondiagnostic” FNAs with low TSH
- . Nodule with thyrotoxicosis and low TSH

### **What is the role of thyroid suppression of a thyroid nodule?**

Diagnostic and therapeutic; administration of thyroid hormone suppresses TSH secretion, and up to half of the benign thyroid nodules will disappear!

**In evaluating a thyroid nodule, which of the following suggest thyroid carcinoma:**

**History?**

- . Neck radiation
- . Family history (thyroid cancer, MEN-II)
- . Young age (especially children)
- . Male > female

**Signs?**

- . Single nodule
- . Cold nodule
- . Increased calcitonin levels
- . Lymphadenopathy
- . Hard, immobile nodule

**Symptoms?**

- . Voice change (vocal cord paralysis)
- . Dysphagia
- . Discomfort (in neck)
- . Rapid enlargement

**What is the most common cause of thyroid enlargement?**

Multinodular goiter

**What are indications for surgery with multinodular goiter?**

Cosmetic deformity, compressive symptoms, cannot rule out cancer

**What is Plummer's disease?**

Toxic multinodular goiter

## **Malignant Thyroid Nodules**

**What percentage of cold thyroid nodules are malignant?**

≈25% in adults

**What percentage of multinodular masses are malignant?**

≈1%

**What is the treatment of a patient with a history of radiation exposure, thyroid nodule, and negative FNA?**

Most experts would remove the nodule surgically (because of the high risk of radiation) with thyroid lobectomy

**What should be done with thyroid cyst aspirate?**

Send to cytopathology

## ■ Thyroid Carcinoma

**Name the FIVE main types of thyroid carcinoma and their relative percentages**

- . Papillary carcinoma: 80% (**P**opular = **P**apillary)
- . Follicular carcinoma: 10%
- . Medullary carcinoma: 5%
- . Hürthle cell carcinoma: 4%
- . Anaplastic/undifferentiated carcinoma: 1% to 2%

**What are the signs/symptoms?**

Mass/nodule, lymphadenopathy; most are **euthyroid**

**What comprises the workup?**

FNA, thyroid U/S, TSH, calcium level, CXR, ±  $^{123}\text{I}$  scintiscan

**What oncogenes are associated with thyroid cancers?**

*Ras* gene family and RET proto-oncogene

## ■ Papillary Adenocarcinoma

**What is papillary carcinoma's claim to fame?**

Most common thyroid cancer (Think: **P**apillary = **P**opular) = 80% of all thyroid

cancers

**What is the environmental risk?**

Radiation exposure

**What is the average age?**

30 to 40 years

**What is the sex distribution?**

Female > male; 2:1

**What are the associated histologic findings?**

Psammoma bodies (Remember, **P** = **P**sammoma = **P**apillary)

**Describe the route and rate of spread**

Most spread via lymphatics (cervical adenopathy); spread occurs slowly

**<sup>131</sup>I uptake?**

Good uptake

**What is the 10-year survival rate?**

≈95%

**What is the treatment for:**

**<1.5 cm and no history of neck radiation exposure?**

Options:

1. Thyroid lobectomy and isthmectomy
2. Near-total thyroidectomy
3. Total thyroidectomy

**>1.5 cm, bilateral, + cervical node metastasis OR a history of radiation exposure?**

Total thyroidectomy

**What is the treatment for:**

**Lateral palpable cervical LNs?**

Selective neck dissection (ipsilateral)

### **Central?**

Central neck dissection

### **Do positive cervical nodes affect the prognosis?**

NO!

### **What is a “lateral aberrant thyroid” in papillary cancer?**

Misnomer—it is metastatic papillary carcinoma to a LN

### **What postoperative medication should be administered?**

Thyroid hormone replacement, to suppress TSH

### **What is a postoperative treatment option for papillary carcinoma?**

Postoperative  $^{131}\text{I}$  scan can locate residual tumor and distant metastasis that can be treated with ablative doses of  $^{131}\text{I}$

### **What is the most common site of distant metastases?**

Pulmonary (lungs)

### **What are the “P’s” of papillary thyroid cancer (7)?**

Papillary cancer:

1. **P**opular (most common)
2. **P**sammoma bodies
3. **P**alpable LNs (spreads most commonly by lymphatics, seen in  $\approx 33\%$  of patients)
4. **P**ositive  $^{131}\text{I}$  uptake
5. **P**ositive prognosis
6. **P**ostoperative  $^{131}\text{I}$  scan to diagnose/treat metastases
7. **P**ulmonary metastases

## **Follicular Adenocarcinoma**

### **What percentage of thyroid cancers does it comprise?**

$\approx 10\%$

**Describe the nodule consistency**

Rubbery, encapsulated

**What is the route of spread?**

Hematogenous, more aggressive than papillary adenocarcinoma

**What is the male-to-female ratio?**

1:3

**<sup>131</sup>I uptake?**

Good uptake

**What is the overall 10-year survival rate?**

≈85%

**Can the diagnosis be made by FNA?**

No; tissue structure is needed for a diagnosis of cancer

**What histologic findings define malignancy in follicular cancer?**

Capsular or blood vessel invasion

**What is the most common site of distant metastasis?**

Bone

**What is the treatment for follicular cancer?**

Total thyroidectomy

**What is the postoperative treatment option if malignant?**

Postoperative <sup>131</sup>I scan for diagnosis/treatment

**What are the “F’s” of follicular cancer?**

Follicular cancer:

1. **F**ar-away metastasis (spreads hematogenously)
2. **F**emale (3:1)
3. **F**NA ... NOT (FNA CANNOT diagnose cancer)
4. **F**avorable prognosis

## ■ Hürthle Cell Thyroid Cancer

### **What is it?**

Thyroid cancer of the Hürthle cells

### **What percentage of thyroid cancers does it comprise?**

≈5%

### **What is the cell of origin?**

Follicular cells

### **<sup>131</sup>I uptake?**

No uptake

### **How is the diagnosis made?**

FNA can identify cells, but malignancy can be determined only by tissue histology (like follicular cancer)

### **What is the route of metastasis?**

Lymphatic > hematogenous

### **What is the treatment?**

Total thyroidectomy

### **What is the 10-year survival rate?**

80%

## ■ Medullary Carcinoma

### **What percentage of all thyroid cancers does it comprise?**

≈5%

### **With what other conditions is it associated?**

MEN type II; autosomal-dominant genetic transmission

**Histology?**

Amyloid (aMyloid = Medullary)

**What does it secrete?**

Calcitonin (tumor marker)

**What is the appropriate stimulation test?**

Pentagastrin (causes an increase in calcitonin)

**Describe the route of spread.**

Lymphatic and hematogenous distant metastasis

**How is the diagnosis made?**

FNA

**<sup>131</sup>I uptake?**

Poor uptake

**What is the associated genetic mutation?**

RET proto-oncogene

**What is the female-to-male ratio?**

Female > male; 1.5:1

**What is the 10-year survival rate?**

80% without LN involvement

45% with LN spread

**What should all patients with medullary thyroid cancer also be screened for?**

MEN II: pheochromocytoma, hyperparathyroidism

**If medullary thyroid carcinoma and pheochromocytoma are found, which one is operated on first?**

Pheochromocytoma

**What is the treatment?**

Total thyroidectomy and median LN dissection

Modified neck dissection, if lateral cervical nodes are positive

### **What are the “M’s” of medullary carcinoma?**

Medullary cancer:

1. **M**EN II
2. a**M**yloid
3. **M**edian LN dissection
4. **M**odified neck dissection if lateral nodes are positive

## **Anaplastic Carcinoma**

### **What is it also known as?**

Undifferentiated carcinoma

### **What is it?**

Undifferentiated cancer arising in  $\approx 75\%$  of previously differentiated thyroid cancers (most commonly, follicular carcinoma)

### **What percentage of all thyroid cancers does it comprise?**

$\approx 2\%$

### **What is the gender preference?**

Women > men

### **What are the associated histologic findings?**

Giant cells, spindle cells

### **$^{131}\text{I}$ uptake?**

Very poor uptake

### **How is the diagnosis made?**

FNA (large tumor)

### **What is the major differential diagnosis?**

Thyroid lymphoma (much better prognosis!)

**What is the treatment of the following disorders:**

**Small tumors?**

Total thyroidectomy + XRT/chemotherapy

**Airway compromise?**

Debulking surgery and tracheostomy, XRT/chemotherapy

**What is the prognosis?**

Dismal, because most patients are at stage IV at presentation (3% alive at 5 years)

## ■ Miscellaneous

**What laboratory value must be followed postoperatively after a thyroidectomy?**

**Calcium** decreased secondary to parathyroid damage

**What is the differential diagnosis of postoperative dyspnea after a thyroidectomy?**

Neck hematoma (remove sutures and clot at the **bedside**)

**Bilateral** recurrent laryngeal nerve damage

**What is a “lateral aberrant rest” of the thyroid?**

Misnomer: It is **papillary** cancer of a LN from metastasis

## ■ Benign Thyroid Disease

**What is the most common cause of hyperthyroidism?**

Graves' disease

**What is Graves' disease?**

Diffuse goiter with hyperthyroidism, exophthalmos, and pretibial myxedema

### **What is the etiology?**

Caused by circulating **antibodies** that stimulate TSH receptors on follicular cells of the thyroid

### **What is the female-to-male ratio?**

6:1

### **What specific physical finding is associated with Graves'?**

Exophthalmos

### **How is the diagnosis made?**

Increased T3, T4, and anti-TSH receptor antibodies, decreased TSH, global uptake of  $^{131}\text{I}$  radionuclide

### **Name treatment option modalities for Graves' disease**

- . **Medical blockade:** iodide, propranolol, propylthiouracil (PTU), methimazole, Lugol's solution (potassium iodide)
- . **Radioiodide ablation:** most popular therapy
- . **Surgical resection** (bilateral subtotal thyroidectomy)

### **What are the possible indications for surgical resection?**

Suspicious nodule; if patient is noncompliant or refractory to medicines, pregnant, a child, or if patient refuses radioiodide therapy

### **What is the major complication of radioiodide or surgery for Graves' disease?**

Hypothyroidism

### **What does PTU stand for?**

PropylThioUracil

### **How does PTU work?**

- . Inhibits incorporation of iodine into T4/T3 (by blocking peroxidase oxidation of iodide to iodine)
- . Inhibits peripheral conversion of T4 to T3

### **How does methimazole work?**

Inhibits incorporation of iodine into T4/T3 **only** (by blocking peroxidase

oxidation of iodide to iodine)

## ■ Toxic Multinodular Goiter

### **What is it also known as?**

Plummer's disease

### **What is it?**

Multiple thyroid nodules with one or more nodules producing thyroid hormone, resulting in hyperfunctioning thyroid (hyperthyroidism or a “toxic” thyroid state)

### **What medication may bring on hyperthyroidism with a multinodular goiter?**

Amiodarone (or any iodine-containing medication/contrast)

### **How is the hyperfunctioning nodule(s) localized?**

<sup>131</sup>I radionuclide scan

### **What is the treatment?**

Surgically remove hyperfunctioning nodule(s) with lobectomy or near total thyroidectomy

## ■ Thyroiditis

### **What are the features of acute thyroiditis?**

Painful, swollen thyroid; fever; overlying skin erythema; dysphagia

### **What is the cause of ACUTE thyroiditis?**

Bacteria (usually *Streptococcus* or *Staphylococcus*), usually caused by a thyroglossal fistula or anatomic variant

### **What is the treatment of ACUTE thyroiditis?**

Antibiotics, drainage of abscess, needle aspiration for culture; most patients need definitive surgery later to remove the fistula

### **What are the features of SUBACUTE thyroiditis?**

Glandular swelling, tenderness, often follows URI, elevated ESR

### **What is the cause of SUBACUTE thyroiditis?**

Viral infection

### **What is the treatment of SUBACUTE thyroiditis?**

Supportive: NSAIDS,  $\pm$  steroids

### **What is De Quervain's thyroiditis?**

Just another name for subacute thyroiditis caused by a virus (Think: De QuerVain = Virus)

### **How can the differences between etiologies of ACUTE and SUBACUTE thyroiditis be remembered?**

Alphabetically: **A** before **S**, **B** before **V** (i.e., **A**cute before Subacute and **B**acterial before **V**iral, and thus: **A**cute = **B**acterial and Subacute = **V**iral)

### **What are the common causative bacteria in acute suppurative thyroiditis?**

*Streptococcus or Staphylococcus*

### **What are the two types of chronic thyroiditis?**

- . Hashimoto's thyroiditis
- . Riedel's thyroiditis

### **What is the etiology of Hashimoto's disease?**

Autoimmune (Think: HashimOTO = AUTO; thus, Hashimoto = autoimmune)

### **What is Riedel's thyroiditis?**

Benign inflammatory thyroid enlargement **with fibrosis** of thyroid

Patients present with painless, large thyroid

Fibrosis may involve surrounding tissues

### **What is the treatment for Riedel's thyroiditis?**

Surgical tracheal decompression, thyroid hormone replacement as needed—possibly steroids/tamoxifen if refractory

---

## RAPID FIRE REVIEW

**Name the diagnostic stimulation test for the following:**

**Medullary thyroid carcinoma?**

Pentagastrin (also calcium)

**Name the most likely diagnosis:**

**60-year-old woman with a thyroid mass, + follicular cells on biopsy, + capsular invasion, + vascular invasion**

Thyroid follicular carcinoma

**42-year-old woman with thyroid mass, + amyloid on histology, hypercalcemia**

Medullary thyroid carcinoma

**25-year-old man with thyroid mass, + psammoma bodies on histology**

Papillary thyroid carcinoma

**Hypothyroidism, “woody” hard thyroid, tracheal compression**

Riedel’s thyroiditis

**17-year-old woman with upper respiratory tract infection followed by fever, neck pain, dysphagia, tender thyroid gland, + strep cultures**

Acute suppurative thyroiditis

**28-year-old woman with tender thyroid, hypothyroidism, elevated antimicrosomal antibodies, increased antithyroglobulin antibodies**

Hashimoto’s thyroiditis

# Chapter 58 Parathyroid

## ANATOMY

**How many parathyroids are there?**

Usually **four** (two superior and two inferior)

**What percentage of patients have five parathyroid glands?**

≈5% (Think: 5 = 5)

**What percentage of patients have three parathyroid glands?**

≈10%

**What is the usual position of the inferior parathyroid glands?**

Posterior and lateral behind the thyroid and below the inferior thyroid artery

**What is the most common site of an “extra” gland?**

Thymus gland

**What percentage of patients have a parathyroid gland in the mediastinum?**

≈1%

**If only three parathyroid glands are found at surgery, where can the fourth be hiding?**

Thyroid gland

Thymus/mediastinum

Carotid sheath

Tracheoesophageal groove

Behind the esophagus

**What is the embryologic origin of the following structures:**

### **Superior parathyroid glands?**

Fourth pharyngeal pouch

### **Inferior parathyroid glands?**

Third pharyngeal pouch (counterintuitive)

### **What supplies blood to all four parathyroid glands?**

Inferior thyroid artery

### **What is the most common cause of hypercalcemia in outpatients?**

Hyperparathyroidism

## **PHYSIOLOGY**

### **What cell type produces PTH?**

Chief cells produce **ParaThyroid Hormone (PTH)**

### **What are the major actions of PTH?**

**Increases** blood **calcium** levels (takes from bone breakdown, GI absorption, increased resorption from kidney, excretion of phosphate by kidney), **decreases** serum phosphate

### **How does vitamin D work?**

Increases intestinal absorption of calcium and phosphate

### **Where is calcium absorbed?**

Duodenum and proximal jejunum

## **HYPERPARATHYROIDISM (HPTH)**

### **Define primary HPTH**

Increased secretion of PTH by parathyroid gland(s); marked by elevated calcium, low phosphorus

### **Define secondary HPTH**

Increased serum PTH resulting from calcium wasting caused by **renal failure or**

**decreased GI calcium absorption**, rickets or osteomalacia; calcium levels are usually **low**

### **Define tertiary HPTH**

Persistent HPTH after correction of secondary hyperparathyroidism; results from autonomous PTH secretion not responsive to the normal negative feedback due to elevated  $\text{Ca}^{2+}$  levels

### **What are the methods of imaging the parathyroids?**

Surgical operation

Ultrasound

#### **Sestamibi scan**

$^{201}\text{Tl}$  (technetium)–thallium subtraction scan

CT scan/MRI

A-gram (rare)

Venous sampling for PTH (rare)

### **What are the indications for a localizing preoperative study?**

**Reoperation** for recurrent hyperparathyroidism

### **What is the most common cause of primary HPTH?**

Adenoma (>85%)

### **What are the etiologies of primary HPTH and percentages?**

**Adenoma** ( $\approx$ 85%)

Hyperplasia ( $\approx$ 10%)

Carcinoma ( $\approx$ 1%)

### **What is the incidence of primary HPTH in the United States?**

$\approx$ 1/1000 to 4000

### **What are the risk factors for primary HPTH?**

Family history, MEN-I and MEN-IIa, irradiation

### **What are the signs/symptoms of primary HPTH hypercalcemia?**

**“Stones, bones, groans, and psychiatric overtones”:**

**Stones:** Kidney stones

**Bones:** Bone pain, pathologic fractures, subperiosteal resorption

**Groans:** Muscle pain and weakness, pancreatitis, gout, constipation

**Psychiatric overtones:** Depression, anorexia, anxiety

**Other symptoms:** Polydipsia, weight loss, HTN (10%), polyuria, lethargy

### **What is the “33-to-1” rule?**

Most patients with primary HPTH have a ratio of serum ( $\text{Cl}^-$ ) to phosphate  $\geq 33$

### **What plain x-ray findings are classic for HPTH?**

Subperiosteal bone resorption (usually in hand digits; said to be “pathognomonic” for HPTH!)

### **How is primary HPTH diagnosed?**

Labs—elevated PTH (hypercalcemia,  $\downarrow$  phosphorus,  $\uparrow$  chloride); urine calcium should be checked for familial hypocalciuric hypercalcemia

### **What is familial hypocalciuric hypercalcemia?**

Familial (autosomal dominant) inheritance of a condition of **asymptomatic** hypercalcemia and low urine calcium, with or without elevated PTH; in contrast, hypercalcemia from HPTH results in high levels of urine calcium

**Note:** Surgery to remove parathyroid glands is not indicated for this diagnosis

### **How many of the glands are USUALLY affected by the following conditions:**

#### **Hyperplasia?**

4

#### **Adenoma?**

1

#### **Carcinoma?**

1

### **What is the differential diagnosis of hypercalcemia?**

#### **“CHIMPANZEES”:**

Calcium overdose

Hyperparathyroidism (1°/2°/3°),

Hyperthyroidism, Hypocalciuric Hypercalcemia (familial)

Immobility/Iatrogenic (thiazide diuretics)  
Metastasis/Milk alkali syndrome (rare)  
Paget's disease (bone)  
Addison's disease/acromegaly  
Neoplasm (colon, lung, breast, prostate, multiple myeloma)  
Zollinger–Ellison syndrome  
Excessive vitamin D  
Excessive vitamin A  
Sarcoid

### **What is the initial medical treatment of hypercalcemia (1° HPTH)?**

Medical—IV fluids, furosemide—**NOT** thiazide diuretics

### **Although most recommend surgery for asymptomatic 1° HPTH, when is it considered mandatory?**

#### **“ROACH”**

Renal insufficiency (CR ↓ by 30%)  
Osteoporosis (T score < -2.5)  
Age <50  
Calcium >1 mg/dL above upper limit of normal  
Hypercalciuria (>400 mg/day Ca<sup>2+</sup> excretion)

### **What is the definitive treatment of HPTH in the following cases:**

#### **Primary HPTH resulting from HYPERPLASIA?**

Neck exploration removing all parathyroid glands and leaving at least 30 mg of parathyroid tissue placed in the forearm muscles (nondominant arm, of course!)

#### **Primary HPTH resulting from parathyroid ADENOMA?**

Surgically remove adenoma (send for frozen section) and biopsy all abnormally enlarged parathyroid glands (some experts biopsy all glands)

#### **Primary HPTH resulting from parathyroid CARCINOMA?**

Remove carcinoma, ipsilateral thyroid lobe, and all enlarged lymph nodes (modified radical neck dissection for LN metastases)

#### **Secondary HPTH?**

Correct calcium and phosphate; perform renal transplantation (no role for parathyroid surgery)

### **Tertiary HPTH?**

Correct calcium and phosphate; perform surgical operation to remove all parathyroid glands and reimplant 30 to 40 mg in the forearm if **REFRACTORY** to medical management

### **Why place 30 to 40 mg of sliced parathyroid gland in the forearm?**

To retain parathyroid function; if HPTH recurs, remove some of the parathyroid gland from the easily accessible forearm

### **What must be ruled out in the patient with HPTH from hyperplasia?**

MEN type I and MEN type IIa

### **What carcinomas are commonly associated with hypercalcemia?**

**Breast cancer metastases**, prostate cancer, kidney cancer, lung cancer, pancreatic cancer, multiple myeloma

### **What is the most likely diagnosis if a patient has a PALPABLE neck mass, hypercalcemia, and elevated PTH?**

Parathyroid carcinoma (vast majority of other causes of primary HPTH have nonpalpable parathyroids)

## **PARATHYROID CARCINOMA**

### **What is it?**

Primary carcinoma of the parathyroid gland

### **What is the number of glands usually affected?**

1

### **What are the signs/symptoms?**

Hypercalcemia, elevated PTH, **PALPABLE** parathyroid gland (50%), pain in neck, recurrent laryngeal nerve paralysis (change in voice), hypercalcemic crisis (usually associated with calcium levels  $>14$ )

**What is the common tumor marker?**

Human Chorionic Gonadotropin (HCG)

**What is the treatment?**

Surgical resection of parathyroid mass with ipsilateral thyroid lobectomy, ipsilateral lymph node resection

**What percentage of all cases of primary HPTH are caused by parathyroid carcinoma?**

1%

## ■ Postoperative Complications of Parathyroidectomy

**What are the possible postoperative complications after a parathyroidectomy?**

Recurrent nerve injury (unilateral: voice change; bilateral: airway obstruction), neck hematoma (open at bedside if breathing is compromised), hypocalcemia, superior laryngeal nerve injury

**What is “hungry bone syndrome”?**

Severe hypocalcemia seen after surgical correction of HPTH as chronically calcium-deprived bone aggressively absorbs calcium

**What are the signs/symptoms of postoperative hypocalcemia?**

Perioral tingling, paresthesia, +Chvostek’s sign, +Trousseau’s sign, +tetany

**What is the treatment of hypoparathyroidism?**

Acute: IV calcium

Chronic: PO calcium, and vitamin D

**What is parathyromatosis?**

Multiple small hyperfunctioning parathyroid tissue masses found over the neck and mediastinum—thought to be from congenital rests or spillage during surgery—remove surgically (RARE)

---

## RAPID FIRE REVIEW

**What is the correct diagnosis:**

**Palpable parathyroid gland and hypercalcemia**

Parathyroid carcinoma

**50-year-old female with parathyroid hyperplasia, jejunal ulcers, loss of peripheral vision**

MEN-I (parathyroid hyperplasia, gastrinoma, pituitary tumor)

**45-year-old female with palpable neck mass and hypercalcemia with elevated parathyroid hormone**

Parathyroid carcinoma

**34-year-old female with a symptomatic hypercalcemia with low calcium level in her urine**

Familial hypocalciuric hypercalcemia

**Name the radiographic test for localizing the following:**

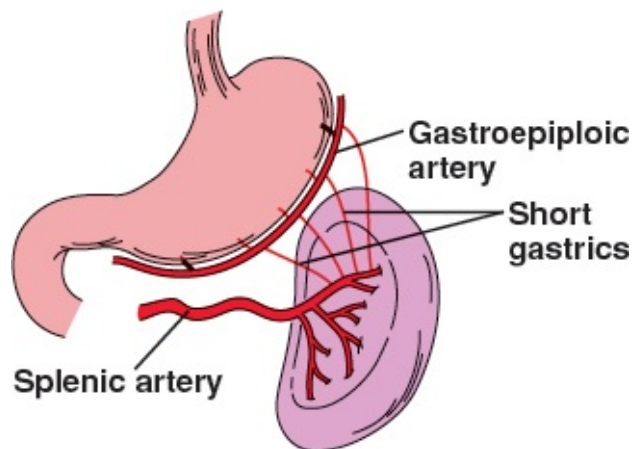
**Hyperfunctioning parathyroid**

<sup>99</sup>mTc-sestamibi scintigraphy

# Chapter 59 Spleen and Splenectomy

## Which arteries supply the spleen?

Splenic artery (a branch of the celiac trunk) and the short gastric arteries that arise from the gastroepiploic arteries



## What is the venous drainage of the spleen?

**Portal** vein, via the splenic vein and the left gastroepiploic vein

## What is said to “tickle” the spleen?

Tail of the pancreas

## What percentage of people have an accessory spleen?

≈20%

## What is “delayed splenic rupture”?

Subcapsular hematoma or pseudoaneurysm may rupture sometime after blunt trauma, causing “delayed splenic rupture”; rupture classically occurs ≈2 weeks post injury and presents with shock/abdominal pain

## What are the signs/symptoms of ruptured/injured spleen?

Hemoperitoneum and Kehr’s sign, LUQ abdominal pain, Ballance’s sign

### **What is Kehr's sign?**

Left shoulder pain seen with splenic rupture

### **How is a spleen injury diagnosed?**

Abdominal CT scan, **if the patient is stable**; DPL or FAST exam if the patient is unstable

### **What is the treatment?**

- . Nonoperative in a stable patient with an isolated splenic injury without hilar involvement/complete rupture
- . If patient is unstable, DPL/FAST laparotomy with splenorrhaphy or splenectomy
- . Embolization is an option in selected patients

### **What is a splenorrhaphy?**

Splenic salvage operation: wrapping Vicryl® mesh, aid of topical hemostatic agents or partial splenectomy, sutures (buttressed)

### **What are the other indications for splenectomy:**

#### **Malignant diseases?**

Hodgkin's staging not conclusive by CT scan (rare)

Splenic tumors (primary/metastatic/locally invasive)

Hypersplenism caused by other leukemias/non-Hodgkin's lymphomas

#### **Anemias?**

Medullary fibrosis with myeloid metaplasia

Hereditary elliptocytosis

Sickle cell anemia (rare, most autosplenectomize)

Pyruvate kinase deficiency

Autoimmune hemolytic anemia

Hereditary spherocytosis

Thalassemias (e.g.,  $\beta$ -thalassemia major, a.k.a. "Cooley's")

#### **Thrombocytopenia?**

**ITP** (Idiopathic Thrombocytopenic Purpura)

**TTP** (Thrombotic Thrombocytopenic Purpura)

**Is G6PD deficiency an indication for splenectomy?**

NO

**What are the possible postsplenectomy complications?**

Thrombocytosis, subphrenic abscess, atelectasis, pancreatitis, gastric dilation, and **Overwhelming PostSplenectomy Sepsis (OPSS)**, pancreatic injury (tail)

**What causes OPSS?**

Increased susceptibility to fulminant bacteremia, meningitis, or pneumonia because of loss of splenic function

**What is the incidence of OPSS in adults?**

<1%

**What is the incidence and overall mortality of OPSS in children?**

1% to 2% with 50% mortality rate

**What is the typical presentation of OPSS?**

Fever, lethargy, common cold, sore throat, URI followed by confusion, shock, and coma with death ensuing within 24 hours in up to 50% of patients

**What are the common organisms associated with OPSS?**

**Encapsulated:** *Streptococcus pneumoniae*, *Neisseria meningitides*, *Haemophilus influenzae*

**What is the most common bacteria in OPSS?**

*S. pneumoniae*

**What is the preventive treatment of OPSS?**

Vaccinations for pneumococcus, *H. influenzae*, and meningococcus  
Prophylactic penicillin for all minor infections/illnesses and immediate medical care if febrile illness develops

**What is the best time to give immunizations to splenectomy patients?**

**Preoperatively**, if at all possible

If emergent, then 2 weeks postoperatively

**What lab tests are abnormal after splenectomy?**

WBC count increases by 50% over the baseline; marked **thrombocytosis** occurs;  
RBC smear is abnormal

**What are the findings on postsplenectomy RBC smear?**

Peripheral smear will show Pappenheimer bodies, Howell–Jolly bodies, and Heinz bodies

**What is the most common cause of splenic vein thrombosis?**

Pancreatitis

**What opsonins does the spleen produce?**

**PRO**perdin, **TU**Ftsin (Think: “**PRO**fessionally **TUF** spleen”)

**What is the most common cause of ISOLATED GASTRIC varices?**

Splenic vein thrombosis (usually from pancreatitis)

**What is the treatment of gastric varices caused by splenic vein thrombosis?**

Splenectomy

**Which patients develop hyposplenism?**

Patients with ulcerative colitis

**What vaccinations should every patient with a splenectomy receive?**

Pneumococcus

Meningococcus

*H. influenzae* type B

**Define hypersplenism**

Hyperfunctioning spleen

Documented loss of blood elements (WBC, Hct, platelets)

Large spleen (splenomegaly)

Hyperactive bone marrow (trying to keep up with loss of blood elements)

**Define splenomegaly**

Enlarged spleen

**What is idiopathic thrombocytopenic purpura (ITP)?**

Autoimmune (antiplatelet antibodies IgG in >90% of patients) platelet destruction leading to troublesome bleeding and purpura

**What is the most common cause of failure to correct thrombocytopenia after splenectomy for ITP?**

Missed accessory spleen

**What are the “I’s” of ITP?**

- . Immune etiology (IgG antiplatelets ABs)
- . Immunosuppressive treatment (initially treated with steroids)
- . Immune globulin
- . Improvement with splenectomy (75% of patients have improved platelet counts after splenectomy)

**What is TTP?**

Thrombotic Thrombocytopenic Purpura

**What is the treatment of choice for TTP?**

Plasmapheresis (splenectomy reserved as a last resort—very rare)

**What is the most common physical finding of portal hypertension?**

Splenomegaly

# Chapter 60 Surgically Correctable HTN

## **What is it?**

Hypertension caused by conditions that are amenable to surgical correction

## **What percentage of patients with HTN have a surgically correctable cause?**

≈7%

## **What diseases that cause HTN are surgically correctable?**

Think “**CAN I CHURP?**”:

Cushing’s syndrome

Aortic coarctation

Neuroblastoma/neoplasia

Increased intracranial pressure

Conn’s syndrome (primary hyperaldosteronism)

Hyperparathyroidism/hyperthyroidism

Unilateral renal parenchymal disease

Renal artery stenosis

Pheochromocytoma

# Chapter 61 Soft Tissue Sarcomas and Lymphomas

## SOFT TISSUE SARCOMAS

Name the following types of malignant sarcoma:

**Fat**

Liposarcoma

**Gastrointestinal**

**GIST** (GastroIntestinal Stromal Tumor)

**Myofibroblast**

Malignant fibrous histiocyoma

**Striated muscle**

Rhabdomyosarcoma

**Vascular endothelium**

Angiosarcoma

**Fibroblast**

Fibrosarcoma

**Lymph vessel**

Lymphangiosarcoma

**Peripheral nerve**

Malignant neurilemmoma or schwannoma

## **AIDS**

Kaposi's sarcoma

## **Lymphedema**

Lymphangiosarcoma

### **What are the signs/symptoms?**

Soft tissue mass; pain from compression of adjacent structures, often noticed after minor trauma to area of mass

### **How do most sarcomas metastasize?**

Hematogenously (i.e., via blood)

### **What is the most common location and route of metastasis?**

**Lungs** via hematogenous route

### **What are the three most common malignant sarcomas in adults?**

Fibrous histiocytoma (25%)

Liposarcoma (20%)

Leiomyosarcoma (15%)

### **What are the two most common in children?**

Rhabdomyosarcoma (≈50%), fibrosarcoma (20%)

### **What is the most common sarcoma of the retroperitoneum?**

Liposarcoma

### **How is the diagnosis made?**

Imaging workup—MRI is superior to CT scan at distinguishing the tumor from adjacent structures

Mass <3 cm: excisional biopsy

**Mass >3 cm:** incisional biopsy or **core biopsy**

### **Define excisional biopsy**

Biopsy by removing the **entire** mass

### **Define incisional biopsy**

Biopsy by removing a **piece** of the mass

### **What is the orientation of incision for incisional biopsy of a suspected extremity sarcoma?**

**Longitudinal**, not transverse, so that the incision can be incorporated in a future resection if biopsy for sarcoma is positive

### **What determines histologic grade of sarcomas?**

- . Differentiation
- . Mitotic count
- . Tumor necrosis

Grade 1 = well differentiated

Grade 2 = moderately differentiated

Grade 3 = poorly differentiated

### **What is a pseudocapsule and what is its importance?**

Outer layer of a sarcoma that represents compressed malignant cells

### **What is the most important factor in the prognosis?**

**Histologic grade** of the primary lesion

### **What is the treatment?**

Surgical resection and radiation (with or without chemotherapy)

### **What surgical margins are obtained?**

2 cm (1 cm minimum)

### **What is the “limb-sparing” surgery for extremity sarcoma?**

Avoidance of amputation with local resection and chemoradiation

### **What is the treatment of pulmonary metastasis?**

Surgical resection for isolated lesions

## **GI Lymphoma**

### **What is it?**

Non-Hodgkin's lymphoma arising in the GI tract

**What is the risk factor for gastric lymphoma?**

*Helicobacter pylori*

**What are the signs/symptoms?**

Abdominal pain, obstruction, GI hemorrhage, GI tract perforation, fatigue

**What is the treatment of intestinal lymphoma?**

Surgical resection with removal of draining lymph nodes and chemotherapy

**What is the most common site of primary GI tract lymphoma?**

Stomach (66%)

# Chapter 62 Skin Lesions

## **What are the most common skin cancers?**

- . Basal cell carcinoma (75%)
- . Squamous cell carcinoma (20%)
- . Melanoma (4%)

## **What is the most common fatal skin cancer?**

Melanoma

## **What is malignant melanoma?**

A redundancy! All melanomas are considered malignant!

## **SQUAMOUS CELL CARCINOMA**

### **What is it?**

Carcinoma arising from epidermal cells

### **What are the most common sites?**

Head, neck, and hands

### **What are the risk factors?**

Sun exposure, pale skin, chronic inflammatory process, immunosuppression, xeroderma pigmentosum, arsenic

### **What is a precursor skin lesion?**

Actinic keratosis

### **What are the signs/symptoms?**

Raised, slightly pigmented skin lesion; ulceration/exudate; chronic scab; itching

### **How is the diagnosis made?**

Small lesion—excisional biopsy  
Large lesions—incisional biopsy

### **What is the treatment?**

Small lesion (<1 cm): Excise with 0.5-cm margin  
Large lesion (>1 cm): Resect with 1- to 2-cm margins of normal tissue (large lesions may require skin graft/flap)

### **What is the dreaded sign of metastasis?**

Palpable lymph nodes (remove involved lymph node basin)

### **What is Marjolin's ulcer?**

Squamous cell carcinoma that arises in an area of chronic inflammation (e.g., chronic fistula, burn wound, osteomyelitis)

### **What is the prognosis?**

Excellent if totally excised (95% cure rate); most patients with positive lymph node metastasis eventually die from metastatic disease

### **What is the treatment for solitary metastasis?**

Surgical resection

## **BASAL CELL CARCINOMA**

### **What is it?**

Carcinoma arising in the germinating basal cell layer of epithelial cells

### **What are the risk factors?**

Sun exposure, fair skin, radiation, chronic dermatitis, xeroderma pigmentosum

### **What are the most common sites?**

Head, neck, and hands

### **What are the signs/symptoms?**

Slow-growing skin mass (chronic, scaly); scab; ulceration, with or without pigmentation, often described as “pearl-like”

### **How is the diagnosis made?**

Excisional or incisional biopsy

### **What is the treatment?**

Resection with 5-mm margins (2-mm margin in cosmetically sensitive areas)

### **What is the risk of metastasis?**

Very low (recur locally)

## **MISCELLANEOUS SKIN LESIONS**

### **What is an Epidermal Inclusion Cyst?**

**EIC** = Benign subcutaneous cyst filled with epidermal cells (should be removed surgically) filled with waxy material; no clinical difference from a sebaceous cyst

### **What is a sebaceous cyst?**

Benign subcutaneous cyst filled with sebum (waxy, paste-like substance) from a blocked sweat gland (should be removed with a small area of skin that includes the blocked gland); may become infected; much less common than EIC

### **What is actinic keratosis?**

Premalignant skin lesion from sun exposure; seen as a scaly skin lesion (surgical removal eliminates the 20% risk of cancer transformation)

### **What is seborrheic keratosis?**

Benign pigmented lesion in the elderly; observe or treat by excision (especially if there is any question of melanoma), curettage, or topical agents

### **How to remember actinic keratosis versus seborrheic keratosis malignant potential?**

Actinic Keratosis = **AK** = Asset Kicker = premalignant (20% convert to carcinoma)

Seborrheic Keratosis = **SK** = Soft Kicker = benign

### **What is Bowen's disease of the skin?**

Squamous carcinoma in situ (should be removed or destroyed, thereby removing

the problem)

**What is “Mohs” surgery?**

Mohs technique or surgery: repeats thin excision until margins are clear by microscopic review (named after Dr. Mohs)—used to minimize collateral skin excision (e.g., on the face)

# Chapter 63 Melanoma

## **What is it?**

Neoplastic disorder produced by malignant transformation of the melanocyte; melanocytes are derived from neural crest cells

## **Which patients are at greatest risk?**

White patients with blonde/red hair, fair skin, freckling, a history of blistering sunburns, blue/green eyes, actinic keratosis

Male > female

## **What are the three most common sites?**

- . Skin
- . Eyes
- . Anus

(Think: **SEA** = Skin, Eyes, Anus)

## **What is the most common site in African Americans?**

Palms of the hands, soles of the feet (acral lentiginous melanoma)

## **What characteristics are suggestive of melanoma?**

Usually a pigmented lesion with an irregular border, irregular surface, or irregular coloration

Other clues: darkening of a pigmented lesion, development of pigmented satellite lesions, irregular margins or surface elevations, notching, recent or rapid enlargement, erosion or ulceration of surface, pruritus

## **What are the “ABCDs” of melanoma?**

**A**symmetry

**B**order irregularity

**C**olor variation

**D**iameter >6 mm and **D**ark lesion

**What are the associated risk factors?**

Severe sunburn before age 18, giant congenital nevi, family history, race (white), ultraviolet radiation (sun), multiple dysplastic nevi

**How does location differ in men and women?**

Men get more lesions on the trunk; women on the extremities

**Which locations are unusual?**

Noncutaneous regions, such as mucous membranes of the vulva/vagina, anorectum, esophagus, and choroidal layer of the eye

**What is the most common site of melanoma in men?**

Back (33%)

**What is the most common site of melanoma in women?**

Legs (33%)

**What are the four major histologic types?**

- . Superficial spreading
- . Lentigo maligna
- . Acral lentiginous
- . Nodular

**Define the following terms:****Superficial spreading melanoma**

Occurs in both sun-exposed and non-exposed areas; **most common** of all melanomas (75%)

**Lentigo maligna melanoma**

Malignant cells that are superficial, found usually in elderly patients on the head or neck

Called “Hutchinson’s freckle” if noninvasive

Least aggressive type; very good prognosis

Accounts for <10% of all melanomas

**Acral lentiginous melanoma**

Occurs on the palms, soles, subungual areas, and mucous membranes

Accounts for  $\approx 5\%$  of all melanomas (most common melanoma in African American patients;  $\approx 50\%$ )

### **Nodular melanoma**

Vertical growth predominates

Lesions are usually dark

Most aggressive type/worst prognosis

Accounts for  $\approx 15\%$  of all melanomas

### **Amelanotic melanoma**

Melanoma from melanocytes but with obvious lack of pigment

### **What is the most common type of melanoma?**

Superficial spreading ( $\approx 75\%$ ) (Think: **SUPER**ficial = **SUPER**ior)

### **What type of melanoma arises in Hutchinson's freckle?**

Lentigo maligna melanoma

### **What is Hutchinson's freckle?**

Lentigo maligna melanoma in the radial growth phase without vertical extension (noninvasive); usually occurs on the faces of elderly women

### **What are the common sites of metastasis?**

Nodes (local)

Distant: lung, liver, bone, heart, and brain

Melanoma has a specific attraction for small bowel mucosa

Brain metastases are a common cause of death

### **What are the metastatic routes?**

Both lymphatic and hematogenous

### **How is the diagnosis made?**

Excisional biopsy (complete removal leaving only normal tissue) or incisional biopsy for very large lesions

(**Note:** Early diagnosis is crucial)

### **What is the role of shave biopsy?**

No role

**What is the “sentinel node” biopsy?**

Inject Lymphazurin® blue dye, colloid with a radiolabel, or both around the melanoma; the first lymph node (LN) in the draining chain is identified as the “sentinel lymph node” and reflects the metastatic status of the group of LNs

**When is elective LN dissection recommended?**

Controversial—possible advantage in melanomas 1 to 2 mm in depth but jury still out; sentinel node biopsy if >1 mm is becoming very common

**Melanomin “tumor marker?”**

S-100

**What is the recommended size of the surgical margin for depth of invasion:****Melanoma in situ?**

0.5-cm margin

**Ä1 mm thick?**

1-cm margin

**1 to 4 mm thick?**

2-cm margin

**>4 mm thick?**

3-cm margin

**What is the treatment for digital melanoma?**

Amputation

**What is the treatment of palpable LN metastasis?**

Lymphadenectomy

**What factors determine the prognosis?**

Depth of invasion and metastasis are the most important factors

**What is the workup to survey for metastasis in the patient with melanoma?**

Physical exam, LFTs, CXR (bone scan/CT scan/MRI reserved for symptoms)

**What is the treatment of intestinal metastasis?**

Surgical resection to prevent bleeding/obstruction

**What is FDA-approved adjuvant therapy?**

Interferon alpha-2b (for stages IIB/III)

**What is the treatment of unresectable brain metastasis?**

Radiation

**What is the treatment of isolated adrenal metastasis?**

Surgical resection

**What is the treatment of isolated lung metastasis?**

Surgical resection

**What is the most common symptom of anal melanoma?**

Bleeding

**What is the treatment of anal melanoma?**

APR or wide excision (no survival benefit from APR, but better local control)

**What is the median survival with distant metastasis?**

≈6 months

# Chapter 64 Surgical Intensive Care

## INTENSIVE CARE UNIT (ICU) BASICS

### How is an ICU note written?

By **systems**:

Neurologic (e.g., GCS, MAE, pain control)

Pulmonary (e.g., vent settings)

CVS (e.g., pressors, Swan numbers)

GI (gastrointestinal)

Heme (CBC)

FEN (e.g., Chem 10, nutrition)

Renal (e.g., urine output, BUN, Cr)

ID (e.g., T<sub>max</sub>, WBC, antibiotics)

Assessment

Plan

(**Note:** Physical exam included in each section)

### What is the best way to report urine output in the ICU?

24 hrs/last shift/last 3 hourly rate = “urine output has been 2 L over the last 24 hours, 350 last shift, and 45, 35, 40 cc over the last 3 hours”

### What are the possible causes of fever in the ICU?

Central line infection

Pneumonia/atelectasis

UTI, urosepsis

Intra-abdominal abscess

Sinusitis

DVT

Thrombophlebitis

Drug fever

Fungal infection, meningitis, wound infection

Endocarditis

**What is the most common bacteria in ICU pneumonia?**

Gram-negative rods

**What is the acronym for the basic ICU care checklist (Dr. Vincent)?**

**“FAST HUG”:**

Feeding

Analgesia

Sedation

Thromboembolic prophylaxis

Head-of-bed elevation (pneumonia prevention)

Ulcer prevention

Glucose control

## INTENSIVE CARE UNIT FORMULAS AND TERMS YOU SHOULD KNOW

**What is CO?**

Cardiac Output:  $HR \text{ (heart rate)} \times SV \text{ (stroke volume)}$

**What is the normal CO?**

4 to 8 L/min

**What factors increase CO?**

Increased contractility, heart rate, and preload; decreased afterload

**What is CI?**

Cardiac Index:  $CO/BSA \text{ (body surface area)}$

**What is the normal CI?**

2.5 to 3.5 L/min/M<sub>2</sub>

**What is SV?**

Stroke Volume: the amount of blood pumped out of the ventricle each beat;

simply, end-diastolic volume minus the end-systolic volume **or** CO/HR

**What is the normal SV?**

60 to 100 cc

**What is CVP?**

Central Venous Pressure: indirect measurement of intravascular volume status

**What is the normal CVP?**

4 to 11

**What is PCWP?**

Pulmonary Capillary Wedge Pressure: indirectly measures left atrial pressure, which is an estimate of intravascular volume (LV filling pressure)

**What is the normal PCWP?**

5 to 15

**What is anion gap?**

$\text{Na}^+ - (\text{Cl}^- + \text{HCO}_3^-)$

**What are the normal values for anion gap?**

10 to 14

**Why do you get an increased anion gap?**

Unmeasured acids are unmeasured anions in the equation that are part of the “counterbalance” to the sodium cation

**What are the causes of increased anion gap acidosis in surgical patients?**

Think “SALUD”:

Starvation

Alcohol (ethanol/methanol)

Lactic acidosis

Uremia (renal failure)

DKA

**Define MODS**

## Multiple Organ Dysfunction Syndrome

### What is SVR?

Systemic Vascular Resistance:  $MAP - CVP / CO \times 80$  (remember,  $P = F \times R$ , Power FoRward; and calculating resistance:  $R = P/F$ )

### What is SVRI?

Systemic Vascular Resistance Index:  $SVR / BSA$

### What is the normal SVRI?

1500 to 2400

### What is MAP?

Mean Arterial Pressure: diastolic blood pressure +  $1/3$  (systolic – diastolic pressure)

(**Note:** Not the mean between diastolic and systolic blood pressure because diastole lasts longer than systole)

### What is PVR?

Pulmonary Vascular Resistance:  $PA(MEAN) - PCWP / CO \times 80$  (PA is pulmonary artery pressure and LA is left atrial or PCWP pressure)

### What is the normal PVR value?

$100 \pm 50$

### What is the formula for arterial oxygen content?

$Hemoglobin \times O_2 \text{ saturation } (Sao_2) \times 1.34$

### What is the basic formula for oxygen delivery?

$CO \times (\text{oxygen content})$

### What is the full formula for oxygen delivery?

$CO \times (1.34 \times Hgb \times Sao_2) \times 10$

### What factors can increase oxygen delivery?

Increased CO by increasing SV, HR, or both; increased  $O_2$  content by increasing the hemoglobin content,  $Sao_2$ , or both

**What is mixed venous oxygen saturation?**

Svo<sub>2</sub>; simply, the O<sub>2</sub> saturation of the blood in the right ventricle or pulmonary artery; an indirect measure of peripheral oxygen supply and demand

**Which lab values help assess adequate oxygen delivery?**

Svo<sub>2</sub> (low with inadequate delivery), lactic acid (elevated with inadequate delivery), pH (acidosis with inadequate delivery), base deficit

**What is FENa?**

Fractional Excretion of Sodium (Na<sup>+</sup>):  $(U_{Na}^{+} \times P_{cr} / P_{Na}^{+} \times U_{cr}) \times 100$

**What is the memory aid for calculating FENa?**

Think: **YOU NEED PEE = U (Urine) N (Na<sup>+</sup>) P (Plasma);**  $U_{Na}^{+} \times P_{cr}$ ; for the denominator, switch everything,  $P_{Na}^{+} \times U_{cr}$  (cr = creatinine)

**What is the prerenal FENa value?**

<1.0; renal failure from decreased renal blood flow (e.g., cardiogenic, hypovolemia, arterial obstruction, etc.)

## Lab Values Acute Renal Failure

**BUN-to-Cr ratio:****Prerenal?**

>20:1

**Renal ATN?**

<20:1

**FENa:****Prerenal?**

<1

**Renal ATN?**

>1

## **Urine osmolality:**

**Prerenal?**

>500

**Renal ATN?**

<350

## **Urine Na<sup>+</sup>:**

**Prerenal?**

<20

**Renal ATN?**

>40

## **Urine SG (Specific Gravity):**

**Prerenal?**

>1.020

## **How long do Lasix® effects last?**

6 hours = **L**ASIX = **L**Asts **SIX** hours

## **What is the formula for flow/pressure/resistance?**

Remember **P**ower **FoR**ward: **P**ressure = **F**low × **R**esistance

## **What is the “10-for-0.08 rule” of acid–base?**

For every increase of  $P_{aCO_2}$  by **10** mm Hg, the pH falls by **0.08**

## **What is the “40, 50, 60 for 70, 80, 90 rule” for O<sub>2</sub> sats?**

$PaO_2$  of **40, 50, 60** corresponds roughly to an O<sub>2</sub> sat of **70, 80, 90**, respectively

## **One liter of O<sub>2</sub> via nasal cannula raises Fio<sub>2</sub> by how much?**

≈3%

## **What is pure respiratory acidosis?**

Low pH (acidosis), increased  $\text{Paco}_2$ , normal bicarbonate

**What is pure respiratory alkalosis?**

High pH (alkalosis), decreased  $\text{Paco}_2$ , normal bicarbonate

**What is pure metabolic acidosis?**

Low pH, low bicarbonate, normal  $\text{Paco}_2$

**What is pure metabolic alkalosis?**

High pH, high bicarbonate, normal  $\text{Paco}_2$

**List how the body compensates for each of the following:**

**Respiratory acidosis**

Increased bicarbonate

**Respiratory alkalosis**

Decreased bicarbonate

**Metabolic acidosis**

Decreased  $\text{Paco}_2$

**Metabolic alkalosis**

Increased  $\text{Paco}_2$

**What does MOF stand for?**

Multiple Organ Failure

**What does SIRS stand for?**

Systemic Inflammatory Response Syndrome

## SICU DRUGS

### Dopamine

**What is the site of action and effect at the following levels:**

**Low dose (1 to 3  $\mu\text{g/kg/min}$ )?**

+ + dopa agonist; **renal vasodilation** (a.k.a. “renal dose dopamine”)

**Intermediate dose (4 to 10  $\mu\text{g/kg/min}$ )?**

+  $\alpha_1$ , + +  $\beta_1$ ; positive inotropy and some vasoconstriction

**High dose ( $>10 \mu\text{g/kg/min}$ )?**

+ + +  $\alpha_1$  agonist; marked afterload increase from arteriolar vasoconstriction

**Has “renal dose” dopamine been shown to decrease renal failure?**

NO

## ■ Dobutamine

**What is the site of action?**

+ + +  $\beta_1$  agonist, + +  $\beta_2$

**What is the effect?**

↑ inotropy; ↑ chronotropy, decrease in systemic vascular resistance

## ■ Isoproterenol

**What is the site of action?**

+ + +  $\beta_1$  and  $\beta_2$  agonist

**What is the effect?**

↑ inotropy; ↑ chronotropy; (+ vasodilation of skeletal and mesenteric vascular beds)

## ■ Epinephrine (EPI)

### **What is the site of action?**

++  $\alpha_1$ ,  $\alpha_2$ , +++  $\beta_1$ , and  $\beta_2$  agonist

### **What is the effect?**

↑ inotropy; ↑ chronotropy

### **What is the effect at high doses?**

Vasoconstriction

## ■ Norepinephrine (NE)

### **What is the site of action?**

+++  $\alpha_1$ ,  $\alpha_2$ , +++  $\beta_1$ , and  $\beta_1$  agonist

### **What is the effect?**

↑ inotropy; ↑ chronotropy; ++ increase in blood pressure

### **What is the effect at high doses?**

Severe vasoconstriction

## ■ Vasopressin

### **What is the action?**

Vasoconstriction (increases MAP, SVR)

### **What are the indications?**

Hypotension, especially refractory to other vasopressors (low-dose infusion—0.01–0.04 units per minute) or as a bolus during ACLS (40 u)

## ■ Sodium Nitroprusside (SNP)

### What is the site of action?

+++ venodilation; +++ arteriolar dilation

### What is the effect?

Decreased preload and afterload (allowing blood pressure titration)

### What is the major toxicity of SNP?

**Cyanide** toxicity

## INTENSIVE CARE PHYSIOLOGY

### Define the following terms:

#### **Preload**

Load on the heart muscle that stretches it to end-diastolic volume (end-diastolic pressure) = intravascular volume

#### **Afterload**

Load or resistance the heart must pump against = vascular tone = SVR

#### **Contractility**

Force of heart muscle contraction

#### **Compliance**

Distensibility of heart by the preload

### What is the Frank-Starling curve?

Cardiac output increases with increasing preload up to a point

### What factors influence mixed venous oxygen saturation?

Oxygen **delivery** (hemoglobin concentration, arterial oxygen saturation, cardiac output) and oxygen **extraction** by the peripheral tissues

**What lab test for tissue ischemia is based on the shift from aerobic to anaerobic metabolism?**

Serum lactic acid levels

**Define the following terms:**

**Dead space**

That part of the inspired air that does not participate in gas exchange (e.g., the gas in the large airways/ET tube not in contact with capillaries)

Think: space = air

**Shunt fraction**

That fraction of pulmonary venous blood that does not participate in gas exchange

Think: shunt = blood

**What causes increased dead space?**

Overventilation (emphysema, excessive PEEP) or underperfusion (pulmonary embolus, low cardiac output, pulmonary artery vasoconstriction)

**At high shunt fractions, what is the effect of increasing  $F_{iO_2}$  on arterial  $P_{O_2}$ ?**

At high shunt fractions (>50%), changes in  $F_{iO_2}$  have almost no effect on arterial  $P_{O_2}$  because the blood that does “see” the  $O_2$  is already at maximal  $O_2$  absorption; thus, increasing the  $F_{iO_2}$  has no effect ( $F_{iO_2}$  can be minimized to prevent oxygen toxicity)

**Define ARDS**

**A**cute **R**espiratory **D**istress **S**yndrome: lung inflammation causing respiratory failure

**What is the ARDS diagnostic triad?**

**A “CXR”:**

**C:** Capillary wedge pressure <18

**X:** X-ray of chest with bilateral infiltrates

**R:** Ratio of  $P_{aO_2}$  to  $F_{iO_2}$  <300 (a.k.a. “P/F ratio”)

## **Define ARDS:**

### **Mild?**

P/F ratio 200 to 300

### **Moderate?**

P/F ratio 100 to 200

### **Severe?**

P/F ratio  $\leq 100$

## **What does the classic chest x-ray look like with ARDS?**

Bilateral fluffy infiltrates

## **How can you remember the $P_{aO_2}$ -to- $F_{iO_2}$ , or PF, ratio?**

Think: “PUFF” ratio: PF ratio =  $P_{aO_2}$ : $F_{iO_2}$  ratio

## **At what concentration does $O_2$ toxicity occur?**

$F_{iO_2}$  of  $>60\% \times 48$  hours; thus, try to keep  $F_{iO_2} <60\%$  at all times

## **What are the ONLY ventilatory parameters that have been shown to decrease mortality in ARDS patients?**

Low tidal volumes ( $\leq 6$  cc/kg) and low plateau pressures  $<30$

## **What are the main causes of carbon dioxide retention?**

Hypoventilation, increased dead space ventilation, and increased carbon dioxide production (as in hypermetabolic states)

## **Why are carbohydrates minimized in the diet/TPN of patients having difficulty with hypercapnia?**

Respiratory Quotient (RQ) is the ratio of  $CO_2$  production to  $O_2$  consumption and is highest for carbohydrates (1.0) and lowest for fats (0.7)

# **HEMODYNAMIC MONITORING**

## **Why are indwelling arterial lines used for blood pressure monitoring**

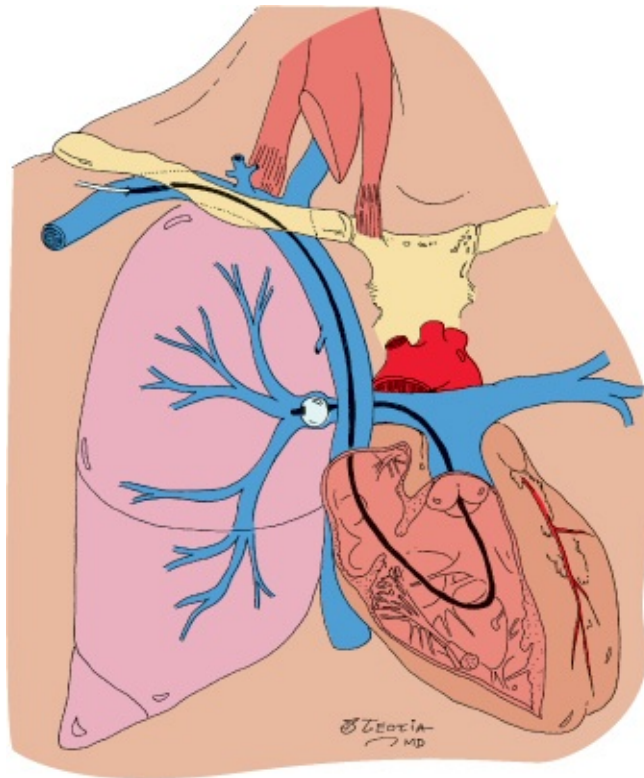
### **in critically ill patients?**

Because of the need for frequent measurements, the inaccuracy of frequently repeated cuff measurements, the inaccuracy of cuff measurements in hypotension, and the need for frequent arterial blood sampling/labs

### **What is a Swan–Ganz (PA) catheter?**

Pulmonary capillary pressure after balloon occlusion of the pulmonary artery, which is equal to left atrial pressure because there are no valves in the pulmonary system

Left atrial pressure is essentially equal to left ventricular end-diastolic pressure (LVEDP): left heart preload, and, thus, intravascular volume status.



### **What is the primary use of the PCWP?**

As an indirect measure of preload = intravascular volume

## **MECHANICAL VENTILATION**

### **Define ventilation**

Air through the lungs; monitored by  $P_{CO_2}$

## **Define oxygenation**

Oxygen delivery to the alveoli; monitored by O<sub>2</sub> sats and PO<sub>2</sub>

## **What can increase ventilation to decrease PCO<sub>2</sub>?**

Increased respiratory rate (RR), increased tidal volume (minute ventilation)

## **What is minute ventilation?**

Volume of gas ventilated through the lungs (RR × tidal volume)

## **Define tidal volume**

Volume delivered with each breath; should be 6 to 8 cc/kg on the ventilator

## **Are ventilation and oxygenation related?**

Basically no; you can have an O<sub>2</sub> sat of 100% and a Pco<sub>2</sub> of 150; O<sub>2</sub> sats do not tell you anything about the Pco<sub>2</sub> (key point!)

## **What can increase PO<sub>2</sub> (oxygenation) in the ventilated patient?**

Increased FiO<sub>2</sub>

Increased PEEP

## **What can decrease PCO<sub>2</sub> in the ventilated patient?**

Increased RR

Increased tidal volume (i.e., increase minute ventilation)

## **Define the following modes:**

### **IMV**

**Intermittent Mandatory Ventilation:** mode with intermittent mandatory ventilations at a predetermined rate; patients can also breathe on their own above the mandatory rate **without** help from the ventilator

### **SIMV**

**Synchronous IMV:** mode of IMV that delivers the mandatory breath synchronously with patient's initiated effort; if no breath is initiated, the ventilator delivers the predetermined mandatory breath

### **A-C**

**Assist-Control ventilation:** mode in which the ventilator delivers a breath when the patient initiates a breath, or the ventilator “assists” the patient to breathe; if the patient does not initiate a breath, the ventilator takes “control” and delivers a breath at a predetermined rate

### **CPAP**

**Continuous Positive Airway Pressure:** positive pressure delivered **continuously** (during expiration and inspiration) by ventilator, but no volume breaths (patient breathes on own)

### **Pressure support**

Pressure is delivered only **with an initiated breath**; pressure support decreases the work of breathing by overcoming the resistance in the ventilator circuit

### **APRV**

**Airway Pressure Release Ventilation:** high airway pressure intermittently released to a low airway pressure (shorter period of time)

### **HFV**

**High Frequency Ventilation:** rapid rates of ventilation with small tidal volumes

### **Define PEEP**

**Positive End Expiration Pressure:** positive pressure maintained at the end of a breath; keeps alveoli open

### **What is “physiologic PEEP”?**

PEEP of 5 cm H<sub>2</sub>O; thought to approximate normal pressure in normal nonintubated people caused by the closed glottis

### **What are the typical initial ventilator settings:**

#### **Mode?**

Synchronous Intermittent mandatory ventilation

#### **Tidal volume?**

6 to 8 mL/kg

**Ventilator rate?**

10 breaths/min

**Fio<sub>2</sub>?**

100% and wean down

**PEEP?**

5 cm H<sub>2</sub>O

From these parameters, change according to blood-gas analysis

**What is a normal I:E (inspiratory-to-expiratory time)?**

1:2

**When would you use an inverse I:E ratio (e.g., 2:1, 3:1, etc.)?**

To allow for longer inspiration in patients with poor compliance, to allow for “alveolar recruitment”

**When would you use a prolonged I:E ratio (e.g., 1:4)?**

COPD, to allow time for complete exhalation (prevents “breath stacking”)

**What clinical situations cause increased airway resistance?**

Airway or endotracheal tube obstruction, bronchospasm, ARDS, mucous plug, CHF (pulmonary edema)

**What are the presumed advantages of PEEP?**

Prevention of alveolar collapse and atelectasis, improved gas exchange, increased pulmonary compliance, decreased shunt fraction

**What parameters must be evaluated in deciding if a patient is ready to be extubated?**

Patient alert and able to protect airway, gas exchange ( $P_{aO_2} > 70$ ,  $P_{aCO_2} < 50$ ), tidal volume ( $> 5$  cc/kg), minute ventilation ( $< 10$  L/min), negative inspiratory pressure ( $< -20$  cm H<sub>2</sub>O, or more negative),  $F_{iO_2} \leq 40\%$ , PEEP 5,  $P_{H} > 7.25$ , RR  $< 35$ , Tobin index  $< 105$

**What is the Rapid-Shallow Breathing (a.k.a. “Tobin”) index?**

Rate: Tidal volume ratio; Tobin index  $<105$  is associated with successful extubation (Think: **R**espiratory **T**herapist = **RT** = **R**ate: **T**idal volume)

**What is a possible source of fever in a patient with an NG or nasal endotracheal tube?**

Sinusitis (diagnosed by sinus films/CT scan)

**What is the 35–45 rule of blood gas values?**

Normal values:

pH = 7.35 - 7.45

Pco<sub>2</sub> = 35 - 45

**Which medications can be delivered via an endotracheal tube?**

Think “NAVEL”:

Narcan

Atropine

Vasopressin

Epinephrine

Lidocaine

**What conditions should you think of with ↑ peak airway pressure and ↓ urine output?**

- . Tension pneumothorax
- . Abdominal compartment syndrome

## RAPID FIRE REVIEW

**What is the diagnosis?**

**48-year-old male with pancreatitis now with acute onset of respiratory failure, PaO<sub>2</sub> to FiO<sub>2</sub> ratio of 89, nl heart echo, bilateral pulmonary edema on CXR**

Severe ARDS

**67-year-old female with severe diverticulitis now with acute onset of respiratory failure, PaO<sub>2</sub>-to-FiO<sub>2</sub> ratio of 234, nl heart echo, bilateral pulmonary edema on CXR**

Mild ARDS

**22-year-old male s/p MCC 48-year-old now with bleeding through liver and pelvic packs; TEG reveals a progressive narrowing of the TEG tracing over time (small tail)**

Hyperfibrinolysis

**22-year-old female s/p fall with severe TBI, urine output 30 to 50 cc/hr, CVP 15, sodium of 128**

SIADH

**45-year-old with severe pancreatitis, now with increasing peak airway pressures, decreased urine output, and hypotension**

Abdominal compartment syndrome

**70-year-old male with severe sepsis on three pressors (vasopressors), antibiotics, refractory to fluid bolus and progressively increasing doses of pressors**

Adrenal insufficiency

**44-year-old male with pulmonary contusions s/p several infusions of KCl for hypokalemia but with no increase in post-infusion potassium level**

Hypomagnesemia

**44-year-old female with severe pancreatitis on ventilator ABG reveals pH of 7.2, PO<sub>2</sub> of 100, PCO<sub>2</sub> of 65, bicarbonate 26**

Respiratory acidosis (uncompensated)

**65-year-old male s/p pulmonary contusion on a ventilator, ABG reveals pH 7.35, PO<sub>2</sub> 80, PCO<sub>2</sub> of 60, bicarbonate of 35**

Compensated respiratory acidosis

**34-year-old female s/p liver injury from an MVC on the ventilator,**

**ABG reveals pH 7.23, PO<sub>2</sub> 105, PCO<sub>2</sub> 40, bicarbonate 17**

Metabolic acidosis

**76-year-old male with severe diverticulitis on ventilator, pH 7.35, PO<sub>2</sub> 76, PCO<sub>2</sub> 25, bicarbonate 16**

Metabolic acidosis with respiratory compensation

**45-year-old "found down" with pH of 7.17, PCO<sub>2</sub> 39, PO<sub>2</sub> 90, sodium 140, chloride 108, bicarbonate 26**

Normal anion gap metabolic acidosis ( $140 - 108 - 26 = 6$ )

**56-year-old female "found down" with pH of 7.19, sodium 140, bicarbonate 18, chloride 100**

Increased anion gap acidosis ( $140 - 18 - 100 = 22$ )

**What is the treatment?**

**34-year-old female s/p MVC with carotid dissection on CTA**

Antiplatelet (aspirin and/or Plavix®) or anticoagulation (enoxaparin or IV heparin or PO anticoagulation medication, classically Coumadin®) therapy

**25-year-old male s/p crush injury with CK of 45,000, dark urine**

Myoglobinuria: IV fluid hydration, ± bicarbonate IV

**DVT prophylaxis for 34-year-old trauma patient with acute renal failure**

Unfractionated heparin

**78-year-old male in ICU develops SVT and hypotensive 75/palp**

Synchronized cardioversion

**80-year-old male s/p Hartmann's procedure for severe fecal diverticulitis, now with urine output of 10 ccs per hour, FENA <1%, creatinine 1.7, BUN-to-cre ratio of >20, urine sodium of 8**

Prerenal acute renal failure, treat with IV volume

# Chapter 65 Vascular Surgery

**What must be present for a successful arterial bypass operation?**

- . Inflow (e.g., patent aorta)
- . Outflow (e.g., open distal popliteal artery)
- . Run off (e.g., patent trifurcation vessels down to the foot)

**What is the major principle of safe vascular surgery?**

Get **proximal** and **distal** control of the vessel to be worked on!

**What does it mean to “POTTS” a vessel?**

Place a vessel loop twice around a vessel so that if you put tension on the vessel loop, it will occlude the vessel

**What is the suture needle orientation through graft versus diseased artery in a graft to artery anastomosis?**

Needle “in-to-out” of the lumen in diseased artery to help **tack down the plaque** and the needle “out-to-in” on the graft

**What are the three layers of an artery?**

- . Intima
- . Media
- . Adventitia

**Which arteries supply the blood vessel itself?**

Vaso vasorum

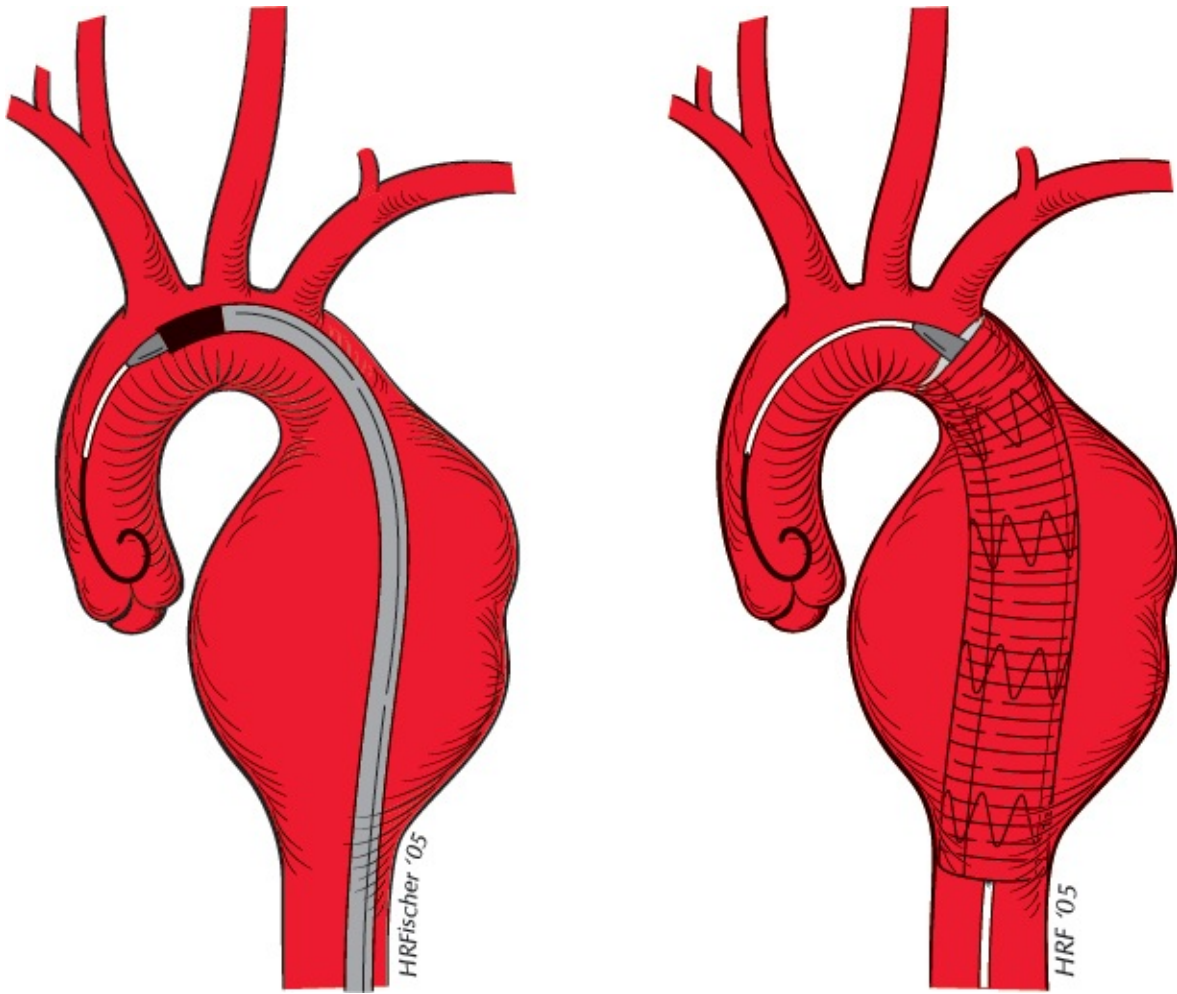
**What is a true aneurysm?**

Dilation ( $>2\times$  nL diameter) of all three layers of a vessel

**What is a false aneurysm (a.k.a. “pseudoaneurysm”)?**

Dilation of artery not involving all three layers

**What is “ENDOVASCULAR” repair?**



Placement of a catheter in artery and then deployment of a graft intraluminally

## PERIPHERAL VASCULAR DISEASE

**What is peripheral vascular disease (PVD)?**

Occlusive atherosclerotic disease in the lower extremities

**What is the most common site of arterial atherosclerotic occlusion in the lower extremities?**

Occlusion of the SFA in Hunter's canal

**What are the symptoms of PVD?**

Intermittent claudication, rest pain, erectile dysfunction, sensorimotor

impairment, tissue loss

### **What is intermittent claudication?**

Pain, cramping, or both of the lower extremity, usually the calf muscle, after walking a specific distance; then the pain/cramping resolves after stopping for a specific amount of time while standing; this pattern is reproducible

### **What is rest pain?**

Pain in the foot, usually over the distal metatarsals; this pain arises at rest (classically at night, awakening the patient)

### **What classically resolves rest pain?**

Hanging the foot over the side of the bed or standing; gravity affords some extra flow to the ischemic areas

### **What are the signs of PVD?**

Absent pulses, bruits, muscular atrophy, decreased hair growth, thick toenails, tissue necrosis/ulcers/infection

### **What is the site of a PVD ulcer versus a venous stasis ulcer?**

PVD arterial insufficiency ulcer—usually on the toes/foot

Venous stasis ulcer—medial malleolus (ankle)

### **What is the ABI?**

Ankle to Brachial Index (**ABI**); simply, the ratio of the systolic blood pressure at the ankle to the systolic blood pressure at the arm (brachial artery) A:B; ankle pressure taken with Doppler; the ABI is noninvasive

### **What ABIs are associated with normals, claudicators, and rest pain?**

Normal ABI:  $\geq 1.0$

Claudicator ABI:  $< 0.6$

Rest pain ABI:  $< 0.4$

### **Who gets false ABI readings?**

Patients with calcified arteries, especially those with diabetes

### **What are PVRs?**

Pulse Volume Recordings; pulse wave forms are recorded from lower

extremities representing volume of blood per heart beat at sequential sites down leg

Large wave form means good collateral blood flow  
(Noninvasive using pressure cuffs)

### **Prior to surgery for chronic PVD, what diagnostic test will every patient receive?**

**A-gram** (arteriogram: dye in vessel and x-rays) maps disease and allows for best treatment option (i.e., angioplasty vs. surgical bypass vs. endarterectomy)  
Gold standard for diagnosing PVD

### **What is the bedside management of a patient with PVD?**

- . Sheep skin (easy on the heels)
- . Foot cradle (keeps sheets/blankets off the feet)
- . Skin lotion to avoid further cracks in the skin that can go on to form a fissure and then an ulcer

### **What are the indications for surgical treatment in PVD?**

Use the acronym “**STIR**”:

Severe claudication refractory to conservative treatment that affects quality of life/livelihood (e.g., can't work because of the claudication)

Tissue necrosis

Infection

Rest pain

### **What is the treatment of claudication?**

For the vast majority, conservative treatment, including exercise, smoking cessation, treatment of HTN, diet, aspirin, with or without Trental<sup>®</sup> (pentoxifylline)

### **How can the medical conservative treatment for claudication be remembered?**

Use the acronym “**PACE**”:

Pentoxifylline

Aspirin

Cessation of smoking

Exercise

**How does aspirin work?**

Inhibits platelets (inhibits cyclooxygenase and platelet aggregation)

**How does Trental® (pentoxifylline) work?**

Results in increased RBC deformity and flexibility (Think: pentoXifylline = RBC fleXibility)

**What is the risk of limb loss with claudication?**

5% limb loss at 5 years (Think: 5 in 5), 10% at 10 years (Think: 10 in 10)

**What is the risk of limb loss with rest pain?**

>50% of patients will have amputation of the limb at some point

**In the patient with PVD, what is the main postoperative concern?**

Cardiac status, because most patients with PVD have coronary artery disease;  
≈20% have an AAA

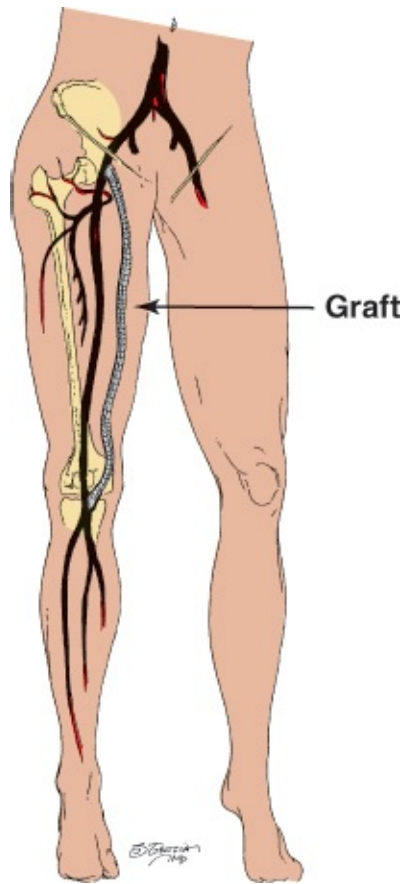
MI is the most common cause of postoperative death after a PVD operation

**What are the treatment options for severe PVD?**

- . Surgical graft bypass
- . Angioplasty—balloon dilation
- . Endarterectomy—remove diseased intima and media
- . Surgical patch angioplasty (place patch over stenosis)

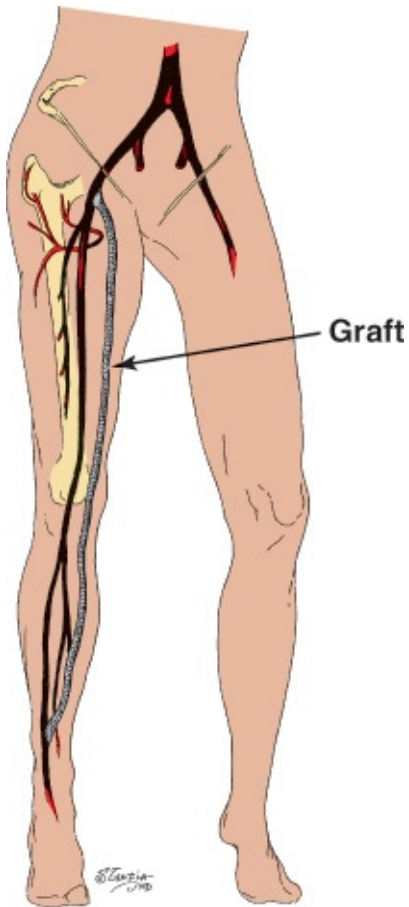
**What is a FEM-POP bypass?**

Bypass SFA occlusion with a graft from the **FEM**oral artery to the **POPl**iteal artery



### **What is a FEM-DISTAL bypass?**

Bypass from the **FEM**oral artery to a **DISTAL** artery (peroneal artery, anterior tibial artery, or posterior tibial artery)



**What graft material has the longest patency rate?**

Autologous vein graft

**What is an “in situ” vein graft?**

Saphenous vein is more or less left in place, all branches are ligated, and the vein valves are broken with a small hook or cut out; a vein can also be used if reversed so that the valves do not cause a problem

**What type of graft is used for above-the-knee FEM-POP bypass?**

Either vein or Gortex® graft; vein still has better patency

**What type of graft is used for below-the-knee FEM-POP or FEM-DISTAL bypass?**

Must use vein graft; prosthetic grafts have a prohibitive thrombosis rate

**What is DRY gangrene?**

Dry necrosis of tissue without signs of infection (“mummified tissue”)

### **What is WET gangrene?**

Moist necrotic tissue with signs of infection

### **What is blue toe syndrome?**

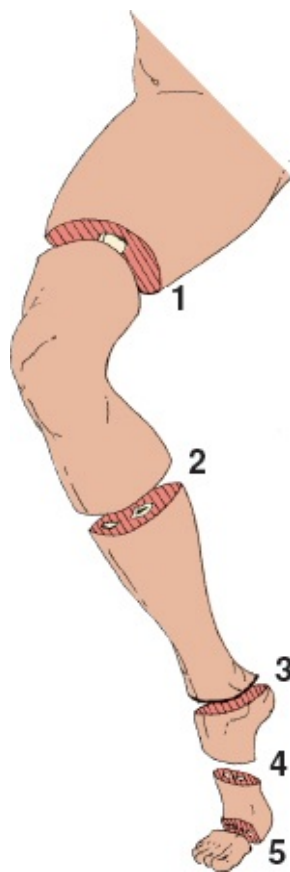
Intermittent painful blue toes (or fingers) due to microemboli from a proximal arterial plaque

## **LOWER EXTREMITY AMPUTATIONS**

### **What are the indications?**

Irreversible tissue ischemia (no hope for revascularization bypass) and necrotic tissue, severe infection, severe pain with no bypassable vessels, or if patient is not interested in a bypass procedure

### **Identify the level of the following amputations:**



- . Above-the-**K**nee Amputation (**AKA**)
- . Below-the-**K**nee Amputation (**BKA**)

- . Symes amputation
- . Transmetatarsal amputation
- . Toe amputation

### **What is a Ray amputation?**

Removal of toe and head of metatarsal

## **ACUTE ARTERIAL OCCLUSION**

### **What is it?**

Acute occlusion of an artery, usually by embolization; other causes include acute thrombosis of an atheromatous lesion, vascular trauma

### **What are the classic signs/symptoms of acute arterial occlusion?**

**“Six P’s”:**

1. **Pain**
2. **Paralysis**
3. **Pallor**
4. **Paresthesia**
5. **Polar** (some say **Poikilothermia**—you pick)
6. **Pulselessness**

(You **must** know these!)

### **What is the classic timing of pain with acute arterial occlusion from an embolus?**

Acute onset; the patient can classically tell you exactly when and where it happened

### **What is the immediate preoperative management?**

- . Anticoagulate with IV heparin (bolus followed by constant infusion)
- . A-gram

### **What are the sources of emboli?**

- . Heart—85% (e.g., clot from AFib, clot forming on dead muscle after MI, endocarditis, myxoma)
- . Aneurysms

- . Atheromatous plaque (atheroembolism)

**What is the most common cause of embolus from the heart?**

**AFib**

**What is the most common site of arterial occlusion by an embolus?**

Common femoral artery (SFA is the most common site of arterial occlusion from atherosclerosis)

**What diagnostic studies are in order?**

- . A-gram
- . ECG (looking for MI, AFib)
- . Echocardiogram ( $\pm$ ) looking for clot, MI, valve vegetation

**What is the treatment?**

Surgical embolectomy via cutdown and Fogarty balloon (bypass is reserved for embolectomy failure)

**What is a Fogarty?**

Fogarty balloon catheter—catheter with a balloon tip that can be inflated with saline; used for embolectomy

**How is a Fogarty catheter used?**

Insinuate the catheter with the balloon deflated past the embolus and then inflate the balloon and pull the catheter out; the balloon brings the embolus with it

**How many mm in diameter is a 12-French Fogarty catheter?**

Simple: To get mm from French measurements, divide the French number by  $\pi$ , or 3.14; thus, a 12-French catheter is  $12/3 = 4$  mm in diameter

**What must be looked for postoperatively after reperfusion of a limb?**

**Compartment syndrome**, hyperkalemia, renal failure from myoglobinuria, MI

**What is compartment syndrome?**

Leg (calf) is separated into compartments by very unyielding fascia; **tissue swelling** from reperfusion can increase the intracompartmental pressure

**What are the signs/symptoms of compartment syndrome?**

Classic signs include pain, especially after passive flexing/extension of the foot, paralysis, paresthesias, and pallor; **pulses are present** in most cases because systolic pressure is much higher than the minimal 30 mm Hg needed for the syndrome!

**Can a patient have a pulse and compartment syndrome?**

**YES!**

**How is the diagnosis made?**

History/suspicion, compartment pressure measurement

**What is the treatment of compartment syndrome?**

Treatment includes opening compartments via bilateral calf-incision fasciotomies of all four compartments in the calf

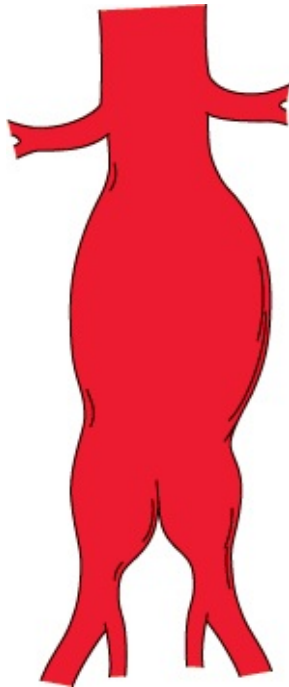
## ABDOMINAL AORTIC ANEURYSMS

**What is it also known as?**

AAA, or “triple A”

**What is it?**

Abnormal dilation of the abdominal aorta ( $>1.5\text{--}2\times$  normal), forming a true aneurysm



**What is the male-to-female ratio?**

≈6:1

**What is the common etiology?**

Believed to be **atherosclerotic** in 95% of cases; 5% inflammatory

**What is the most common site?**

Infrarenal (95%)

**What is the incidence?**

5% of all adults >60 years of age

**What percentage of patients with AAA have a peripheral arterial aneurysm?**

20%

**What are the risk factors?**

**Atherosclerosis**, hypertension, smoking, male gender, advanced age, connective tissue disease

**What are the symptoms?**

Most AAAs are **asymptomatic** and discovered during routine abdominal exam

by primary care physicians; in the remainder, symptoms range from vague epigastric discomfort to back and abdominal pain

### **What are the risk factors for rupture?**

Increasing aneurysm diameter, COPD, HTN, recent rapid expansion, large diameter, hypertension, symptomatic

### **What are the signs of rupture?**

Classic triad of ruptured AAA:

1. **Abdominal pain**
2. **Pulsatile abdominal mass**
3. **Hypotension**

### **What is the risk of rupture per year based on AAA diameter size?**

<5 cm = 4%

5 to 7 cm = 7%

>7 cm = 20%

### **Where does the aorta bifurcate?**

At the level of the **umbilicus**; therefore, when palpating for an AAA, palpate above the umbilicus and below the xiphoid process

### **What are the diagnostic tests?**

Use U/S to follow AAA clinically; other tests involve contrast CT scan and A-gram; A-gram will assess lumen patency and iliac/renal involvement

### **What are the indications for surgical repair of AAA?**

**AAA >5.5 cm** in diameter, if the patient is not an overwhelming high risk for surgery; also, rupture of the AAA, any size AAA with rapid growth, symptoms/embolization of plaque

### **What is the treatment?**

Endovascular repair for most

### **What is endovascular repair?**

Repair of the AAA by femoral catheter placed stents

# MESENTERIC ISCHEMIA

## ■ Chronic Mesenteric Ischemia

### **What is it?**

Chronic intestinal ischemia from long-term occlusion of the intestinal arteries; most commonly results from atherosclerosis; usually in two or more arteries because of the extensive collaterals

### **What are the symptoms?**

Weight loss, postprandial abdominal pain, anxiety/fear of food because of postprandial pain,  $\pm$  heme occult,  $\pm$  diarrhea/vomiting

### **What is “intestinal angina”?**

Postprandial pain from gut ischemia

### **What are the signs?**

Abdominal bruit is commonly heard

### **How is the diagnosis made?**

A-gram, duplex, MRA

### **What is the classic finding on A-gram?**

Two of the three mesenteric arteries are occluded, and the third patent artery has atherosclerotic narrowing

### **What are the treatment options?**

Bypass, endarterectomy, angioplasty, stenting

## ■ Acute Mesenteric Ischemia

### **What is it?**

Acute onset of intestinal ischemia

### **What are the causes?**

- . **Emboli** to a mesenteric vessel from the heart
- . **Acute thrombosis** of long-standing atherosclerosis of mesenteric artery

### **What are the causes of emboli from the heart?**

**AFib**, MI, cardiomyopathy, valve disease/endocarditis, mechanical heart valve

### **What drug has been associated with acute intestinal ischemia?**

Digitalis

### **To which intestinal artery do emboli preferentially go?**

Superior Mesenteric Artery (SMA)

### **What are the signs/symptoms of acute mesenteric ischemia?**

Severe pain—classically “**pain out of proportion to physical exam**,” no peritoneal signs until necrosis, vomiting/diarrhea/hyperdefecation,  $\pm$  heme stools

## **MEDIAN ARCUATE LIGAMENT SYNDROME**

### **What is it?**

Mesenteric ischemia resulting from narrowing of the celiac axis vessels by extrinsic compression by the median arcuate ligament

### **What is the median arcuate ligament composed of?**

Diaphragm hiatus fibers

### **What are the symptoms?**

Postprandial pain, weight loss

### **What are the signs?**

Abdominal bruit in almost all patients

### **How is the diagnosis made?**

A-gram

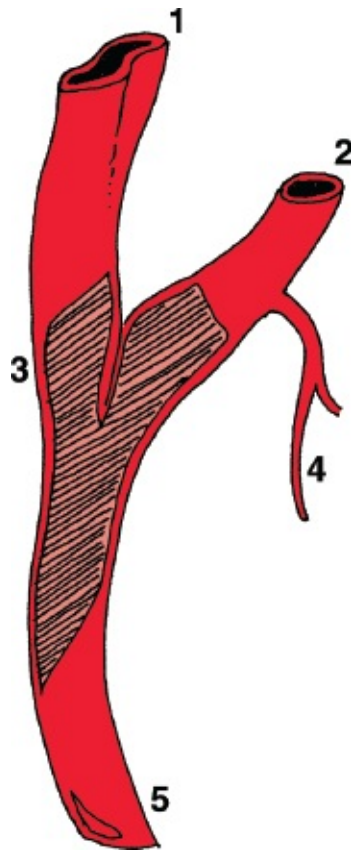
### **What is the treatment?**

Release arcuate ligament surgically

# CAROTID VASCULAR DISEASE

## Anatomy

Identify the following structures:



- . Internal carotid artery
  - . External carotid artery
  - . Carotid “bulb”
  - . Superior thyroid artery
  - . Common carotid artery
- (Shaded area: common site of plaque formation)

**What are the signs/symptoms?**

Amaurosis fugax, TIA, RIND, CVA

**Define the following terms:**

## **Amaurosis fugax**

Temporary monocular blindness (“curtain coming down”): seen with microemboli to retina; example of TIA

## **TIA**

**Transient Ischemic Attack:** focal neurologic deficit with resolution of all symptoms within 24 hours

## **RIND**

**Reversible Ischemic Neurologic Deficit:** transient neurologic impairment (without any lasting sequelae) lasting 24 to 72 hours

## **CVA**

**CerebroVascular Accident (stroke):** neurologic deficit with permanent brain damage

### **What is the risk of a CVA in patients with TIA?**

≈10% a year

### **What is the noninvasive method of evaluating carotid disease?**

**Carotid ultrasound/Doppler:** gives general location and degree of stenosis

### **What is the gold standard invasive method of evaluating carotid disease?**

A-gram

### **What is the surgical treatment of carotid stenosis?**

**Carotid EndArterectomy (CEA):** the removal of the diseased intima and media of the carotid artery, often performed with a shunt in place

### **What are the indications for CEA in the ASYMPTOMATIC patient?**

Carotid artery stenosis >60% (greatest benefit is probably in patients with >80% stenosis)

### **What are the indications for CEA in the SYMPTOMATIC (CVA, TIA, RIND) patient?**

Carotid stenosis >50%

**Before performing a CEA in the symptomatic patient, what study other than the A-gram should be performed?**

Head CT

**In bilateral high-grade carotid stenosis, on which side should the CEA be performed in the asymptomatic, right-handed patient?**

Left CEA first, to protect the dominant hemisphere and speech center

**What is the dreaded complication after a CEA?**

Stroke (CVA)

**What are the possible postoperative complications after a CEA?**

CVA, MI, hematoma, wound infection, hemorrhage, hypotension/hypertension, thrombosis, vagus nerve injury (change in voice), hypoglossal nerve injury (tongue deviation toward side of injury—"wheelbarrow" effect), intracranial hemorrhage

**What is the mortality rate after CEA?**

≈1%

**What is the perioperative stroke rate after CEA?**

Between 1% (asymptomatic patient) and 5% (symptomatic patient)

**What is the postoperative medication?**

Aspirin (inhibits platelets by inhibiting cyclooxygenase)

**What is the most common cause of death during the early postoperative period after a CEA?**

MI

**Define "Hollenhorst plaque"?**

Microemboli to retinal arterioles seen as bright defects

## **CLASSIC CEA INTRAOPERATIVE QUESTIONS**

**What thin muscle is cut right under the skin in the neck?**

Platysma muscle

**What are the extracranial branches of the internal carotid artery?**

None

**Which vein crosses the carotid bifurcation?**

Facial vein

**What is the first branch of the external carotid?**

Superior thyroidal artery

**Which muscle crosses the common carotid proximally?**

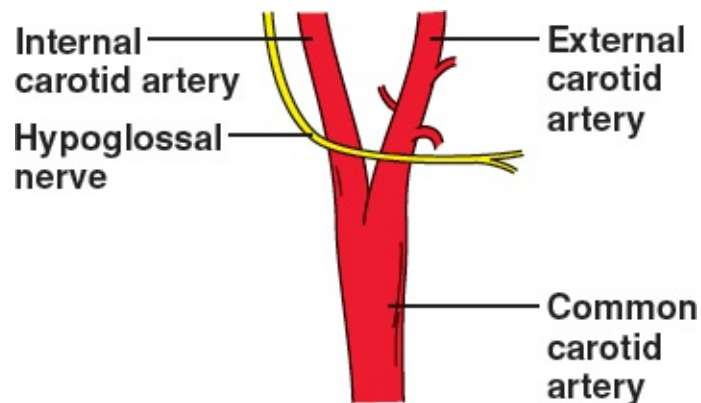
Omohyoid muscle

**Which muscle crosses the carotid artery distally?**

Digastric muscle (Think: **D**igastric = **D**istal)

**Which nerve crosses  $\approx 1$  cm distal to the carotid bifurcation?**

Hypoglossal nerve; cut it and the tongue will deviate toward the side of the injury (the “wheelbarrow effect”)



**Which nerve crosses the internal carotid near the ear?**

Facial nerve (marginal branch)

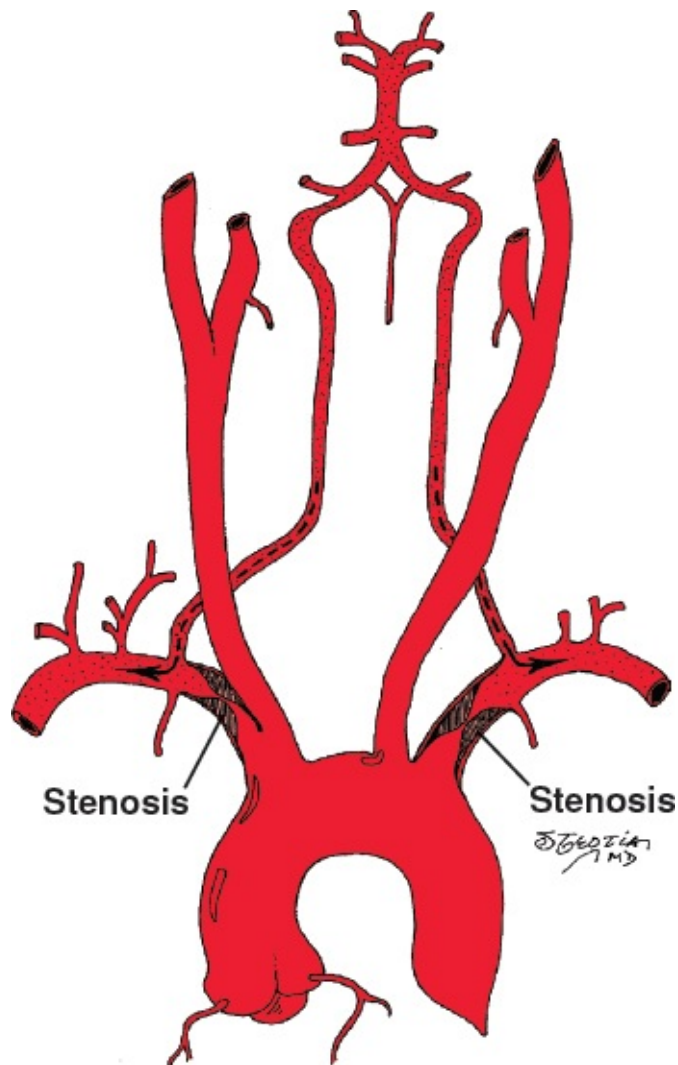
**What is in the carotid sheath?**

- . Carotid artery
- . Internal jugular vein
- . **Vagus** nerve (lies posteriorly in 98% of patients and anteriorly in 2%)
- . Deep cervical lymph nodes

# SUBCLAVIAN STEAL SYNDROME

## What is it?

Arm fatigue and vertebrobasilar insufficiency from obstruction of the left subclavian artery or innominate proximal to the vertebral artery branch point; ipsilateral arm movement causes increased blood flow demand, which is met by retrograde flow from the vertebral artery, thereby “stealing” from the vertebrobasilar arteries



## Which artery is most commonly occluded?

Left subclavian

## What are the symptoms?

Upper extremity claudication, syncopal attacks, vertigo, confusion, dysarthria, blindness, ataxia

### **What are the signs?**

Upper extremity blood pressure discrepancy, bruit (above the clavicle), vertebrobasilar insufficiency

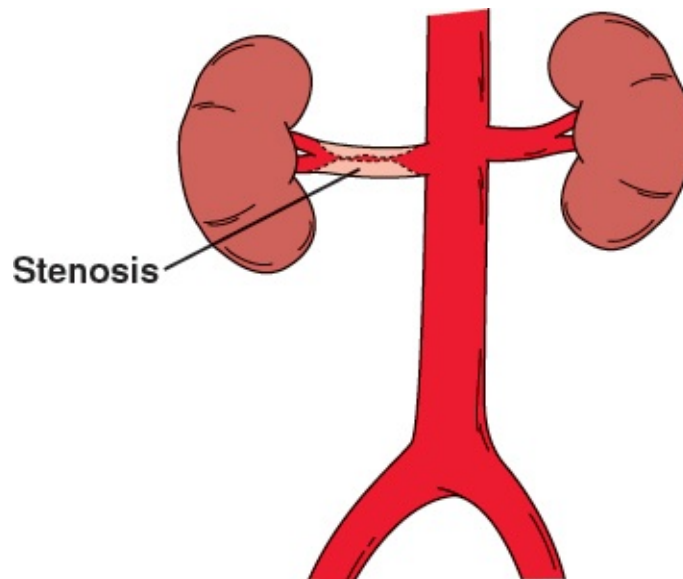
### **What is the treatment?**

Surgical bypass or endovascular stent

## **RENAL ARTERY STENOSIS**

### **What is it?**

Stenosis of renal artery, resulting in decreased perfusion of the juxtaglomerular apparatus and subsequent activation of the renin-angiotensin-aldosterone system (i.e., hypertension from renal artery stenosis)



### **What antihypertensive medication is CONTRAINDICATED in patients with hypertension from renovascular stenosis?**

ACE inhibitors (result in renal insufficiency)

## **SPLENIC ARTERY ANEURYSM**

### **What are the causes?**

Women—medial dysplasia

Men—atherosclerosis

### **How is the diagnosis made?**

Usually by abdominal pain → U/S or CT scan, in the O.R. after rupture, or incidentally by **eggshell calcifications seen on AXR**

### **What is the risk factor for rupture?**

Pregnancy

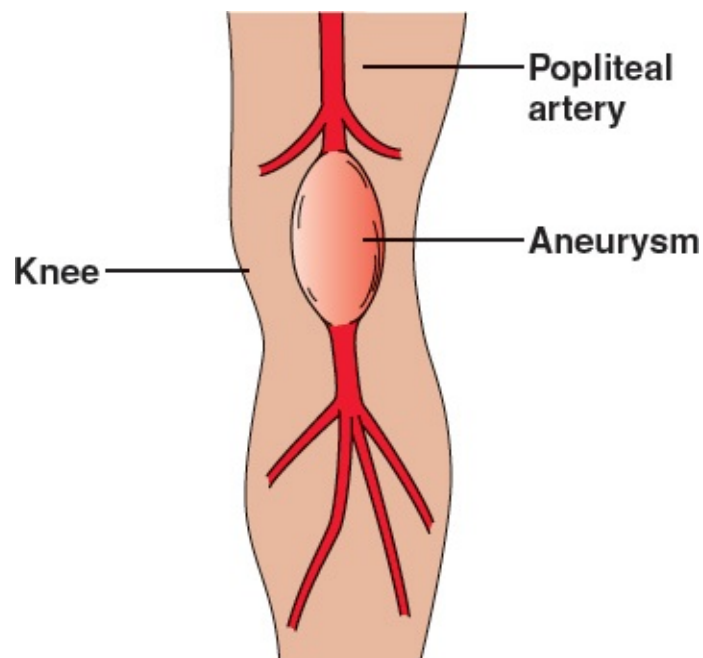
### **What are the indications for splenic artery aneurysm removal?**

Pregnancy, >2 cm in diameter, symptoms, and in women of childbearing age

## **POPLITEAL ARTERY ANEURYSM**

### **What is it?**

Aneurysm of the popliteal artery caused by atherosclerosis and, rarely, bacterial infection



### **How is the diagnosis made?**

Usually by physical exam → A-gram, U/S

### **Why examine the contralateral popliteal artery?**

50% of all patients with a popliteal artery aneurysm have a popliteal artery aneurysm in the contralateral popliteal artery

### **Why examine the rest of the arterial tree (especially the abdominal aorta)?**

**75% of all patients with popliteal aneurysms have additional aneurysms elsewhere;** >50% of these are located in the abdominal aorta/iliacs

### **What size of the following aneurysms is usually considered indications for surgical repair:**

#### **Thoracic aorta?**

>6.5 cm

#### **Abdominal aorta?**

>5.5 cm

#### **Iliac artery?**

>4 cm

#### **Femoral artery?**

>2.5 cm

#### **Popliteal artery?**

>2 cm

## **RAPID FIRE REVIEW**

### **What is the correct diagnosis?**

**65-year-old male presents with atrial fibrillation and acute onset of severe abdominal pain without peritonitis**

Mesenteric ischemia from an embolus to the SMA

**Tender pulsatile abdominal mass**

Abdominal aortic aneurysm

**Syncope with the use of the left arm**

Subclavian steal syndrome

**Name the most likely diagnosis:**

**24-year-old heavy cigarette smoker with initial onset of foot pain followed by digit necrosis**

Buerger's disease

**55-year-old woman with calf claudication, "hourglass" stenosis on angiogram of popliteal artery, and cyst on ultrasound of posterior knee**

Cystic degeneration of the popliteal artery

**65-year-old woman started on Coumadin® alone for atrial fibrillation develops acute DVT**

Coumadin®-induced hypercoagulable state due to decreased protein C and S

**72-year-old man with history of hypertension and tobacco abuse presents with 20 minutes of left eye blindness; left carotid bruit is detected on exam**

TIA—amaurosis fugax

**Pain on passive flexion/extension, arm or leg pain "out of proportion to injury"**

Extremity compartment syndrome

**29-year-old male smoker with necrotic fingers**

Buerger's disease

**Skier with fingers that go from white to blue to red**

Raynaud's phenomenon

**19-year-old man in motorcycle crash with knee dislocation and loss of pedal pulses**

Thrombosed popliteal artery

**Pregnant 22-year-old woman with LUQ pain and hypotension**

Ruptured splenic artery aneurysm

**Claudication, impotence, atrophy of thigh**

Leriche's syndrome

**Name the diagnostic modality:**

**28-year-old s/p head on MVC presents with chest pain and a widened mediastinum on chest x-ray**

CTA of chest to rule out aortic injury

**22-year-old male s/p gunshot wound to the left leg, distal pulse intact, no pulsatile bleeding nor hematoma, ABI is 0.5 (ABI is 1.1 in right leg)**

CTA or angiogram to rule out arterial injury to the extremity

**What is the treatment?**

**45-year-old with recent fascial closure after an open abdomen develops hypotension, decreased urine output, and elevated peak airway pressures**

Open fascia to treat for abdominal compartment syndrome

# SECTION IV

## **Subspecialty Surgery**

# Chapter 66 Introduction

**What is the motto of pediatric surgery?**

“Children are NOT little adults!”

## Pediatric IV Fluids and Nutrition

**What is the maintenance IV fluid for children?**

D5 1/4 NS + 20 mEq KCl

**Why 1/4 NS?**

Children (especially those <4 years of age) cannot concentrate their urine and cannot clear excess sodium

**How are maintenance fluid rates calculated in children?**

**4, 2, 1 per hour:**

**4 cc/kg for the first 10 kg of body weight**

**2 cc/kg for the second 10 kg of body weight**

**1 cc/kg for every kilogram over the first 20** (e.g., the rate for a child weighing 25 kg is  $4 \times 10 = 40$  plus  $2 \times 10 = 20$  plus  $1 \times 5 = 5$ , for an IVF rate of 65 cc/hr)

**What is the minimal urine output for children?**

From 1 to 2 mL/kg/hr

**What are the caloric requirements by age for the following patients:**

**Premature infants?**

80 Kcal/kg/day and then go up

**Children <1 year?**

≈100 Kcal/kg/day (90 to 120)

**Children ages 1 to 7?**

≈85 Kcal/kg/day (75 to 90)

**Children ages 7 to 12?**

≈70 Kcal/kg/day (60 to 75)

**Youths ages 12 to 18**

≈40 Kcal/kg/day (30 to 60)

**What are the protein requirements by age for the following patients:**

**Children <1 year?**

3 g/kg/day (2 to 3.5)

**Children ages 1 to 7?**

2 g/kg/day (2 to 2.5)

**Children ages 7 to 12?**

2 g/kg/day

**Youths ages 12 to 18?**

1.5 g/kg/day

**How many calories are in breast milk?**

20 Kcal/30 cc (same as most formulas)

## PEDIATRIC BLOOD VOLUMES

**Give blood volume per kilogram:**

**Newborn infant?**

85 cc

**Infants age 1 to 3 months?**

75 cc

**Child?**

70 cc

## FETAL CIRCULATION

**Oxygenated blood travels through the liver to the IVC through which structure?**

Ductus venosus

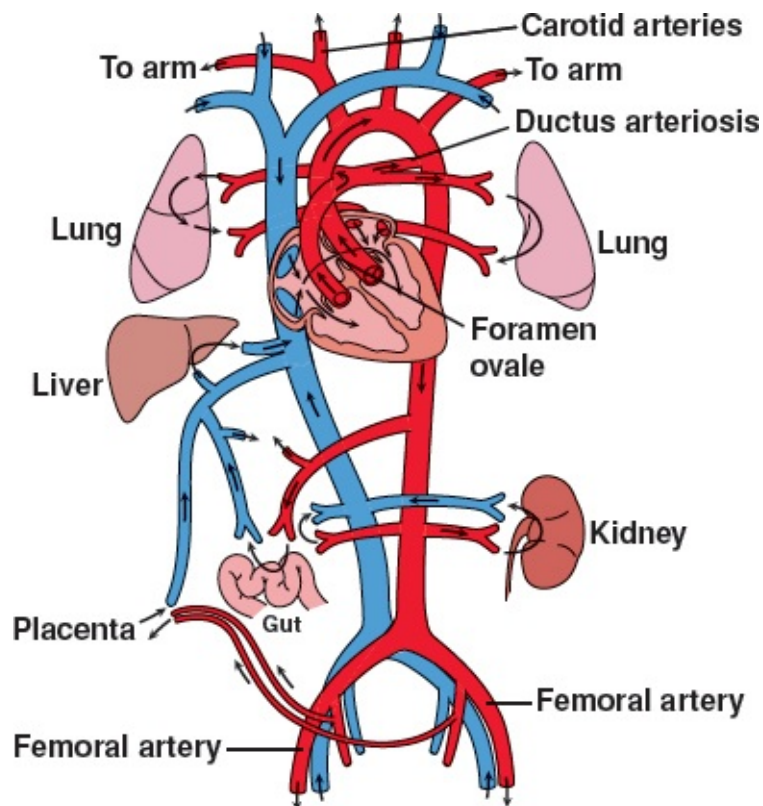
**Oxygenated blood passes from the right atrium to the left atrium through which structure?**

Foramen ovale

**Unsaturated blood goes from the right ventricle to the descending aorta through which structure?**

Ductus arteriosum

**Define the overall fetal circulation**



## ECMO

### What is ECMO?

**ExtraCorporeal Membrane Oxygenation:** chronic cardiopulmonary bypass—for complete respiratory support

### What are the indications?

Severe hypoxia, usually from congenital diaphragmatic hernia, meconium aspiration, persistent pulmonary hypertension, sepsis

### What are the contraindications?

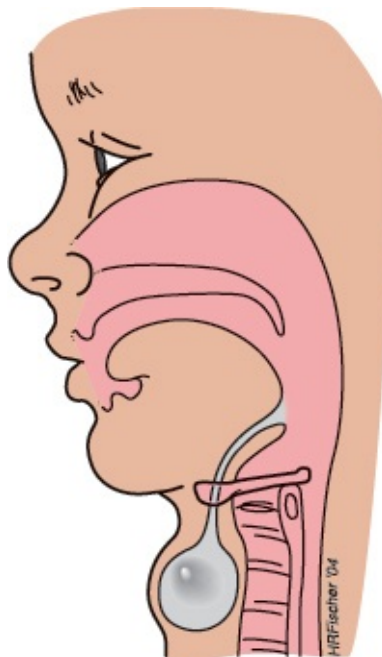
Weight <2 kg, **IVH** (Intra**V**entricular **H**emorrhage in brain contraindicated because of heparin in line)

## NECK

### ■ Thyroglossal Duct Cyst

#### What is it?

Remnant of the diverticulum formed by migration of thyroid tissue



**What is the average age at diagnosis?**

Usually presents  $\approx$ 5 years of age

**How is the diagnosis made?**

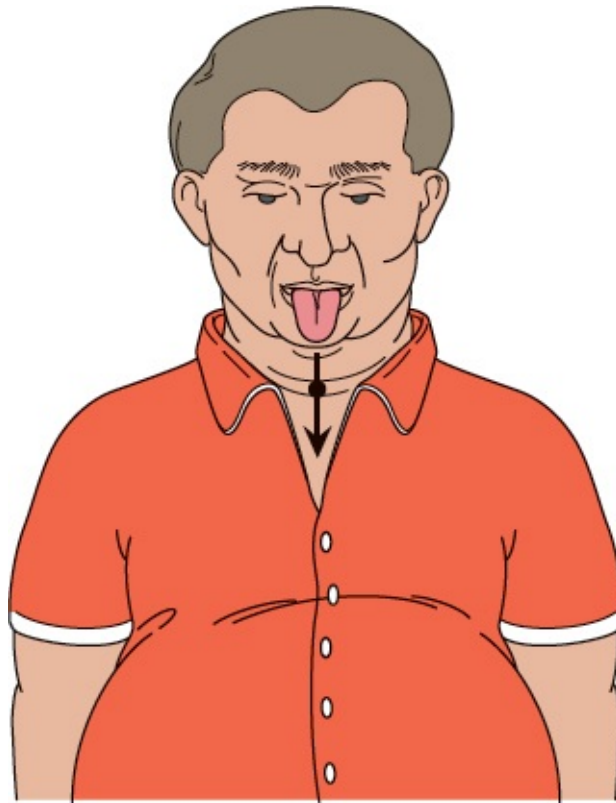
Ultrasound

**What is the anatomic location?**

Almost always in the **midline**

**How can one remember the position of the thyroglossal duct cyst?**

Think: thyro**GLOSSAL** = **TONGUE** midline sticking out



**What is the treatment?**

Antibiotics if infection is present, then excision, which must include the midportion of the hyoid bone and entire tract to foramen cecum (**Sistrunk** procedure)

■ **Branchial Cleft Anomalies**

### **What is it?**

Remnant of the primitive branchial clefts in which epithelium forms a sinus tract between the pharynx (second cleft), or the external auditory canal (first cleft), and the skin of the anterior neck; if the sinus ends blindly, a cyst may form

### **What is the common presentation?**

Infection because of communication between pharynx and external ear canal

### **What is the anatomic position?**

Second cleft anomaly—**lateral to the midline** along anterior border of the sternocleidomastoid, anywhere from angle of jaw to clavicle

First cleft anomaly—less common than second cleft anomalies; tend to be located higher under the mandible

### **What is the treatment?**

Antibiotics if infection is present, then surgical excision of cyst and tract once inflammation is resolved

### **What is the major anatomic difference between thyroglossal cyst and branchial cleft cyst?**

Thyroglossal cyst = **midline**

Branchial cleft cyst = **lateral**

(Think: brAnchial = lAteral)

## **Stridor**

### **What is stridor?**

Harsh, high-pitched sound heard on breathing caused by obstruction of the trachea or larynx

### **What are the signs/symptoms?**

Dyspnea, cyanosis, difficulty with feedings

### **What is the differential diagnosis?**

Laryngomalacia

Tracheobronchomalacia

## ■ Cystic Hygroma

### What is it?

Congenital abnormality of lymph sac resulting in lymphangioma

### What is the anatomic location?

Occurs in sites of primitive lymphatic lakes and can occur virtually anywhere in the body, most commonly in the floor of mouth; under the jaw; or in the neck, axilla, or thorax

### What is the treatment?

Early total surgical removal because they tend to enlarge; sclerosis may be needed if the lesion is unresectable

## ASPIRATED FOREIGN BODY (FB)

### Which bronchus do FBs go into more commonly (left or right)?

<Age 4—50/50

Age ≥4—most go into right bronchus because it develops into a straight shot (less of an angle)

### What is the most commonly aspirated object?

Peanut

### What is the associated risk with peanut aspiration?

Lipoid pneumonia

### How can you tell on A-P CXR if a coin is in the esophagus or the trachea?

Coin in **esophagus** results in the coin lying “en face” with face of the coin viewed as a **round object** because of compression by anterior and posterior structures

If coin is in the **trachea**, it is viewed as a **side projection** due to the U-shaped cartilage with membrane posteriorly

### What is the treatment of tracheal or esophageal FB?

Remove FB with bronchoscope or esophagoscope

## CHEST

### ■ Pectus Deformity

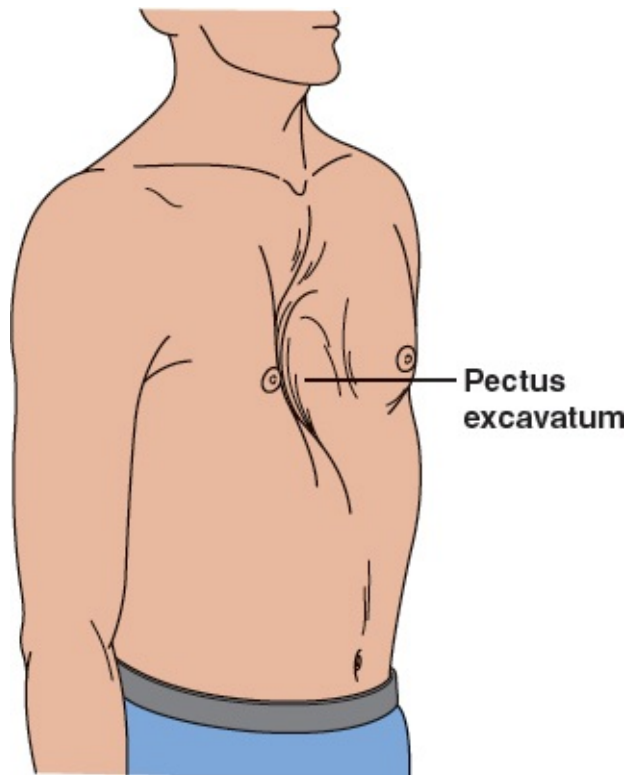
**What heart abnormality is associated with pectus abnormality?**

Mitral valve prolapse (many patients receive preoperative echocardiogram)

### ■ Pectus Excavatum

**What is it?**

Chest wall deformity with sternum caving inward (Think: exCAVatum = CAVE)



**What is the treatment?**

Open perichondrium, remove abnormal cartilage, place substernal strut; new cartilage grows back in the perichondrium in normal position; remove strut 6

months later

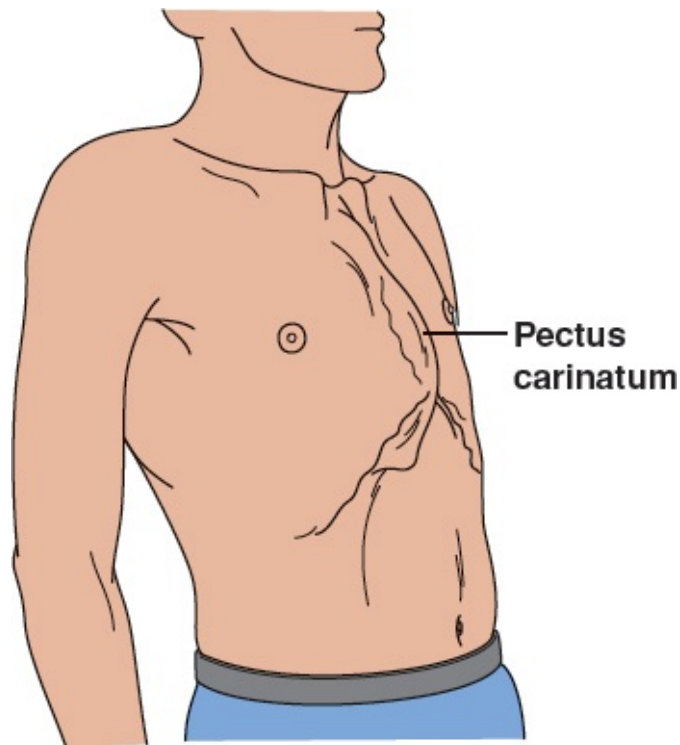
### **What is the NUSS procedure?**

Placement of metal strut to elevate sternum **without** removing cartilage

## **■ Pectus Carinatum**

### **What is it?**

Chest wall deformity with sternum outward (pectus = chest, carinatum = pigeon); much less common than pectus excavatum



### **What is the treatment?**

Open perichondrium and remove abnormal cartilage

Place substernal strut

New cartilage grows into normal position

Remove strut 6 months later

## **■ Esophageal Atresia without**

## Tracheoesophageal (TE) Fistula

### What is it?

Blind-ending esophagus from atresia

### What are the signs?

Excessive oral secretions and inability to keep food down

### How is the diagnosis made?

Inability to pass NG tube; plain x-ray shows tube coiled in upper esophagus and no gas in abdomen

### What is the definitive treatment?

Surgical with 1° anastomosis, often with preoperative stretching of blind pouch (other options include colonic or jejunal interposition graft or gastric tube formation if esophageal gap is long)

## ■ Esophageal Atresia with Tracheoesophageal (TE) Fistula

### What is it?

Esophageal atresia occurring with a fistula to the trachea; occurs in >90% of cases of esophageal atresia

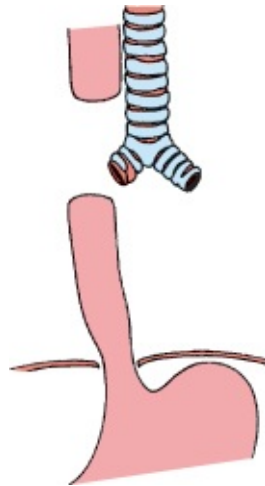### What is the incidence?

1 in 1500 to 3000 births

### Define the following types of fistulas/atresias:

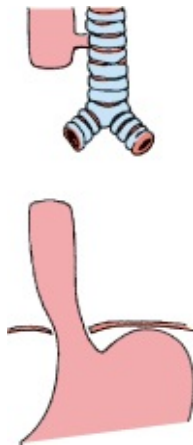#### Type A

Esophageal atresia without TE fistula (8%)



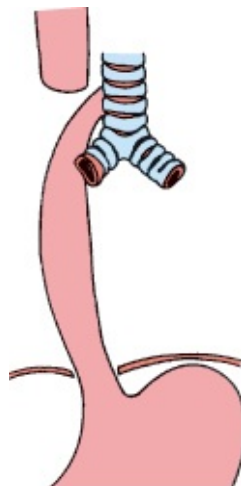
### **Type B**

Proximal esophageal atresia with proximal TE fistula (1%)



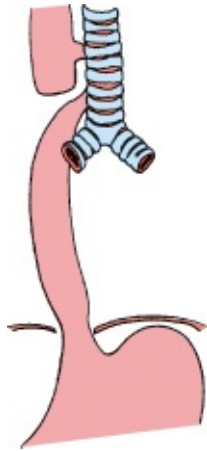
### **Type C**

Proximal esophageal atresia with distal TE fistula (85%); most common type



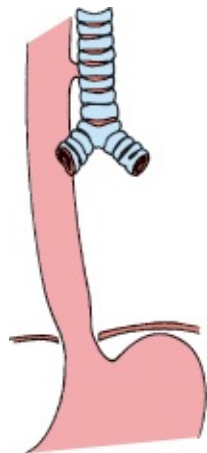
### **Type D**

Proximal esophageal atresia with both proximal and distal TE fistulas (2%)  
(Think: **D** = **D**ouble connection to trachea)



### **Type E**

“H-type” TE fistula without esophageal atresia (4%)



**How do you remember which type is most common?**

Simple: Most Common type is type **C**

**What is the initial treatment?**

Directed toward minimizing complications from aspiration:

1. Suction blind pouch (NPO/TPN)
2. Upright position of child
3. Prophylactic antibiotics (Amp/gent)

**What is the definitive treatment?**

Surgical correction via a thoracotomy, usually through the right chest with division of fistula and end-to-end esophageal anastomosis, if possible

### **What are the associated anomalies?**

**VACTERL** cluster (present in about 10% of cases):

Vertebral or vascular, **A**norectal, **C**ardiac, **T**E fistula, **E**sophageal atresia

**R**adial limb and renal abnormalities, **L**umbar and limb

Previously known as **VATER**: **V**ertebral, **A**nus, **T**E fistula, **R**adial

### **What is the significance of a “gasless” abdomen on AXR?**

No air to the stomach and, thus, no tracheoesophageal fistula

## **Congenital Diaphragmatic Hernia**

### **What is it?**

Failure of complete formation of the diaphragm, leading to a defect through which abdominal organs are herniated

### **What are the types of hernias?**

Bochdalek and Morgagni

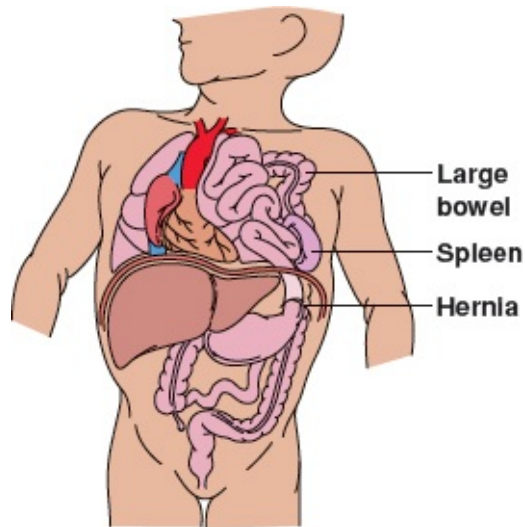
### **What are the associated positions?**

Bochdalek—posterolateral with L > R

Morgagni—anterior parasternal hernia, relatively uncommon

### **How to remember the position of the Bochdalek hernia?**

Think: BOCH DA LEK = “BACK TO THE LEFT”



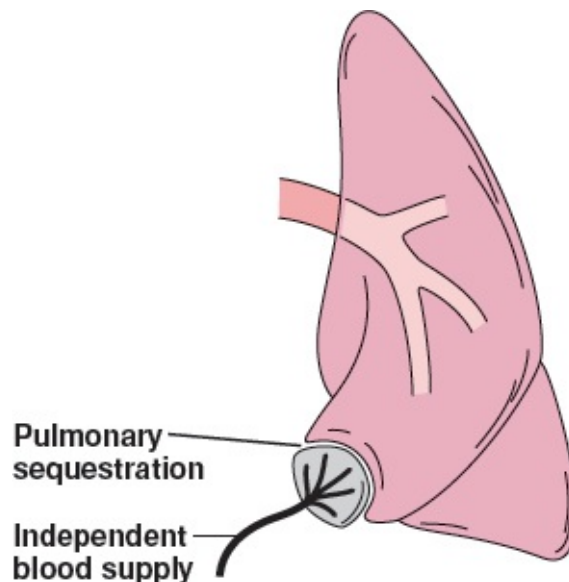
### What is the treatment?

NG tube, ET tube, stabilization, and if patient is stable, surgical repair; if patient is unstable: nitric oxide  $\pm$  ECMO then to the O.R. when feasible

## PULMONARY SEQUESTRATION

### What is it?

Abnormal benign lung tissue with separate blood supply that **DOES NOT** communicate with the normal tracheobronchial airway



What is the treatment of each type:

### **Extralobar?**

Surgical resection

### **Intralobar?**

Lobectomy

### **What is the major risk during operation for sequestration?**

Anomalous blood supply from below the diaphragm (can be cut and retracted into the abdomen and result in exsanguination!); always document blood supply by A-gram or U/S with Doppler flow

## **INGUINAL HERNIA**

### **What is the most commonly performed procedure by U.S. pediatric surgeons?**

Indirect inguinal hernia repair

### **What is the most common inguinal hernia in children?**

Indirect

### **What is an indirect inguinal hernia?**

Hernia lateral to Hesselbach's triangle into the internal inguinal ring and down the inguinal canal (Think: through the abdominal wall indirectly into the internal ring and out through the external inguinal ring)

### **What is Hesselbach's triangle?**

Triangle formed by:

1. Epigastric vessels
2. Inguinal ligament
3. Lateral border of the rectus sheath

### **What type of hernia goes through Hesselbach's triangle?**

Direct hernia from a weak abdominal floor; rare in children (0.5% of all inguinal hernias)

### **What is the incidence of indirect inguinal hernia in all children?**

≈3%

**What is the incidence in premature infants?**

Up to 30%

**What is the male-to-female ratio?**

6:1

**What are the risk factors for an indirect inguinal hernia?**

Male gender, ascites, V-P shunt, prematurity, family history, meconium ileus, abdominal wall defect elsewhere, hypo/epispadias, connective tissue disease, bladder exstrophy, undescended testicle, CF

**Which side is affected more commonly?**

**Right** (≈60%)

**What percentage are bilateral?**

≈15%

**What percentage have a family history of indirect hernias?**

≈10%

**What are the signs/symptoms?**

Groin bulge, scrotal mass, thickened cord, silk glove sign

**What is the “silk glove” sign?**

Hernia sac rolls under the finger like the finger of a silk glove

**Why should it be repaired?**

Risk of incarcerated/strangulated bowel or ovary; will not go away on its own

**How is a pediatric inguinal hernia repaired?**

High ligation of hernia sac (no repair of the abdominal wall floor, which is a big difference between the procedure in children vs. adults; high refers to high position on the sac neck next to the peritoneal cavity)

**Which infants need overnight apnea monitoring/observation?**

Premature infants; infants <3 months of age

**What is the risk of recurrence after high ligation of an indirect pediatric hernia?**

≈1%

**Define the following terms:**

**Cryptorchidism**

Failure of the testicle to descend into the scrotum

**Hydrocele**

Fluid-filled sac (i.e., fluid in a patent processus vaginalis or in the tunica vaginalis around the testicle)

**Communicating hydrocele**

Hydrocele that communicates with the peritoneal cavity and thus fills and drains peritoneal fluid or gets bigger, then smaller

**Noncommunicating hydrocele**

Hydrocele that does not communicate with the peritoneal cavity; stays about the same size

## ■ **Classic Intraoperative Questions During Repair of an Indirect Inguinal Hernia**

**From what abdominal muscle layer is the cremaster muscle derived?**

Internal oblique muscle

**From what abdominal muscle layer is the inguinal ligament (a.k.a. “Poupart’s ligament”) derived?**

External oblique

**What nerve travels with the spermatic cord?**

Ilioinguinal nerve

**Name the five structures in the spermatic cord**

- . Cremasteric muscle fibers
- . Vas deferens
- . Testicular artery
- . Testicular pampiniform venous plexus
- . With or without hernia sac

**What is the hernia sac made of?**

Basically peritoneum or a patent processus vaginalis

**What attaches the testicle to the scrotum?**

Gubernaculum

**How can the opposite side be assessed for a hernia intraoperatively?**

Many surgeons operatively explore the opposite side when they repair the affected side

Laparoscope is placed into the abdomen via the hernia sac and the opposite side internal inguinal ring is examined

**Name the remnant of the processus vaginalis around the testicle**

Tunica vaginalis

**What is a Littre's inguinal hernia?**

Hernia with a Meckel's diverticulum in the hernia sac

**What may a yellow/orange tissue that is not fat be on the spermatic cord/testicle?**

Adrenal rest

**What is the most common organ in an inguinal hernia sac in boys?**

Small intestine

**What is the most common organ in an inguinal hernia sac in girls?**

Ovary/fallopian tube

**What lies in the inguinal canal in girls instead of the vas?**

Round ligament

**Where in the inguinal canal does the hernia sac lie in relation to the other structures?**

Anteriomedially

**What is a “cord lipoma”?**

Preperitoneal fat on the cord structures (pushed in by the hernia sac); not a real lipoma

Should be removed surgically, if feasible

**Within the spermatic cord, do the vessels or the vas lie medially?**

Vas is medial to the testicular vessels

**What is a small outpouching of testicular tissue off the testicle?**

Testicular appendage (a.k.a. “the appendix testes”); should be removed with electrocautery

**What is a “blue dot” sign?**

Blue dot on the scrotal skin from a twisted testicular appendage

**How is a transected vas treated?**

Repair with primary anastomosis

**How do you treat a transected ilioinguinal nerve?**

Should not be repaired; many surgeons ligate it to inhibit neuroma formation

**What happens if you cut the ilioinguinal nerve?**

Loss of sensation to the medial aspect of the inner thigh and scrotum/labia; loss of cremasteric reflex

## UMBILICAL HERNIA

**What is it?**

Fascial defect at the umbilical ring

**What are the risk factors?**

- . African American infant
- . Premature infant

### **What are the indications for surgical repair?**

- . >1.5 cm defect
- . Bowel incarceration
- . >4 years of age

## **GERD**

### **What is it?**

GastroEsophageal Reflux Disease

### **What cytologic aspirate finding on bronchoscopy can diagnose aspiration of gastric contents?**

Lipid-laden macrophages (from phagocytosis of fat)

### **What are the indications for surgery?**

“SAFE”:

Stricture

Aspiration, pneumonia/asthma

Failure to thrive

Esophagitis

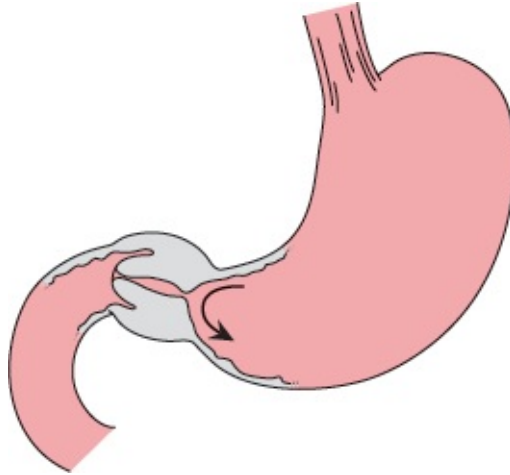
### **What is the surgical treatment?**

Nissen 360° fundoplication, with or without G tube

## **CONGENITAL PYLORIC STENOSIS**

### **What is it?**

Hypertrophy of smooth muscle of pylorus, resulting in obstruction of outflow

**What are the associated risks?**

Family history, firstborn males are affected most commonly, decreased incidence in African American population

**What is the incidence?**

1 in 750 births, male-to-female ratio = 4:1

**What is the average age at onset?**

Usually from 3 weeks after birth to about 3 months (“3 to 3”)

**What are the symptoms?**

Increasing frequency of regurgitation, leading to eventual nonbilious projectile vomiting

**Why is the vomiting nonbilious?**

Obstruction is proximal to the ampulla of Vater

**What are the signs?**

Abdominal mass or “olive” in epigastric region (85%), hypokalemic hypochloremic metabolic alkalosis, icterus (10%), visible gastric peristalsis, paradoxical aciduria, hematemesis (<10%)

**What is the differential diagnosis?**

Pylorospasm, milk allergy, increased ICP, hiatal hernia, GERD, adrenal insufficiency, uremia, malrotation, duodenal atresia, annular pancreas, duodenal web

**How is the diagnosis made?**

Usually by history and physical exam alone

U/S—demonstrates elongated (>15 mm) pyloric channel and thickened muscle wall (>3.5 mm)

If U/S is nondiagnostic, then barium swallow—shows “string sign” or “double railroad track sign”

**What is the initial treatment?**

Hydration and correction of alkalosis with D10 NS plus 20 mEq of KCl

(**Note:** the infant’s liver glycogen stores are very small; therefore, use D10; Cl<sup>-</sup> and hydration will correct the alkalosis)

**What is the definitive treatment?**

Surgical, via Fredet–Ramstedt pyloromyotomy (division of circular muscle fibers without entering the lumen/mucosa)

**What are the postoperative complications?**

Unrecognized incision through the duodenal mucosa, bleeding, wound infection, aspiration pneumonia

**What is the appropriate postoperative feeding?**

Start feeding with Pedialyte® at 6 to 12 hours postoperatively; advance to full-strength formula over 24 hours

**Which vein crosses the pylorus?**

Vein of Mayo

## DUODENAL ATRESIA

**What is it?**

Complete obstruction or stenosis of duodenum caused by an ischemic insult during development or failure of recanalization

**What are the signs?**

Bilious vomiting (if distal to the ampulla), epigastric distention

**What is the differential diagnosis?**

Malrotation with Ladd's bands, annular pancreas

### **How is the diagnosis made?**

Plain abdominal film revealing "double bubble," with one air bubble in the stomach and the other in the duodenum

### **What is the treatment?**

Duodenoduodenostomy or duodenojejunostomy

### **What are the associated abnormalities?**

50% to 70% have cardiac, renal, or other GI defects; 30% have trisomy 21

## **MECONIUM ILEUS**

### **What is it?**

Intestinal obstruction from solid meconium concretions

### **What is the incidence?**

Occurs in ≈15% of infants with CF

### **What percentage of patients with meconium ileus have CF (cystic fibrosis)?**

>95%

### **What are the signs/symptoms of meconium ileus?**

Bilious vomiting, abdominal distention, failure to pass meconium, Neuhauser's sign, peritoneal calcifications

### **What is the treatment?**

70% nonoperative clearance of meconium using Gastrografin® enema, ± acetylcysteine, which is hypertonic and therefore draws fluid into lumen, separating meconium pellets from bowel wall (60% success rate)

### **What is the surgical treatment?**

If enema is unsuccessful, then enterotomy with intraoperative catheter irrigation using acetylcysteine (Mucomyst®)

**What should you remove during all operative cases?**

Appendix

**What is the long-term medical treatment?**

Pancreatic enzyme replacement

## MECONIUM PERITONITIS

**What is it?**

Sign of **intrauterine** bowel perforation; sterile meconium leads to an intense local inflammatory reaction with eventual formation of calcifications

**What are the signs?**

Calcifications on plain films

## MECONIUM PLUG SYNDROME

**What is it?**

Colonic obstruction from meconium, forming a “plug”

**What are the signs/symptoms?**

Abdominal distention and **failure to pass meconium within the first 24 hours of life**; plain films demonstrate many loops of distended bowel and air-fluid levels

**What is the nonoperative treatment?**

Contrast enema is both diagnostic and therapeutic

**What is the major differential diagnosis?**

Hirschsprung's disease

**Is meconium plug highly associated with CF?**

No; <5% of patients have CF, in contrast to meconium ileus, in which nearly all have CF (95%)

# ANORECTAL MALFORMATIONS

## ■ Imperforate Anus

### **What is it?**

Congenital absence of normal anus (complete absence or fistula)

### **Define a “high” imperforate anus**

Rectum patent to level above puborectalis sling

### **Define “low” imperforate anus**

Rectum patent to below puborectalis sling

### **Which type is much more common in women?**

Low

### **What are the associated anomalies?**

Vertebral abnormalities, Anal abnormalities, Cardiac, **TE** fistulas, Esophageal Atresia, **R**adial/**R**enal abnormalities, **L**umbar abnormalities (**VACTERL**; most commonly TE fistula)

### **What are the signs/symptoms?**

No anus, fistula to anal skin or bladder, UTI, fistula to vagina or urethra, bowel obstruction, distended abdomen, hyperchloremic acidosis

### **How is the diagnosis made?**

Physical exam, perineal ultrasound

### **What is the treatment of the following conditions:**

#### **Low imperforate anus with anal fistula?**

Dilatation of anal fistula and subsequent anoplasty

#### **High imperforate anus?**

Diverting colostomy and mucous fistula; neoanus is usually made at 1 year of age

# HIRSCHSPRUNG'S DISEASE

## **What is it also known as?**

Aganglionic megacolon

## **What is it?**

Neurogenic form of intestinal obstruction in which obstruction results from inadequate relaxation and peristalsis; absence of normal ganglion cells of the rectum and colon

## **What is the male-to-female ratio?**

4:1

## **What is the anatomic location?**

Aganglionosis begins at the anorectal line and involves rectosigmoid in 80% of cases (10% have involvement to splenic flexure, and 10% have involvement of entire colon)

## **What are the signs/symptoms?**

Abdominal distention and bilious vomiting; >95% present with failure to pass meconium in the first 24 hours; may also present later with constipation, diarrhea, and decreased growth

## **What is the classic history?**

Failure to pass meconium in the first 24 hours of life

## **What imaging studies should be ordered?**

**AXR:** reveals dilated colon

**Unprepared barium enema:** reveals constricted aganglionic segment with dilated proximal segment, but this picture may not develop for 3 to 6 weeks; BE will also demonstrate retention of barium for 24 to 48 hours (normal evacuation = 10 to 18 hours)

## **What is needed for definitive diagnosis?**

Rectal biopsy

## **What is the “colonic transition zone”?**

Transition (taper) from aganglionic small colon into the large dilated normal colon seen on BE

### **What is the initial treatment?**

In neonates, a colostomy proximal to the transition zone prior to correction, to allow for pelvic growth and dilated bowel to return to normal size

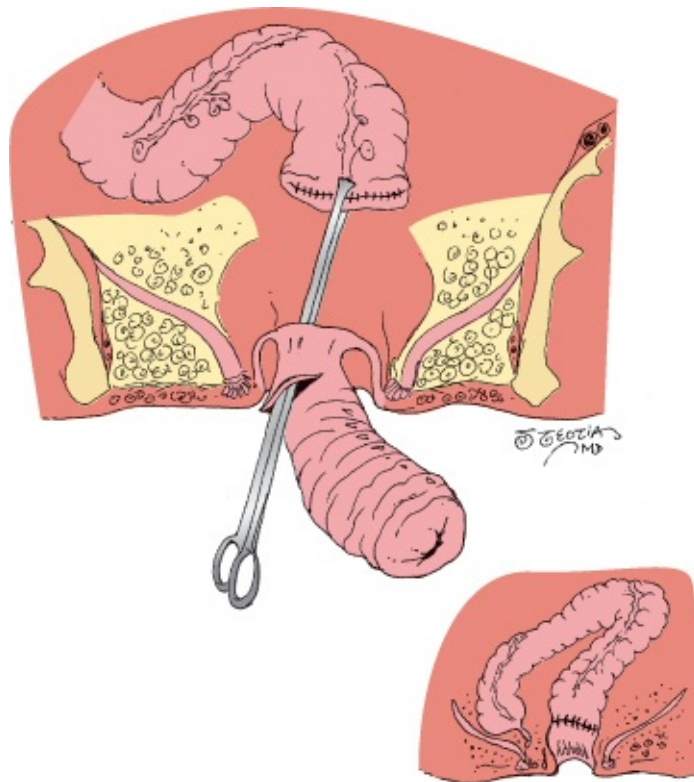
### **What is a “leveling” colostomy?**

Colostomy performed for Hirschsprung’s disease at the level of normally innervated ganglion cells as ascertained on frozen section intraoperatively

### **Describe the following procedures:**

#### **Swenson**

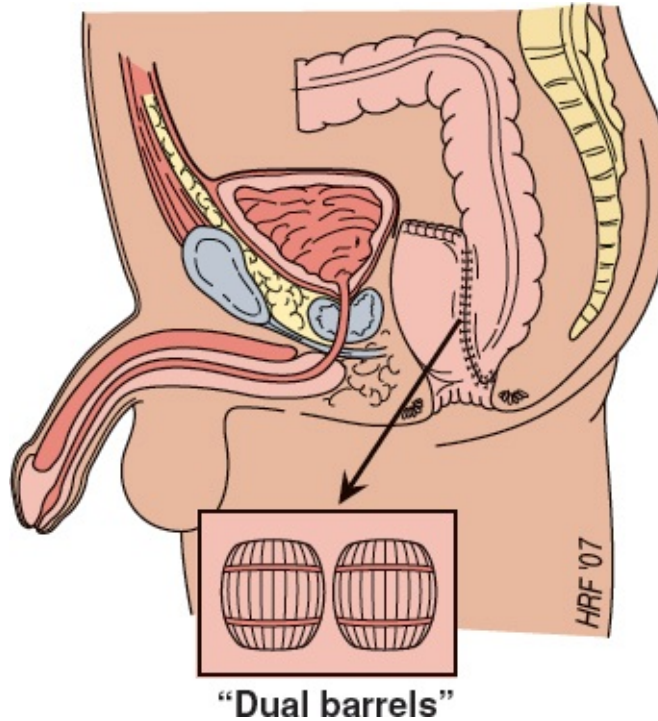
Primary anastomosis between the anal canal and healthy bowel (rectum removed)



#### **Duhamel**

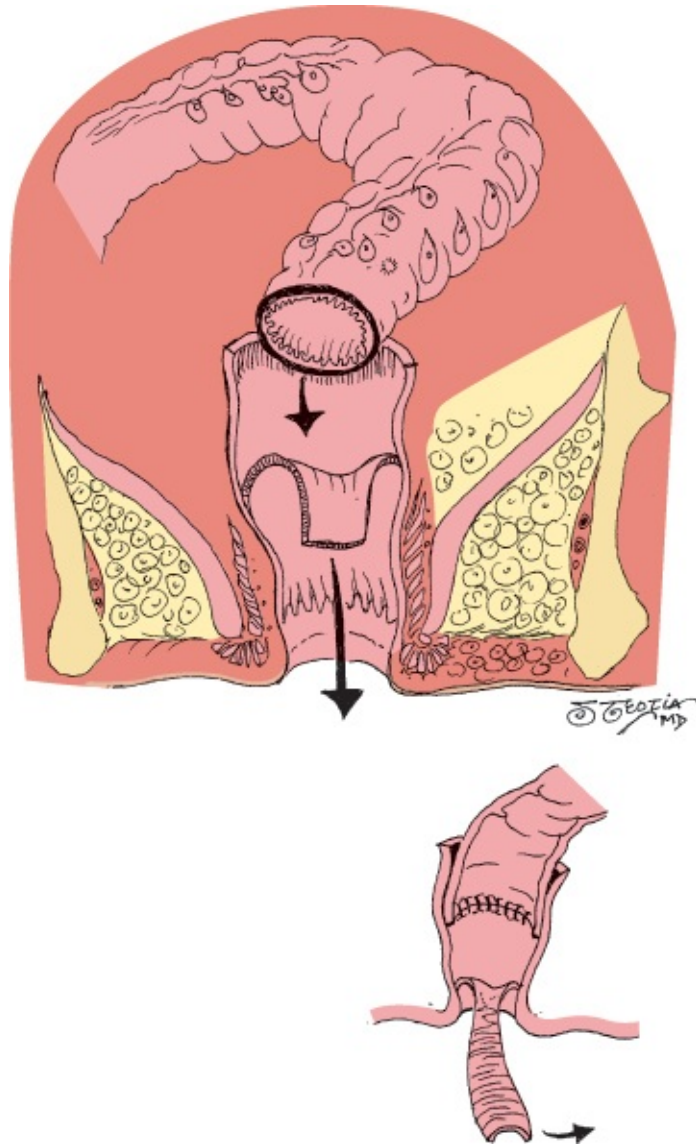
Anterior, aganglionic region of the rectum is preserved and anastomosed to a posterior portion of healthy bowel; a functional rectal pouch is thereby

created (Think: **duha** = **dual** barrels side by side)



## Soave

A.k.a. “endorectal pull-through”; this procedure involves bringing proximal normal colon through the aganglionic rectum, which has been stripped of its mucosa but otherwise present (Think: **SOAVE** = **SAVE** the rectum, lose the mucosa)



### What is the prognosis?

Overall survival rate >90%; >96% of patients continent; postoperative symptoms improve with age

## MALROTATION AND MIDGUT VOLVULUS

### What is it?

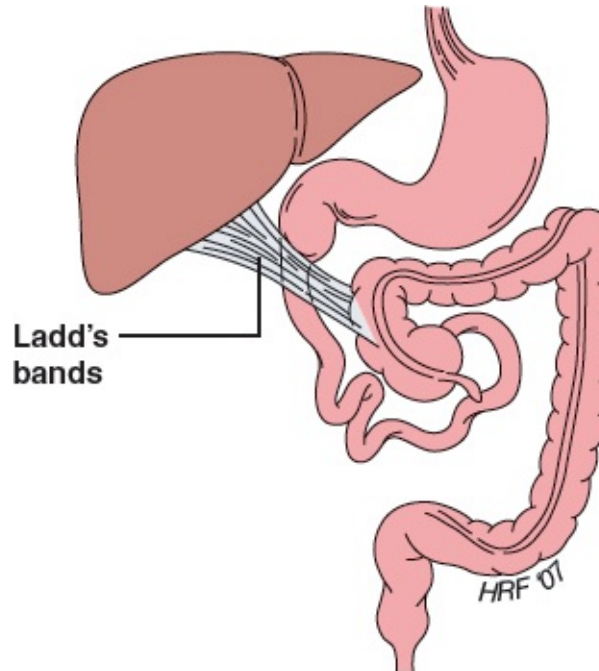
Failure of the normal 270° counterclockwise bowel rotation, with resultant abnormal intestinal attachments and anatomic position

### Where is the cecum?

With malrotation, the cecum usually ends up in the RUQ

### **What are Ladd's bands?**

Fibrous bands that extend from the abnormally placed cecum in the RUQ, often crossing over the duodenum and causing obstruction



### **What is the usual age at onset?**

33% are present by 1 week of age, 75% by 1 month, and 90% by 1 year

### **What is the usual presentation?**

Sudden onset of bilious vomiting (bilious vomiting in an infant is malrotation until proven otherwise!)

### **Why is the vomiting bilious?**

“Twist” is distal to the ampulla of Vater

### **How is the diagnosis made?**

Upper GI contrast study showing cutoff in duodenum; BE showing abnormal position of cecum in the upper abdomen

### **What are the possible complications?**

Volvulus with midgut infarction, leading to death or necessitating massive enterectomy (**rapid diagnosis is essential!**)

### **What is the treatment?**

IV antibiotics and fluid resuscitation with LR, followed by emergent laparotomy with Ladd's procedure; second-look laparotomy if bowel is severely ischemic in 24 hours to determine if remaining bowel is viable

### **What is the Ladd's procedure?**

- . **Counterclockwise** reduction of midgut volvulus
- . Splitting of Ladd's bands
- . Division of peritoneal attachments to the cecum, ascending colon
- . Appendectomy

### **In what direction is the volvulus reduced—clockwise or counterclockwise?**

Rotation of the bowel in a counterclockwise direction

### **Where is the cecum after reduction?**

LLQ

### **What is the cause of bilious vomiting in an infant until proven otherwise?**

Malrotation with midgut volvulus

## **OMPHALOCELE**

### **What is it?**

Defect of abdominal wall at umbilical ring; sac **covers** extruded viscera

### **How is it diagnosed prenatally?**

May be seen on **fetal** U/S after 13 weeks' gestation, with elevated maternal AFP

### **What comprises the "sac"?**

Peritoneum and amnion

### **What organ is often found protruding from an omphalocele, but is almost never found with a gastroschisis?**

Liver

## **What is the incidence?**

≈1 in 5000 births

## **How is the diagnosis made?**

Prenatal U/S

## **What are the possible complications?**

Malrotation of the gut, anomalies

## **What is the treatment?**

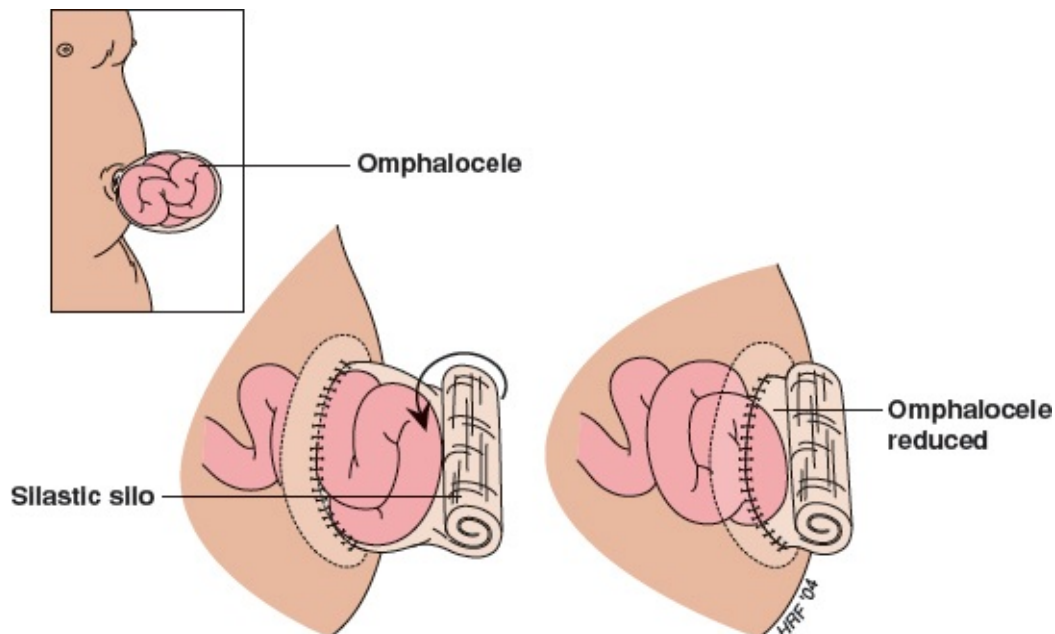
- . NG tube for decompression
- . IV fluids
- . Prophylactic antibiotics
- . Surgical repair of the defect

## **What is the treatment of a small defect (<2 cm)?**

Closure of abdominal wall

## **What is the treatment of a medium defect (2 to 10 cm)?**

Removal of outer membrane and placement of a silicone patch to form a “silo,” temporarily housing abdominal contents; the silo is then slowly decreased in size over 4 to 7 days, as the abdomen accommodates the viscera; then the defect is closed



### **What is the treatment of “giant” defects (>10 cm)?**

Skin flaps or treatment with Betadine® spray, mercurochrome, or silver sulfadiazine (Silvadene®) over defect; this allows an eschar to form, which epithelializes over time, allowing opportunity for future repair months to years later

### **What are the associated abnormalities?**

50% of cases occur with abnormalities of the GI tract, cardiovascular system, GU tract, musculoskeletal system, CNS, and chromosomes

### **Of what “pentalogy” is omphalocele a part?**

Pentalogy of Cantrell

### **What is the pentalogy of Cantrell?**

#### **“D COPS”:**

Diaphragmatic defect (hernia)

Cardiac abnormality

Omphalocele

Pericardium malformation/absence

Sternal cleft

## **GASTROSCHISIS**

### **What is it?**

Defect of abdominal wall; sac does not cover extruded viscera

### **How is it diagnosed prenatally?**

Possible at fetal ultrasound after 13 weeks' gestation, elevated maternal AFP

### **Where is the defect?**

Lateral to the umbilicus (Think: gAstrochisis = lAteral)

### **On what side of the umbilicus is the defect most commonly found?**

Right

### **What is the usual size of the defect?**

2 to 4 cm

### **What are the possible complications?**

Thick edematous peritoneum from exposure to amniotic fluid; malrotation of the gut

Other complications include hypothermia; hypovolemia from third-spacing; sepsis; and metabolic acidosis from hypovolemia and poor perfusion, NEC, prolonged ileus

### **How is the diagnosis made?**

Prenatal U/S

### **What is the treatment?**

Primary—NG tube decompression, IV fluids (D10 LR), and IV antibiotics

Definitive—surgical reduction of viscera and abdominal closure; may require staged closure with silo

### **What is a “silo”?**

Silastic silo is a temporary housing for external abdominal contents; silo is slowly tightened over time

### **What is the prognosis?**

>90% survival rate

### **What are the associated anomalies?**

Unlike omphalocele, relatively uncommon except for intestinal atresia, which occurs in 10% to 15% of cases

### **What are the major differences compared with omphalocele?**

No membrane coverings

Uncommon associated abnormalities

Lateral to umbilicus—not on umbilicus

### **How can you remember the position of omphalocele vs. gastroschisis?**

Think: OMphalocele = ON the umbilicus

### **How do you remember that omphalocele is associated with**

## **abnormalities in 50% of cases?**

Think: Omphalocele = “Oh no, lots of abnormalities”

# **APPENDICITIS**

## **What is it?**

Obstruction of the appendiceal lumen (fecalith, lymphoid hyperplasia), producing a closed loop with resultant inflammation that can lead to necrosis and perforation

## **What is its claim to fame?**

Most common surgical disease requiring emergency surgery in children

## **What is the affected age?**

Very rare before 3 years of age

## **What is the usual presentation?**

Onset of referred or **periumbilical pain** followed by **anorexia**, nausea, and vomiting (**Note:** Unlike gastroenteritis, **pain precedes vomiting**, then migrates to the **RLQ**, where it intensifies from local peritoneal irritation)  
If the patient is hungry and can eat, seriously question the diagnosis of appendicitis

## **How is the diagnosis made?**

History and physical exam

## **What are the signs/symptoms?**

Signs of peritoneal irritation may be present—guarding, muscle spasm, rebound tenderness, obturator and Psoas signs; low-grade fever rising to high grade if perforation occurs

## **What is the differential diagnosis?**

Intussusception, volvulus, Meckel’s diverticulum, Crohn’s disease, ovarian torsion, cyst, tumor, perforated ulcer, pancreatitis, PID, ruptured ectopic pregnancy, mesenteric lymphadenitis

## **What is the common bacterial cause of mesenteric lymphadenitis?**

*Yersinia enterocolitica*

**What are the associated lab findings with appendicitis?**

Increased WBC ( $>10,000$  per  $\text{mm}^3$  in  $>90\%$  of cases, with a left shift in most)

**What is the role of urinalysis?**

To evaluate for possible pyelonephritis or renal calculus, but mild hematuria and pyuria are common in appendicitis because of ureteral inflammation

**What radiographic studies may be performed?**

Often none; CXR to rule out RML or RLL pneumonia; abdominal films are usually nonspecific, but calcified fecalith is present in 5% of cases; U/S, CT scan

**What is the treatment?**

**Nonperforated**—prompt appendectomy and cefoxitin to avoid perforation

**Perforated**—triple antibiotics, fluid resuscitation, and prompt appendectomy; all pus is drained and cultures obtained, with postoperative antibiotics continued for 5 to 7 days,  $\pm$  drain

**How long should antibiotics be administered if nonperforated?**

24 hours

**How long if perforated?**

Usually 5 to 7 days or until WBCs are normal and patient is afebrile

**If a normal appendix is found upon exploration, what must be examined/ruled out?**

Meckel's diverticulum, Crohn's disease, intussusception, gynecologic disease

**What is the approximate risk of perforation?**

$\approx 25\%$  after 24 hours from onset of symptoms

$\approx 50\%$  by 36 hours

$\approx 75\%$  by 48 hours

## INTUSSUSCEPTION

**What is it?**

Obstruction caused by bowel telescoping into the lumen of adjacent distal bowel; may result when peristalsis carries a “leadpoint” downstream

**What is its claim to fame?**

Most common cause of small bowel obstruction in toddlers (<2 years old)

**What is the usual age at presentation?**

Disease of infancy; 60% present from 4 to 12 months of age, 80% by 2 years of age

**What is the most common site?**

Terminal ileum involving ileocecal valve and extending into ascending colon

**What is the most common cause?**

Hypertrophic Peyer’s patches, which act as a lead point; many patients have prior viral illness

**What are the signs/symptoms?**

Alternating lethargy and irritability (colic), bilious vomiting, “currant jelly” stools, RLQ mass on plain abdominal film, empty RLQ on palpation (Dance’s sign)

**What is the intussusciens?**

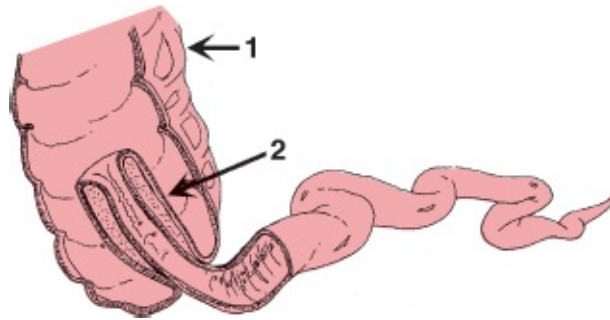
Recipient segment of bowel (Think: **recipiens** = intussusciens)

**What is the intussusceptum?**

Leading point or bowel that enters the intussusciens

**Identify locations 1 and 2 on the following illustration:**

- . Intussusciens
- . Intussusceptum



### **How can the spelling of intussusception be remembered?**

Imagine a navy ship named “The U.S.S. U.S.”—INTUSSUSCEPTION

### **What is the treatment?**

**Air** or barium enema; 85% reduce with hydrostatic pressure (i.e., barium = meter elevation air = maximum of 120 mm Hg); if unsuccessful, then laparotomy and reduction by “milking” the ileum from the colon should be performed

### **What are the causes of intussusception in older patients?**

Meckel’s diverticulum, polyps, and tumors, all of which act as a lead point

## **MECKEL’S DIVERTICULUM**

### **What is it?**

Remnant of the omphalomesenteric duct/vitelline duct, which connects the yolk sac with the primitive midgut in the embryo

### **What is the usual location?**

Between 45 and 90 cm proximal to the ileocecal valve on the antimesenteric border of the bowel

### **What is the major differential diagnosis?**

Appendicitis

### **Is it a true diverticulum?**

Yes; all layers of the intestine are found in the wall

### **What is the incidence?**

2% of the population at autopsy, but >90% of these are asymptomatic

**What is the gender ratio?**

2 to 3× more common in males

**What is the usual age at onset of symptoms?**

Most frequently in the first 2 years of life, but can occur at any age

**What are the possible complications?**

**Intestinal hemorrhage** (painless)—50%

Accounts for 50% of all lower GI bleeding in patients <2 years; bleeding results from ectopic gastric mucosa secreting acid → ulcer → bleeding

**Intestinal obstruction**—25%

Most common complication in adults; includes volvulus and intussusception

**Inflammation** (± perforation)—20%

**What percentage of cases have heterotopic tissue?**

>50%; usually gastric mucosa (85%), but duodenal, pancreatic, and colonic mucosa have been described

**What is the most common ectopic tissue in a Meckel's diverticulum?**

Gastric mucosa

**What other pediatric disease entity can also present with GI bleeding secondary to ectopic gastric mucosa?**

Enteric duplications

**What is the most common cause of lower GI bleeding in children?**

Meckel's diverticulum with ectopic gastric mucosa

**What is the "rule of 2s"?**

**2% are symptomatic**

Found ≈2 feet from ileocecal valve

Found in 2% of the population

Most symptoms occur before age 2

One of 2 will have ectopic tissue

Most diverticula are about 2 inches long

Male-to-female ratio = 2:1

### **What is a Meckel's scan?**

Scan for ectopic gastric mucosa in Meckel's diverticulum; uses **technetium** Tc 99m **pertechnetate** IV, which is preferentially taken up by gastric mucosa

## **NECROTIZING ENTEROCOLITIS**

### **What is it also known as?**

NEC

### **What is it?**

Necrosis of intestinal mucosa, often with bleeding; may progress to transmural intestinal necrosis, shock/sepsis, and death

### **What are the predisposing conditions?**

#### **PREMATURITY**

Stress: shock, hypoxia, RDS, apneic episodes, sepsis, exchange transfusions, PDA and cyanotic heart disease, hyperosmolar feedings, polycythemia, indomethacin

### **What is the pathophysiologic mechanism?**

Probable splanchnic vasoconstriction with decreased perfusion, mucosal injury, and probable bacterial invasion

### **What is its claim to fame?**

Most common cause of emergent laparotomy in the neonate

### **What are the signs/symptoms?**

Abdominal distention, vomiting, heme+ or gross rectal bleeding, fever or hypothermia, jaundice, abdominal wall erythema (consistent with perforation and abscess formation)

### **What are the radiographic findings?**

Fixed, dilated intestinal loops; pneumatosis intestinalis (air in the bowel wall); free air; and portal vein air (sign of advanced disease)

**What are the lab findings?**

Low hematocrit, glucose, and platelets

**What is the treatment?**

Most are managed medically:

1. Cessation of feedings
2. OG tube
3. IV fluids
4. IV antibiotics
5. Ventilator support, as needed

**What are the surgical indications?**

Free air in abdomen revealing perforation, and positive peritoneal tap revealing transmural bowel necrosis

**Operation?**

- . Resect
- . Stoma

**What is an option for bowel perforation in <1000 gram NEC patients?**

Placement of percutaneous drain (without laparotomy!)

**Is portal vein gas or pneumatosis intestinalis alone an indication for operation with NEC?**

No

**What are the indications for peritoneal tap?**

Severe thrombocytopenia, distended abdomen, abdominal wall erythema, unexplained clinical downturn

**What are the possible complications?**

Bowel necrosis, gram-negative sepsis, DIC, wound infection, cholestasis, short bowel syndrome, strictures, SBO

**What is the prognosis?**

>80% overall survival rate

## BILIARY TRACT

### **What is “physiologic jaundice”?**

Hyperbilirubinemia in the first 2 weeks of life from inadequate conjugation of bilirubin

### **What enzyme is responsible for conjugation of bilirubin?**

Glucuronyl transferase

### **How is hyperbilirubinemia from “physiologic jaundice” treated?**

UV light

### **What is Gilbert’s syndrome?**

Partial deficiency of glucuronyl transferase, leading to intermittent asymptomatic jaundice in the second or third decade of life

### **What is Crigler–Najjar syndrome?**

Rare genetic absence of glucuronyl transferase activity, causing unconjugated hyperbilirubinemia, jaundice, and death from kernicterus (usually within the first year)

## ■ Biliary Atresia

### **What is it?**

Obliteration of extrahepatic biliary tree

### **What are the signs/symptoms?**

Persistent jaundice (normal physiologic jaundice resolves in <2 weeks), hepatomegaly, splenomegaly, ascites and other signs of portal hypertension, acholic stools, biliuria

### **What are the lab findings?**

Mixed jaundice is always present (i.e., both direct and indirect bilirubin increased), with an elevated serum alkaline phosphatase level

### **What is the differential diagnosis?**

Neonatal hepatitis (TORCH); biliary hypoplasia

### **How is the diagnosis made?**

- . U/S to rule out choledochal cyst and to examine extrahepatic bile ducts and gallbladder
- . HIDA scan—shows no excretion into the GI tract (with phenobarbital preparation)
- . Operative cholangiogram and liver biopsy

### **What is the treatment?**

Early laparotomy by 2 months of age with a modified form of the Kasai hepatoportoenterostomy

### **How does a Kasai work?**

Anastomosis of the porta hepatis and the small bowel allows drainage of bile via many microscopic bile ducts in the fibrous structure of the porta hepatis

### **What if the Kasai fails?**

Revise or liver transplantation

## **Choledochal Cyst**

### **What is it?**

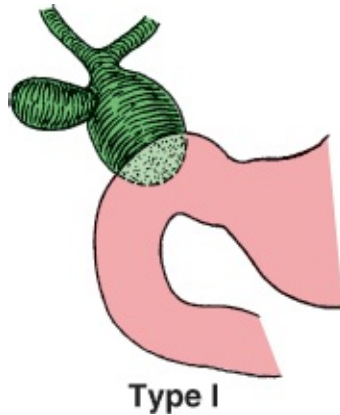
Cystic enlargement of bile ducts; most commonly arises in extrahepatic ducts, but can also arise in intrahepatic ducts

### **What is the usual presentation?**

50% present with intermittent jaundice, RUQ mass, and abdominal pain; may also present with pancreatitis

### **What is the most common anatomic variant?**

Common cyst



### **How is the diagnosis made?**

U/S

### **What is the treatment?**

Operative cholangiogram to clarify pathologic process and delineate the pancreatic duct, followed by complete resection of the cyst and a Roux-en-Y hepatojejunostomy

### **What condition are these patients at increased risk of developing?**

**Cholangiocarcinoma** often arises in the cyst; therefore, treat by complete prophylactic resection of the cyst

## **■ Cholelithiasis**

### **What is it?**

Formation of gallstones

### **What are the common causes in children?**

Etiology differs somewhat from that of adults; the most common cause is cholesterol stones, but the percentage of pigmented stones from hemolytic disorders is increasing

### **What is the treatment?**

Cholecystectomy is recommended for all children with gallstones

## ■ Annular Pancreas

### **What is an annular pancreas?**

Congenital pancreatic abnormality with complete encirclement of the duodenum by the pancreas

### **What are the symptoms?**

Duodenal obstruction

### **What is the treatment?**

Duodenoduodenostomy bypass of obstruction (do not resect the pancreas!)

## TUMORS

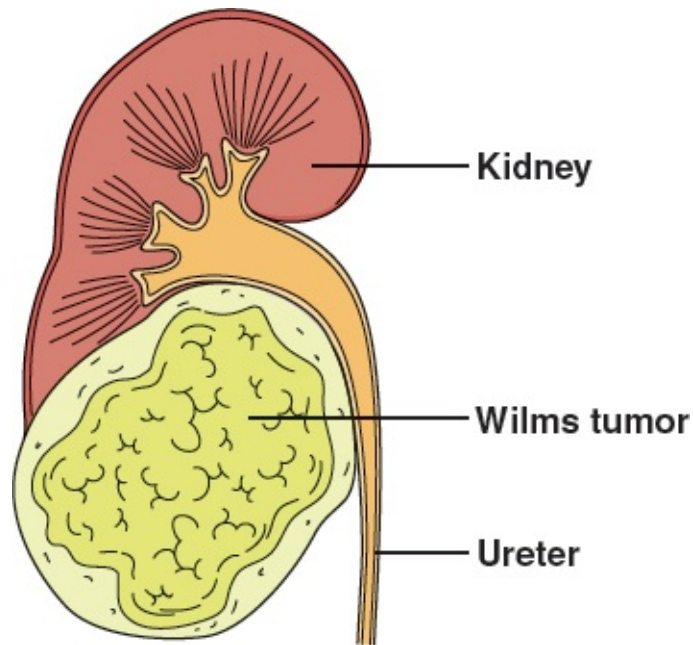
### **What is the differential diagnosis of pediatric abdominal mass?**

Wilms' tumor, neuroblastoma, hernia, intussusception, malrotation with volvulus, mesenteric cyst, duplication cyst, liver tumor (hepatoblastoma/hemangioma), rhabdomyosarcoma, teratoma

## ■ Wilms' Tumor

### **What is it?**

Embryonal tumor of **renal** origin

**What is the incidence?**

Very rare: 500 new cases in the United States per year

**What is the average age at diagnosis?**

Usually 1 to 5 years of age

**What are the symptoms?**

Usually asymptomatic except for abdominal mass; 20% of patients present with minimal blunt trauma to mass

**What is the classic history?**

Found during dressing or bathing

**What are the signs?**

Abdominal mass (most do not cross the midline); hematuria (10%–15%); HTN in 20% of cases, related to compression of juxtaglomerular apparatus; signs of Beckwith–Wiedemann syndrome

**What are the diagnostic radiologic tests?**

Abdominal and chest CT scan

**What are the best indicators of survival?**

Stage and histologic subtype of tumor; 85% of patients have favorable histology

(FH); 15% have unfavorable histology (UH); overall survival for FH is 85% for all stages

### **What is the treatment?**

Radical resection of affected kidney with evaluation for staging, followed by chemotherapy (low stages) and radiation (higher stages)

### **What are the associated abnormalities?**

**Aniridia**, hemihypertrophy, Beckwith–Wiedemann syndrome, neurofibromatosis, horseshoe kidney

### **What is the Beckwith–Wiedemann syndrome?**

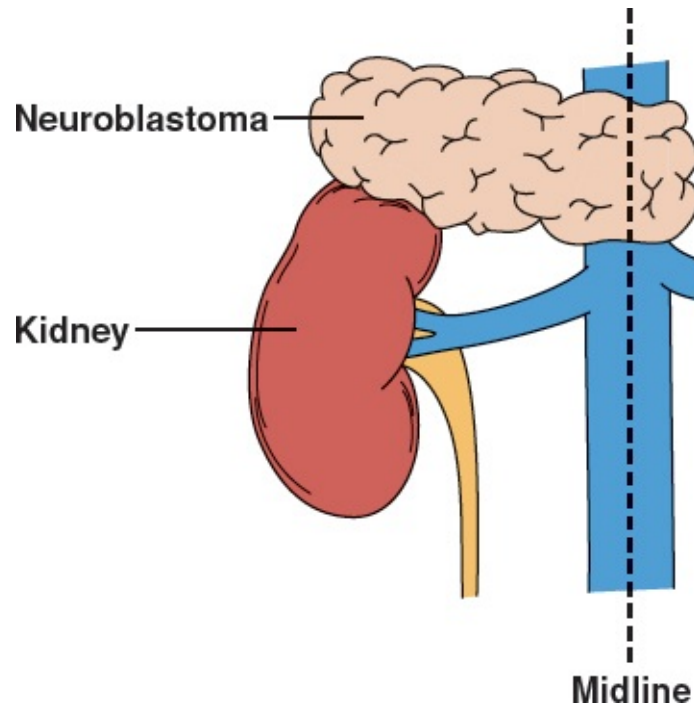
Syndrome of:

1. Umbilical defect
2. Macroglossia (big tongue)
3. Gigantism
4. Visceromegaly (big organs) (Think: **W**ilms' = Beckwith–**W**iedemann)

## **Neuroblastoma**

### **What is it?**

Embryonal tumor of neural crest origin



### **What are the anatomic locations?**

**Adrenal medulla**—50%

Paraaortic abdominal paraspinal ganglia—25%

Posterior mediastinum—20%

Neck—3%

Pelvis—3%

### **With which types of tumor does a patient with Horner's syndrome present?**

Neck, superior mediastinal tumors

### **What is the average age at diagnosis?**

≈50% are diagnosed by 2 years of age

≈90% are diagnosed by 8 years of age

### **What are the signs?**

Asymptomatic abdominal mass (palpable in 50% of cases), respiratory distress (mediastinal tumors), Horner's syndrome (upper chest or neck tumors), proptosis (with orbital metastases), subcutaneous tumor nodules, HTN (20%–35%)

### **Labs?**

24-hour urine to measure VMA, HVA, and metanephrines (elevated in >85%); neuron-specific enolase, N-*myc* oncogene, DNA ploidy

### **What are the diagnostic radiologic tests?**

CT scan, MRI, I-MIBG, somatostatin receptor scan

### **What is the classic abdominal plain x-ray finding?**

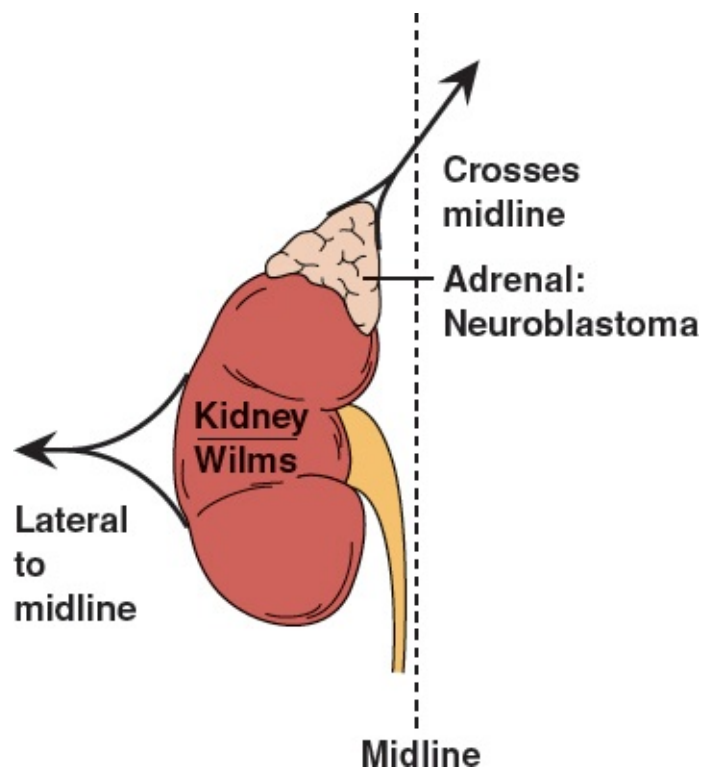
Calcifications (≈50%)

### **How do you assess bone marrow involvement?**

Bone marrow aspirate

### **What is the difference in position of tumors in neuroblastoma versus Wilms' tumors?**

Neuroblastoma may cross the midline, but Wilms' tumors do so only rarely



### **What is the treatment?**

Resection ± chemotherapy ± XRT

### **Which oncogene is associated with neuroblastoma?**

N-*myc* oncogene

Think: N-*myc* = Neuroblastoma

## ■ Rhabdomyosarcoma

### **What is its claim to fame?**

Most common sarcoma in children

### **What is the age distribution?**

Bimodal:

1. 2 to 5 years
2. 15 to 19 years

### **What are the most common sites?**

- . Head and neck (40%)
- . GU tract (20%)
- . Extremities (20%)

### **What are the signs/symptoms?**

Mass

### **How is the diagnosis made?**

Tissue biopsy, CT scan, MRI, bone marrow

### **What is the treatment:**

#### **Resectable?**

Surgical excision, ± chemotherapy and radiation therapy

#### **Unresectable?**

Neoadjuvant chemo/XRT, then surgical excision

## ■ Hepatoblastoma

### **What is it?**

Malignant tumor of the liver (derived from embryonic liver cells)

**What is the average age at diagnosis?**

Presents in the first 3 years of life

**How is the diagnosis made?**

Physical exam—abdominal distention; **RUQ mass that moves with respiration**

Elevated serum  $\alpha$ -fetoprotein and ferritin (can be used as tumor markers)

CT scan of abdomen, which often predicts resectability

**What percentage will have an elevated  $\alpha$ -fetoprotein level?**

≈90%

**What is the treatment?**

Resection by lobectomy or trisegmentectomy is the treatment of choice (plus postoperative chemotherapy); large tumors may require preoperative chemotherapy and **subsequent** hepatic resection

**What is the overall survival rate?**

≈50%

**What is the major difference in age presentation between hepatoma and hepatoblastoma?**

Hepatoblastoma presents at <3 years of age; hepatoma presents at >3 years of age and in adolescents

## PEDIATRIC TRAUMA

**What is the leading cause of death in pediatric patients?**

Trauma

**How are the vast majority of splenic and liver injuries treated in children?**

Observation (i.e., nonoperatively)

**What is a common simulator of peritoneal signs in the blunt pediatric trauma victim?**

Gastric distention (place an NG tube)

**How do you estimate normal systolic blood pressure (SBP) in a child?**

$80 + 2 \times \text{age}$  (e.g., a 5-year-old child should have an SBP of  $\approx 90$ )

**What is the 20–20–10 rule for fluid resuscitation of the unstable pediatric trauma patient?**

First give a **20-cc/kg** LR bolus followed by a second bolus of **20-cc/kg** LR bolus if needed; if the patient is still unstable after the second LR bolus, then administer a **10-cc/kg** bolus of **blood**

**What is the treatment for duodenal hematoma?**

Observation with NGT and TPN

## RAPID FIRE REVIEW

**What are the differences between omphalocele and gastroschisis in terms of the following characteristics:**

**Anomalies**

Common in omphalocele (50%), uncommon in gastroschisis

**Peritoneal/amnion covering (sac)**

Always with omphalocele—never with gastroschisis

**Position of umbilical cord**

On the sac with omphalocele, from skin to the left of the gastroschisis defect

**Thick bowel**

Common with gastroschisis, rare with omphalocele (unless sac ruptures)

**Protrusion of liver**

Common with omphalocele, almost never with gastroschisis

## **Large defect?**

Omphalocele

## **What is the usual age at presentation of the following conditions:**

### **Pyloric stenosis**

3 weeks to 3 months (3 to 3)

### **Intussusception**

4 months to 2 years (>80%)

### **Wilms' tumor**

1 to 5 years

### **Malrotation**

Birth to 1 year (>85%)

### **Neuroblastoma**

≈50% present by 2 years

>80% present by 8 years

### **Hepatoblastoma**

<3 years

### **Appendicitis**

>3 years (but must be considered at *any* age!)

## **What is the correct diagnosis?**

### **Newborn with bilious vomiting**

Malrotation

### **Nonbilious vomiting in an infant <2 months old**

Pyloric stenosis

### **“Currant jelly” stool in young child**

Intussusception

**To pass meconium within the first 24 hours of life**

Hirschsprung's disease

**Inability to pass an NGT in a newborn**

Esophageal atresia

**"Gasless" abdomen in a newborn**

Esophageal atresia

**Newborn with pneumatosis intestinalis**

NEC (necrotizing enterocolitis)

**Name the most likely diagnosis:**

**8-year-old boy with acute scrotal pain; a small "blue dot" is seen through the scrotal skin**

Testicular appendage torsion

**6-year-old child with finger clubbing and history of cyanosis as an infant develops anxiety/increase in respiratory rate and cyanosis with strenuous exercise that is relieved by "squatting down"**

Tetralogy of Fallot

**8-year-old boy with a history of claudication when running, epistaxis, decreased LE pulses, and headaches**

Aortic coarctation

**6-year-old girl with purpuric rash, abdominal pain, hematuria, and joint pain**

Schönlein–Henoch purpura

**17-year-old male presents with thigh pain; x-ray reveals bony mass with a "sunburst" pattern**

Osteosarcoma

**16-year-old female with knee pain; x-ray reveals a periosteum**

**“onion skinning”**

Ewing’s sarcoma

**17-year-old female with history of breast mass, exam reveals a rubbery smooth mass**

Fibroadenoma

**Newborn baby boy with excessive salivation and inability to pass an NGT**

Esophageal atresia

**Name the diagnostic modality:**

**1-day-old baby boy with no urination**

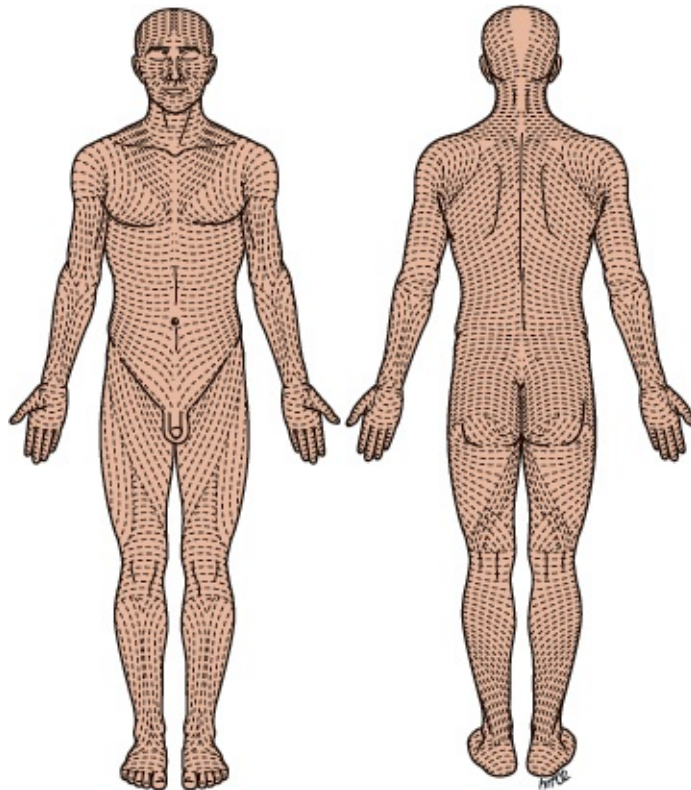
Voiding cystogram looking for posterior urethral valves

# Chapter 67 Plastic Surgery

**Define the following terms:**

## **Langer's lines**

Natural skin lines of minimal tension (e.g., lines across the forehead), incisions perpendicular to Langer's lines result in larger scars than incision parallel to the lines



## WOUND HEALING

**What are the phases of wound healing?**

Think: “In Every Fresh Cut” = IEFC:

1. Inflammation

2. Epithelialization
3. Fibroplasia
4. Contraction

**What are the actions of the following phases:**

**Inflammation?**

Vasoconstriction followed by vasodilation, capillary leak

**Epithelialization?**

Epithelial coverage of wound

**Fibroplasia?**

Fibroblasts and accumulation of collagen, elastin, and reticulin

**Wound contraction?**

Myofibroblasts contract wound

**In which structures does the epithelium grow from superficial burns/wounds?**

Epithelial lining of sweat glands and hair follicles

**In full-thickness burns?**

From wound margins, grows in <1 cm from wound edge because no sweat glands or hair follicles remain; this epithelium has no underlying dermis

## **Wound Contraction**

**Which contracts more: a split-thickness (STSG) or a full-thickness skin graft (FTSG)?**

STSG contracts up to 41% in surface area, whereas an FTSG contracts little, if at all

**What generalized conditions inhibit wound healing?**

Anemia

Malnutrition

Steroids  
Cancer  
Radiation  
Hypoxia  
Sepsis  
Diabetes

**What helps wound healing in patients taking steroids?**

Vitamin A is thought to counteract the deleterious effect of steroids on wound healing

**When does a wound gain more than 90% of its maximal tensile strength?**

After  $\approx$ 6 weeks

**Define the following terms:**

**Hypertrophic scar**

Hypertrophic scar **within** original wound margins

**Keloid**

Proliferative scar tumor progressively enlarging scar **beyond** original wound margins

**Why not clean lacerations with Betadine®?**

Betadine® is harmful to and inhibits normal healthy tissue

## SKIN GRAFTS

**What is an STSG?**

Split thickness: includes the epidermis and a variable amount of the dermis

**How thick is it?**

10/1000 to 18/1000 of an inch

**What is an FTSG?**

Full thickness: includes the entire epidermis and dermis

### **What are the prerequisites for a skin graft to take?**

Bed must be vascularized; a graft to a bone or tendon will not take

Bacteria must be  $<100,000$

Shearing motion and fluid beneath the graft must be minimized

### **What is a better bed for a skin graft: fascia or fat?**

Fascia (much better blood supply)

### **How do you increase surface area of an STSG?**

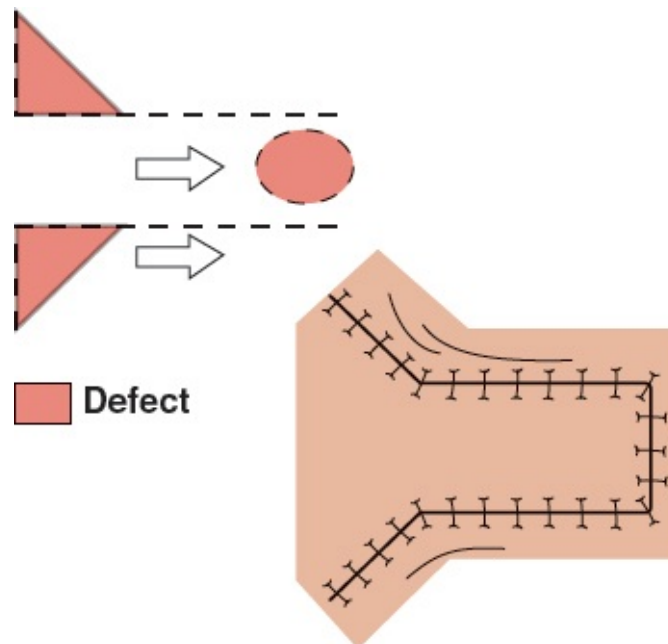
Mesh it (also allows for blood/serum to be removed from underneath the graft)

### **How does an STSG get nutrition for the first 24 hours?**

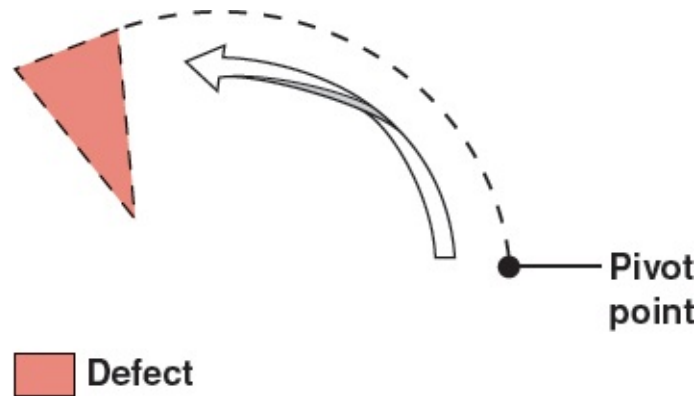
Imbibition

## **FLAPS**

### **What is a simple advancement flap?**



### **What is a rotational flap?**



### What is a “free flap”?

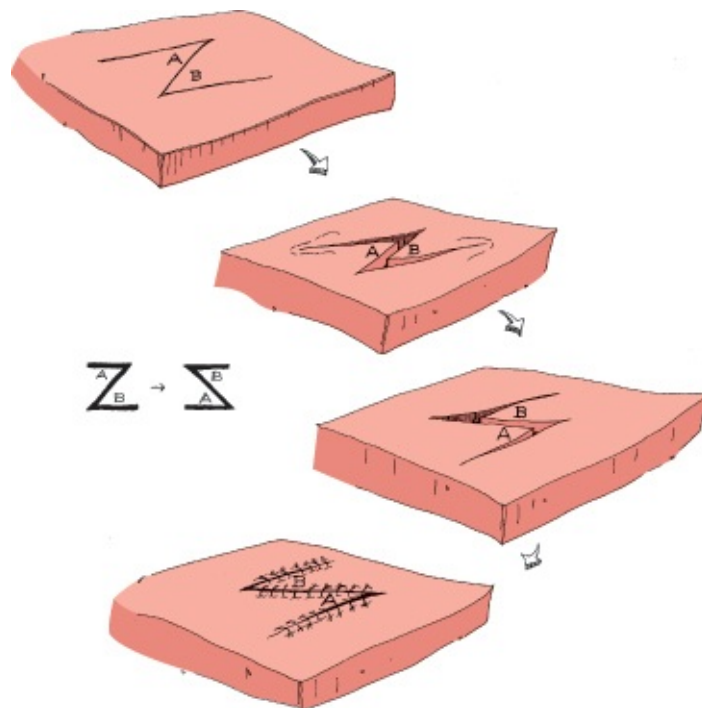
Flap separated from all vascular supply that requires microvascular anastomosis (microscope)

### What is a TRAM flap?

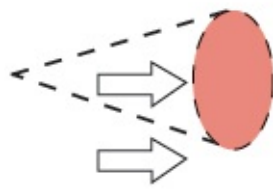
Transverse Rectus Abdominis Myocutaneous flap (see [page 287](#))

### What is a “Z-plasty”?

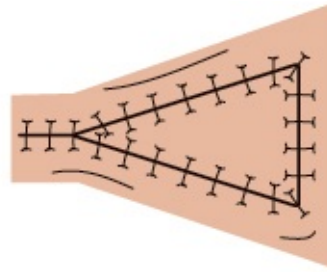
Reorients and lengthens a scar



### What is a “V-Y advancement flap”?



 Defect



# Chapter 68 Hand Surgery

## **Who operates on hands?**

Plastic surgeons **and** orthopedic surgeons

## **What are the bones of the hand?**

Phalanges (fingers)

Metacarpal bones

Carpal bones

## **What is the distal finger joint?**

Distal InterPhalangeal (**DIP**) joint

## **What is the middle finger joint?**

Proximal InterPhalangeal (**PIP**) joint

## **What is the proximal finger joint?**

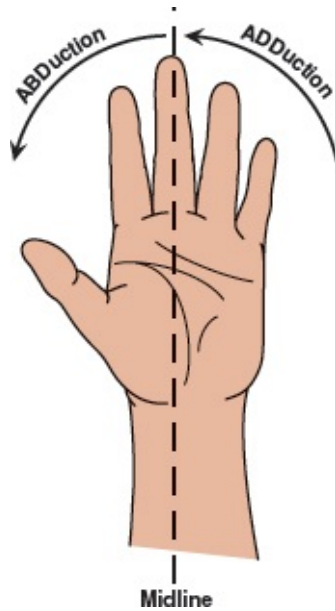
Metacarpal Phalangeal (**MP**) joint

## **What are the “intrinsic” hand muscles?**

Lumbricals, interosseous muscle

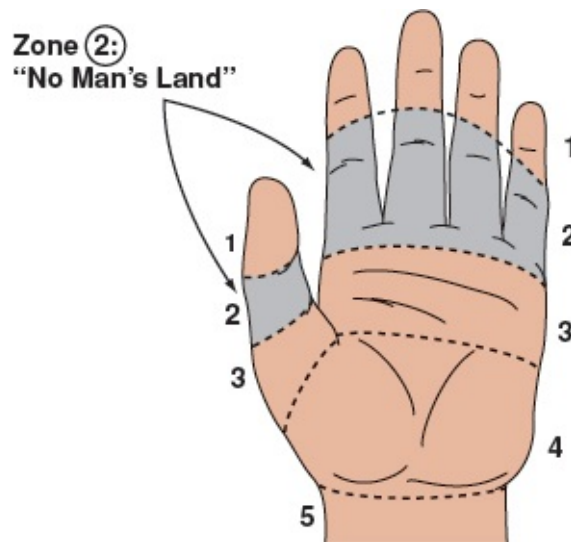
## **What is ADDuction and ABDuction of the fingers?**

**ADD**uction is to midline and **ABD**uction is separation from midline



### Where is “no man’s land”?

Zone extending from the distal palmar crease to just beyond the PIP joint (zone 2)

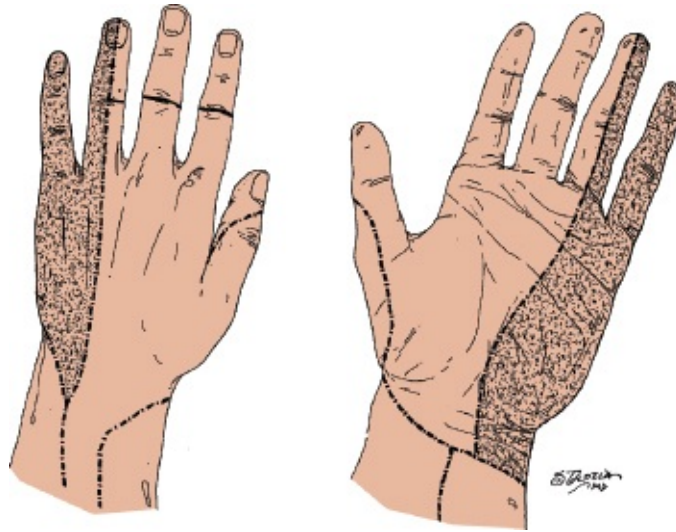


### What is the significance of the “no man’s land”?

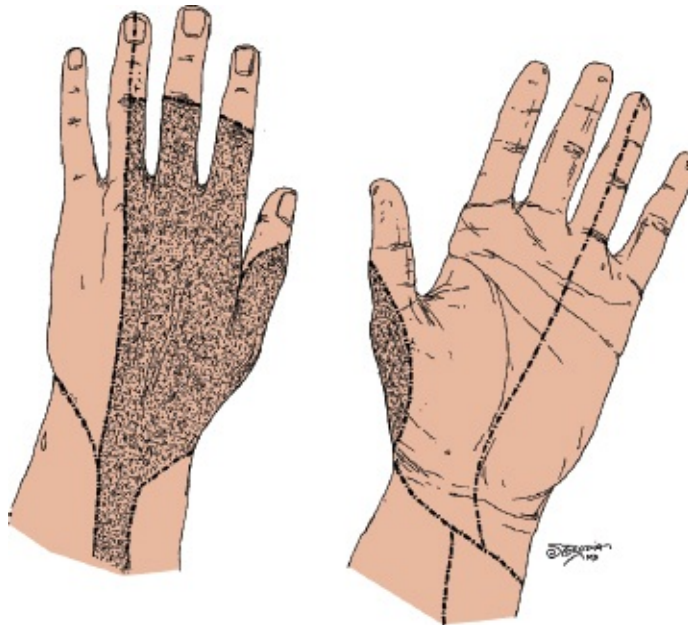
Flexor tendon injuries here have a poor prognosis

## SENSORY SUPPLY TO THE HAND

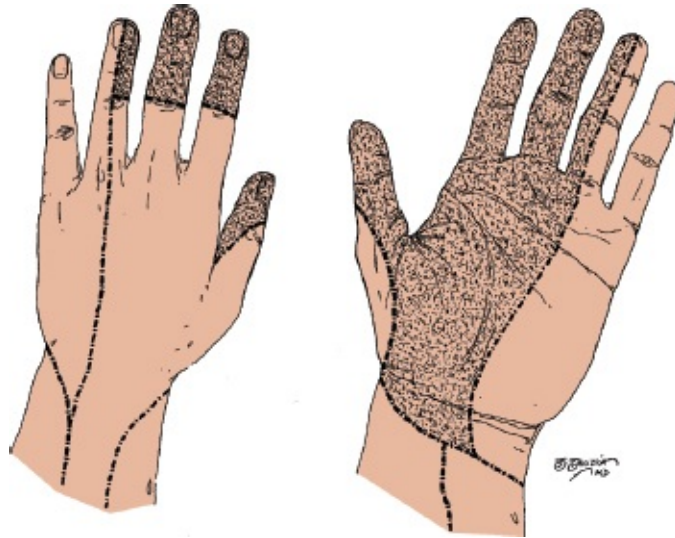
What is the ulnar nerve distribution?



**What is the radial nerve distribution?**



**What is the median nerve distribution?**



### **How can the radial nerve motor function be tested?**

- . Wrist and MCP extension
- . Abduction and extension of thumb

### **How can the ulnar nerve motor function be tested?**

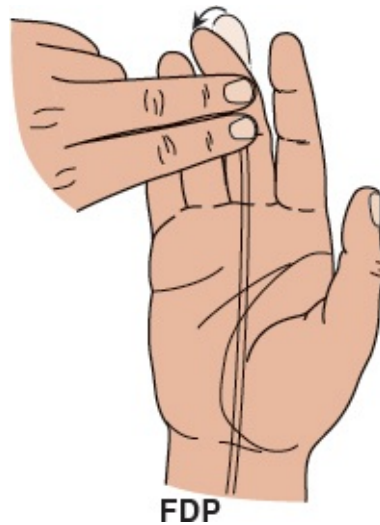
- . Spread fingers apart against resistance
- . Check ability to cross index and middle fingers

### **How can the median nerve function be tested?**

- . Touch the thumb to the pinky (distal median nerve)
- . Squeeze examiner's finger (proximal median nerve)

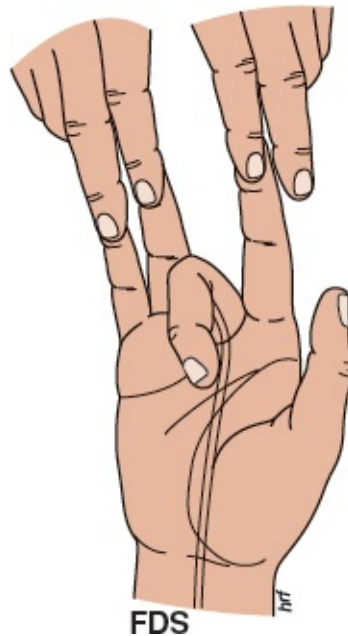### **How can the flexor digitorum *profundus* (FDP) apparatus be tested?**

Check isolated flexion of the finger DIP joint



**How can the flexor digitorum *superficialis* (FDS) apparatus be tested?**

Check isolated flexion of the finger at the MP joint



**Where do the digital arteries run?**

On medial and lateral sides of the digit

**What hand laceration should be left unsutured?**

Lacerations from human bites or animal bites

**Should a clamp ever be used to stop a laceration bleeder?**

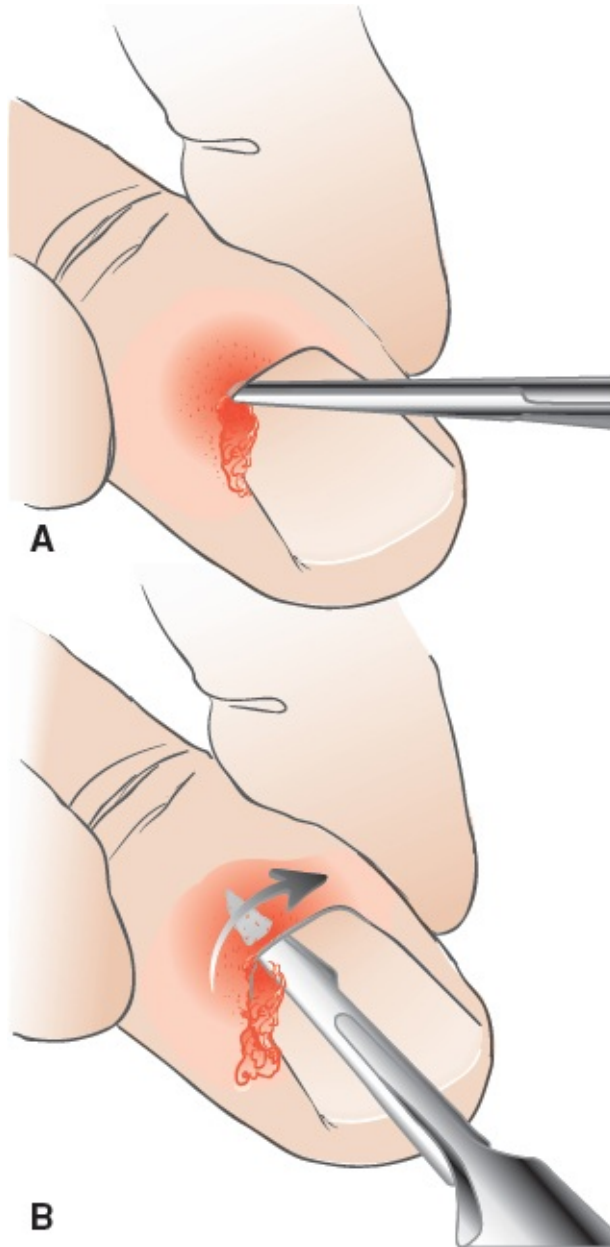
**No;** use pressure and then tourniquet for definitive repair if bleeding does not cease because **nerves run with blood vessels!**

### **What is a felon?**

Infection in the **tip** of the finger pad (Think: **felon** = **f**ingerprints = **i**nfection in **p**ad); treat by incision and drainage

### **What is a paronychia?**

Infection on the **side** of the fingernail (nail fold); treat by incision and drainage



**What is tenosynovitis?**

Tendon sheath infection

**What are Kanavel's signs?**

Four signs of tenosynovitis:

1. Affected finger held in flexion
2. Pain over volar aspect of affected finger tendon sheath upon palpation
3. Swelling of affected finger (fusiform)
4. Pain on passive extension of affected finger

**Most common bacteria in tenosynovitis and paronychia?**

*Staphylococcus aureus*

**How are human and animal hand bites treated?**

Débridement/irrigation/administration of antibiotics; **leave wound open**

**What unique bacteria are found in human bites?**

*Eikenella corrodens*

**What unique bacteria are found in dog and cat bites?**

*Pasteurella multocida*

**What is the most common hand/wrist tumor?**

Ganglion cyst

**What is an extremely painful type of subungual tumor?**

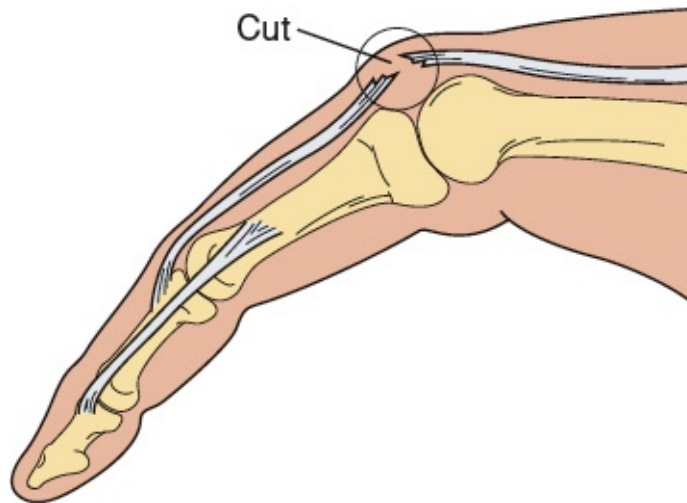
Glomus tumor (subungual: under the nail)

**What is a "boxer's fracture"?**

Fracture of the fourth or fifth metacarpal

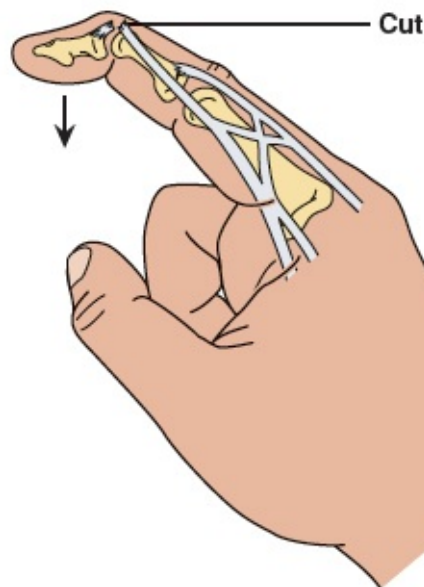
**What is a "drop finger" injury?**

Laceration of extensor tendon over the MP joint



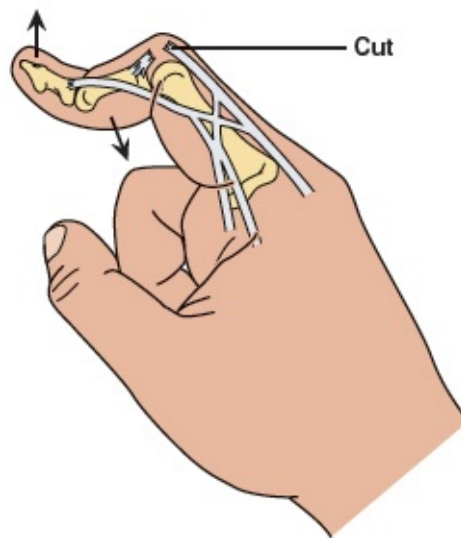
**What is the classic deformity resulting from laceration of the extensor tendon over the DIP joint?**

Mallet finger

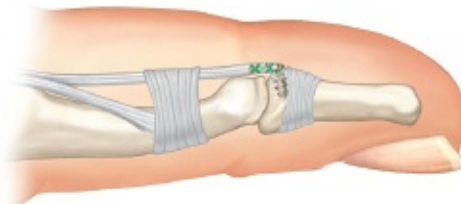
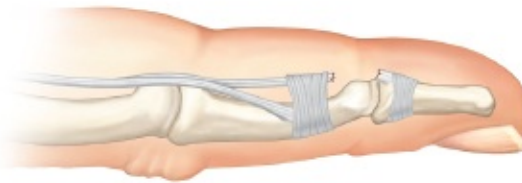
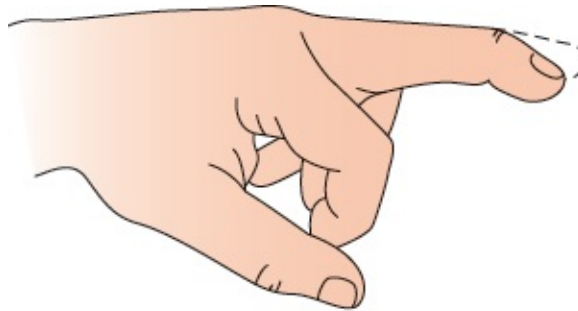


**What is the classic deformity resulting from laceration of the extensor tendon over the PIP joint?**

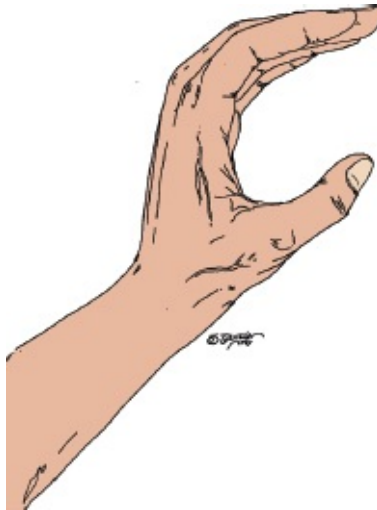
### Boutonniere deformity



### What is a “Jersey finger”?



### What is the “safe position” of hand splinting?

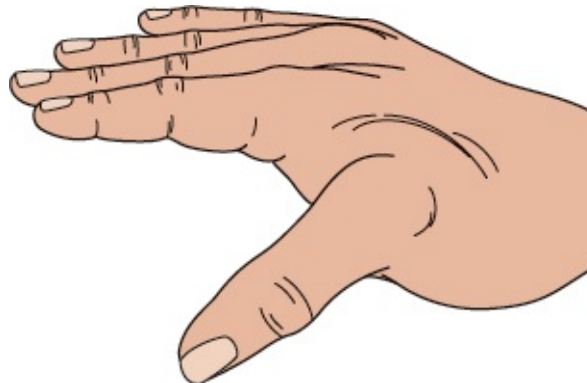


**What is Dupuytren's contracture?**

Fibrosis of palmar fascia, causing contracture of and inability to extend digits

**What is "gamekeeper's thumb"?**

Injury to the ulnar collateral ligament of the thumb



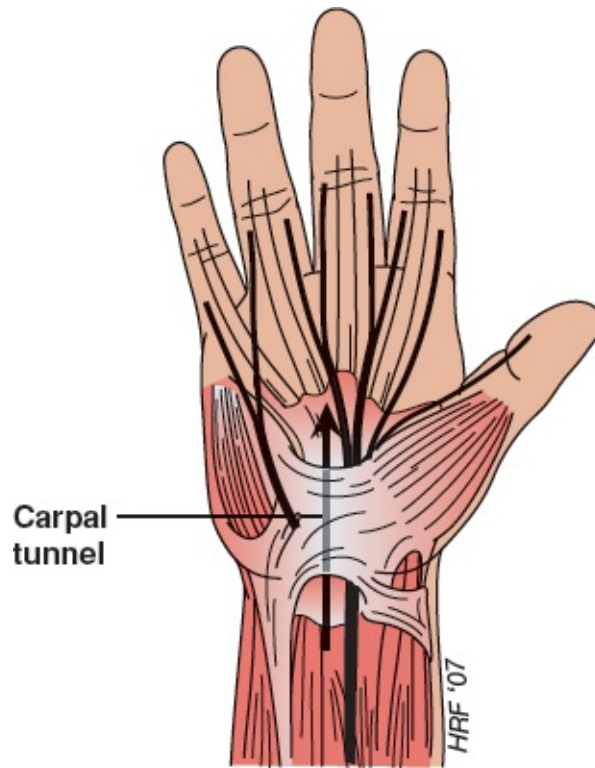
**How should a subungual hematoma be treated?**

Release pressure by burning a hole in the nail (use handheld disposable battery-operated coagulation probe)

## CARPAL TUNNEL SYNDROME

**What is it?**

Compression of the median nerve in the carpal tunnel



**What is the most common cause?**

Synovitis

**What are other causes?**

**“MEDIAN TRAPS”:**

Median artery (persistent)

Edema of pregnancy

Diabetes

Idiopathic

Acromegaly

Neoplasm (e.g., ganglioneuroma)

Thyroid (myxedema)

Rheumatoid arthritis

Amyloid

Pneumatic drill usage

SLE

**What are the symptoms?**

Pain and numbness in the median nerve distribution

**What are the signs?**

Tinel's sign (symptoms with percussion over median nerve), Phalen's test (symptoms with flexion of wrists), thenar atrophy, Wartenberg's sign

**What is Wartenberg's sign?**

With hand resting on a surface, the fifth digit ("pinky") rests in ABduction compared to the other four fingers

**What is the workup?**

EMG, nerve conduction study

**What is initial treatment?**

Nonoperative, rest, wrist splint, NSAIDs

**What are indications for surgery?**

Refractory symptoms, thenar atrophy, thenar weakness

**What surgery is performed?**

Release transverse carpal ligament

**RAPID FIRE REVIEW****Name the most likely diagnosis:**

**34-year-old male carpenter develops a decrease in coordination in his hammer hand (right hand); he wakes in the middle of the night with right hand pain and "pins and needles" in the right thumb/index/middle fingers**

Carpel tunnel syndrome

# Chapter 69 Otolaryngology: Head and Neck Surgery

## EAR

### ■ Otitis Externa (Swimmer's Ear)

#### **What is it?**

Generalized infection involving the external ear canal and often the tympanic membrane

#### **What is the usual cause?**

Prolonged water exposure and damaged squamous epithelium of the ear canal (e.g., swimming, hearing aid use)

#### **What are the typical pathogens?**

Most frequently *Pseudomonas*, may be *Proteus*, *Staphylococcus*, occasionally *Escherichia coli*, fungi (*Aspergillus*, *Candida*), or virus (herpes zoster or herpes simplex)

#### **What are the signs/symptoms?**

Ear pain (otalgia); swelling of external ear, ear canal, or both; erythema; pain on manipulation of the auricle; debris in canal; otorrhea

#### **What is the treatment?**

Keep the ear dry; mild infections respond to cleaning and dilute acetic acid drops; most infections require complete removal of all debris and topical antibiotics with or without hydrocortisone (anti-inflammatory)

## ■ Malignant Otitis Externa (MOE)

### What is it?

Fulminant **bacterial** otitis externa

### Is it malignant cancer?

NO!

### Who is affected?

Most common scenario: elderly patient with poorly controlled diabetes (other forms of immunosuppression do not appear to predispose patients to MOE)

### What are the causative organisms?

Usually *Pseudomonas aeruginosa*

### What is the classic feature?

Nub of granulation tissue on the floor of the external ear canal at the bony–cartilaginous junction

### What are the other signs/symptoms?

Severe ear pain, excessive purulent discharge, and usually **exposed bone**

### What are the diagnostic tests?

- . CT scan: shows erosion of bone, inflammation
- . Technetium-99 scan: temporal bone inflammatory process
- . Gallium-tagged white blood cell scan: to follow and document resolution

### What are the complications?

Invasion of surrounding structures to produce a cellulitis, osteomyelitis of temporal bone, mastoiditis; later, a facial nerve palsy, meningitis, or brain abscess

### What is the treatment?

Control of diabetes, meticulous local care with extensive débridement, hospitalization and IV antibiotics (anti-*Pseudomonas*: usually an aminoglycoside plus a penicillin)

## ■ Tumors of the External Ear

### **What are the most common types?**

Squamous cell most common; occasionally, basal cell carcinoma or melanoma

### **From what location do they usually arise?**

Auricle, but occasionally from the external canal

### **What is the associated risk factor?**

Excessive sun exposure

### **What is the treatment of the following conditions:**

#### **Cancers of the auricle?**

Usually wedge excision

#### **Extension to the canal?**

May require excision of the external ear canal or partial temporal bone excision

#### **Middle ear involvement?**

Best treated by en bloc temporal bone resection and lymph node dissection

## ■ Tympanic Membrane (TM) Perforation

### **What is the etiology?**

Usually the result of trauma (direct or indirect) or secondary to middle ear infection; often occurs secondary to slap to the side of the head (compression injury), explosions

### **What are the symptoms?**

Pain, bleeding from the ear, conductive hearing loss, tinnitus

### **What are the signs?**

Clot in the meatus, visible tear in the TM

**What is the treatment?**

Keep dry; use topical antibiotics if there is evidence of infection or contamination

**What is the prognosis?**

Most (90%) heal spontaneously, although larger perforations may require surgery (e.g., fat plug, temporalis fascia, or tragal cartilage tympanoplasty)

## ■ Cholesteatoma

**What is it?**

Epidermal inclusion cyst of the middle ear or mastoid, containing desquamated keratin debris; may be acquired or congenital

**What are the causes?**

Negative middle ear pressure from eustachian tube dysfunction (primary acquired) or direct growth of epithelium through a TM perforation (secondary acquired)

**What other condition is it often associated with?**

Chronic middle ear infection

**What is the usual history?**

Chronic ear infection with chronic, malodorous drainage

**What is the appearance?**

Grayish white, shiny keratinous mass behind or involving the TM; often described as a “pearly” lesion

**What is the treatment?**

Surgery (tympanoplasty/mastoidectomy) aimed at eradication of disease and reconstruction of the ossicular chain

## ■ Bullous Myringitis

**What is it?**

Vesicular infection of the TM and adjacent deep canal

**What are the causative agents?**

Unknown; viral should be suspected because of frequent association with viral URI (in some instances, *Mycoplasma pneumoniae* has been cultured)

**What are the symptoms?**

Acute, severe ear pain; low-grade fever; and bloody drainage

**What are the findings on otoscopic examination?**

Large, reddish blebs on the TM, wall of the meatus, or both

**Is hearing affected?**

Rarely; occasional reversible sensorineural loss

**What is the treatment?**

Oral antibiotics (erythromycin if *Mycoplasma* is suspected); topical analgesics may be used, with resolution of symptoms usually occurring in 36 hours

## ■ Acute Suppurative Otitis Media (OM)

**What is it?**

Bacterial infection of the middle ear, often following a viral URI; may be associated with a middle ear effusion

**What is the cause?**

Dysfunction of the eustachian tube that allows bacterial entry from nasopharynx; often associated with an occluded eustachian tube, although it is uncertain whether this is a cause or a result of the infection

**What are the predisposing factors?**

Young age, male gender, bottle feeding, crowded living conditions (e.g., day care), cleft palate, Down's syndrome, cystic fibrosis

**What is the etiology?**

- . *Streptococcus pneumoniae* (33% of cases)
- . *Haemophilus influenzae*
- . *Moraxella catarrhalis*
- . *Staphylococcus*
- .  $\beta$ -Hemolytic strep
- . *Pseudomonas aeruginosa*
- . Viral/no culture

### **What is the etiology in infants <6 months?**

- . *Staphylococcus aureus*
- . *E. coli*
- . *Klebsiella*

### **What are the symptoms?**

Otalgia, fever, decreased hearing, infant pulls on ear, increased irritability; as many as 25% of patients are asymptomatic

### **What are the signs?**

Early, redness of the TM; later, TM bulging with the loss of the normal landmarks; finally, impaired TM mobility on pneumatic otoscopy

### **If pain disappears instantly, what may have happened?**

TM perforation!

### **What are the complications?**

TM perforation, acute mastoiditis, meningitis, brain abscess, extradural abscess, labyrinthitis; if recurrent or chronic, OM may have adverse effects on speech and cognitive development as a result of decreased hearing

### **What is the treatment?**

10-day course of antibiotics; amoxicillin is the first-line agent; if the patient is allergic to PCN, trimethoprim/sulfamethoxazole or erythromycin should be administered

### **What is the usual course?**

Symptoms usually resolve in 24 to 36 hours

### **What are the indications for myringotomy and PE tube placement?**

- . Persistent middle ear effusion over 3 months
- . Debilitated or immunocompromised patient
- . >3 episodes over 6 months (especially if bilateral)

### **What is a PE tube?**

Pneumatic Equalization tube (tube placed through tympanic membrane)

### **What is a Bezold's abscess?**

Abscess behind the superior attachment of the sternocleidomastoid muscle resulting from extension of a mastoid infection

### **What are causes of chronic otitis media?**

Mixed, *S. aureus*, *P. aeruginosa*

### **What are the signs/symptoms of chronic otitis media?**

Otorrhea and hearing loss

## **Otosclerosis**

### **What is it?**

Genetic disease characterized by abnormal spongy and sclerotic bone formation in the temporal bone around the footplate of the stapes, thus preventing its normal movement

### **What is the inheritance pattern?**

Autosomal dominant with incomplete one-third penetrance

### **What are the symptoms?**

Painless, progressive hearing loss (may be unilateral or bilateral), tinnitus

### **What is the usual age of onset?**

Second through fourth decade

### **How is the diagnosis made?**

Normal TM with conductive hearing loss and no middle-ear effusion (though may be mixed or even sensorineural if bone of cochlea is affected)

### **What is Schwartze's sign?**

Erythema around the stapes from hypervascularity of new bone formation

### **What is the treatment?**

Frequently surgical (stapedectomy with placement of prosthesis), hearing aids, or observation; sodium fluoride may be used if a sensorineural component is present or for preoperative stabilization

## **MISCELLANEOUS**

### **■ Facial Nerve Paralysis**

#### **What are the causes?**

Bell's palsy

Trauma

Cholesteatoma

Tumor (carcinoma, glomus jugulare)

Herpes zoster inflammation of geniculate ganglion (Ramsay–Hunt syndrome)

Peripheral lesions are usually parotid gland tumors

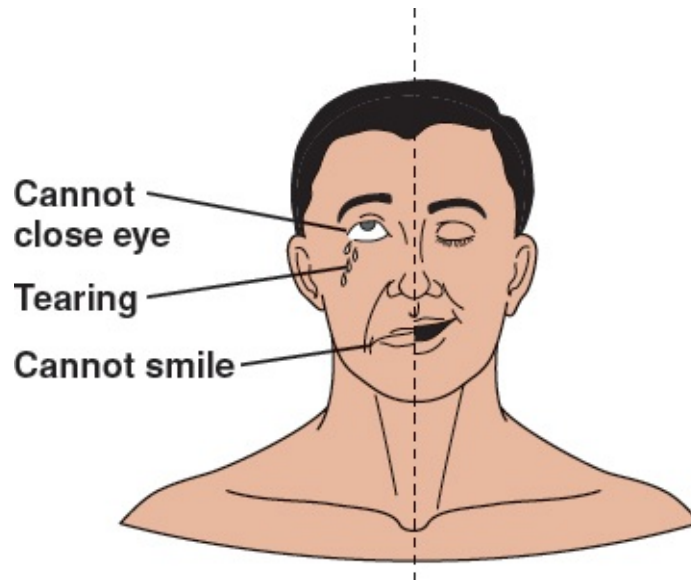
#### **What is the most common cause of bilateral facial nerve palsy?**

Lyme disease (*Borrelia burgdorferi*)

### **■ Bell's Palsy**

#### **What is it?**

Sudden onset, unilateral facial weakness or paralysis in absence of CNS, ear, or cerebellopontine angle disease (i.e., no identifiable cause)



### **What is the clinical course?**

Acute onset, with greatest muscle weakness reached within 3 weeks

### **What is the incidence?**

Most common cause of **unilateral** facial weakness/paralysis

### **What is the pathogenesis?**

Unknown; most widely accepted hypothesis is viral etiology (herpes virus); ischemic and immunologic factors are also implicated

### **What is the common preceding event?**

URI

### **What are the signs/symptoms?**

Pathology is related to swelling of the facial nerve; may present with total facial paralysis, altered lacrimation, increased tearing on affected side, change in taste if region above chorda tympani is affected, dry mouth, and hyperacusis

### **What is the treatment?**

Usually none is required, as most cases resolve spontaneously in 1 month;  
protect eye with drops and tape closed as needed; most otolaryngologists  
advocate steroids and acyclovir

Surgical decompression of CN VII is indicated if paralysis progresses or tests  
indicate deterioration

### **What is the prognosis?**

Overall, 90% of patients recover completely; if paralysis is incomplete, 95% to 100% will recover without sequelae

## **■ Ménière's Disease**

### **What is it?**

Disorder of the membranous labyrinth, causing fluctuating sensorineural hearing loss, episodic vertigo, nystagmus, tinnitus, and aural fullness, N/V

### **What is the classic triad?**

**“H, T, V”:**

1. **H**earing loss
2. **T**innitus
3. **V**ertigo

### **What is the medical treatment?**

Salt restriction, diuretics (thiazides), antinausea agents; occasionally diazepam is added; 80% of patients respond to medical management, antihistamines

### **What are the indications for surgery?**

Surgery is offered to those who fail medical treatment or who have incapacitating vertigo (60% to 80% effective)

## **■ Glomus Tumors**

### **What are they?**

Benign, slow-growing tumors arising in glomus bodies found in the adventitial layer of blood vessels; often associated with cranial nerves IX and X in the middle ear

### **What is the usual location?**

Middle ear, jugular bulb, course of CN IX to XII

**How common are they?**

Most common benign tumor of the temporal bone

**What is the treatment?**

Surgical resection, radiation therapy for poor operative candidates or for recurrences

## NOSE AND PARANASAL SINUSES

### ■ Epistaxis

**What is it?**

Bleeding from the nose

**What are the predisposing factors?**

Trauma, anticoagulants, “nose picking,” sinus infection, allergic or atrophic rhinitis, blood dyscrasias, tumor, environmental extremes (hot, dry climates; winters)

**What is the usual cause?**

Rupture of superficial mucosal blood vessels (Kiesselbach’s plexus if anterior, sphenopalatine artery if posterior)

**What is the most common type?**

Anterior (90%); usually the result of trauma

**Which type is more serious?**

Posterior; usually occurs in the elderly or is associated with a systemic disorder (hypertension, tumor, arteriosclerosis)

**What is the treatment?**

Direct pressure; if this fails, proceed to nasal packing

**What is the treatment of last resort?**

Ligation or embolization of the sphenopalatine artery (posterior) or ethmoidal artery (anterior)

## ■ Acute Sinusitis

### **What is the typical history?**

Previously healthy patient with unrelenting progression of a viral URI or allergic rhinitis beyond the normal 5- to 7-day course

### **What are the symptoms?**

Periorbital pressure/pain, nasal obstruction, nasal/postnasal mucopurulent discharge, fatigue, fever, headache

### **What are the signs?**

Tenderness over affected sinuses, pus in the nasal cavity; may also see reason for obstruction (septal deviation, spur, tight osteomeatal complex); transillumination is unreliable

### **What is the pathophysiology?**

Thought to be secondary to decreased ciliary action of the sinus mucosa and edema causing obstruction of the sinus ostia, lowering intrasinus oxygen tension and predisposing patients to bacterial infection

### **What are the causative organisms?**

Up to 50% of patients have negative cultures and cause is presumably (initially) viral; pneumococcus, *S. aureus*, group A streptococci, and *H. influenzae* are the most common bacteria cultured

### **What is the treatment?**

14-day course of antibiotics (penicillin G, amoxicillin, Ceclor<sup>®</sup>, and Augmentin<sup>®</sup> are commonly used), topical and systemic decongestants, and saline nasal irrigation

### **What is the treatment for fungal sinusitis?**

Fungal sinusitis is commonly caused by *Mucor* and seen in immunosuppressed patients; treatment is IV antifungals (e.g., amphotericin or caspofungin) and surgical débridement of all necrotic tissue

## ■ Chronic Sinusitis

### **What is it?**

Infection of nasal sinuses lasting >4 weeks, or pattern of recurrent acute sinusitis punctuated by brief asymptomatic periods

### **What is the pathology?**

Permanent mucosal changes secondary to inadequately treated acute sinusitis, consisting of mucosal fibrosis, polypoid growth, and inadequate ciliary action, hyperostosis (increased bone density on CT scan)

### **What are the symptoms?**

Chronic nasal obstruction, postnasal drip, mucopurulent rhinorrhea, low-grade facial and periorbital pressure/pain

### **What are the causative organisms?**

Usually anaerobes (such as *Bacteroides*, *Veillonella*, *Rhinobacterium*); also *H. influenzae*, *Streptococcus viridans*, *S. aureus*, *Staphylococcus epidermidis*

### **What is the treatment?**

Medical management with decongestants, mucolytics, topical steroids, and antibiotics; if this approach fails, proceed to endoscopic or external surgical intervention

### **What is FESS?**

Functional Endoscopic Sinus Surgery

### **What are the complications of sinusitis?**

Orbital cellulitis (if ethmoid sinusitis), meningitis, epidural or brain abscess (frontal sinus), cavernous sinus thrombosis (ethmoid or sphenoid), osteomyelitis (a.k.a. “Pott’s puffy tumor” if frontal)

## ■ Cancer of the Nasal Cavity and Paranasal Sinuses

**What are the usual locations?**

Maxillary sinus (66%)

Nasal cavity

Ethmoid sinus

Rarely in frontal or sphenoid sinuses

**What are the associated cell types?**

Squamous cell (80%)

Adenocellular (15%)

Uncommon: sarcoma, melanoma

**What rare tumor arises from olfactory epithelium?**

Esthesioneuroblastoma; usually arises high in the nose (cribriform plate) and is locally invasive

**What are the signs/symptoms?**

Early—nasal obstruction, blood-tinged mucus, epistaxis

Late—localized pain, cranial nerve deficits, facial/palate asymmetry, loose teeth

**How is the diagnosis made?**

CT scan can adequately identify extent of the disease and local invasion; MRI is often also used to evaluate soft-tissue disease

**What is the treatment?**

Surgery ±XRT

**What is the prognosis?**

5-year survival for T1 or T2 lesions approaches 70%

## ■ Juvenile Nasopharyngeal Angiofibroma

**What is it?**

Most commonly encountered vascular mass in the nasal cavity; locally aggressive but nonmetastasizing

**What is the usual history?**

Adolescent boys who present with nasal obstruction, recurrent massive epistaxis, possibly anosmia

**What is the usual location?**

Site of origin is the roof of the nasal cavity at the superior margin of sphenopalatine foramen

**Into what can the mass transform?**

Fibrosarcoma (rare cases reported)

**How is the diagnosis made?**

Carotid arteriography, CT scan; biopsy is contraindicated secondary to risk of uncontrollable hemorrhage

**What are indications for biopsy?**

**None!**

**What is the treatment?**

Surgery via lateral rhinotomy or sublabial maxillotomy with bleeding controlled by internal maxillary artery ligation or preoperative embolization, in the setting of hypotensive anesthesia; preoperative irradiation has also been used to shrink the tumor

## ORAL CAVITY AND PHARYNX

### ■ Pharyngotonsillitis

**What is the common site of referred throat pain?**

EAR

**What is it?**

Acute or chronic infection of the nasopharynx or oropharynx and/or Waldeyer's ring of lymphoid tissue (consisting of palatine, lingual, and pharyngeal tonsils and the adenoids)

**What is the etiology?**

Acute attacks can be viral (adenovirus, enterovirus, coxsackievirus, Epstein-Barr virus in infectious mononucleosis) or bacterial (group A  $\beta$ -hemolytic streptococci are the leading bacterial agent); chronic tonsillitis often with mixed population, including streptococci, staphylococci, and *M. catarrhalis*

### **What are the symptoms?**

Acute—Sore throat, fever, local lymphadenopathy, chills, headache, malaise  
Chronic—Noisy mouth breathing, speech and swallowing difficulties, apnea, halitosis

### **What are the signs?**

Viral—Injected tonsils and pharyngeal mucosa; exudate may occur, but less often than with bacterial tonsillitis  
Bacterial—Swollen, inflamed tonsils with white-yellow exudate in crypts and on surface; cervical adenopathy

### **How is the diagnosis made?**

CBC, throat culture, Monospot test

### **What are the possible complications?**

Peritonsillar abscess (quinsy), retropharyngeal abscess (causing airway compromise), rheumatic fever, poststreptococcal glomerulonephritis (with  $\beta$ -hemolytic streptococci)

### **What is the treatment?**

Viral—symptomatic → acetaminophen, warm saline gargles, anesthetic throat spray  
Bacterial—10 days PCN (erythromycin if PCN-allergic)

### **What are the indications for tonsillectomy?**

Sleep apnea/cor pulmonale secondary to airway obstruction, suspicion of malignancy, hypertrophy causing malocclusion, peritonsillar abscess, recurrent acute or chronic tonsillitis

### **What are the possible complications?**

Acute or delayed hemorrhage

## ■ Peritonsillar Abscess

### **What is the clinical setting?**

Inadequately treated recurrent acute or chronic tonsillitis

### **What is the associated microbiology?**

Mixed aerobes and anaerobes (which may be PCN-resistant)

### **What is the site of formation?**

Begins at the superior pole of the tonsil

### **What are the symptoms?**

Severe throat pain, drooling dysphagia, odynophagia, trismus, cervical adenopathy, fever, chills, malaise

### **What is the classic description of voice?**

“Hot-potato” voice

### **What are the signs?**

Bulging, erythematous, edematous tonsillar pillar; swelling of uvula and displacement to contralateral side

### **What is the treatment?**

IV antibiotics and surgical evacuation by incision and drainage; most experts recommend tonsillectomy after resolution of inflammatory changes

## ■ Ludwig Angina

### **What is it?**

Infection and inflammation of the floor of the mouth (sublingual and submandibular)

### **What is the source?**

Dental infection

**What is the treatment?**

Antibiotics, emergency airway, I & D

## Cancer of the Oral Cavity

**What is the usual cell type?**

Squamous cell (>90% of cases)

**What are the most common sites?**

**Lip**, tongue, floor of mouth, gingiva, cheek, and palate

**What is the etiology?**

Linked to smoking, alcohol, and smokeless tobacco products (alcohol and tobacco together greatly increase the risk), HPV (on the rise)

**What is the frequency of the following conditions:****Regional metastasis?**

≈30%

**Second primary?**

≈25%

**Nodal metastasis?**

Depends on size of tumor and ranges from 10% to 60%, usually to jugular and **jugulodigastric nodes, submandibular nodes**

**Distant metastasis?**

Infrequent

**How is the diagnosis made?**

Full history and physical examination, dental assessment, Panorax or bone scan if mandible is thought to be involved, CT scan/MRI for extent of tumor and nodal disease, FNA (often U/S guided)

**What is the treatment?**

Radiation, surgery, or both for small lesions; localized lesions can usually be treated surgically; larger lesions require combination therapy, possible mandibulectomy and neck dissection

### **What is the prognosis?**

Depends on stage, site, and etiology:

Most common cause of death in successfully treated head and neck cancer is development of a second primary (occurs in 20%–40% of cases)

HPV+ tumors have better prognosis

Tongue: 20% to 70% survival

Floor of mouth: 30% to 80% survival

## **Salivary Gland Tumors**

### **What is the frequency of gland involvement?**

Parotid gland (80%)

Submandibular gland (15%)

Minor salivary glands (5%)

### **What is the potential for malignancy?**

Greatest in **minor salivary gland** tumors (80% are malignant) and least in parotid gland tumors (80% are benign); **the smaller the gland, the greater the likelihood of malignancy**

### **How do benign and malignant tumors differ in terms of history and physical examination?**

Benign—mobile, nontender, no node involvement or facial weakness

Malignant—painful, fixed mass with evidence of local metastasis and facial paresis/paralysis

### **What is the diagnostic procedure?**

FNA; **never** perform excisional biopsy of a parotid mass; superficial parotidectomy is the procedure of choice for benign lesions of the lateral lobe

### **What is the treatment?**

Involves adequate surgical resection, sparing facial nerve if possible, neck

dissection for node-positive necks

### **What are the indications for postop XRT?**

Postoperative radiation therapy if high-grade cancer, recurrent cancer, residual disease, invasion of adjacent structures, any T3 or T4 parotid tumors

### **What is the most common benign salivary tumor?**

**Pleomorphic adenoma** (benign mixed tumor) 66%

Think: **P**leomorphic = **P**opular

### **What is the usual location?**

Parotid gland

### **What is the clinical course?**

They are well delineated and slow growing

### **What is the second most common benign salivary gland tumor?**

Warthin's tumor (1% of all salivary gland tumors)

### **What is the usual location?**

95% are found in parotid; 3% are bilateral

### **Describe the lesion.**

Slow-growing, cystic mass is usually located in the tail of the superficial portion of the parotid; it rarely becomes malignant

### **What is the most common malignant salivary tumor?**

**Mucoepidermoid carcinoma** (10% of all salivary gland neoplasms) Think:

**M**ucoepidermoid = **M**alignant

Most common parotid malignancy

Second most common submandibular gland malignancy

### **What is the second most common malignant salivary tumor in adults?**

Adenoid cystic carcinoma; most common malignancy in submandibular and minor salivary glands

## ■ Croup (Laryngotracheobronchitis)

### **What is it?**

Viral infection of the larynx and trachea, generally affecting children (boys > girls)

### **What is the usual cause?**

Parainfluenza virus (Think: crou**P** = **P**arainfluenza)

### **What age group is affected most?**

Ages 6 months to 3 years

### **Is the condition considered seasonal?**

Yes; outbreaks most often occur in autumn

### **What are the precipitating events?**

Usually preceded by URI

### **What is the classic symptom?**

Barking (seal-like), nonproductive cough

### **What are the other symptoms?**

Respiratory distress, low-grade fever

### **What are the signs?**

Tachypnea, inspiratory retractions, prolonged inspiration, inspiratory stridor, expiratory rhonchi/wheezes

### **What is the differential diagnosis?**

Epiglottitis, bacterial tracheitis, foreign body, diphtheria, retropharyngeal abscess, peritonsillar abscess, asthma

### **How is the diagnosis made?**

A-P neck x-ray shows classic “steeple sign,” indicating subglottic narrowing; ABG may show hypoxemia plus hypercapnia

### **What is the treatment?**

**Keep child calm** (agitation only worsens obstruction); cool mist; steroids; aerosolized racemic EPI may be administered to reduce edema/airway obstruction

### **What are the indications for intubation?**

If airway obstruction is severe or child becomes exhausted

### **What is the usual course?**

Resolves in 3 to 4 days

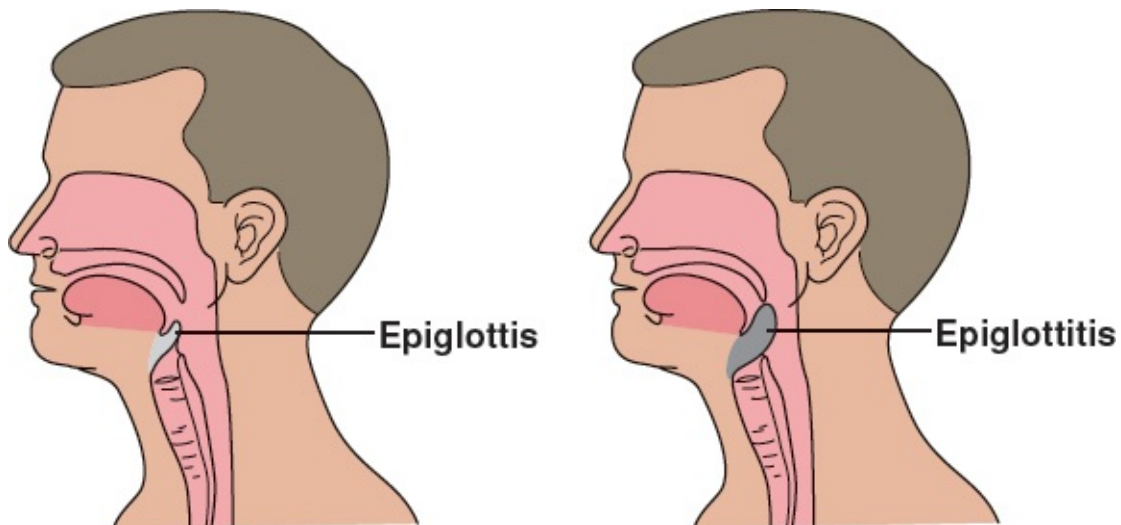
### **What type of secondary infection occurs?**

Secondary bacterial infection (streptococcal, staphylococcal)

## **■ Epiglottitis**

### **What is it?**

Severe, rapidly progressive infection of the epiglottis



### **What is the usual causative agent?**

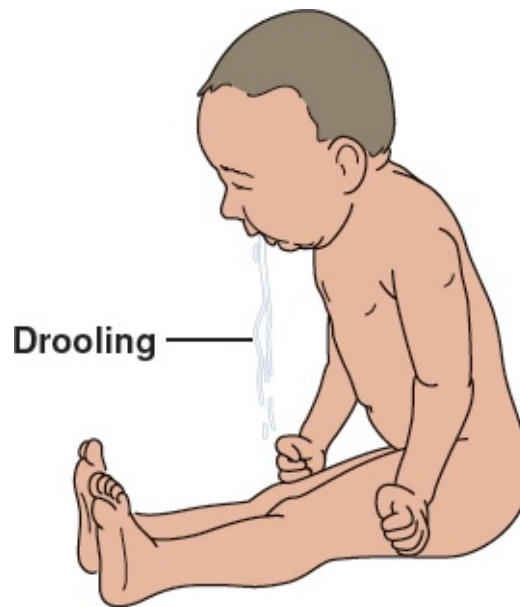*H. influenzae* type B

### **What age group is affected?**

Children 2 to 5 years of age

### **What are the signs/symptoms?**

Sudden onset, high fever (40°C); “hot-potato” voice; dysphagia (→ drooling); no cough; patient prefers to sit upright, lean forward; patient appears toxic and stridulous



### **How is the diagnosis made?**

Can usually be made clinically and does not involve direct observation of the epiglottitis (which may worsen obstruction by causing laryngospasm)

### **What is the treatment?**

Involves immediate airway support in the O.R.: intubation or possibly tracheostomy, medical treatment is composed of steroids and IV antibiotics against *H. influenzae*

## **■ Malignant Lesions of the Larynx**

### **What is the incidence?**

Accounts for ≈2% of all malignancies, more often in males

### **What is the most common site?**

Glottis (66%)

**What is the second most common type?**

Supraglottis (33%)

**Which type has the worst prognosis?**

Subglottic tumors (infrequent)

**What are the risk factors?**

Tobacco, alcohol

**What is the pathology?**

90% are squamous cell carcinoma

**What are the symptoms?**

Hoarseness, throat pain, dysphagia, odynophagia, neck mass, (referred) ear pain

## ■ Supraglottic Lesions

**What is the usual location?**

Laryngeal surface of epiglottis

**What area is often involved?**

Pre-epiglottic space

**Extension?**

Tend to remain confined to supraglottic region, though may extend to vallecula or base of tongue

**What is the associated type of metastasis?**

High propensity for nodal metastasis

**What is the treatment?**

Early stage = XRT

Late stage = laryngectomy

## ■ Glottic Lesions

### **What is the usual location?**

Anterior part of true cords

### **Extension?**

May invade thyroid cartilage, cross midline to invade contralateral cord, or invade paraglottic space

### **What is the associated type of metastasis?**

Rare nodal metastasis

### **What is the treatment?**

Early stage = XRT

Late stage = laryngectomy

## **Neck Mass**

### **What is the usual etiology in infants?**

Congenital (branchial cleft cysts, thyroglossal duct cysts)

### **What is the usual etiology in adolescents?**

Inflammatory (cervical adenitis is #1), with congenital also possible

### **What is the usual etiology in adults?**

Malignancy (squamous is #1), especially if painless and immobile

### **What is the “80% rule”?**

In general, **80%** of neck masses are **benign** in children; **80%** are **malignant** in adults >40 years of age

### **What are the seven cardinal symptoms of neck masses?**

- . Dysphagia
- . Odynophagia
- . Hoarseness
- . Stridor (signifies upper airway obstruction)
- . Globus

- . Speech disorder
- . Referred ear pain (via CN V, IX, or X)

### **What comprises the workup?**

Full head and neck examination, indirect laryngoscopy, CT scan and MRI, FNA for tissue diagnosis; biopsy contraindicated because it may adversely affect survival if malignant

### **What is the differential diagnosis?**

Inflammatory: cervical lymphadenitis, cat-scratch disease, infectious mononucleosis, infection in neck spaces

Congenital: thyroglossal duct cyst (midline, elevates with tongue protrusion), branchial cleft cysts (lateral), dermoid cysts (midline submental), hemangioma, cystic hygroma

Neoplastic: primary or metastatic

### **What is the workup of node-positive squamous cell carcinoma and no primary site?**

Triple endoscopy (laryngoscopy, esophagoscopy, bronchoscopy) and biopsies of likely sites, PET scan

### **What is the treatment?**

Surgical excision for congenital or neoplastic; two most important procedures for cancer treatment are selective and modified neck dissection

### **What is the role of adjuvant treatment in head and neck cancer?**

Postoperative chemotherapy/XRT

## **■ Radical Neck Dissection**

### **What is involved?**

Classically, removal of **nodes** from clavicle to mandible, sternocleidomastoid muscle, **submandibular gland**, tail of **parotid**, internal **jugular vein**, **digastric muscles**, **stylohyoid** and **omohyoid muscles**, **fascia** within the anterior and posterior triangles, CN XI, and cervical plexus sensory nerves

## ■ Modified Neck Dissection

### **What is involved?**

Removal of lymph nodes in levels 1 to 5 with preservation of one of the three following structures: spinal accessory nerve, internal jugular vein, or sternocleidomastoid muscle

### **What are the contraindications?**

- . Distant METS
- . Fixation of vital structures (e.g., carotid artery)

## ■ Selective Neck Dissection

### **What is involved?**

One or more of the lymph node groups in levels 1 to 5 are preserved based on the location of the primary tumor

### **What are the advantages when compared to modified radical neck dissection?**

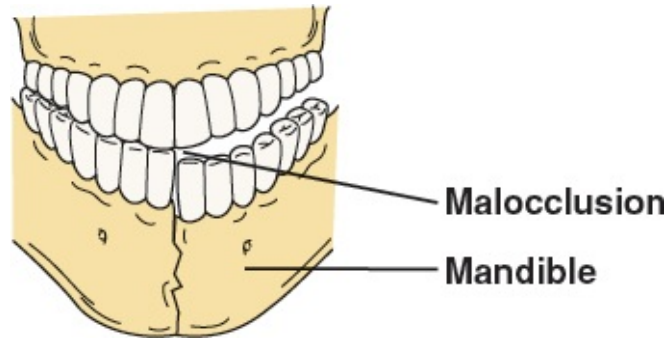
Decision to perform a selective neck dissection is based on the location of the primary tumor and its likelihood to metastasize to a specific size

## FACIAL FRACTURES

## ■ Mandible Fractures

### **What are the symptoms?**

Gross disfigurement, pain, **malocclusion**, drooling



### **What are the signs?**

Trismus, fragment mobility and lacerations of gingiva, hematoma in floor of mouth

### **What are the possible complications?**

Malunion, nonunion, osteomyelitis, TMJ ankylosis

### **What is the treatment?**

Open or closed reduction

**MMF** = **M**axillo**M**andibular **F**ixation (wire jaw shut)

## **■ Midface Fractures**

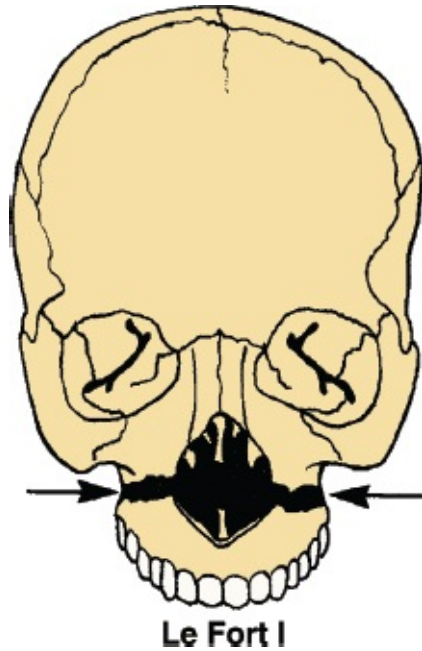
### **How are they evaluated?**

Careful physical examination and CT scan

### **► Classification**

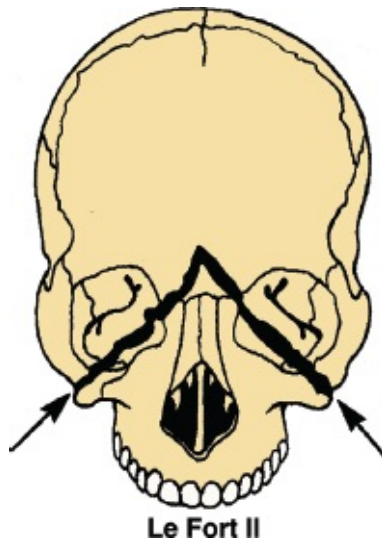
#### **Le Fort I?**

Transverse maxillary fracture above the dental apices, which also traverses the pterygoid plate; palate is mobile, but nasal complex is stable



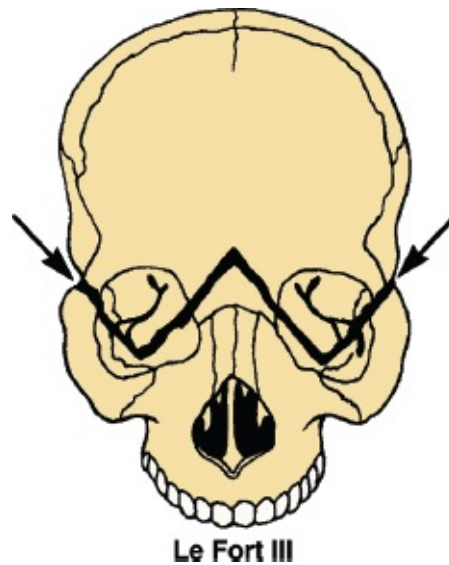
### Le Fort II?

Fracture through the frontal process of the maxilla, through the orbital floor and pterygoid plate; midface is mobile



### Le Fort III?

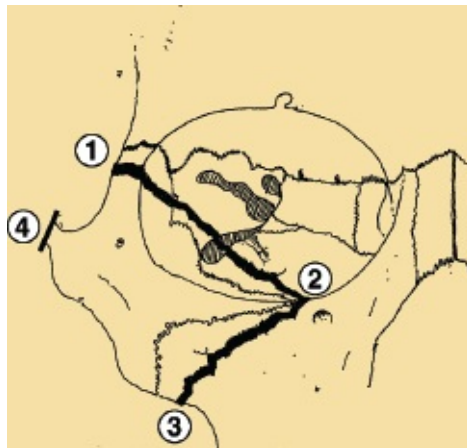
**Complete craniofacial separation;** differs from II in that it extends through the nasofrontal suture and frontozygomatic sutures



### What is a “tripod” fracture?

Fracture of the zygomatic complex; involves four fractures:

1. Frontozygomatic suture
2. Inferior orbital rim
3. Zygomaticomaxillary suture
4. Zygomaticotemporal suture



### What is a “blowout” fracture?

Orbital fracture with “blowout” of supporting bony structural support of orbital floor; patient has enophthalmos (sunken-in eyeball)

### What is “entrapment”?

Orbital fracture with “entrapment” of periorbital tissues within the fracture opening, including entrapment of extraocular muscles; loss of extraocular

muscle mobility (e.g., lateral tracking) and diplopia (double vision)

**What is a “step off”?**

Fracture of the orbit with palpable “step off” of bony orbital rim (inferior or lateral)

**Are mandibular fractures usually a single fracture?**

No; because the mandible forms an anatomic ring, >95% of mandible fractures have more than one fracture site

**What is the best x-ray study for mandibular fractures?**

Panorex

**What must be ruled out and treated with a broken nose (nasal fracture)?**

Septal hematoma; must drain to remove chance of pressure-induced septal necrosis

## RAPID FIRE REVIEW

**How can otitis externa be distinguished from otitis media on examination?**

Otitis externa is characterized by severe pain upon manipulation of the auricle

**What causes otitis media?**

Most cases are caused by pneumococci and *H. influenzae*

**What causes otitis externa?**

*Pseudomonas aeruginosa*

**What must be considered in unilateral serous otitis?**

Nasopharyngeal carcinoma

**What is the most common cause of facial paralysis?**

**Bell’s palsy**, which has an unidentified etiology

**What is the single most important prognostic factor in Bell's palsy?**

Whether the affected muscles are completely paralyzed (if not, prognosis is >95% complete recovery)

**What is the most common cause of parotid swelling?**

Mumps

**What is Heerfordt's syndrome?**

Sarcoidosis with parotid enlargement, facial nerve paralysis, and uveitis

**Which systemic disease causes salivary gland stones?**

Gout

**What is the most common salivary gland site of stone formation?**

Submandibular gland

**What is Mikulicz's syndrome?**

Any cause of bilateral enlargement of the parotid, lacrimal, and submandibular glands

**What are the three major functions of the larynx?**

1. Airway protection
2. Airway/respiration
3. Phonation

**What is a cricothyroidotomy?**

Emergent surgical airway by incising the cricothyroid membrane

**What is the classic triad of Ménière's disease?**

Hearing loss, tinnitus, vertigo (HTV)

**What is the most common posterior fossa tumor, and where is it located?**

Acoustic neuroma, usually occurring at the cerebellopontine angle

**What is the most common site of sinus cancer?**

Maxillary sinus

**What tumor arises from olfactory epithelium?**

Esthesioneuroblastoma

**What cell type is most common in head and neck cancer?**

Squamous cell

**What are the most important predisposing factors to head and neck cancer?**

Excessive alcohol use and **tobacco** abuse of any form—incidence of HPV-related cancer on the rise!

**What is the most frequent site of salivary gland tumor?**

Parotid gland

**What is the most common salivary gland neoplasm:**

**Benign?**

Pleomorphic adenoma

**Malignant?**

Mucoepidermoid carcinoma

**What is the classic feature of croup?**

Barking, seal-like cough

**What are the classic features of epiglottitis?**

“Hot-potato” voice, sitting up, **drooling**, toxic appearance, high fever, **leaning forward**

**What is the most common malignant neck mass in children, adolescents, and young adults?**

Lymphoma

**What is the most common primary malignant solid tumor of the head and neck in children?**

Rhabdomyosarcoma

**Most common causes of ENT infections?**

## **Croup**

Parainfluenza virus

## **Otitis externa**

*Pseudomonas*

## **Epiglottitis**

*H. influenzae*

## **Malignant otitis externa**

*Pseudomonas*

## **Parotitis**

*Staphylococcus*

## **Acute suppurative otitis media**

*S. pneumoniae* (33%)

## **What is the correct diagnosis?**

### **“Hot potato” voice**

Epiglottitis or peritonsillar abscess

### **Neck abscess with sulfur granules**

*Actinomyces* infection

## **Name the most likely diagnosis:**

**28-year-old man with intermittent vertigo, intermittent hearing loss, tinnitus, and a subjective feeling of having ear swelling**

Ménière’s disease

**16-year-old girl with severe sore throat, lateral uvula displacement, bulging tonsillar pillar, + *Streptococcus pyogenes***

Quinsy’s abscess (peritonsillar abscess)

**61-year-old man develops acute onset of pain and “blurry” vision in the right eye; sees “rings” around lights; states that he feels a little nauseated**

Open-angle glaucoma

**23-year-old woman while playing basketball gets hit in the left eye; has “blurry” vision in that eye; sees flashing lights and then sees things “floating” across**

Detached retina

**61-year-old woman with history of left-sided headaches, left temporal tenderness with swelling, pain in the left side of her jaw when she eats, elevated ESR**

Temporal arteritis

**2-year-old boy with a “lazy” left eye; left eye has decreased vision and lacks “red reflex” on exam**

Retinoblastoma

# Chapter 70 Thoracic Surgery

## THORACIC OUTLET SYNDROME (TOS)

### **What is thoracic outlet syndrome (TOS)?**

Compression of the neurovascular structures traversing the thoracic outlet, namely:

1. Subclavian artery (“arterial TOS”)
2. Subclavian vein (“venous TOS”)
3. Brachial plexus (“neurogenic TOS”)

### **What is the pathophysiology of TOS?**

Abnormal dynamics between the anterior scalene, middle scalene, and the first rib causing compression

### **What are the three causes of TOS?**

- . Congenital anomalies, including cervical rib (an “extra first rib”), abnormal fascial bands to the first rib, or abnormal scalene muscles
- . Trauma—first rib or clavicle fracture, humeral head dislocation, or crush injury
- . Repetitive use/overuse (i.e., baseball pitchers)

### **What are the symptoms?**

Paresthesias (neck, shoulder, arm, hand); 90% in ulnar nerve distribution

Weakness (neural/arterial)

Coolness of involved extremity (arterial)

Edema, venous distension, discoloration (venous)

### **What are the most common symptoms with TOS?**

Neurogenic

Mixed neurogenic and arterial combined or pure neurogenic TOS accounts for 95% of TOS; pure arterial or venous TOS occurs 5% of the time

### **Which nerve is most often involved?**

Ulnar nerve

### **What are the signs?**

Paget–von Schroetter syndrome—venous thrombosis (a.k.a. “effort thrombosis”) leading to edema, arm discoloration, and distension of the superficial veins

Weak brachial and radial pulses in the involved arm

Hypesthesia/anesthesia

Atrophy in the distribution of the ulnar nerve

Positive Adson maneuver/Tinel’s sign

Edema

### **What is the Adson maneuver?**

#### **Evaluates for arterial compromise**

Patient:

1. Extends neck (lifts head)
2. Takes a deep breath and holds
3. Turns head toward examined side

Physician:

Monitors radial pulse on examined side

Test finding is positive if the radial pulse decreases or disappears during maneuver

### **What is Tinel’s test?**

Tapping of the supraclavicular fossa producing paresthesias

### **What is the treatment for neurogenic TOS?**

- . 3 months of physical therapy
- . Decompression of the thoracic outlet. Principles are: scalenectomy, brachial plexus neurolysis, and first rib resection

### **What is the treatment for venous TOS (Paget–von Schroetter disease?)**

Thrombolytic and, soon after, surgery to decompress the thoracic outlet, including venolysis

### **What is the treatment for arterial TOS?**

Surgery to decompress the thoracic outlet and, if necessary, repair/reconstruct the injured subclavian artery

## CHEST WALL TUMORS

**What are the most common benign chest wall tumors and their typical presentation?**

- . Osteochondroma (30% to 50%), painless mass on the rib metaphysis
- . Fibrous dysplasia (20% to 30%), painful rib lesion or pathologic fracture
- . Chondroma (15% to 20%), slowly enlarging, painless mass at the costochondral junction

**What are the most common primary chest wall malignancies?**

- . Chondrosarcoma
- . Osteosarcoma
- . Ewing's sarcoma and primitive neuroectodermal tumor or PNET (an aggressive form of Ewing's sarcoma)
- . Solitary plasmacytoma

**Which chest wall tumor demonstrates a classic “onion-peel” appearance on x-ray?**

Ewing's sarcoma

**Which chest wall tumor demonstrates a classic “sunburst” appearance on x-ray?**

Osteosarcoma

**What is the treatment for malignant chest wall tumors?**

Wide resection with 4 to 5 cm margins

## DISEASES OF THE PLEURA

### ■ Pleural Effusion

**What are the two types of pleural effusions and their etiologies?**

- . Transudative—congestive heart failure, nephrotic syndrome, and cirrhosis
- . Exudative—infection, malignancy, trauma, and pancreatitis

**What are Light's criteria, whereby if at least one of the criteria is met, the fluid is defined as exudative?**

- . Pleural fluid-to-serum protein ratio  $>0.5$
- . Pleural fluid-to-serum LDH ratio  $>0.6$
- . Pleural fluid LDH  $>2/3$  upper limit of laboratory's normal serum LDH

**What is the diagnostic test of choice?**

Thoracentesis (needle drainage) with pleural fluid studies, including cytology

**What is the treatment?**

- . Pigtail catheter or thoracostomy (chest tube)
- . Treat underlying condition
- . Consider sclerosis if malignant pleural effusion

**What is an empyema?**

Infected pleural effusion; must be drained, usually with chest tube(s)

Decortication may be necessary if tube thoracostomy drainage is incomplete

**What is a decortication?**

Thoracotomy and removal of an infected fibrous rind from around the lung (think of it as taking off a fibrous “cortex” from the lung)

## ■ Spontaneous Pneumothorax

**What are the causes?**

Primary (idiopathic or no cause identified) or secondary (due to bleb disease/emphysema, rarely cancer)

**What body habitus is associated with primary spontaneous pneumothorax?**

Thin and tall

**What is the treatment?**

Chest tube or pigtail catheter

**What are the options if refractory, recurrent, or bilateral?**

Thoracoscopy with mechanical pleurodesis

**Who might also need a pleurodesis after the first episode?**

Those whose lifestyles place them at increased risk for pneumothorax (e.g., pilots, scuba divers)

**What is a catamenial pneumothorax?**

Pneumothorax due to intrathoracic endometriosis

## DISEASES OF THE LUNGS

### ■ Lung Cancer

**What is the number of annual deaths from lung cancer?**

160,000; most common cancer death in the United States in men and women

**What is the #1 risk factor?**

Smoking

**Does asbestos exposure increase the risk in patients who smoke?**

Yes

**What type of lung cancer arises in nonsmokers?**

Adenocarcinoma

**Cancer arises more often in which lung?**

Right > left; upper lobes > lower lobes

**What are the signs/symptoms?**

Change in a chronic cough

Hemoptysis, chest pain, dyspnea

Pleural effusion (suggests chest wall involvement)

Hoarseness (recurrent laryngeal nerve involvement)

Superior vena cava syndrome  
Diaphragmatic paralysis (phrenic nerve involvement)  
Symptoms of metastasis/paraneoplastic syndrome  
Finger clubbing

### **What is a Pancoast (superior sulcus) tumor?**

Tumor at the apex of the lung or superior sulcus that may involve the brachial plexus, sympathetic ganglia, and vertebral bodies, leading to pain, upper extremity weakness, and Horner's syndrome

### **What is Horner's syndrome?**

Injury to the cervical sympathetic chain; think: "MAP"

1. **M**iosis (small pupil)
2. **A**nhidrosis of ipsilateral face
3. **P**tosis

### **What are the five most common sites of extrathoracic metastases?**

- . Brain
- . Bone
- . Adrenals
- . Liver
- . Kidney

### **What are paraneoplastic syndromes?**

Syndromes that are associated with tumors but may affect distant parts of the body; they may be caused by hormones released from endocrinologically active tumors or may be of uncertain etiology

### **Name five general types of paraneoplastic syndromes**

- . Metabolic: Cushing's, SIADH, hypercalcemia
- . Neuromuscular: Eaton-Lambert, cerebellar ataxia
- . Skeletal: hypertrophic osteoarthropathy
- . Dermatologic: acanthosis nigricans
- . Vascular: thrombophlebitis

### **What are the associated radiographic tests?**

CXR, CT scan, PET scan

## How is the tumor diagnosed?

- . Needle biopsy (CT or fluoro guidance)
- . Bronchoscopy with brushings, biopsies, or both
- . ± Mediastinoscopy, mediastinotomy, scalene node biopsy, or thoracoscopic/open lung biopsy for definitive diagnosis

## How is small cell carcinoma treated?

Chemotherapy ± XRT and prophylactic whole brain irradiation (very small isolated lesions can be surgically resected)

## What are the contraindications to surgery for lung cancer?

Think: “SSSTOP IT”

Superior vena cava syndrome

Supraclavicular node metastasis

Scalene node metastasis

Tracheal carina involvement

Oat cell carcinoma (treat with chemotherapy ± radiation)

Pulmonary function tests show  $FEV_1 < 0.8$  L

Infarction (myocardial); a.k.a. “cardiac cripple”

Tumor elsewhere (metastatic disease)

## What postoperative $FEV_1$ must you have?

$FEV_1 \geq 800$  cc; thus, a preoperative  $FEV_1 \geq 2$  L is usually needed for a pneumonectomy

If  $FEV_1$  is  $< 2$  L, a ventilation perfusion scan should be performed

## What is hypertrophic pulmonary osteoarthropathy?

Periosteal proliferation and new bone formation at the end of long bones and in the bones of the hand (seen in 10% of patients with lung cancer)

## ■ Solitary Pulmonary Nodules (Coin Lesions)

### What is a solitary pulmonary nodule (SPN)?

Intraparenchymal pulmonary lesion that is  $< 3$  cm (considered a “mass” at 3 cm);

causes can be benign (60%) or malignant (40%)

### **What is the risk of malignancy based on size?**

| <b>Size</b> | <b>Risk</b> |
|-------------|-------------|
| <3 mm       | 0.2%        |
| 4–7 mm      | 0.9%        |
| 8–20 mm     | 18%         |
| >20 mm      | 50%         |

### **How is the diagnosis made?**

CXR, chest CT scan

### **What is the characteristic appearance of hamartoma on CXR?**

“Popcorn” calcification

### **What are the common benign etiologies of SPN?**

- . Infectious granuloma (80% of benign SPN)
- . Hamartoma (10% of benign SPN)

### **What percentage are malignant?**

Overall, 5% to 10% (but >50% are malignant in smokers >50 years)

### **Is there a gender risk?**

Yes; the incidence of coin lesions is 3 to 9× higher and malignancy is nearly twice as common in men as in women

### **What are the risk factors for malignancy?**

- . Size: lesions >1 cm have a significant chance of malignancy, and those >4 cm are very likely to be malignant
- . Indistinct margins (corona radiata)
- . Documented growth on follow-up x-ray (if no change in 2 years, most likely benign)
- . Increasing age

### **What are the diagnostic modalities available for tissue diagnosis?**

- . CT-guided percutaneous biopsy (excellent accuracy if  $\geq 1$  cm)
- . Navigational bronchoscopy (employs CT and electromagnetic guidance to

- target the bronchus associated with pulmonary nodule for biopsy; also can place markers to aid in thoracoscopic identification for wedge resection)
- . Thoracoscopic (better tolerated) or open thoracotomy with wedge resection

### **What if the patient has an SPN and pulmonary hypertrophic osteoarthropathy?**

>75% chance of carcinoma

### **What is its incidence?**

≈7% of patients with lung cancer (2% to 12%)

### **What are the signs?**

Associated with finger clubbing; diagnosed by x-ray of long bones, revealing periosteal bone hypertrophy

## **Carcinoid Tumor**

### **What is it?**

**APUD** (**A**mine-**P**recursor **U**ptake and **D**ecarboxylation) cell tumor of the bronchus

### **What is its natural course in the lung?**

Slow growing (but may be malignant)

### **What are the primary local findings?**

Wheezing and atelectasis caused by bronchial obstruction/stenosis

### **What condition can it be confused with?**

Asthma

### **How is the diagnosis made?**

Bronchoscopy reveals round red-yellow-purple mass covered by epithelium that protrudes into bronchial lumen

### **What is the treatment?**

Surgical resection (lobectomy with lymph node dissection)

Sleeve resection is also an option for proximal bronchial lesions

### **What is a sleeve resection?**

Resection of a ring segment of bronchus (with tumor inside) and then end-to-end anastomosis of the remaining ends, allowing salvage of lower lobe

### **What is the most common benign lung tumor?**

Hamartoma (normal cells in a weird configuration)

## **■ Pulmonary Sequestration**

### **What is it?**

Abnormal benign lung tissue with separate blood supply that **DOES NOT** communicate with the normal tracheobronchial airway; have **systemic arterial blood supply** (usually off thoracic aorta)

### **Define the following terms and venous drainage:**

#### **Interlobar**

Sequestration in normal lung tissue covered by normal visceral pleura; **pulmonary venous drainage** (and usually found in adults)

#### **Extralobar**

Sequestration not in normal lung covered by its own pleura; **systemic venous drainage** (and usually found in children)

## **■ Lung Abscess**

### **What are the signs/symptoms?**

Fever, productive cough, sepsis, fatigue

### **What are the associated diagnostic studies?**

CXR: air–fluid level

CT scan to define position and to differentiate from an empyema

Bronchoscopy (looking for cancer/culture)

### **What is the treatment?**

- . Antibiotics and bronchoscopy for culture and drainage
- . Percutaneous drainage
- . Surgical resection if nonoperative management fails or underlying cancer

### **What is middle lobe syndrome?**

Recurrent right middle lobe pneumonia caused most commonly by intermittent extrinsic bronchial obstruction

## **Hemoptysis**

### **What is it?**

Bleeding into the bronchial tree

### **What are the causes?**

- . Bronchitis (50%)
- . Tumor mass (20%)
- . TB (8%)
- . Other causes: bronchiectasis, pulmonary catheters, trauma

### **What defines massive hemoptysis?**

>600 cc/24 hr

### **What comprises the workup?**

CXR

Bronchoscopy

CT arteriogram

### **What is the usual cause of death?**

Asphyxia (not hemorrhagic shock)

### **Which arterial system is most often the source of massive hemoptysis?**

Bronchial (not pulmonary) arteries

### **What is the acute management of massive hemoptysis?**

- . Protect the nonbleeding lung by positioning the patient “bleeding side down”
- . Establish an airway with at least #8 endotracheal tube or ETT (for bronchoscopy and intervention)—either single lumen ETT into nonbleeding lung ± fiberoptic bronchoscopic guidance or double lumen ETT with bronchial cuff inflated to protect good lung from bleeding lung
- . Reverse any coagulopathies
- . Stop the bleeding

### **What are the options for controlling the bleeding?**

- . Bronchoscopy with 4-Fr Fogarty balloon occlusion
- . Arteriography and selective bronchial artery embolization

## **DISEASES OF THE MEDIASTINUM**

### **■ Primary Mediastinal Tumors**

#### **▶ Thymoma**

### **Where are they found in the mediastinum?**

Anterior

### **How is the diagnosis made?**

CT scan

### **What percentage of patients with thymoma have myasthenia gravis?**

30% to 45%

### **What percentage of myasthenia gravis patients have thymoma?**

10% to 15%

### **Should myasthenia gravis patients undergo thymectomy?**

Yes, and counterintuitively, myasthenia patients **without thymoma have better symptomatic improvement** after thymectomy than patients with thymoma

## ► *Teratomas*

### **What are they?**

Tumors of branchial cleft cells; the tumors contain ectoderm, endoderm, and mesoderm

### **What is a dermoid cyst?**

Teratoma made up of ectodermal derivatives (e.g., teeth, skin, hair)

### **Which age group is affected?**

Usually adolescents, but can occur at any age

### **Where in the mediastinum do they occur?**

Anterior

### **What are the characteristic x-ray findings?**

Calcifications or teeth; tumors may be cystic

### **What percentage are malignant?**

≈15%

### **What is the treatment of benign dermoid cysts?**

Surgical excision

### **What is the treatment of malignant teratoma?**

Preoperative chemotherapy until tumor markers are normal, then surgical resection

### **Which tumor markers are associated with malignant teratomas?**

AFP, CEA

## ► *Neurogenic Tumors*

### **What is the incidence?**

**Most common** mediastinal tumors in all age groups

### **Where in the mediastinum do they occur?**

Posterior, in the paravertebral gutters

### **What percentage are malignant?**

50% in children

10% in adults

## **Lymphoma**

### **Where in the mediastinum does it occur?**

Anywhere, but most often in the anterosuperior mediastinum or hilum in the middle mediastinum

### **What percentage of lymphomas involve mediastinal nodes?**

≈50%

### **What are the symptoms?**

Cough, fever, chest pain, weight loss, SVC syndrome, chylothorax

### **How is the diagnosis made?**

- . CXR, CT scan
- . Mediastinoscopy or mediastinotomy with node biopsy

### **What is the treatment?**

Nonsurgical (chemotherapy, radiation, or both)

## **Mediastinitis**

### *Acute Mediastinitis*

### **What is it?**

Acute suppurative mediastinal infection

### **What are the six etiologies?**

- . Esophageal perforation (Boerhaave's syndrome)

- . Postoperative wound infection
- . Head and neck infections
- . Lung or pleural infections
- . Rib or vertebral osteomyelitis
- . Distant infections

### **What are the clinical features?**

Fever, chest pain, dysphagia (especially with esophageal perforation), respiratory distress, leukocytosis

### **What is the treatment?**

- . Wide drainage (via right thoracoscopy or thoracotomy or transcervical mediastinal drainage)
- . Treatment of primary cause
- . Antibiotics

## **Chronic Mediastinitis**

### **What is it?**

Mediastinal fibrosis secondary to *chronic* granulomatous infection

### **What is the most common etiology?**

Histoplasma capsulatum

### **What are the clinical features?**

50% are asymptomatic; symptoms are related to compression of adjacent structures: SVC syndrome, bronchial and esophageal strictures, constrictive pericarditis

### **How is the diagnosis made?**

CXR or CT scan may be helpful, but surgery/biopsy often makes the diagnosis

### **What is the treatment?**

Antibiotics; surgical removal of the granulomas is rarely helpful

## ■ Superior Vena Cava Syndrome

### **What is it?**

Obstruction of the superior vena cava, usually by extrinsic compression

### **What is the #1 cause?**

Malignant tumors cause ≈90% of cases; lung cancer is by far the most common; other tumors include thymoma, lymphoma, and Hodgkin's disease

### **What are the clinical manifestations?**

- . Blue discoloration and puffiness of the face, arms, and shoulders
- . CNS manifestations may include headache, nausea, vomiting, visual distortion, stupor, and convulsions.
- . Cough, hoarseness, and dyspnea

### **What is the treatment?**

The goals are to relieve symptoms and attempt to cure any malignant process:

1. Elevation of the head and supplemental oxygen
2. Steroids and diuretics for laryngeal or cerebral edema is controversial
3. Prompt radiation therapy ± chemotherapy for any causative cancer (symptoms improve, but overall prognosis is poor)

## DISEASES OF THE ESOPHAGUS

### ■ Anatomic Considerations

**Identify the esophageal muscle type:**

#### **Proximal 1/3**

Skeletal muscle

#### **Middle 1/3**

Smooth muscle > skeletal muscle

## **Distal 1/3**

Smooth muscle

### **Why is the esophagus notorious for anastomotic leaks?**

Esophagus has no serosa (same as the distal rectum)

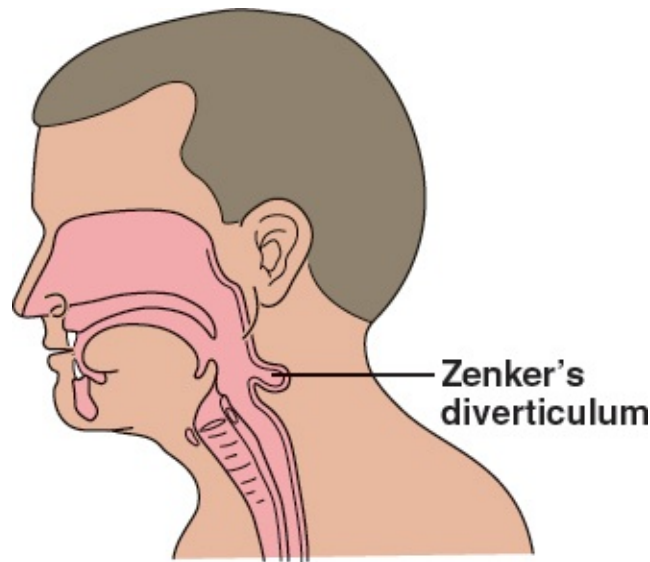
### **What nerve runs with the esophagus?**

Vagus nerve

## **Zenker's Diverticulum**

### **What is it?**

Pharyngoesophageal diverticulum; a false diverticulum containing mucosa and submucosa at the UES at the pharyngoesophageal junction through Killian's triangle



### **What are the signs/symptoms?**

Dysphagia, neck mass, halitosis, food regurgitation, heartburn

### **How is the diagnosis made?**

Barium swallow

### **What is the treatment?**

- . One stage cricopharyngeal myotomy and diverticulectomy
- . Other options are cricopharyngeal myotomy and diverticulopexy to the prevertebral fascia or transoral stapling of the common wall between the diverticulum and the esophagus with diverticulum  $\geq 3$  cm (to fit the stapler)

## ■ Achalasia

### What is it?

- . Failure of the LES to relax during swallowing
- . Aperistalsis of the esophageal body

### What are the proposed etiologies?

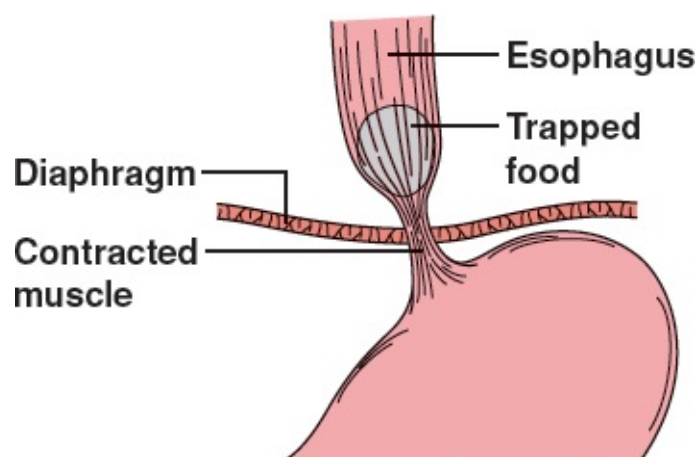
- . Neurologic (ganglionic degeneration of Auerbach's plexus, vagus nerve, or both); possibly infectious in nature
- . Chagas' disease in South America

### What are the associated long-term conditions?

Esophageal carcinoma secondary to Barrett's esophagus from food stasis

### What are the symptoms?

Dysphagia for both solids and liquids, followed by regurgitation; dysphagia for liquids is worse



### What are the diagnostic findings?

Radiographic contrast studies reveal dilated esophageal body with narrowing

inferiorly

**Manometry:** motility studies reveal failure of the LES to relax during swallowing and aperistalsis of the esophageal body

### **What are the treatment options?**

- . Upper endoscopy and balloon dilation of the LES
- . Laparoscopic Heller myotomy of the lower esophagus and LES (6 cm) and 2 cm onto the stomach

## **Diffuse Esophageal Spasm**

### **What is it?**

Strong, nonperistaltic contractions of the esophageal body; sphincter function is usually normal

### **What is the associated condition?**

Gastroesophageal reflux

### **What are the symptoms?**

Spontaneous chest pain that radiates to the back, ears, neck, jaw, or arms

### **What is the differential diagnosis?**

Angina pectoris

Psychoneurosis

Nutcracker esophagus

### **What are the associated diagnostic tests?**

**Esophageal manometry:** Motility studies reveal repetitive, high-amplitude contractions with normal sphincter response

Upper GI may be normal, but 50% show segmented spasms or corkscrew esophagus

Endoscopy

### **What is the classic finding on esophageal contrast study (UGI)?**

“Corkscrew esophagus”

**What is the treatment?**

Medical (antireflux measures, calcium channel blockers, nitrates)  
Long esophagomyotomy in refractory cases

## Nutcracker Esophagus

**What is it also known as?**

Hypertensive peristalsis

**What is it?**

Very strong peristaltic waves

**What are the symptoms?**

Spontaneous chest pain that radiates to the back, ears, neck, jaw, or arms

**What is the differential diagnosis?**

Angina pectoris

Psychoneurosis

Diffuse esophageal spasm

**What are the associated diagnostic tests?**

- . Esophageal manometry: motility studies reveal repetitive, high-amplitude contractions with normal sphincter response
- . Results of UGI may be normal (rule out mass)
- . Endoscopy

**What is the treatment?**

Medical (antireflux measures, calcium channel blockers, nitrates)  
Long esophagomyotomy in refractory cases

## ESOPHAGEAL REFLUX

**What is it?**

Reflux of gastric contents into the lower esophagus resulting from the decreased function of the LES

**What are the causes?**

- . Decreased LES tone
- . Decreased esophageal motility
- . Hiatal hernia
- . Gastric outlet obstruction
- . NGT

**What are four associated conditions/factors?**

- . Sliding hiatal hernia
- . Tobacco and alcohol
- . Scleroderma
- . Decreased endogenous gastrin production

**What are the symptoms?**

Substernal pain, heartburn, regurgitation; symptoms are worse when the patient is supine and after meals

**How is the diagnosis made?**

Bravo pH study (wireless capsule pH monitoring) of the lower esophagus reveals acid reflux; allows for 48-hr (vs. 24-hr) monitoring and better tolerated compared to traditional catheter-based “pH probe”

**What is the initial treatment?**

Medical: H<sub>2</sub>-blockers, antacids, metoclopramide, omeprazole  
Elevation of the head of the bed; small, multiple meals

**Which four complications require surgery?**

- . Failure of medical therapy
- . Esophageal strictures
- . Progressive pulmonary insufficiency secondary to documented nocturnal aspiration
- . Barrett’s esophagus

**Describe each of the following types of surgery:****Nissen**

360° fundoplication: wrap fundus of stomach all the way around the

esophagus

### **Belsey Mark IV**

Left thoracic approach: 270° fundoplication (wrap fundus of stomach to recreate LES)

### **Hill**

Tighten arcuate ligament around esophagus and tack stomach to diaphragm

### **Laparoscope Nissen**

360° fundoplication (Nissen) via laparoscope

### **Laparoscopic Toupet**

Laparoscopic fundoplication posteriorly with less than 220° to 250° wrap used with decreased esophageal motility; disadvantage is more postoperative reflux

## **What is Barrett's esophagus?**

Replacement of the lower esophageal squamous epithelium with columnar epithelium secondary to reflux

## **Why is it significant?**

This lesion is premalignant

## **What is the treatment?**

People with significant reflux should be followed with regular surveillance, EGDs with biopsies, proton pump inhibitor (PPI), and antireflux precautions. Patients with severe dysplasia should undergo endoscopic mucosal resection (EMR) of dysplastic areas or nodules plus radiofrequency ablation of all Barrett's

Any invasive cancer identified should undergo staging and treatment with esophagectomy

## **Caustic Esophageal Strictures**

**Which agents may cause strictures if ingested?**

Lye, oven cleaners, drain cleaners, batteries, sodium hydroxide tablets (Clinitest)

### **How is the diagnosis made?**

History; EGD is clearly indicated early on to assess the extent of damage (<24 hrs); scope to level of severe injury (deep ulcer) only, water soluble contrast study for deep ulcers to rule out perforation

### **What is the initial treatment?**

- . NPO/IVF/H<sub>2</sub>-blocker
- . Do **not** induce emesis
- . Corticosteroids (controversial—probably best for shallow/moderate ulcers), antibiotics (penicillin/gentamicin) for moderate ulcers
- . Antibiotic for deep ulcers
- . Upper GI at 10 to 14 days

### **What is the long-term follow-up?**

Because of increased risk of esophageal squamous cancer (especially with ulceration), **endoscopies every other year**

## **Esophageal Carcinoma**

### **What are the two main types?**

- . Adenocarcinoma at the GE junction
- . Squamous cell carcinoma in most of the esophagus

### **What is the most common histology?**

**Worldwide:** squamous cell carcinoma (95%)

**USA:** adenocarcinoma

### **What is the age and gender distribution?**

Most common in the sixth decade of life, and men predominate

### **What are the etiologic factors (5)?**

- . Tobacco
- . Alcohol
- . GE reflux

- . Barrett's esophagus
- . Radiation

### **What are the symptoms?**

Dysphagia, weight loss

Other symptoms include chest pain, back pain, hoarseness, symptoms of metastasis

### **What comprises the workup?**

- . UGI
- . EGD
- . Endoscopic (endoesophageal) ultrasound (EUS)
- . PET-CT scan

### **What is the differential diagnosis?**

Leiomyoma, metastatic tumor, lymphomas, benign stricture, achalasia, diffuse esophageal spasm, GERD

### **How is the diagnosis made?**

- . Upper GI localizes tumor
- . EGD obtains biopsy and assesses resectability
- . Full metastatic workup (CXR, PET-CT scan, LFTs)

### **Describe the stages of adenocarcinoma esophageal cancer:**

#### **Stage I**

Tumor: invades lamina propria, muscularis mucosae, or submucosa (T1)

Nodes: negative

#### **Stage IIa**

Tumor: invades muscularis propria (T2)

Nodes: negative (N0)

#### **Stage IIb**

1. Tumor: invades muscularis propria (T2)
2. Nodes: positive regional nodes (N1)
3. Invades adventitia with negative nodes (T3N0)

### **Stage III**

1. Tumor: invades adventitia (T3)
1. Nodes: positive regional nodes (N1)
2. Tumor: invades adjacent structures (T4anyN)

### **Stage IV**

Distant metastasis

### **What is the treatment by stage?**

Esophagectomy with gastric pull-up

### **What is the operative mortality rate?**

10% overall

### **What is the postop complication rate?**

≈33% (mainly due to anastomotic leak, pulmonary complications, and atrial fibrillation)

## **RAPID FIRE REVIEW**

### **Name the most likely diagnosis:**

**54-year-old woman with dysphagia (to both liquid and solids) and intermittent chest pain; food “comes up” after falling asleep at night; manometry reveals high LES pressures that do not decrease with swallowing; absent esophageal peristalsis**

Achalasia

**Recurrent pneumonias, infiltrate on chest x-ray, no bronchus leading to area of infiltrate**

Pulmonary sequestration

**58-year-old male smoker with oat cell cancer of the lung and hyponatremia**

SIADH

**45-year-old male with hypertension, Marfan's syndrome describes abrupt onset of severe chest pain "tearing to my back"**

Aortic dissection

**30-year-old male seat belted involved in high-speed head-on MVC presents with massive subcutaneous air over entire chest, chest tube placed for massive pneumothorax on right reveals massive airleak**

Bronchial tear

**45-year-old man back from a visit to South America who was exposed to *Trypanosoma cruzi* now presents with dysphagia**

Chagas disease

**Name the diagnostic modality:**

**22-year-old male s/p gunshot wound to umbilicus; bullet is in the spine on x-rays**

Exploratory laparotomy

**27-year-old woman with stab to right flank**

CT scan with triple contrast (rectal, PO, IV)

**What is the treatment?**

**57-year-old s/p a fall with a right-sided tension pneumothorax**

Right-sided chest tube; if delay in placing chest tube, then needle decompression can temporize until the chest tube is placed

# Chapter 71 Cardiovascular Surgery

What do the following abbreviations stand for:

**AI?**

Aortic Insufficiency/regurgitation

**AS?**

Aortic Stenosis

**ASD?**

Atrial Septal Defect

**CABG?**

Coronary Artery Bypass Grafting

**CAD?**

Coronary Artery Disease

**CPB?**

CardioPulmonary Bypass

**IABP?**

IntraAortic Balloon Pump

**LAD?**

Left Anterior Descending coronary artery

**IMA?**

Internal Mammary Artery

**MR?**

Mitral Regurgitation

**PTCA?**

Percutaneous Transluminal Coronary Angioplasty (balloon angioplasty)

**VAD?**

Ventricular Assist Device

**VSD?**

Ventricular Septal Defect

**Define the following terms:****Stroke volume (SV)**

mL of blood pumped per heartbeat ( $SV = CO/HR$ )

**Cardiac output (CO)**

Amount of blood pumped by the heart each minute: heart rate  $\times$  SV

**Cardiac Index (CI)**

CO/BSA (body surface area)

**Ejection fraction**

Percentage of blood pumped out of the left ventricle:  $SV \div \text{end-diastolic volume}$  (nl 55% to 70%)

**Compliance**

Change in volume  $\div$  change in pressure

**SVR**

Systemic Vascular Resistance =

$$\frac{MAP - CVP}{CO \times 80}$$

**Preload**

Left ventricular end-diastolic pressure or volume

**Afterload**

Arterial resistance the heart pumps against

### **PVR**

**P**ulmonary **V**ascular **R**esistance =

$$PA_{(\text{mean})} - PCWP/CO \times 80$$

### **MAP**

**M**ean **A**rterial **P**ressure = diastolic BP + 1/3 (systolic BP – diastolic BP)

### **What is a normal CO?**

4 to 8 L/minute

### **What is a normal CI?**

2.5 to 4 L/minute

### **When does most of the coronary blood flow take place?**

During diastole (66%)

### **What are the three major coronary arteries?**

- . Left Anterior Descending (LAD)
- . Circumflex
- . Right coronary

### **What are the three main “cardiac electrolytes”?**

- . Calcium (inotropic)
- . Potassium (dysrhythmias)
- . Magnesium (dysrhythmias)

## **ACQUIRED HEART DISEASE**

### **Coronary Artery Disease (CAD)**

#### **What is it?**

Atherosclerotic occlusive lesions of the coronary arteries; segmental nature makes CABG possible

### **What is the incidence?**

CAD is the #1 killer in the Western world; >50% of cases are triple vessel diseases involving the LAD, circumflex, and right coronary arteries

### **Who classically gets “silent” MIs?**

Patients with diabetes (autonomic dysfunction)

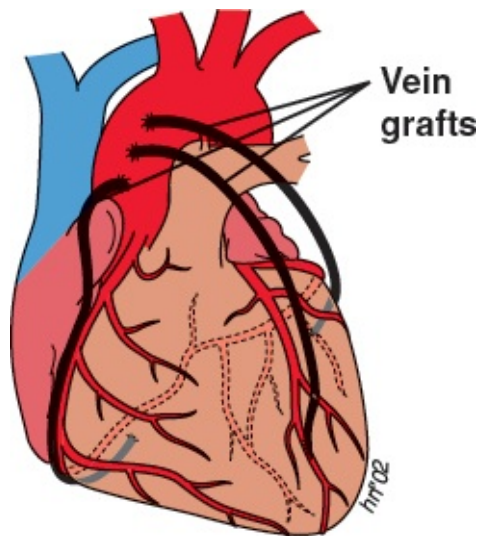
### **What is the treatment?**

Medical therapy ( $\beta$ -blockers, aspirin, nitrates, HTN medications), angioplasty (PTCA),  $\pm$  stents, surgical therapy: CABG

## **CABG**

### **What is it?**

Coronary Artery Bypass Grafting



### **What are the indications?**

Left main disease

$\geq 2$ -vessel disease (especially diabetics)

Unstable or disabling angina unresponsive to medical therapy/PTCA

Postinfarct angina

Coronary artery rupture, dissection, thrombosis after PTCA

### **CABG vs. PTCA $\pm$ stents?**

CABG = Survival improvement for diabetics and  $\geq 2$ -vessel disease,  $\uparrow$  short-term morbidity

PTCA =  $\downarrow$  short-term morbidity,  $\downarrow$  cost,  $\downarrow$  hospital stay,  $\uparrow$  reintervention,  $\uparrow$  postprocedure angina

### **What procedures are most often used in the treatment?**

Coronary arteries grafted (usually 3 to 6): internal mammary pedicle graft and saphenous vein free graft are most often used (IMA 95% 10-year patency vs. 50% with saphenous)

### **What medications should almost every patient be given after CABG?**

Aspirin,  $\beta$ -blocker

### **Can a CABG be performed off cardiopulmonary bypass?**

Yes, today they are performed with or without bypass

## **Postpericardiotomy Syndrome**

### **What is it?**

Pericarditis after pericardiotomy (unknown etiology), occurs weeks to 3 months postoperatively

### **What are the signs/symptoms?**

Fever

Chest pain, atrial fibrillation

Malaise

Pericardial friction rub

Pericardial effusion/pleural effusion

### **What is the treatment?**

NSAIDs,  $\pm$  steroids

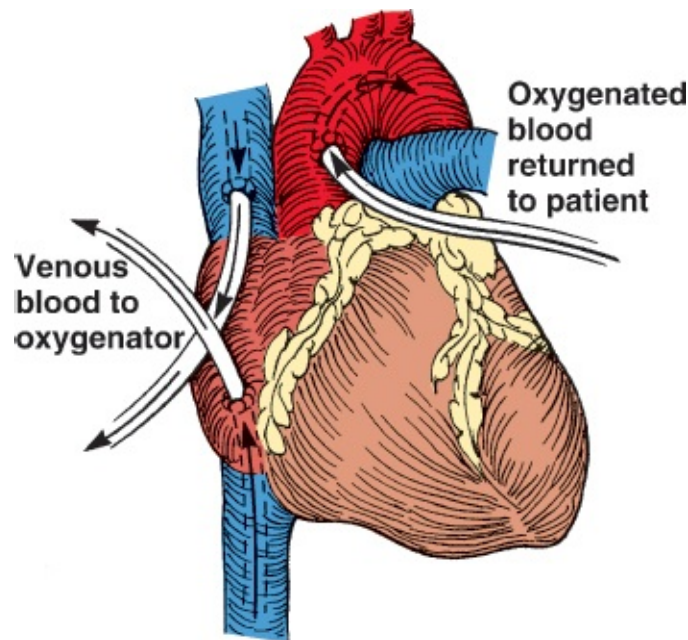
### **What is pericarditis after an MI called?**

Dressler's syndrome

## ■ Cardiopulmonary Bypass (CPB)

### What is it?

Pump and oxygenation apparatus remove blood from SVC and IVC and return it to the aorta, bypassing the heart and lungs and allowing cardiac arrest for open-heart procedures, heart transplant, lung transplant, or heart–lung transplant as well as procedures on the proximal great vessels



### Is anticoagulation necessary?

Yes, just before and during the procedure, with heparin

### How is anticoagulation reversed?

Protamine

### What are the ways to manipulate cardiac output after CPB?

Rate, rhythm, afterload, preload, inotropes, mechanical (IABP and VAD)

### What mechanical problems can decrease CO after CPB?

Cardiac tamponade, pneumothorax

### What is “tamponade physiology”?

↓ Cardiac output, ↑ heart rate, hypotension, ↑ CVP = ↑ wedge pressure

**What are the possible complications?**

Trauma to formed blood elements (especially thrombocytopenia and platelet dysfunction)

Pancreatitis (low flow)

Heparin rebound

CVA

Failure to wean from bypass

Technical complications (operative technique)

MI

**What are the options for treating postop CABG mediastinal bleeding?**

Protamine, ↑ PEEP, FFP, platelets, aminocaproic acid

**What is “heparin rebound”?**

Increased anticoagulation after CPB from increased heparin levels, as increase in peripheral blood flow after CPB returns heparin residual that was in the peripheral tissues

**What are the options if a patient cannot be weaned from CPB?**

Inotropes (e.g., epinephrine)

VAD, IABP

**What is the workup of a postoperative patient with AFib?**

Rule out PTX (ABG, CT scan), acidosis (ABG), electrolyte abnormality (LABS), and ischemia (EKG), CXR

**What is a MIDCAB?**

**Minimally Invasive Direct Coronary Artery Bypass**—LIMA to LAD bypass without CPB and through a small thoracotomy

**What is TMR?**

**TransMyocardial laser Revascularization**: laser through groin catheter makes small holes (intramyocardial sinusoids) in cardiac muscle to allow blood to nourish the muscle

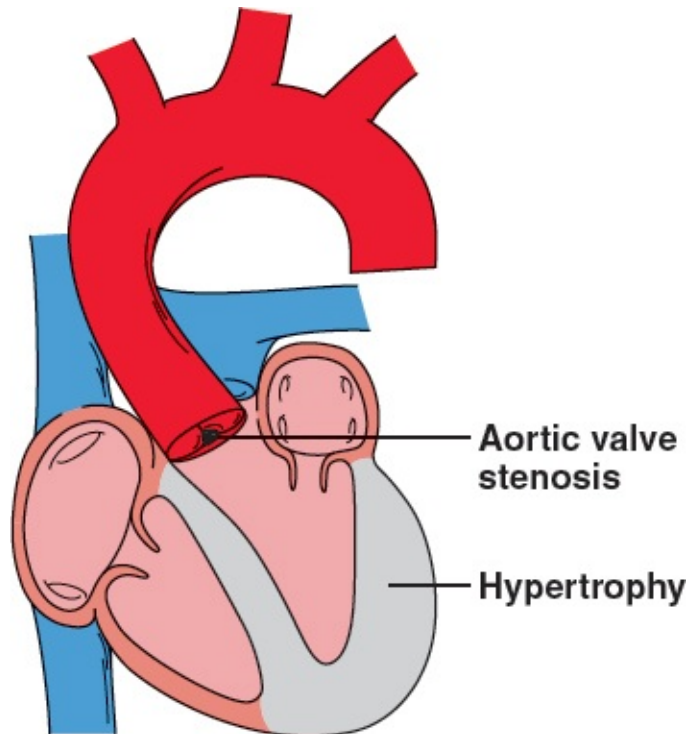
**What is OPCAB?**

**Off-Pump Coronary Artery Bypass**—median sternotomy but no bypass pump

## ■ Aortic Stenosis (AS)

### What is it?

Destruction and calcification of valve leaflets, resulting in obstruction of left ventricular outflow



### What are the causes?

Calcification of bicuspid aortic valve  
Rheumatic fever  
Acquired calcific AS (7th to 8th decades)

### What are the symptoms?

Angina (5 years life expectancy if left untreated)  
Syncope (3 years life expectancy if left untreated)  
CHF (2 years life expectancy if left untreated)  
Often asymptomatic until late

### What is the memory aid for the aortic stenosis complications?

**Aortic Stenosis Complications = Angina Syncope CHF—5,3,2**

**What are the signs?**

Murmur: crescendo-decrescendo systolic second right intercostal space with radiation to the carotids

Left ventricular heave or lift from left ventricular hypertrophy

**What tests should be performed?**

CXR, ECG, echocardiography

Cardiac catheterization—needed to plan operation

**What is the surgical treatment?**

Valve replacement with tissue or mechanical prosthesis

**What are the indications for surgical repair?**

If patient is symptomatic or valve cross-sectional area is  $<0.75 \text{ cm}^2$  (nl 2.5 to 3.5  $\text{cm}^2$ ) and/or gradient  $>50 \text{ mm Hg}$

**What are the pros/cons of mechanical valve?**

Mechanical valve is more durable, but requires lifetime anticoagulation

**What is the treatment option in poor surgical candidates?**

Balloon aortic “valvuloplasty” (percutaneous)

**Why is a loud murmur often a good sign?**

Implies a high gradient, which indicates preserved LV function

**Why might an AS murmur diminish over time?**

It may imply a decreasing gradient from a decline in LV function

## **Aortic Insufficiency (AI)**

**What is it?**

Incompetency of the aortic valve (regurgitant flow)

**What are the causes?**

Bacterial endocarditis (*Staphylococcus aureus*, *Streptococcus viridans*)  
Rheumatic fever (rare)  
Annular ectasia from collagen vascular disease (especially Marfan's syndrome)

### **What are the predisposing conditions?**

Bicuspid aortic valve, connective tissue disease

### **What are the symptoms?**

Palpitations from dysrhythmias and dilated left ventricle  
Dyspnea/orthopnea from left ventricular failure  
Excess fatigue  
Angina from ↓ diastolic BP and coronary flow (**Note:** Most coronary blood flow occurs during diastole and aorta rebound)  
Musset sign (bobble-head)

### **What are the signs?**

↑ diastolic BP  
Murmur: blowing, decrescendo diastolic at left sternal border  
Austin–Flint murmur: reverberation of regurgitant flow  
Increased pulse pressure: “pistol shots,” “water-hammer” pulse palpated over peripheral arteries  
Quincke sign (capillary pulsations of uvula)

### **Which diagnostic tests should be performed?**

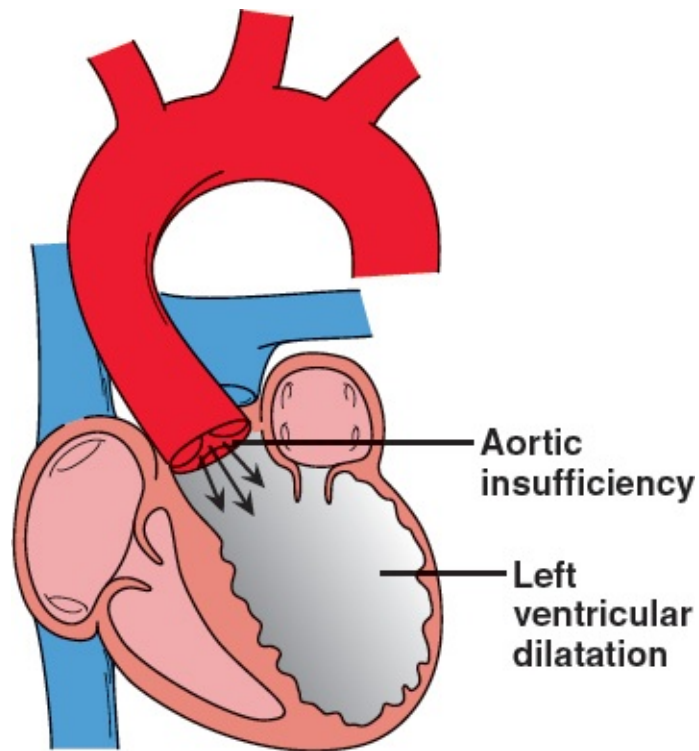
- . CXR: increasing heart size can be used to follow progression
- . Echocardiogram
- . Catheterization (definitive)
- . TEE

### **What is the treatment?**

Aortic valve replacement

### **What are the indications for surgical treatment?**

Symptomatic patients (CHF, PND, etc.), left ventricle dilatation, decreasing LV function, decreasing EF, acute AI onset



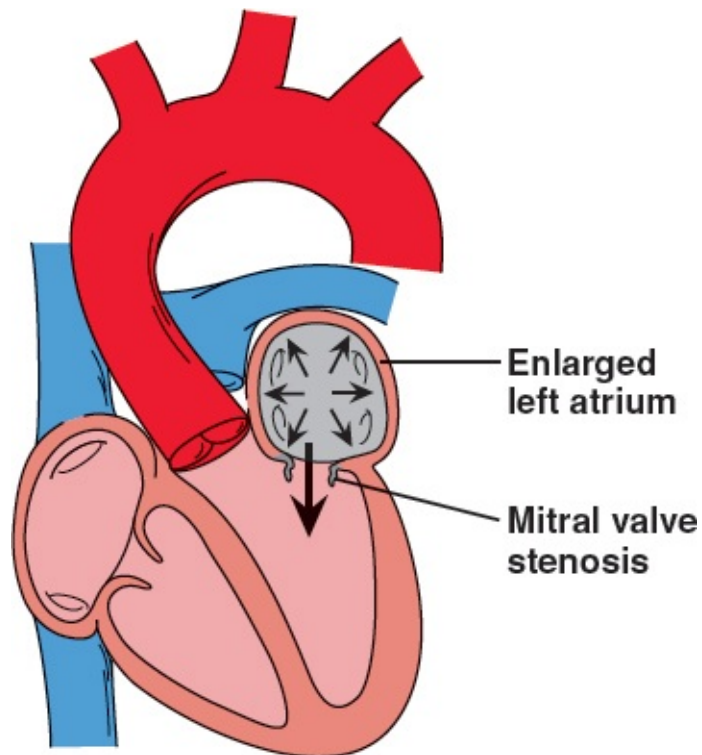
### **What is the prognosis?**

Surgery gives symptomatic improvement and may improve longevity; low operative risk

## **■ Mitral Stenosis (MS)**

### **What is it?**

Calcific degeneration and narrowing of the mitral valve resulting from rheumatic fever in most cases



### **What are the symptoms?**

- . Dyspnea from increased left atrial pressure, causing pulmonary edema (i.e., CHF)
- . Hemoptysis (rarely life-threatening)
- . Hoarseness from dilated left atrium impinging on the recurrent laryngeal nerve
- . Palpations (AFib)

### **What are the signs?**

Murmur: crescendo diastolic rumble at apex

Irregular pulse from AFib caused by dilated left atrium

Stroke caused by systemic emboli from left atrium (AFib and obstructed valve allow blood to pool in the left atrium and can lead to thrombus formation)

### **Which diagnostic tests should be performed?**

Echocardiogram

Catheterization

### **What are the indications for intervention?**

- . Symptoms (severe)
- . Pulmonary HTN and mitral valve area  $<1 \text{ cm}^2/\text{m}^2$

- . Recurrent thromboembolism

### **What are the treatment options?**

- . Open commissurotomy (open heart operation)
- . Balloon valvuloplasty: percutaneous
- . Valve replacement

### **What is the medical treatment for mild symptomatic patients?**

Diuretics

### **What is the prognosis?**

>80% of patients are well at 10 years with successful operation

## **Mitral Regurgitation (MR)**

### **What is it?**

Incompetence of the mitral valve

### **What are the causes?**

Severe mitral valve prolapse (some prolapse is found in 5% of the population, with women  $\geq$  men)

Rheumatic fever

Post-MI from papillary muscle dysfunction/rupture

Ruptured chordae

### **What are the most common causes?**

Rheumatic fever (#1 worldwide), ruptured chordae/papillary muscle dysfunction

### **What are the symptoms?**

Often insidious and late: dyspnea, palpitations, fatigue

### **What are the signs?**

Murmur: holosystolic, apical radiating to the axilla

### **What are the indications for treatment?**

- . Symptoms

- . LV >45 mm end-systolic dimension (left ventricular dilation)

### **What is the treatment?**

- . Valve replacement
- . Annuloplasty: suture a prosthetic ring to the dilated valve annulus

## **Artificial Valve Placement**

### **What is it?**

Replacement of damaged valves with tissue or mechanical prosthesis

### **What are the types of artificial valves?**

Tissue and mechanical

### **What are the pros and cons:**

#### **Tissue?**

NO anticoagulation but shorter duration (20% to 40% need replacement in 10 years); good for elderly

#### **Mechanical?**

Last longer (>15 years) but require ANTICOAGULATION

#### **Contraindications for tissue valve?**

Dialysis (calcify), youth

#### **Contraindications for mechanical valve?**

Pregnancy (or going to be pregnant due to anticoagulation), bleeding risk (alcoholic, PUD)

### **What is the operative mortality?**

From 1% to 5% in most series

### **What must patients with an artificial valve receive before dental procedures?**

Antibiotics

## What is the Ross procedure?

Aortic valve replacement with a pulmonary **autograft** (i.e., patient's own valve!)

## ■ Infectious Endocarditis

### What is it?

Microbial infection of heart valves

### What are the predisposing conditions?

Pre-existing valvular lesion, procedures that lead to bacteremia, IV drug use

### What are the common causative agents?

*S. viridans*: associated with abnormal valves

*S. aureus*: associated with IV drug use

*S. epidermidis*: associated with prosthetic valves

### What are the signs/symptoms?

Murmur (new or changing)

Petechiae

Splinter hemorrhage (fingernails)

Roth spots (on retina)

Osler nodes (raised, **painful** on soles and palms; **Osler** = **Ouch!**)

Janeway lesions (similar to Osler nodes, but flat and **painless**) (Jane **WAY** = pain a**WAY**)

### Which diagnostic tests should be performed?

Echocardiogram, TEE

Serial blood cultures (definitive)

### What is the treatment?

Prolonged IV therapy with bactericidal antibiotics to which infecting organisms are sensitive

### What is the prognosis?

Infection can progress, requiring valve replacement

# CONGENITAL HEART DISEASE

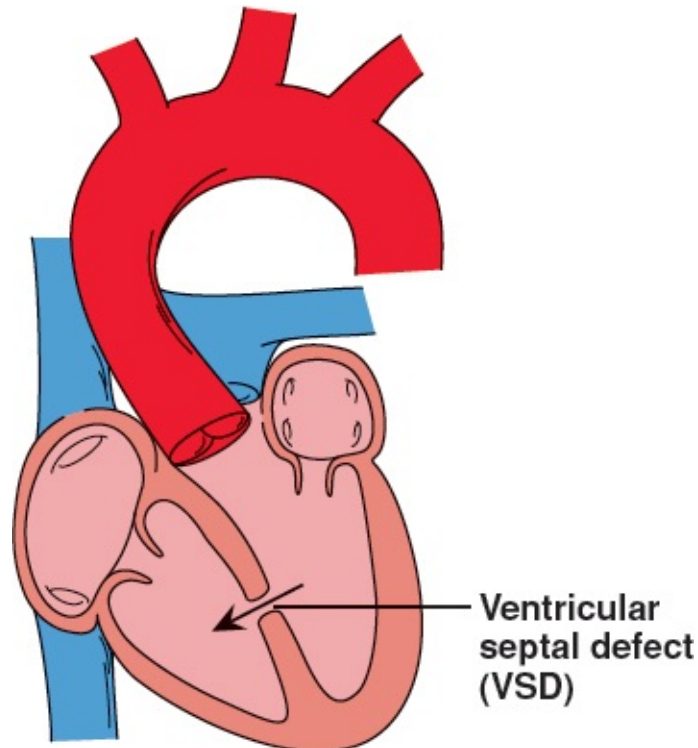
## Ventricular Septal Defect (VSD)

### What is its claim to fame?

Most common congenital heart defect

### What is it?

Failure of ventricular septum to completely close; **80% of cases involve the membranous portion of the septum**, resulting in left-to-right shunt, increased pulmonary blood flow, and CHF if pulmonary to systemic flow is  $>2:1$



### What is pulmonary vascular obstructive disease?

Pulmonary artery hyperplasia from increased pulmonary pressure caused by a left-to-right shunt (e.g., VSD)

### What is Eisenmenger's syndrome?

Irreversible pulmonary HTN from chronic changes in pulmonary arterioles and increased right heart pressures; cyanosis develops when the shunt reverses

(becomes right to left across the VSD)

### **What is the treatment of Eisenmenger's syndrome?**

Only option is heart–lung transplant; otherwise, the disease is untreatable

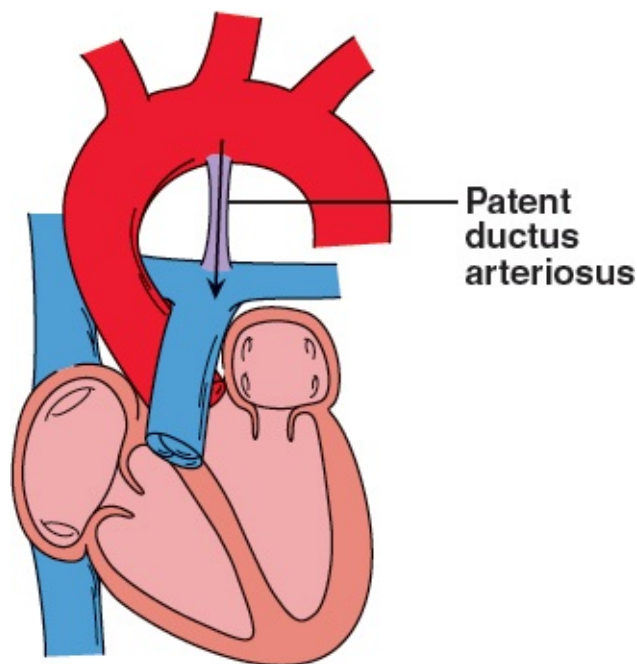
### **What is the incidence of VSD?**

30% of heart defects (most common defect)

## **■ Patent Ductus Arteriosus (PDA)**

### **What is it?**

Physiologic right-to-left shunt in fetal circulation connecting the pulmonary artery to the aorta bypassing fetal lungs; often, this shunt persists in the neonate



### **What are the factors preventing closure?**

Hypoxia, increased prostaglandins, prematurity

### **What are the symptoms?**

Often asymptomatic

Poor feeding

Respiratory distress

CHF with respiratory infections

### **What are the signs?**

Acyanotic, unless other cardiac lesions are present; continuous “machinery” murmur

### **Which diagnostic tests should be performed?**

Physical examination

Echocardiogram (to rule out associated defects)

Catheter (seldom required)

### **What is the medical treatment?**

Indomethacin is an NSAID: prostaglandin (PG) inhibitor (PG keeps PDA open)

### **What is the surgical treatment?**

Surgical ligation or cardiac catheterization closure at 6 months to 2 years of age

## **Tetralogy of Fallot (TOF)**

### **What is it?**

Misalignment of the infundibular septum in early development, leading to the characteristic tetrad:

1. Pulmonary stenosis/obstruction of right ventricular outflow
2. Overriding aorta
3. Right ventricular hypertrophy
4. VSD

### **What are the symptoms?**

Hypoxic spells (squatting behavior increases SVR and increases pulmonary blood flow)

### **What are the signs?**

Cyanosis

Clubbing

Murmur: SEM at left third intercostal space

**Which diagnostic tests should be performed?**

CXR: small, “boot-shaped” heart and decreased pulmonary blood flow  
Echocardiography

**What is the prognosis?**

95% survival at specialized centers

## ■ IHSS

**What is IHSS?**

Idiopathic **H**ypertrophic Subaortic Stenosis

**What is it?**

Aortic outflow obstruction from septal tissue

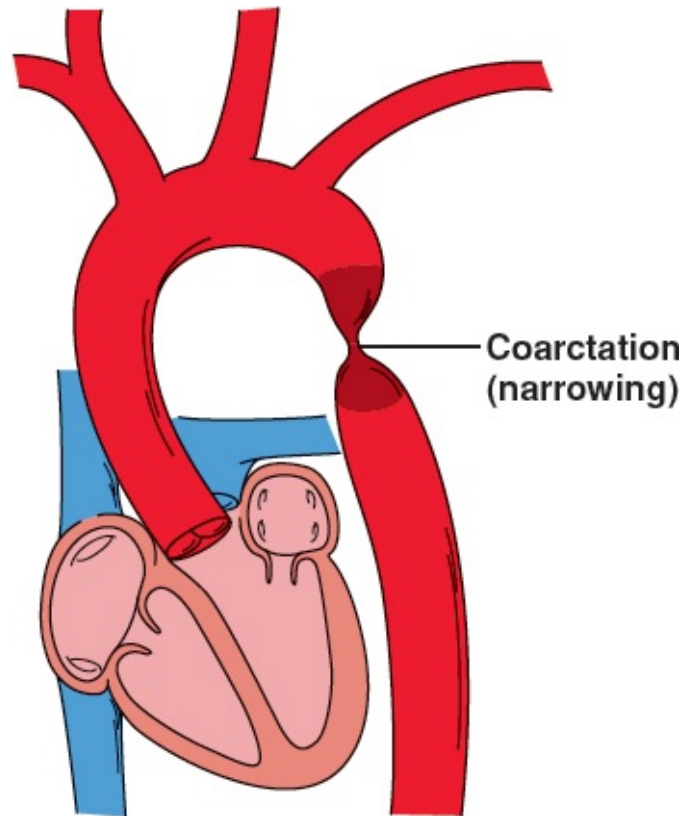
**What is the usual presentation?**

Similar to aortic stenosis

## ■ Coarctation of the Aorta

**What is it?**

Narrowing of the thoracic aorta, with or without intraluminal “shelf” (infolding of the media); usually found near ductus/ligamentum arteriosum



### **What are the three types?**

- . Preductal (fatal in infancy if untreated)
- . Juxtaductal
- . Postductal

### **What percentage are associated with other cardiac defects?**

60% (bicuspid aortic valve is most common)

### **What is the major route of collateral circulation?**

Subclavian artery to the IMA to the intercostals to the descending aorta

### **What are the risk factors?**

Turner's syndrome, male > female

### **What are the symptoms?**

Headache

Epistaxis

Lower extremity fatigue → claudication

## **What are the signs?**

Pulses: decreased lower extremity pulses

Murmurs:

1. Systolic—from turbulence across coarctation, often radiating to infrascapular region
2. Continuous—from dilated collaterals

## **Which diagnostic tests should be performed?**

CXR: “3” sign is aortic knob, coarctation, and dilated poststenotic aorta; rib notching is bony erosion from dilated intercostal collaterals

Echocardiogram

Cardiac catheterization if cardiac defects

## **What is the treatment?**

Surgery:

Resection with end-to-end anastomosis

Subclavian artery flap

Patch graft (rare)

Interposition graft

Endovascular repair an option in adults

## **What are the indications for surgery?**

Symptomatic patient

Asymptomatic patient >3 to 4 years

## **What are the possible postoperative complications?**

Paraplegia

“Paradoxic” HTN

Mesenteric necrotizing panarteritis (GI bleeding), Horner’s syndrome, injury to recurrent laryngeal nerve

# **Transposition of the Great Vessels**

## **What is it?**

Aorta originates from the right ventricle and the pulmonary artery from the left ventricle; fatal without PDA, ASD, or VSD—to allow communication between

the left and right circulations

### **What is the incidence?**

From 5% to 8% of defects

### **What are the signs/symptoms?**

Most common lesion that presents with cyanosis and CHF in neonatal period (>90% by day 1)

### **Which diagnostic tests should be performed?**

CXR: “egg-shaped” heart contour

Catheterization (definitive)

### **What is the treatment?**

Arterial switch operation—aorta and pulmonary artery are moved to the correct ventricle and the coronaries are reimplanted

## **Ebstein's Anomaly**

### **What is it?**

Tricuspid valve is placed abnormally low in the right ventricle, forming a large right atrium and a small right ventricle, leading to tricuspid regurgitation and decreased right ventricular output

### **What are the signs/symptoms?**

Cyanosis

### **What are the risk factors?**

400× the risk if the mother has taken lithium

## **Vascular Rings**

### **What are they?**

Many types; represent an anomalous development of the aorta/pulmonary artery

from the embryonic aortic arch that surrounds and obstructs the trachea/esophagus

### **How are they diagnosed?**

Barium swallow, MRI

### **What are the signs/symptoms?**

Most prominent is stridor from tracheal compression

## **Cyanotic Heart Disease**

### **What are the causes?**

“Five T’s” of cyanotic heart disease:

1. Tetralogy of Fallot
2. Truncus arteriosus
3. Totally anomalous pulmonary venous return (TAPVR)
4. Tricuspid atresia
5. Transposition of the great vessels

## **CARDIAC TUMORS**

### **What is the most common benign lesion?**

Myxoma in adults

### **What is the most common location?**

Left atrium with pedunculated morphology

### **What are the signs/symptoms?**

Dyspnea, emboli

### **What is the most common malignant tumor in children?**

Rhabdomyosarcoma

## **DISEASES OF THE GREAT VESSELS**

## ■ Thoracic Aortic Aneurysm

### **What is the cause?**

Vast majority result from atherosclerosis, connective tissue disease

### **What is the major differential diagnosis?**

Aortic dissection

### **What percentage of patients have aneurysms of the aorta at a different site?**

≈33%! (Rule out AAA)

### **What are the signs/symptoms?**

Most are asymptomatic

Chest pain, stridor, hemoptysis (rare), recurrent laryngeal nerve compression

### **How is it most commonly discovered?**

Routine CXR

### **Which diagnostic tests should be performed?**

CXR, CT scan, MRI, aortography

### **What are the indications for treatment?**

>6 cm in diameter

Symptoms

Rapid increase in diameter

Rupture

### **What is the treatment?**

Replace with graft, open or endovascular stent

### **What are the dreaded complications after treatment of a thoracic aortic aneurysm?**

Paraplegia (up to 20%)

Anterior spinal syndrome

### **What is anterior spinal syndrome?**

Syndrome characterized by:

Paraplegia

Incontinence (bowel/bladder)

Pain and temperature sensation loss

### **What is the cause?**

Occlusion of the great radicular artery of **Adamkiewicz**, which is one of the intercostal/lumbar arteries from T8 to L4

## **Aortic Dissection**

### **What is it?**

Separation of the walls of the aorta from an intimal tear and disease of the tunica media; a false lumen is formed and a “reentry” tear may occur, resulting in “double-barrel” aorta

### **What are the aortic dissection classifications?**

DeBakey classification

Stanford classification

### **Define the Stanford classifications:**

#### **Type A**

Ascending aorta (requires surgery)

±Descending aorta (includes DeBakey types I and II)



### **Type B**

Descending aorta only (nonoperative, except for complications) (same as DeBakey type III)



### **What is the etiology?**

HTN (most common)  
Marfan's syndrome  
Bicuspid aortic valve  
Coarctation of the aorta  
Cystic medial necrosis  
Proximal aortic aneurysm

### **What are the signs/symptoms?**

**Abrupt onset of severe chest pain, most often radiating/“tearing” to the back;** onset is typically more abrupt than that of MI; the pain can migrate as the dissection progresses; patient describes a **“tearing pain”**

### **What are three other sequelae?**

- . Cardiac tamponade; Beck's triad— distant heart sounds, ↑ CVP with JVD, ↓ BP
- . Aortic insufficiency—diastolic murmur
- . Aortic arterial branch occlusion/shearing, leading to ischemia in the involved circulation (i.e., unequal pulses, CVA, paraplegia, renal insufficiency, bowel ischemia, claudication)

## **Which diagnostic tests are indicated?**

CXR:

1. Widened mediastinum
2. Pleural effusion

TEE

CTA (CT angiography)

## **What is the treatment of the various types:**

### **Stanford type A?**

Surgical because of risk of:

1. Aortic insufficiency
2. Compromise of cerebral and coronary circulation
3. Tamponade
4. Rupture

### **Stanford type B?**

Medical (control BP), unless complicated by rupture or significant occlusions

## **How is the surgery for an aortic dissection (Stanford A) done?**

Open the aorta at the proximal extent of dissection, and then sew—graft to—intimal flap and adventitia circumferentially (endovascular an option)

## **What is the preoperative treatment?**

Control BP with sodium nitroprusside and  $\beta$ -blockers (e.g., esmolol);  $\beta$ -blockers decrease shear stress

## **What is the postoperative treatment?**

Lifetime control of BP and monitoring of aortic size

## **What is the possible cause of MI in a patient with aortic dissection?**

Dissection involves the coronary arteries or underlying LAD

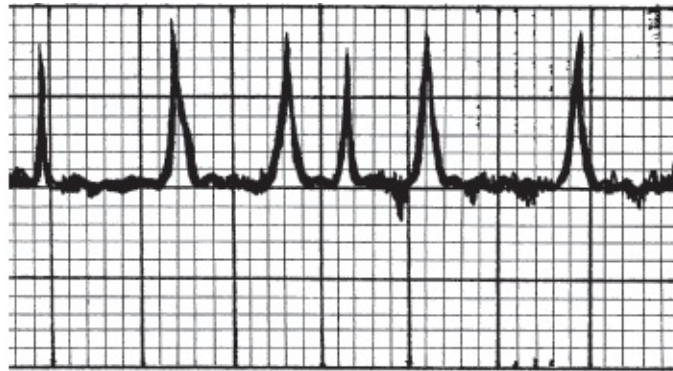
## **What is a dissecting aortic aneurysm?**

Misnomer! Not an aneurysm!

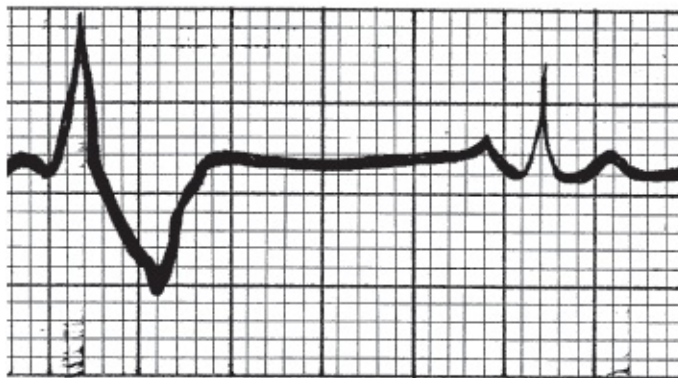
**What are the EKG signs of the following disorders:**

**Atrial fibrillation?**

Irregularly irregular

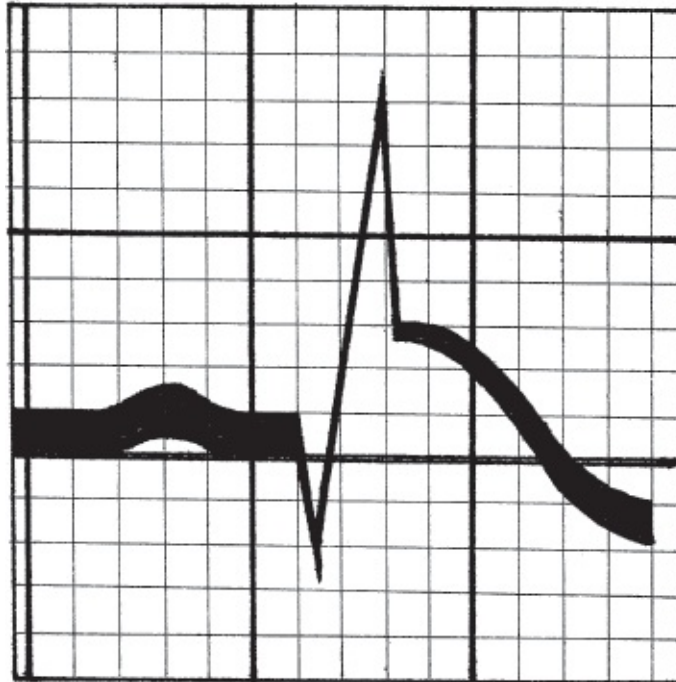


Premature Ventricular Complex: Wide QRS



**PVC?**

Premature Ventricular Complex: Wide QRS



**Ventricular aneurysm?**

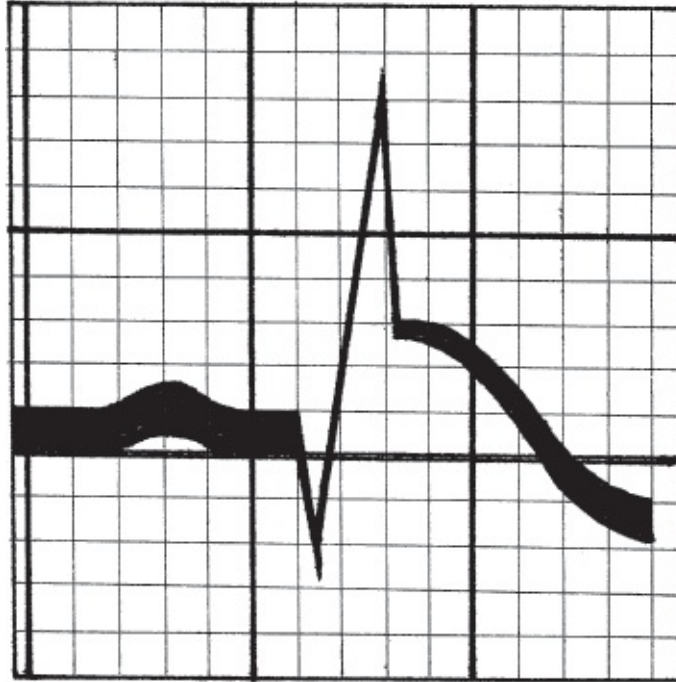
ST elevation

**Ischemia?**

ST elevation/ST depression/flipped T waves

**Infarction?**

Q waves



### **Pericarditis?**

ST elevation throughout leads

### **RBBB?**

Right **B**undle **B**ranch **B**lock: wide QRS and “rabbit ears” or R-R in V1 or V2

### **LBBB?**

Left **B**undle **B**ranch **B**lock: wide QRS and “rabbit ears” or R-R in V5 or V6

### **Wolff–Parkinson–White?**

Delta wave = slurred upswing on QRS

### **First-degree A-V block?**

Prolonged P-R interval (0.2 second)

### **Second-degree A-V block?**

Dropped QRS; not all P waves transmit to produce ventricular contraction

### **Wenckebach phenomenon?**

Second-degree block with progressive delay in P-R interval prior to dropped beat

### **Third-degree A-V block?**

Complete A-V dissociation; random P wave and QRS

## **MISCELLANEOUS**

### **What is Mondor's disease?**

Thrombophlebitis of the thoracoepigastric veins

### **What is a VAD?**

Ventricular Assist Device

### **How does an IABP work?**

IntraAortic Balloon Pump has a balloon tip resting in the aorta

Balloon inflates in diastole, increasing diastolic BP and coronary blood flow; in systole the balloon deflates, creating a negative pressure, lowering afterload, and increasing systolic BP

## **RAPID FIRE REVIEW**

### **What is the correct diagnosis?**

**Chest pain "tearing" to the back**

Aortic dissection

**Chest pain described as "an elephant sitting on my chest"**

Myocardial infarction

### **Name the most likely diagnosis:**

**45-year-old female with CHF, diastolic murmur, atrial fibrillation, atrial hypertrophy**

Mitral stenosis

**15-year-old male with hypertension, lower extremity fatigue, and notching ("scalloping") of ribs on chest x-ray**

Aortic coarctation

**20-year-old male presents with ice pick to his left chest,  
hypotension, JVD, decreased muffled heart sounds**

Cardiac tamponade

# Chapter 72 Transplant Surgery

**Define the following terms:**

**Autograft**

Same individual is both donor and recipient

**Isograft**

Donor and recipient are genetically identical (identical twins)

**Allograft**

Donor and recipient are genetically dissimilar, but of the same species (e.g., human to human)

**Orthotopic**

Donor organ is placed in normal anatomic position (liver, heart)

**Heterotopic**

Donor organ is placed in a different site than the normal anatomic position (kidney, pancreas)

**Paratopic**

Donor organ is placed close to original organ

**Chimerism**

Sharing cells between the graft and donor (thus, immunosuppression is minimal or not required)

## BASIC IMMUNOLOGY

**What are histocompatibility antigens?**

Distinct (genetically inherited) cell surface proteins of the human leukocyte

antigen (HLA) system

### **Why are they important?**

They are targets (class I antigens) and initiators (class II antigens) of immune response to donor tissue (i.e., distinguishing self from nonself)

### **Which cells have class I antigens?**

All nucleated cells (Think: class **1** = **ALL** cells and thus “**ONE** for **ALL**”)

### **Which cells have class II antigens?**

Macrophages, monocytes, B cells, activated T cells, endothelial cells

### **What are the gene products of MHC called in humans?**

**HLA** (Human Leukocyte Antigen)

## **IMMUNOSUPPRESSION**

### **What are the major drugs used for immunosuppression?**

Triple therapy: corticosteroids, azathioprine, cyclosporine/tacrolimus

### **What are the other drugs?**

OKT3, ATGAM, mycophenolate

### **What is the advantage of “triple therapy”?**

Employs three immunosuppressive drugs; therefore, a lower dose of each can be used, decreasing the toxic side effects of each

### **What is “induction therapy”?**

High doses of immunosuppressive drugs to “induce” immunosuppression

## **Corticosteroids**

### **Which is most commonly used in transplants?**

Prednisone

**How does it function?**

Primarily blocks production of IL-1 by macrophage and stabilizes lysosomal membrane of macrophage

**What is the associated toxicity?**

“Cushingoid,” alopecia, striae, HTN, diabetes, pancreatitis, ulcer disease, osteomalacia, aseptic necrosis (especially of the femoral head)

**What is the relative potency of the following corticosteroids:****Cortisol?**

1

**Prednisone?**

4

**Methylprednisolone?**

5

**Dexamethasone?**

25

 **Azathioprine (Aza [Imuran®])****How does it function?**

Prodrug that is cleaved into mercaptopurine; inhibits synthesis of DNA and RNA, leading to decreased cellular (T/B cells) production

**What is the associated toxicity?**

Toxic to bone marrow (leukopenia + thrombocytopenia), hepatotoxic, associated with pancreatitis

**When should a lower dose of AZA be administered?**

When WBC is <4

**What is the associated drug interaction?**

Decrease dose if patient is also on allopurinol, because allopurinol inhibits the enzyme xanthine oxidase, which is necessary for the breakdown of azathioprine

## ■ Cyclosporine (CSA)

### **What is its function?**

“Calcineurin inhibitor” inhibits production of IL-2 by Th cells

### **What is the associated toxicity?**

Toxicity for cyclosporine includes the “**11 H’s and 3 N’s**”: **H**epatitis, **H**ypertrichosis, gingival **H**yperplasia, **H**yperlipidemia (worse than FK), **H**yperglycemia, **H**ypertension (worse than FK), **H**emolytic uremic syndrome, **H**yperkalemia, **H**ypercalcemia, **H**ypomagnesemia, **H**yperuricemia, **N**ephrotoxicity, **N**eurotoxicity (headache, tremor), **N**eoplasia (lymphoma, KS, squamous cell skin cancers)

### **What drugs decrease CSA levels?**

By inducing the p450 system: dilantin, Tegretol®, rifampin, isoniazid, barbiturates

### **What are the drugs of choice for HTN from CSA?**

Clonidine, calcium channel blockers

## ■ ATGAM/Antithymocyte Globulin

### **How does it function?**

Antibody against thymocytes, lymphocytes (polyclonal)

### **When is it typically used?**

For induction

### **What is the associated toxicity?**

Thrombocytopenia, leukopenia, serum sickness, rigors, fever, anaphylaxis, increased risk of viral infection, arthralgia

## ■ OKT3

### **How does it work?**

MONOclonal antibody that binds CD3 receptor (on T cells)

### **What is a major problem with multiple doses?**

Blocking antibodies develop, and OKT3 is less effective each time it is used

### **What are basiliximab and daclizumab?**

Anti-CD25 monoclonal antibodies

## ■ Tacrolimus

### **What is tacrolimus also known as?**

Prograf® (FK506)

### **How does it work?**

Similar to CSA—"calcineurin inhibitor," blocks IL-2 receptor expression, inhibits T cells

### **What is its potency compared to CSA?**

100× more potent than CSA

### **What are its side effects?**

Nephrotoxicity and CNS toxicity (tremor, seizure, paresthesia, coma), hyperkalemia, alopecia, diabetes

## ■ Sirolimus

### **What is sirolimus also known as?**

Rapamycin, Rapamune®

### **How does it work?**

Like CSA and tacrolimus, it does not bind to and inhibit calcineurin; rather, it blocks T-cell signaling

### **Toxicity?**

Hypertriglyceridemia, thrombocytopenia, wound/healing problems, anemia, oral ulcers

## **Mycophenolate Mofetil (MMF)**

### **What is MMF also known as?**

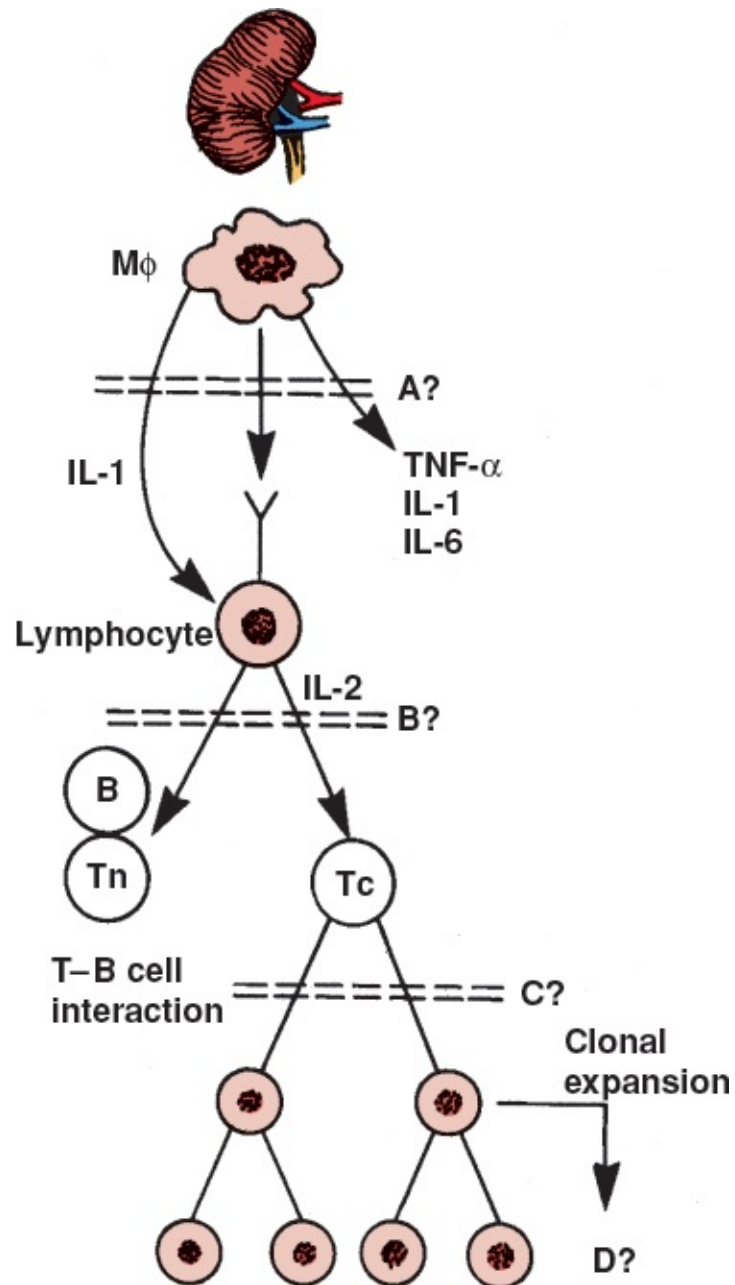
CellCept®

### **How does it work?**

Inhibitor of inosine monophosphate dehydrogenase required for de novo purine synthesis, which expanding T and B cells depend on; also inhibits adhesion molecule and antibody production

## **OVERVIEW OF IMMUNOSUPPRESSION MECHANISMS**

**What drug acts at the following sites:**



A?

Corticosteroids

B?

CSA/tacrolimus

C?

AZA/MMF

D?

OKT3/ATGAM

## MATCHING OF DONOR AND RECIPIENT

**How is ABO crossmatching performed?**

Same procedure as in blood typing

**What is the purpose of lymphocytotoxic crossmatching?**

Tests for HLA antibodies in serum; most important in kidney and pancreas transplants

**How is the test performed?**

Mix recipient serum with donor lymphocyte and rabbit complement

**Is HLA crossmatching important?**

Yes, for kidney and pancreas transplants

## REJECTION

**How many methods of rejection are there?**

2: humoral and cell-mediated

**Name the four types of rejection and their associated time courses.**

- . Hyperacute—immediate in O.R.
- . Accelerated acute—7 to 10 days posttransplant
- . Acute—weeks to months posttransplant
- . Chronic—months to years posttransplant

**What happens in hyperacute rejection?**

Antigraft antibodies in recipient recognize foreign antigen immediately after blood perfuses transplanted organ

**What happens in acute rejection?**

T cell-mediated rejection

**What type of rejection is responsible for chronic rejection?**

Cellular, antibody (humoral), or both

**What is the treatment of hyperacute rejection?**

Remove transplanted organ

**What is the treatment of acute rejection?**

High-dose steroids/OKT3

**What is the treatment of chronic rejection?**

Not much (irreversible) or retransplant

## ORGAN PRESERVATION

**What is the optimal storage temperature of an organ?**

4°C—keep on ice in a cooler

**Why should it be kept cold?**

Cold decreases the rate of chemical reactions; decreased energy use minimizes effects of hypoxia and ischemia

**What is U-W solution?**

University of Wisconsin solution; used to perfuse an organ prior to removal from the donor

**What is in it?**

Potassium phosphate, buffers, starch, steroids, insulin, electrolytes, adenosine

**Why should it be used?**

Lengthens organ preservation time

## MAXIMUM TIME BETWEEN HARVEST AND TRANSPLANT OF ORGAN

**Heart?**

6 hours

**Lungs?**

6 hours

**Pancreas?**

24 hours

### **Liver?**

24 hours

### **Kidney?**

Up to 72 hours

## **KIDNEY TRANSPLANT**

**In what year was the first transplant performed in man?**

1954

### **By whom?**

Joseph E. Murray—1990 Nobel Prize winner in Medicine

**What is the most common cause for kidney transplant?**

**Diabetes** (25%)

## **Statistics**

**What are the sources of donor kidneys?**

Deceased donor (70%)

Living related donor (LRD; 30%)

**What survival rate is associated with deceased donor source?**

90% at 1 year if HLA matched; 80% at 1 year if not HLA matched; 75% graft survival at 3 years

**What survival rate is associated with LRD?**

95% patient survival at 1 year; 75% to 85% graft survival at 3 years

**What are the tests for compatibility?**

ABO, HLA typing

**If a choice of left or right donor kidney is available, which is preferred?**

Left—longer renal vein allows for easier anastomosis

**Should the placement of the kidney be hetero- or orthotopic?**

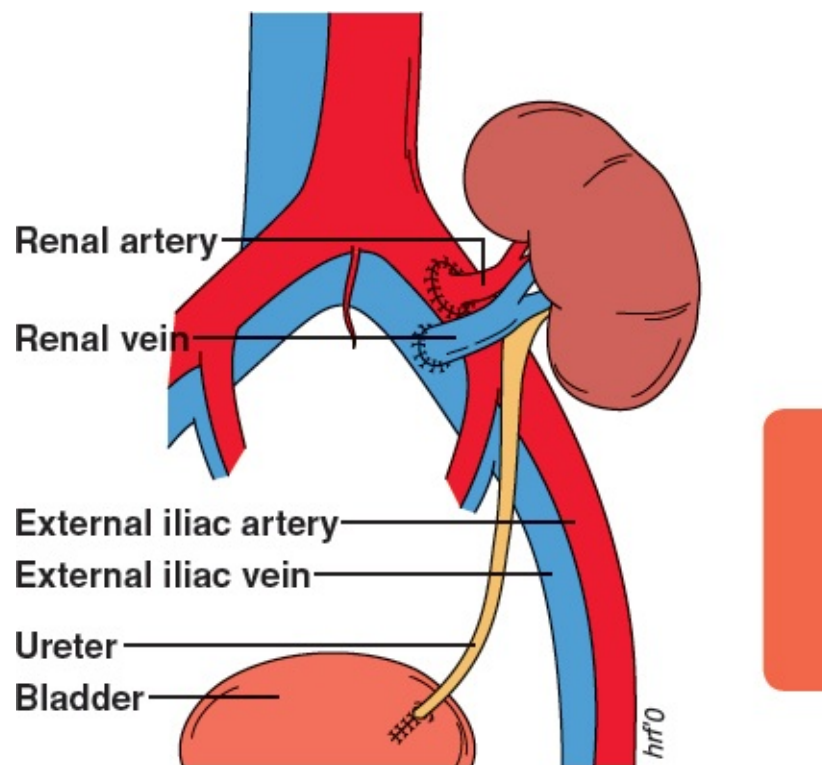
Heterotopic—retroperitoneal in the RLQ or LLQ above the inguinal ligament

**Why?**

Preserves native kidneys, allows easy access to iliac vessels, places ureter close to the bladder, easy to biopsy kidney

**Define anastomoses of a heterotopic kidney transplant**

- . Renal artery to iliac artery
- . Renal vein to iliac vein
- . Ureter to bladder



**What is the correct placement of the ureter?**

Submucosally through the bladder wall—decreases reflux

**What is the differential diagnosis of post-renal transplant fluid**

**collection?**

**“HAUL”:**

Hematoma

Abscess

Urinoma

Lymphocele

**Why keep native kidneys?**

Increased morbidity if they are removed

**What is the indication for removal of native kidneys?**

Uncontrollable HTN, ongoing renal sepsis

## ■ Rejection

**What is the red flag that indicates rejection?**

↑ creatinine

**What is the differential diagnosis of increased creatinine?**

Remember: “-TION”—obstrucTION, dehydraTION, infecTION, intoxicaTION (CSA); plus lymphocele, ATN

**What are the signs/symptoms?**

Fever, malaise, HTN, ipsilateral leg edema, pain at transplant site, oliguria

**What is the workup for the following tests:**

**U/S with Doppler?**

Look for fluid collection around the kidney, hydronephrosis, flow in vessels

**Radionuclide scan?**

Look at flow and function

**Biopsy?**

Distinguish between rejection and cyclosporine toxicity

# LIVER TRANSPLANT

## **Who performed the first liver transplant?**

Thomas Starzl (1963)

## **What is the MELD score?**

“**M**odel for **E**nd Stage **L**iver **D**isease” is the formula currently used to assign points for prioritizing position on the waiting list for deceased donor liver transplant; based on INR, bilirubin, and creatinine with extra points given for the presence of liver cancer

## **What is the test for compatibility?**

ABO typing

## **What is the placement?**

Orthotopic

## **What are the options for biliary drainage?**

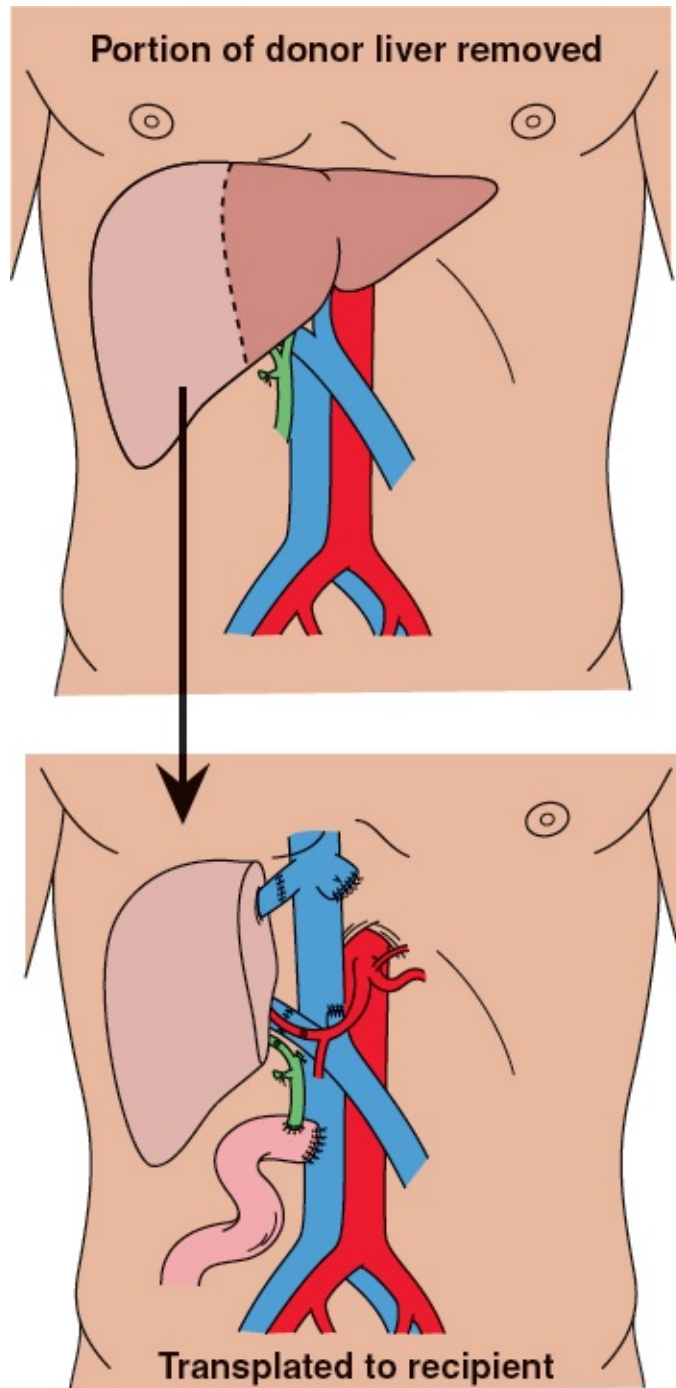
- . Donor common bile to recipient common bile duct end to end
- . Roux-en-Y choledochojejunostomy

## **What is the “piggyback” technique?**

Recipient vena cava is left in place; the donor infrahepatic IVC is oversewn; the donor superior IVC is anastomosed onto a cuff made from the recipient hepatic veins (allows for greater hemodynamic stability of the recipient during OLT)

## **How does Living Donor Liver Transplantation (LDLT) work?**

Adult donates a left lateral segment to a child or an adult donates a right lobe to another adult



### **What is a split liver transplant?**

Deceased donor liver is harvested and divided into two “halves” for two recipients

## **■ Rejection**

---

### **What are the red flags indicating rejection?**

Decreased bile drainage, increased serum bilirubin, increased LFTs

### **What is the site of rejection?**

Rejection involves the biliary epithelium first, and later, the vascular endothelium

### **What is the workup with the following tests:**

#### **U/S with Doppler?**

Look at flow in portal vein, hepatic artery; rule out thrombosis, leaky anastomosis, infection (abscess)

#### **Cholangiogram?**

Look at bile ducts

#### **Biopsy?**

Especially important 3 to 6 weeks postoperatively, when CMV is of greatest concern

#### **Does hepatorenal syndrome renal function improve after liver transplant?**

Yes

## **Survival Statistics**

### **What is the 1year survival rate?**

≈80% to 85%

## **PANCREAS TRANSPLANT**

### **What are the indications?**

Type I (juvenile) diabetes mellitus associated with severe complications (renal failure, blindness, neuropathy) or very poor glucose control

**What are the tests for compatibility?**

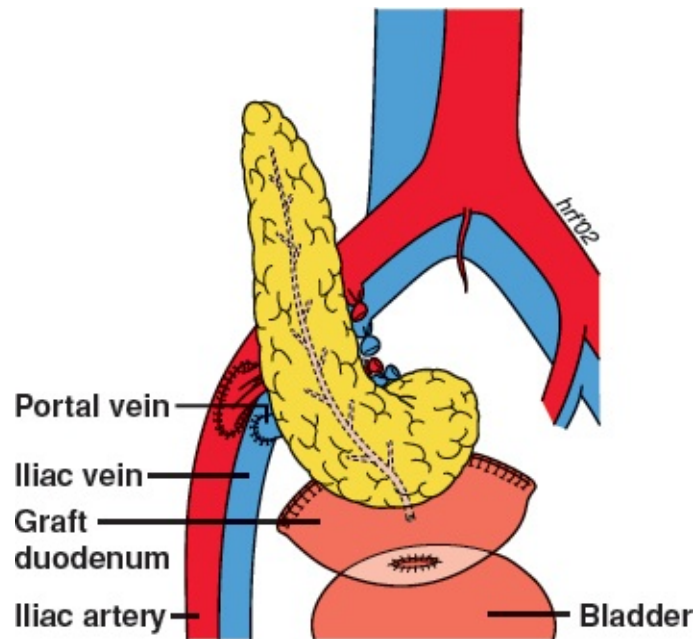
ABO, DR matching (class II)

**What is the placement?**

Heterotopic, in iliac fossa, or paratopic

**Where is anastomosis of the exocrine duct in heterotopic placement?**

To the bladder

**Why?**

Measures the amount of amylase in urine, gives an indication of pancreatic function (i.e., high urine amylase indicates good pancreatic function)

**What is the associated electrolyte complication?**

Loss of bicarbonate

**What are the most common complications after pancreas transplant?**

Thrombosis (#1), rejection

**Where is anastomosis of the exocrine duct in paratopic placement?**

To the jejunum

**Why?**

It is close by and physiologic

**What is the advantage of paratopic placement?**

Endocrine function drains to the portal vein directly to the liver, and pancreatic contents stay within the GI tract (no need to replace bicarbonate)

**What are the red flags indicating rejection?**

Hyperamylasemia, hyperglycemia, hypoamylasuria, graft tenderness

**Why should the kidney and pancreas be transplanted together?**

Kidney function is a better indicator of rejection; also better survival of graft is associated with kidney-pancreas transplant than pancreas alone

**Why is hyperglycemia not a good indicator for rejection surveillance?**

Hyperglycemia appears relatively late with pancreatic rejection

## HEART TRANSPLANT

**Who performed the first heart transplant?**

Christiaan Barnard (1967)

**What are the indications?**

Age birth to 65 years with terminal acquired heart disease—class IV of New York Heart Association classification (inability to do any physical activity without discomfort = 10% chance of surviving 6 months)

**What are the contraindications?**

Active infection

Poor pulmonary function

Increased pulmonary artery resistance

**What are the tests for compatibility?**

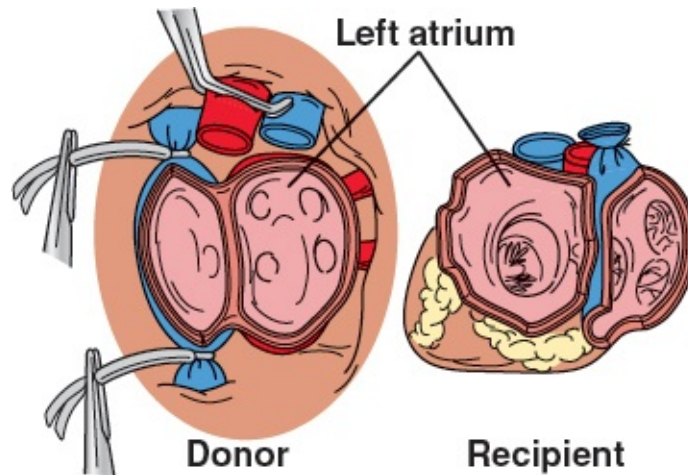
ABO, size

**What is the placement?**

Orthotopic anastomosis of atria, aorta, pulmonary artery

### **What is sewn together in a heart transplant?**

Donor heart atriums, pulmonary artery, and aorta are sewn to the recipient heart atriums, pulmonary artery, and aorta



### **What are the red flags of rejection?**

Fever, hypotension or hypertension, increased T4/T8 ratio

### **What is coronary artery vasculopathy?**

Small vessel occlusion from chronic rejection—often requires retransplant

### **What are the tests for rejection?**

Endomyocardial biopsy—much more important than clinical signs/symptoms; patient undergoes routine biopsy

### **What are survival statistics for:**

**1 year?**

85%

**5 years?**

65%

## **INTESTINAL TRANSPLANTATION**

**What is it?**

Transplantation of the small bowel

**What types of donors are there?**

Living donor, deceased donor

**Anastomosis:****Living donor?**

Ileocolic artery and vein

**Deceased donor?**

SMA, SMV

**What are indications?**

Short gut syndrome, motility disorders, and inability to sustain TPN (liver failure, lack of venous access, etc.)

**What is a common postoperative problem other than rejection?**

GVHD (Graft-Versus-Host Disease) from large lymphoid tissue in transplanted intestines

**CMV status of donor?**

Must be CMV negative if recipient is CMV negative

**What is the most common cause of death postoperatively?**

Sepsis

**How is rejection surveillance conducted?**

Endoscopic biopsies

**What is the clinical clue to rejection?**

Watery diarrhea

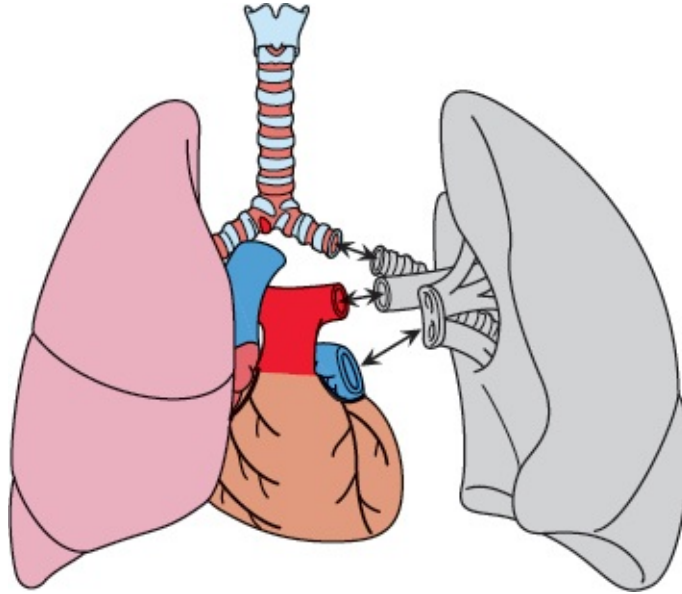
## LUNG TRANSPLANT

**Who performed the first lung transplant?**

James Hardy (1963)

### **What are necessary anastomoses?**

Bronchi, PA, pulmonary veins (Bronchial artery is not necessary)



### **What are the postop complications?**

Bronchial necrosis/stricture, reperfusion, pulmonary edema, rejection

### **What are the four red flags of rejection?**

- . Decreased arterial O<sub>2</sub> tension
- . Fever
- . Increased fatigability
- . Infiltrate on x-ray

### **What is chronic lung rejection called?**

Obliterative Bronchiolitis (OB)

## **TRANSPLANT COMPLICATIONS**

### **What are four major complications?**

- . Infection
- . Rejection
- . Posttransplant lymphoproliferative disease

. Complications of steroids

## ■ Infection

### **What are the usual agents?**

DNA viruses, especially CMV, HSV, VZV

### **When should CMV infection be suspected?**

>21 days posttransplant

### **What is the time of peak incidence of CMV infections?**

4 to 6 weeks posttransplant

### **What are the signs/symptoms of CMV?**

Fever, neutropenia, signs of rejection of transplant; also can present as viral pneumonitis, hepatitis, colitis

### **How is CMV diagnosed?**

Biopsy of transplant to differentiate rejection, cultures of blood, urine

### **What is the treatment of CMV?**

Ganciclovir, with or without immunoglobulin; foscarnet

### **What are the signs/symptoms of HSV?**

Herpetic lesions, shingles, fever, neutropenia, rejection of transplant

### **What is the treatment of HSV?**

Acyclovir until patient is asymptomatic

## ■ Malignancy

### **What are the most common types?**

Skin/lip cancer (40%), B-cell cancer, cervical cancer in women, T-cell lymphoma, Kaposi's sarcoma

**Which epithelial cancers are important after transplant?**

Skin/lip cancer, especially basal cell and squamous cell

**What is posttransplant lymphoma associated with?**

Multiple doses of OKT3

EBV

Young > elderly

**What is the treatment for posttransplant lymphoproliferative disease (PTLD)?**

- . Drastically reduce immunosuppression
- . ± Radiation
- . ± Chemotherapy

**RAPID FIRE REVIEW**

**48-year-old female undergoes second renal transplant; when the clamp is removed to allow arterial inflow, the kidney immediately swells and all the vessels thrombose**

**Hyperacute rejection**

# Chapter 73 Orthopedic Surgery

## Orthopedic Terms

Define the following terms:

**Supination**

Palm up

**Pronation**

Palm down

**Plantarflexion**

Foot down at ankle joint (**PLANT** foot in ground)

**Foot dorsiflexion**

Foot up at ankle joint

**Adduction**

Movement toward the body (**ADD**uction = **ADD** to the body)

**Abduction**

Movement away from the body

**Inversion**

Foot sole faces midline

**Eversion**

Foot sole faces laterally

**Volarflexion**

Hand flexes at wrist joint toward flexor tendons

**Wrist dorsiflexion**

Hand flexes at wrist joint toward extensor tendons

**Allograft bone**

Bone from human donor other than patient

**Reduction**

Maneuver to restore proper alignment to fracture or joint

**Closed reduction**

Reduction done without surgery (e.g., casts, splints)

**Open reduction**

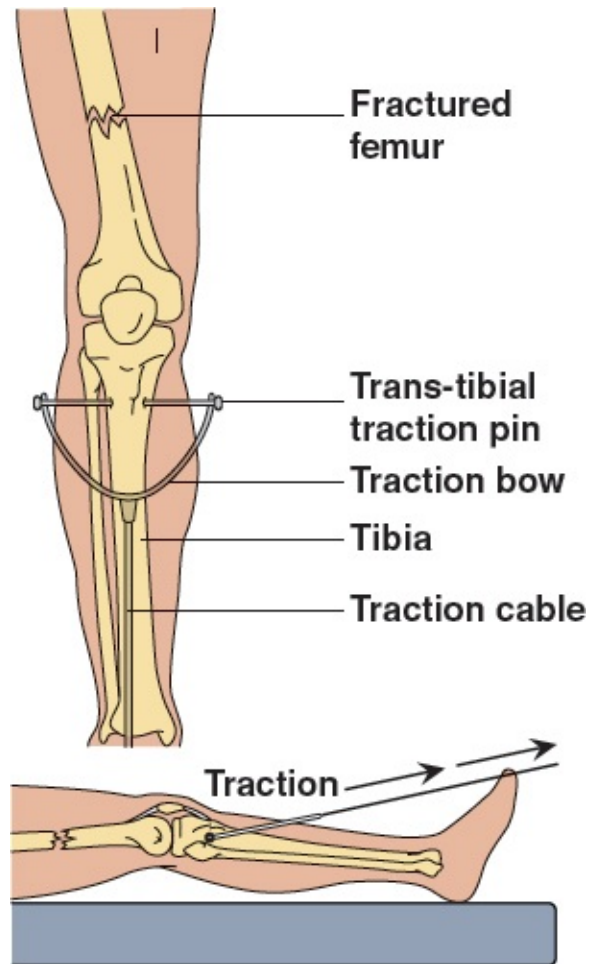
Surgical reduction

**Fixation**

Stabilization of a fracture after reduction by means of surgical placement of hardware that can be external or internal (e.g., pins, plates, screws)

**Tibial pin**

Pin placed in the tibia for treating femur or pelvic fractures by applying skeletal traction



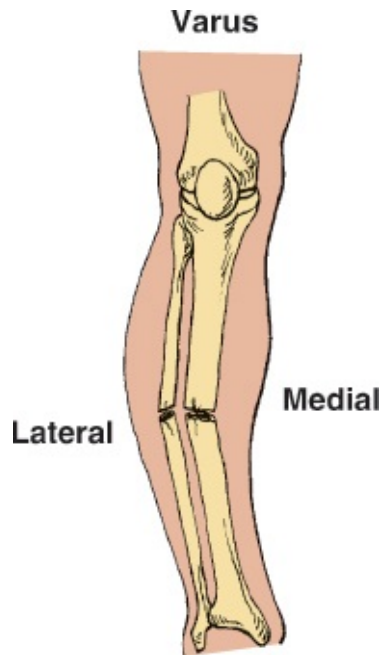
### Unstable fracture or dislocation

Fracture or dislocation in which further deformation will occur if reduction is **not** performed

### Varus

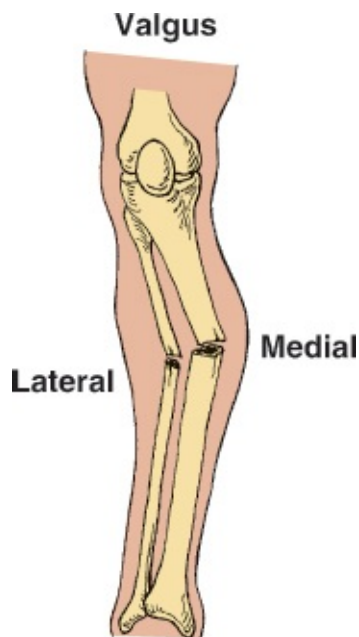
Extremity abnormality with apex of defect pointed away from midline (e.g., genu varum = bowlegged; with valgus, this term can also be used to describe fracture displacement)

(Think: knees are very **varied** apart)



## **Valgus**

Extremity abnormality with apex of defect pointed toward the midline (e.g., genu valgus = knock-kneed)



## **Dislocation**

Total loss of congruity and contact between articular surfaces of a joint

## **Subluxation**

Loss of congruity between articular surfaces of a joint; articular contact remains

### **Arthroplasty**

Total joint replacement

### **Arthrodesis**

Joint fusion with removal of articular surfaces

### **Osteotomy**

Cutting bone (usually wedge resection) to help realigning of joint surfaces

### **Non-union**

Failure of fractured bone ends to fuse

### **Define each of the following:**

#### **Diaphysis**

Main shaft of long bone

#### **Metaphysis**

Flared end of long bone

#### **Physis**

Growth plate, found only in immature bone

## **Trauma General Principles**

### **Define extremity examination in fractured extremities**

- . Observe entire extremity (e.g., open, angulation, joint disruption)
- . Neurologic (sensation, movement)
- . Vascular (e.g., pulses, cap refill)

### **Which x-rays should be obtained?**

Two views (also joint above and below fracture)

### **How are fractures described?**

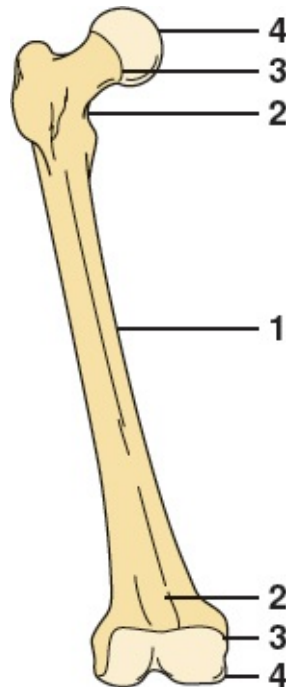
- . Skin status (open or closed)

- . Bone (by thirds: proximal/middle/distal)
- . Pattern of fracture (e.g., comminuted)
- . Alignment (displacement, angulation, rotation)

### **How do you define the degree of angulation, displacement, or both?**

Define lateral/medial/anterior/posterior displacement and angulation of the distal fragment(s) in relation to the proximal bone

### **Identify each numbered structure:**



- . Diaphysis
- . Metaphysis
- . Physis
- . Epiphysis

## **FRACTURES**

### **Define the following patterns of fracture:**

#### **Closed fracture**

Intact skin over fracture/hematoma

### **Open fracture**

Wound overlying fracture, through which fracture fragments are in continuity with outside environment; high risk of infection

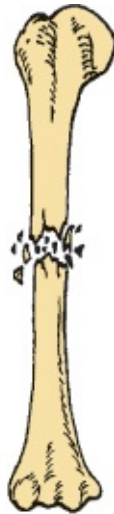(**Note:** Called “compound fracture” in the past)

### **Simple fracture**

One fracture line, two bone fragments

### **Comminuted fracture**

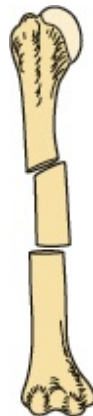Results in more than two bone fragments (a.k.a. “fragmentation”)



**Comminuted fracture**

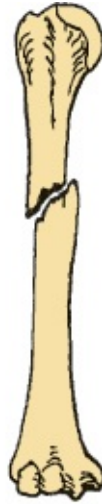### **Segmental fracture**

Two complete fractures with a “segment” in between



### **Oblique fracture**

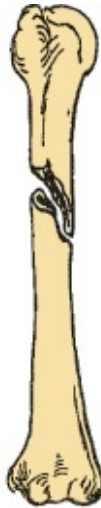Fracture line creates an oblique angle with long axis of bone



Oblique fracture

### **Spiral fracture**

Severe oblique fracture in which fracture plane rotates along the long axis of bone; caused by a twisting injury



Spiral fracture

### **Impacted fracture**

Fracture resulting from compressive force; end of bone is driven into contiguous metaphyseal region without displacement

### **Pathologic fracture**

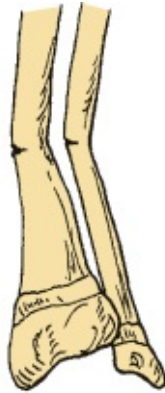
Fracture through abnormal bone (e.g., tumor-laden or osteoporotic bone)

## Stress fracture

Fracture in normal bone from cyclic loading on bone

## Greenstick fracture

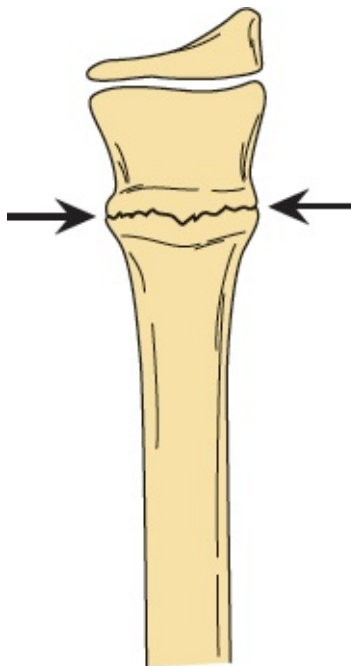
Incomplete fracture in which cortex on **only one side** is disrupted; seen in children



Greenstick fracture

## Torus fracture

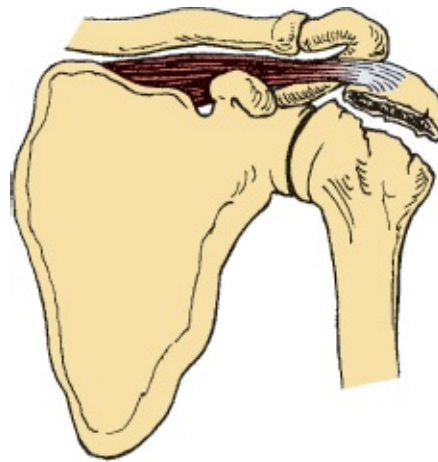
Impaction injury in children in which cortex is buckled but not disrupted (a.k.a. “buckle fracture”)



Torus fracture

## **Avulsion fracture**

Fracture in which tendon is pulled from bone, carrying with it a bone chip



**Avulsion fracture**

## **Periarticular fracture**

Fracture close to but not involving the joint

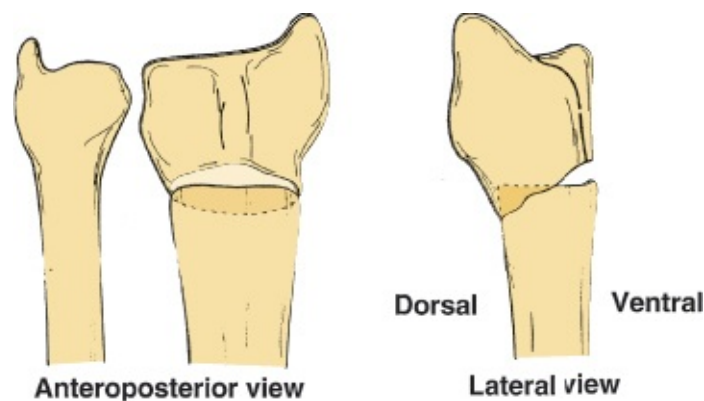
## **Intra-articular fracture**

Fracture through the articular surface of a bone (usually requires ORIF)

**Define the following specific fractures:**

## **Colles' fracture**

**Distal radius** fracture with dorsal displacement and angulation, usually from falling on an outstretched hand



## **Smith's fracture**

“Reverse Colles' fracture”—distal radial fracture with volar displacement and

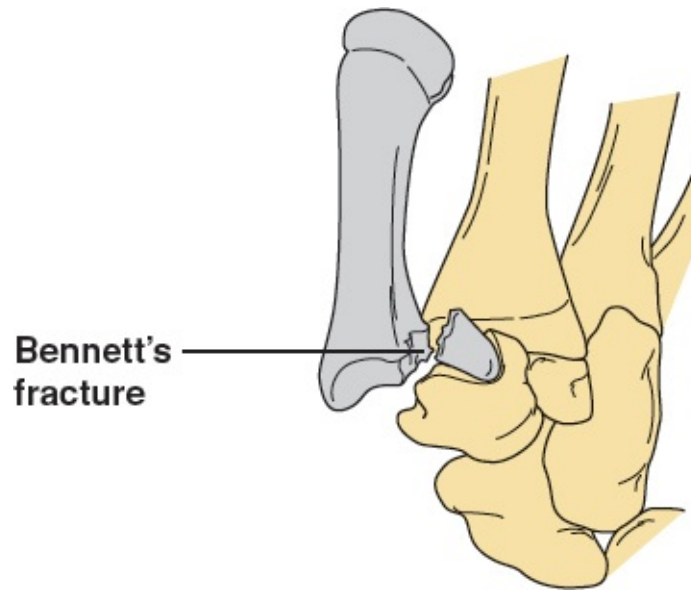
angulation, usually from falling on the **dorsum** of the hand (uncommon)

### **Jones' fracture**

Fracture at the base of the fifth metatarsal diaphysis

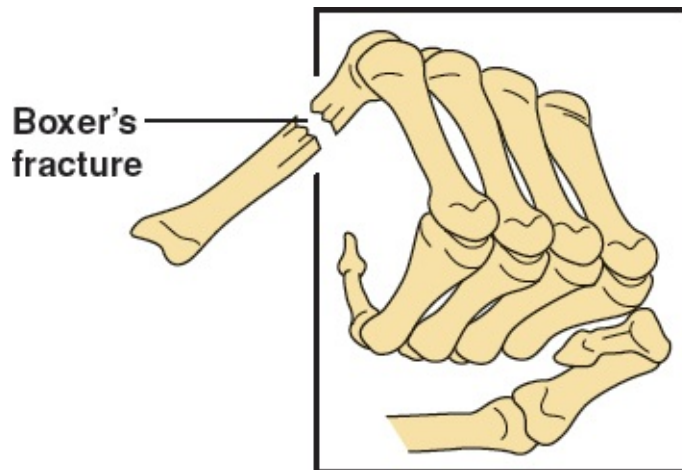
### **Bennett's fracture**

Fracture-dislocation of the base of the first metacarpal (thumb) with disruption of the carpometacarpal joint



### **Boxer's fracture**

Fracture of the metacarpal neck, "classically" of the small finger



### **Nightstick fracture**

Ulnar fracture

**Clay shoveler's avulsion fracture**

Fracture of spinous process of C6–C7

**Hangman's fracture**

Fracture of the pedicles of C2

**Transcervical fracture**

Fracture through the neck of the femur

**Tibial plateau fracture**

Intra-articular fracture of the proximal tibia (the plateau is the flared proximal end)

**Monteggia fracture**

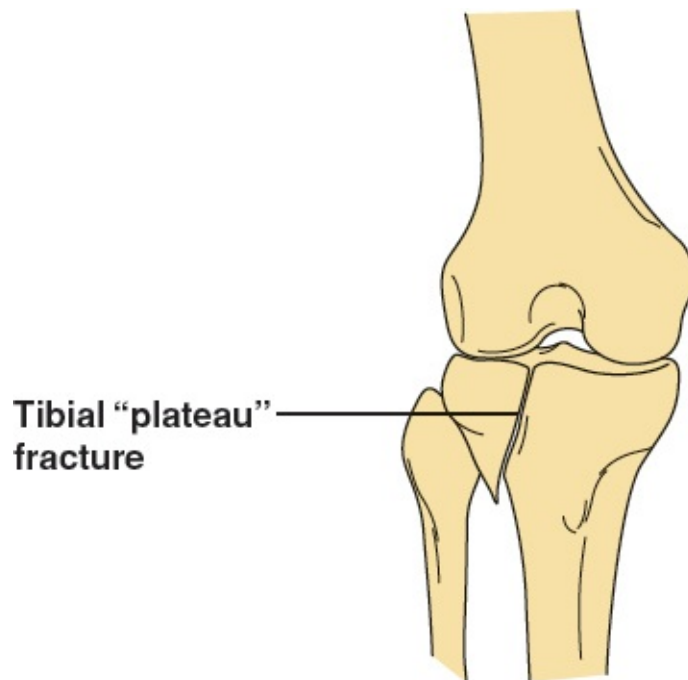
Fracture of the proximal third of the ulna with dislocation of the radial head

**Galeazzi fracture**

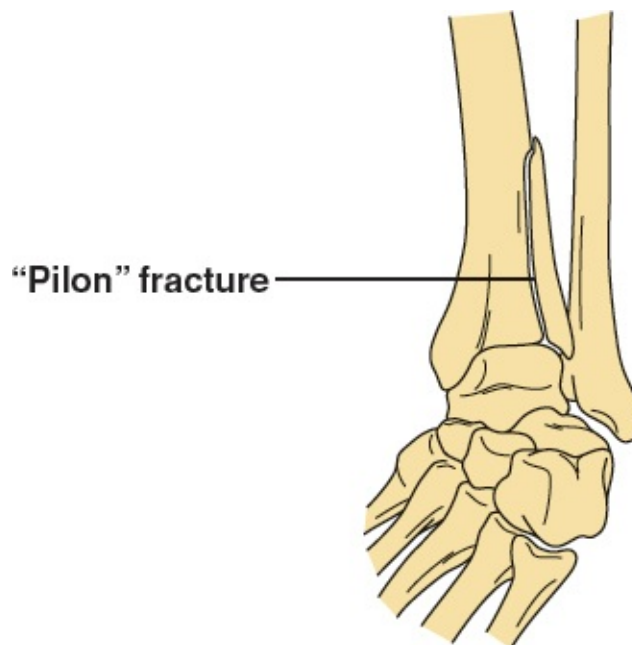
Fracture of the radius at the junction of the middle and distal thirds accompanied by disruption of the distal radioulnar joint

**Tibial "plateau" fracture**

Proximal tibial fracture



**"Pilon" fracture**  
Distal tibial fracture



**Pott's fracture**  
Fracture of distal fibula

**Pott's disease**

## ORTHOPEDIC TRAUMA

### **What are the major orthopedic emergencies?**

- . Open fractures/dislocations
- . Vascular injuries (e.g., knee dislocation)
- . Compartment syndromes
- . Neural compromise, especially spinal injury
- . Osteomyelitis/septic arthritis; acute, i.e., when aspiration is indicated
- . Hip dislocations—require immediate reduction or patient will develop avascular necrosis; “reduce on the x-ray table”
- . Exsanguinating pelvic fracture (binder, external fixator)

### **What is the main risk when dealing with an open fracture?**

Infection

### **Which fracture has the highest mortality?**

Pelvic fracture (up to 50% with open pelvic fractures)

### **Define open fractures by Gustilo–Anderson classification:**

#### **Grade I?**

<1-cm laceration

#### **Grade II?**

>1 cm, minimal soft tissue damage

#### **Grade IIIA?**

Open fracture with massive tissue devitalization/loss, contamination

#### **Grade IIIB?**

Open fracture with massive tissue devitalization/loss and extensive periosteal stripping, contamination, inadequate tissue coverage

#### **Grade IIIC?**

Open fracture with major vascular injury requiring repair

### **What are the five steps in the initial treatment of an open fracture?**

- . Prophylactic antibiotics to include IV gram-positive  $\pm$  anaerobic coverage:  
Grade I—cefazolin (Ancef®) Grade II or III—cefoxitin/gentamicin
- . Surgical débridement
- . Inoculation against tetanus
- . Lavage wound <6 hours postincident with sterile irrigation
- . Open reduction of fracture and stabilization (e.g., use of external fixation)

### **What structures are at risk with a humeral fracture?**

Radial nerve, brachial artery

### **What are the advantages?**

Nearly immediate mobility with decreased morbidity/mortality

### **What is the chief concern following tibial fractures?**

Recognition of associated compartment syndrome

### **What is suggested by pain in the anatomic snuff-box?**

Fracture of scaphoid bone (a.k.a. “navicular fracture”)

### **What is the most common cause of a “pathologic” fracture in adults?**

Osteoporosis

## **Compartment Syndrome**

### **What is acute compartment syndrome?**

Increased pressure within an osteofascial compartment that can lead to ischemic necrosis

### **How is it diagnosed?**

Clinically, using intracompartmental pressures is also helpful (especially in unresponsive patients); fasciotomy is clearly indicated if pressure in the compartment is >40 mm Hg (30 to 40 mm Hg is a gray area)

**What are the causes?**

Fractures, vascular compromise, reperfusion injury, compressive dressings; can occur after any musculoskeletal injury

**What are common causes of forearm compartment syndrome?**

Supracondylar humerus fracture, brachial artery injury, radius/ulna fracture, crush injury

**What is Volkmann's contracture?**

Final sequela of forearm compartment syndrome; **contracture** of the forearm flexors from replacement of dead muscle with fibrous tissue

**What is the most common site of compartment syndrome?**

Calf (four compartments: anterior, lateral, deep posterior, superficial posterior compartments)

**What four situations should immediately alert one to be on the lookout for a developing compartment syndrome?**

- . Supracondylar elbow fractures in children
- . Proximal/midshaft tibial fractures
- . Electrical burns
- . Arterial/venous disruption

**What are the symptoms of compartment syndrome?**

Pain, paresthesias, paralysis

**What are the signs of compartment syndrome?**

Pain on passive movement (out of proportion to injury), cyanosis or pallor, hypoesthesia (decreased sensation, decreased 2-point discrimination), firm compartment

**Complication of missed anterior compartment, compartment syndrome?**

Foot drop due to superficial peroneal nerve injury

**Can a patient have a compartment syndrome with a palpable or Doppler-detectable distal pulse?**

YES!

**What are the possible complications of compartment syndrome?**

Muscle necrosis, nerve damage, contractures, myoglobinuria

**What is the initial treatment of the orthopedic patient developing compartment syndrome?**

Bivalve and split casts, remove constricting clothes/dressings, place extremity at heart level

**What is the definitive treatment of compartment syndrome?**

Fasciotomy within 4 hours (6 to 8 hours maximum) if at all possible

## **Miscellaneous Trauma Injuries and Complications**

**Name the motor and sensation tests used to assess the following peripheral nerves:**

### **Radial**

Wrist extension; dorsal web space; sensation: between thumb and index finger

### **Ulnar**

Little finger abduction; sensation: little finger-distal ulnar aspect

### **Median**

Thumb opposition or thumb pinch sensation: index finger-distal radial aspect

### **Axillary**

Arm abduction; sensation: deltoid patch on lateral aspect of upper arm

### **Musculocutaneous**

Elbow (biceps) flexion; lateral forearm sensation

**How is a peripheral nerve injury treated?**

Controversial, although clean lacerations may be repaired primarily; most

injuries are followed for 6 to 8 weeks (EMG)

**What fracture is associated with a calcaneus fracture?**

L-spine fracture (usually from a fall)

**Name the nerves of the brachial plexus**

Think: “morning rum” or “**A.M. RUM**” = **A**xillary, **M**edian, then **R**adial, **U**lnar, and **M**usculocutaneous nerves

**What are the two indications for operative exploration with a peripheral nerve injury?**

- . Loss of nerve function *after* reduction of fracture
- . No EMG signs of nerve regeneration after 8 weeks (nerve graft)

## DISLOCATIONS

### ■ Shoulder

**What is the most common type?**

95% are anterior (posterior is associated with seizures or electrical shock)

**Which two structures are at risk?**

- . Axillary nerve
- . Axillary artery

**How is it diagnosed?**

Indentation of soft tissue beneath acromion

**What are the three treatment steps?**

- . Reduction via gradual traction
- . Immobilization for 3 weeks in internal rotation
- . ROM exercises

### ■ Elbow

**What is the most common type?**

Posterior

**Which three structures are at risk?**

- . Brachial artery
- . Ulnar nerve
- . Median nerve

**What is the treatment?**

Reduce and splint for 7 to 10 days

## Hip

**When should hip dislocations be reduced?**

Immediately, to decrease risk of avascular necrosis; “reduce on the x-ray table!”

**What is the most common cause of a hip dislocation?**

High-velocity trauma (e.g., MVC)

**What is the most common type?**

Posterior—“dashboard dislocation”—often involves fracture of posterior lip of acetabulum

**Which structures are at risk?**

Sciatic nerve; blood supply to femoral head—avascular necrosis (AVN)

**What is the treatment?**

Closed or open reduction

## Knee

**What are the common types?**

Anterior or posterior

### Which structures are at risk?

Popliteal artery and vein, peroneal nerve—especially with posterior dislocation, ACL, PCL (**Note:** need arteriogram)

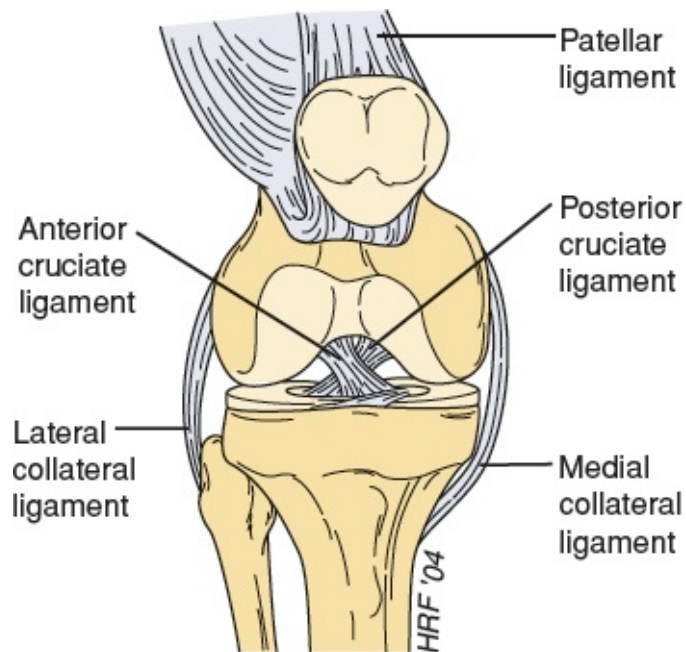
### What is the treatment?

Immediate attempt at relocation, arterial repair, and then ligamentous repair (delayed or primary)

## THE KNEE

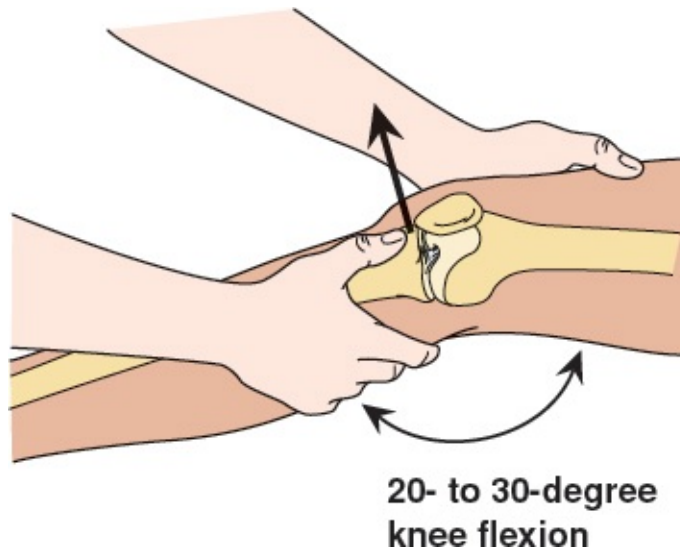
### What are the five ligaments of the knee?

- . Anterior Cruciate Ligament (ACL)
- . Posterior Cruciate Ligament (PCL)
- . Medial Collateral Ligament (MCL)
- . Lateral Collateral Ligament (LCL)
- . Patellar ligament



### What is the Lachman test for a torn ACL?

Thigh is secured with one hand while the other hand pulls the tibia anteriorly



### **What is the meniscus of the knee?**

Cartilage surface of the tibia plateau (lateral and medial meniscus); tears are repaired usually by arthroscopy with removal of torn cartilage fragments

### **What is McMurray's sign?**

Seen with a medial meniscus tear: medial tenderness of knee with flexion and internal rotation of the knee

### **What is the “unhappy triad”?**

Lateral knee injury resulting in:

1. ACL tear
2. MCL tear
3. Medial meniscus injury

### **What is a “locked knee”?**

Meniscal tear that displaces and interferes with the knee joint and prevents complete extension

### **What is a “bucket-handle tear”?**

Meniscal tear longitudinally along contour of normal “C” shape of the meniscus

**In collateral ligament and menisci injuries, which are more common, the medial or the lateral?**

Medial

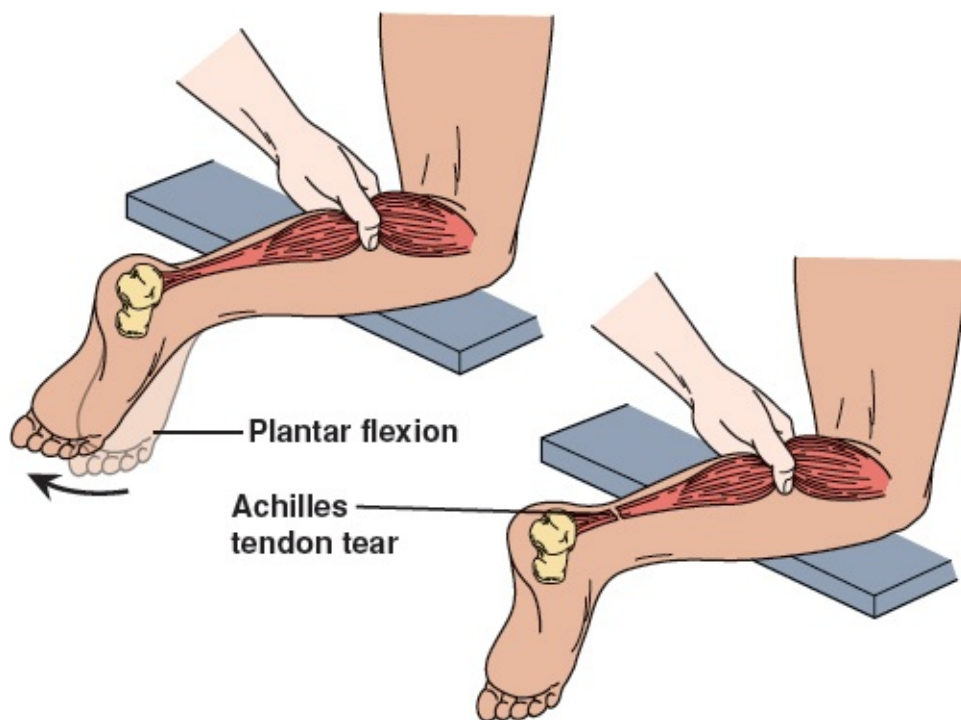
## ACHILLES TENDON RUPTURE

### What are the signs of an Achilles tendon rupture?

Severe calf pain, also bruised swollen calf, two ends of ruptured tendon may be felt, patient will have weak plantar flexion from great toe flexors that should be intact; patient often hears a “pop”

### What is the test for an INTACT Achilles tendon?

**Thompson’s test:** a squeeze of the gastrocnemius muscle results in plantar flexion of the foot (with Achilles tendon rupture = **no** plantar flexion)



### What is the treatment for an Achilles tendon rupture?

Young = surgical repair

Elderly = many can be treated with progressive splints

## ROTATOR CUFF

### What four muscles form the rotator cuff?

Think: “SITS”:

1. Supraspinatus, etc.

2. **Infraspinatus**
3. **Teres minor**
4. **Subscapularis**

### **When do tears usually occur?**

Fifth decade

### **What is the usual history?**

Intermittent shoulder pain especially with **overhead** activity, followed by an episode of acute pain corresponding to a tendon tear; weak abduction

### **What is the treatment?**

Most tears: symptomatic pain relief

Later: if poor muscular function persists, surgical repair is indicated

## **MISCELLANEOUS**

### **Define the following terms:**

#### **Dupuytren's contracture**

Thickening and contracture of palmar fascia; incidence increases with age

#### **Charcot's joint**

Joint arthritis from peripheral neuropathy

#### **Tennis elbow**

Tendonitis of the lateral epicondyle of the humerus; classically seen in tennis players

#### **Turf toe**

Hyperextension of the great toe (tear of the tendon of the flexor hallucis brevis); classically seen in football players

#### **Shin splints**

Exercise-induced anterior compartment hypertension (compartment syndrome); seen in runners

### **Heel spur**

Plantar fasciitis with abnormal bone growth in the plantar fascia; classically seen in runners and walkers

### **Nightstick fracture**

Ulnar fracture

### **Kienbock's disease**

Avascular necrosis of the lunate

### **What is traumatic myositis?**

Abnormal bone deposit in a muscle after blunt trauma deep muscle contusion (benign)

### **How does a “cast saw” cut the cast but not the underlying skin?**

It is an “oscillating” saw (designed by Dr. Homer Stryker in 1947) that goes back and forth cutting anything hard while moving the skin back and forth without injuring it

## **ORTHOPEDIC INFECTIONS**

### **■ Osteomyelitis**

#### **What is osteomyelitis?**

Inflammation/infection of bone marrow and adjacent bone

#### **What is the most common organism isolated in osteomyelitis in the general adult population?**

*Staphylococcus aureus*

#### **What is the most common isolated organism in patients with sickle cell disease?**

*Salmonella*

#### **What is seen on physical examination?**

Tenderness, decreased movement, swelling

**What are the diagnostic steps?**

History and physical examination, needle aspirate, blood cultures, CBC, ESR, bone scan

**What are the treatment options?**

Antibiotics with or without surgical drainage

**What is a Marjolin's ulcer?**

Squamous cell carcinoma that arises in a chronic sinus from osteomyelitis

## ■ Septic Arthritis

**What is it?**

Inflammation of a joint beginning as synovitis and ending with destruction of articular cartilage if left untreated

**What are the causative agents?**

Same as in osteomyelitis, except that gonococcus is a common agent in the adult population

**What are the findings on physical examination?**

Joint pain, decreased motion, joint swelling, joint warm to the touch

**What are the diagnostic steps?**

Needle aspirate (look for pus; culture plus Gram stain), x-ray, blood cultures, ESR

**What is the treatment?**

Decompression of the joint via needle aspiration and IV antibiotics; hip, shoulder, and spine must be surgically incised, débrided, and drained

## ORTHOPEDIC TUMORS

**What is the most common type in adults?**

Metastatic!

**What are the common sources?**

Breast, lung, prostate, kidney, thyroid, and multiple myeloma

**What is the usual presentation?**

Bone pain or as a pathologic fracture

**What is the most common primary malignant bone tumor?**

Multiple myeloma (45%)

**What is the differential diagnosis of a possible bone tumor?**

Metastatic disease

Primary bone tumors

Metabolic disorders (e.g., hyperparathyroidism)

Infection

**Compare benign and malignant bone tumors in terms of:****Size**

Benign—small; <1 cm

Malignant—>1 cm

**Bone reaction**

Benign—sclerotic bone reaction

Malignant—little reaction

**Margins**

Benign—sharp

Malignant—poorly defined

**Invasive**

Benign—confined to bone

Malignant—often extends to surrounding tissues

**Are most pediatric bone tumors benign or malignant?**

80% are benign (most common is osteochondroma)

**Are most adult bone tumors benign or malignant?**

66% are malignant (most commonly metastatic)

### **What are the four diagnostic steps?**

- . PE/lab tests
- . Radiographs
- . CT scan, technetium scan, or both
- . Biopsy

### **What are the radiographic signs of malignant tumors?**

Large size

Aggressive bone destruction, poorly defined margins

Ineffective bone reaction to tumor

Extension to soft tissues

### **What are the radiographic signs of benign tumors?**

Small

Well circumscribed, sharp margins

Effective bone reaction to the tumor (sclerotic periostitis)

No extension—confined to bone

### **What are some specific radiographic findings of the following:**

#### **Osteosarcoma?**

“Sunburst” pattern

#### **Fibrous dysplasia**

Bubbly lytic lesion, “ground glass”

#### **Ewing’s sarcoma**

“Onion skinning”

### **What is the mainstay of treatment for bone tumors?**

Surgery (excision plus débridement) for both malignant and benign lesions; radiation therapy and chemotherapy as adjuvant therapy for many malignant tumors

## ■ Osteosarcoma

**What is the usual age at presentation?**

10 to 20 years

**What is the gender distribution?**

Male > female

**What is the most common location?**

≈66% in the distal femur, proximal tibia

**What is the radiographic sine qua non?**

Bone formation somewhere within tumor

**What is the treatment?**

Resection (limb sparing if possible) plus chemotherapy

**What is the most common site of metastasis?**

Lungs

**What is the most common benign bone tumor?**

**Osteochondroma**; it is cartilaginous in origin and may undergo malignant degeneration

**What is a chondrosarcoma?**

Malignant tumor of cartilaginous origin; presents in middle-aged and older patients and is unresponsive to chemotherapy and radiotherapy

## ■ Ewing's Sarcoma

**What is the usual presentation?**

Pain, swelling in involved area

**What is the most common location?**

Around the knee (distal femur, proximal tibia)

**What is the usual age at presentation?**

Evenly spread among those <20 years of age

**What are the associated radiographic findings?**

Lytic lesion with periosteal reaction termed “onion skinning,” which is calcified layering

Central areas of tumor can undergo liquefaction necrosis, which may be confused with purulent infection (particularly in a child with fever, leukocytosis, and bone pain)

**What is a memory aid for Ewing’s sarcoma?**

“TKO Ewing”:

Twenty years old or younger

Knee joint

“Onion skinning”

**What is the 5-year survival rate?**

50%

**How can Ewing’s sarcoma mimic the appearance of osteomyelitis?**

Bone cysts

**What is a unicameral bone cyst?**

Fluid-filled cyst most commonly found in the proximal humerus in children 5 to 15 years of age

**What is the usual presentation?**

Asymptomatic until pathologic fracture

**What is the treatment?**

Steroid injections

**What is an aneurysmal bone cyst?**

Hemorrhagic lesion that is locally destructive by expansile growth, but does not metastasize

**What is the usual presentation?**

Pain and swelling; pathologic fractures are rare

## **What is the treatment?**

Curettage and bone grafting

# **ARTHRITIS**

## **Which arthritides are classified as degenerative?**

Osteoarthritis

Posttraumatic arthritis

## **What signs characterize osteoarthritis?**

Heberden's nodes/Bouchard's nodes

**Symmetric** destruction, usually of the hip, knee, or spine

## **What are Bouchard's nodes?**

Enlarged PIP joints of the hand from cartilage/bone growth

## **What are Heberden's nodes?**

Enlarged DIP joints of the hand from cartilage/bone growth

## **What is posttraumatic arthritis?**

Usually involves one joint of past trauma

## **What are the three treatment options for degenerative arthritis?**

- . NSAIDs for acute flare-ups, **not** for long-term management
- . Local corticosteroid injections
- . Surgery

## **What are the characteristics of rheumatoid arthritis?**

Autoimmune reaction in which invasive pannus attacks hyaline articular cartilage; rheumatoid factor (anti-IgG/IgM) in 80% of patients; 3× more common in women; skin nodules (e.g., rheumatoid nodule)

## **What is pannus?**

Inflammatory exudate overlying synovial cells inside the joint

## **What are the classic hand findings with rheumatoid arthritis?**

Wrist: radial deviation

Fingers: ulnar deviation

**What are the three surgical management options for joint/bone diseases?**

- . Arthroplasty
- . Arthrodesis (fusion)
- . Osteotomy

**What is the major difference between gout and pseudogout?**

Gout: caused by urate deposition, negative birefringent, needle crystal

Pseudogout: caused by calcium pyrophosphate positive birefringent square crystals (Think: **P**ositive **S**quare crystals = **P**seudogout)

**What is a Charcot's joint?**

Arthritic joint from peripheral neuropathy

## PEDIATRIC ORTHOPEDICS

**What types of fractures are unique to children?**

Greenstick fracture

Torus fracture

Fracture through physis

## ■ Salter-Harris Classification

**What does it describe?**

Fractures in children involving physis

**What does it indicate high risk of?**

Potential growth arrest

**Define the following terms:**

**Salter I**

Through physeal plate only

## **Salter II**

Involves metaphysis and physis

## **Salter III**

Involves physis and epiphysis

## **Salter IV**

Extends from metaphysis through physis, into epiphysis

## **Salter V**

Axial force crushes physal plate

**What acronym can help you remember the Salter classifications?**

**“SALTR”:**

Separated = type I

Above = type II

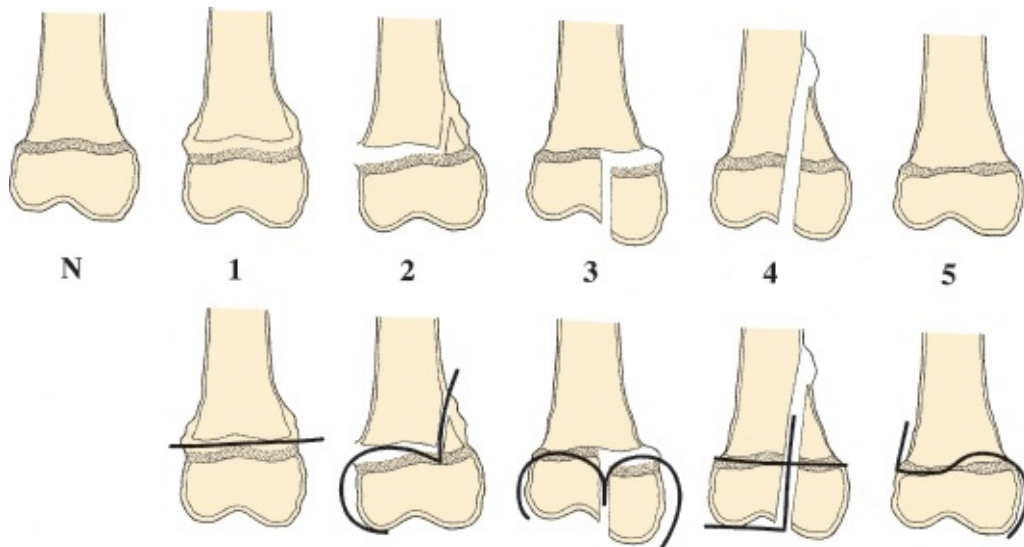
Lower = type III

Through = type IV

Ruined = type V

**What is the simple numerical method for remembering the Salter-Harris classification?**

(N = normal)



**Why is the growth plate of concern in childhood fractures?**

Growth plate represents the “weak link” in the child’s musculoskeletal system; fractures involving the growth plate of long bones may compromise normal growth, so special attention should be given to them

**What is a chief concern when oblique/spiral fractures of long bones are seen in children?**

Child abuse is a possibility; other signs of abuse should be investigated

**What is usually done during reduction of a femoral fracture?**

Small amount of overlap is allowed because increased vascularity from injury may make the affected limb longer if overlap is not present; treatment after reduction is a spica cast

**What is unique about ligamentous injury in children?**

Most “ligamentous” injuries are actually fractures involving the growth plate!

**What two fractures have a high incidence of associated compartment syndrome?**

- . Tibial fractures
- . Supracondylar fractures of humerus (Volkmann’s contracture)

## Congenital Hip Dislocation

**What is the epidemiology?**

Female > male, firstborn children, breech

Presentation, 1 in 1000 births

**What percentage are bilateral?**

10%

**How is the diagnosis made?**

Barlow’s maneuver, Ortolani’s sign

Radiographic confirmation is required

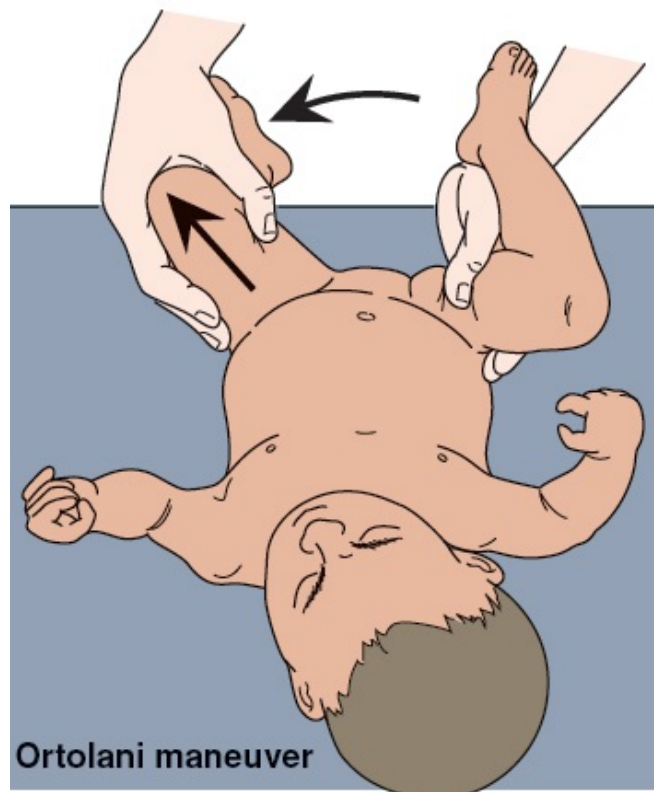
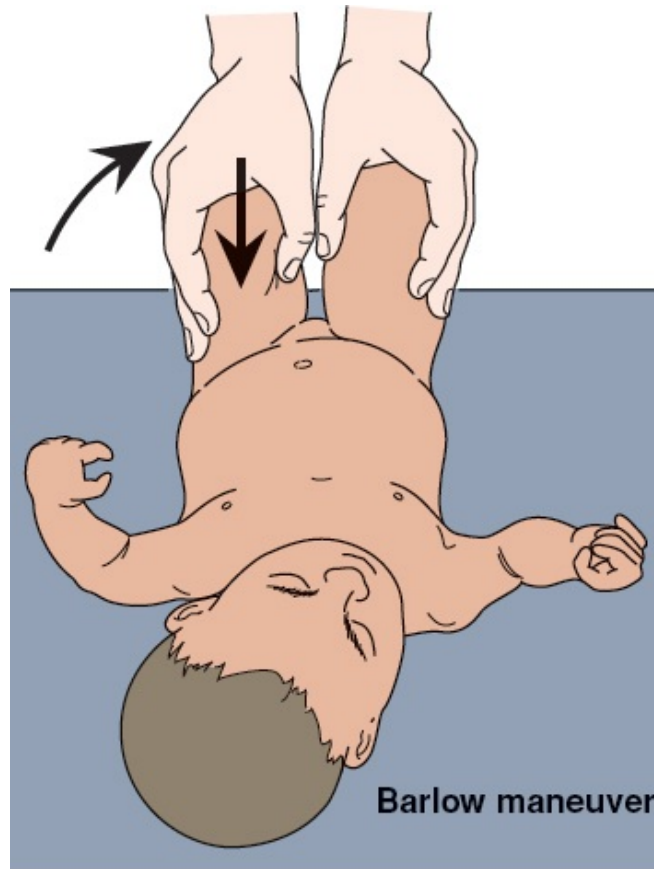
**What is Barlow’s maneuver?**

Detects unstable hip: patient is placed in the supine position and attempt is made

to push femurs posteriorly with knees at 90°/hip flexed and hip will dislocate  
(Think: push **B**ack = **B**arlow)

**What is Ortolani's sign?**

“Clunk” produced by relocation of a dislocated femoral head when the examiner abducts the flexed hip and lifts the greater trochanter anteriorly; detects a dislocated hip (Think: **O**ut = **O**rtolani's)



### **What is the treatment?**

Pavlik harness—maintains hip reduction with hips flexed at 100° to 110°

## **Scoliosis**

### **What is the definition?**

Lateral curvature of a portion of the spine

Nonstructural: corrects with positional change

Structural: does not correct

### **What are three treatment options?**

- . Observation
- . Braces (Milwaukee brace)
- . Surgery

### **What are the indications for surgery for scoliosis?**

Respiratory compromise

Rapid progression

Curves >40°

Failure of brace

## **MISCELLANEOUS**

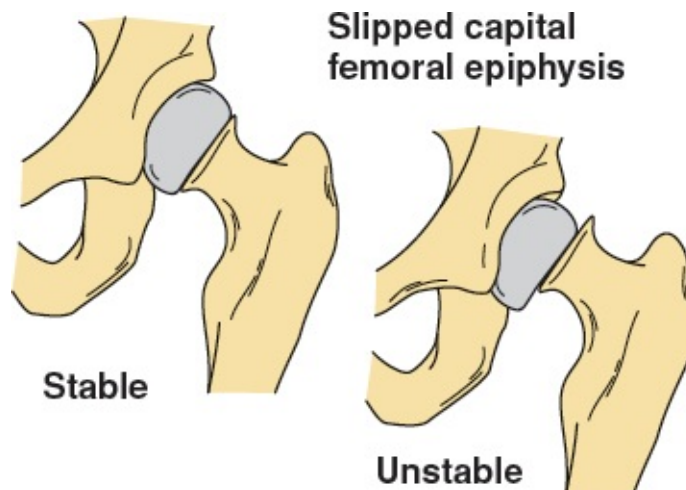
### **Define the following terms:**

#### **Legg–Calvé–Perthes disease**

Idiopathic avascular necrosis of femoral head in children

#### **Slipped capital femoral epiphysis**

Migration of proximal femoral epiphysis on the metaphysis in children; the proximal femoral epiphysis externally rotates and displaces anteriorly from the capital femoral epiphysis, which stays reduced in the acetabulum  
(**Note:** Hip pain in children often presents as knee pain)



### **Blount's disease**

Idiopathic varus bowing of tibia

### **Nursemaid's elbow**

Dislocation of radial head (from pulling toddler's arm)

### **Little League elbow**

Medial epicondylitis

### **Osgood-Schlatter's disease**

Apophysitis of the tibial tubercle resulting from repeated powerful contractions of the quadriceps; seen in adolescents with an open physis

Treatment of mild cases: activity restriction

Treatment of severe cases: cast

### **What is the most common pediatric bone tumor?**

Osteochondroma (Remember, 80% of bone tumors are benign in children)

## **RAPID FIRE REVIEW**

### **What is the correct diagnosis?**

**Bone tumor with "onion skinning" histology**

Ewing's sarcoma

**25-year-old s/p MVC with seatbelt sign and severe lower back pain**

Chance fracture of lumbar spine

**8-year-old s/p fall from a swing with a humerus fracture; weeks later he develops contraction of the forearm flexors**

Volkman's contracture

**55-year-old male develops acute severe calf pain during an aerobics class; x-rays negative for fracture; on exam, there is no plantar flexion with squeeze of gastrocnemius muscle**

Achilles' tendon rupture

**28-year-old man with traumatic superficial arterial occlusion for 7 hours develops severe calf pain with passive dorsiflexion of foot, foot paresthesias, decreased foot/toe movement, and palpable pulse after successful bypass procedure**

Calf compartment syndrome

**Name the most likely diagnosis:**

**30-year-old woman with thoracic back pain, destruction of thoracic vertebral bodies on x-ray, + PPD**

Pott's disease (tuberculosis of the spine)

**16-year-old boy with right knee pain and fevers; x-ray reveals a distal femur lesion with "sunburst" pattern with a triangle of elevated periosteum**

Osteosarcoma

**Femur fracture, dyspnea, mental status changes, tachycardia, petechiae**

Fat embolism syndrome

**Elderly man with shortened and inverted LE**

Hip dislocation

**35-year-old female trips and lands on her right hand; x-rays are negative for fracture; severe pain on palpating over the anatomical “snuff box”**

Scaphoid fracture

**What is the treatment?**

**18-year-old male s/p motorbike jump crash with closed rib fib fracture; good distal pulses but severe pain on passive foot extension**

Fasciotomy for compartment syndrome

**45-year-old male s/p fall with severe pain with breathing due to multiple rib fractures**

Epidural catheter for pain control

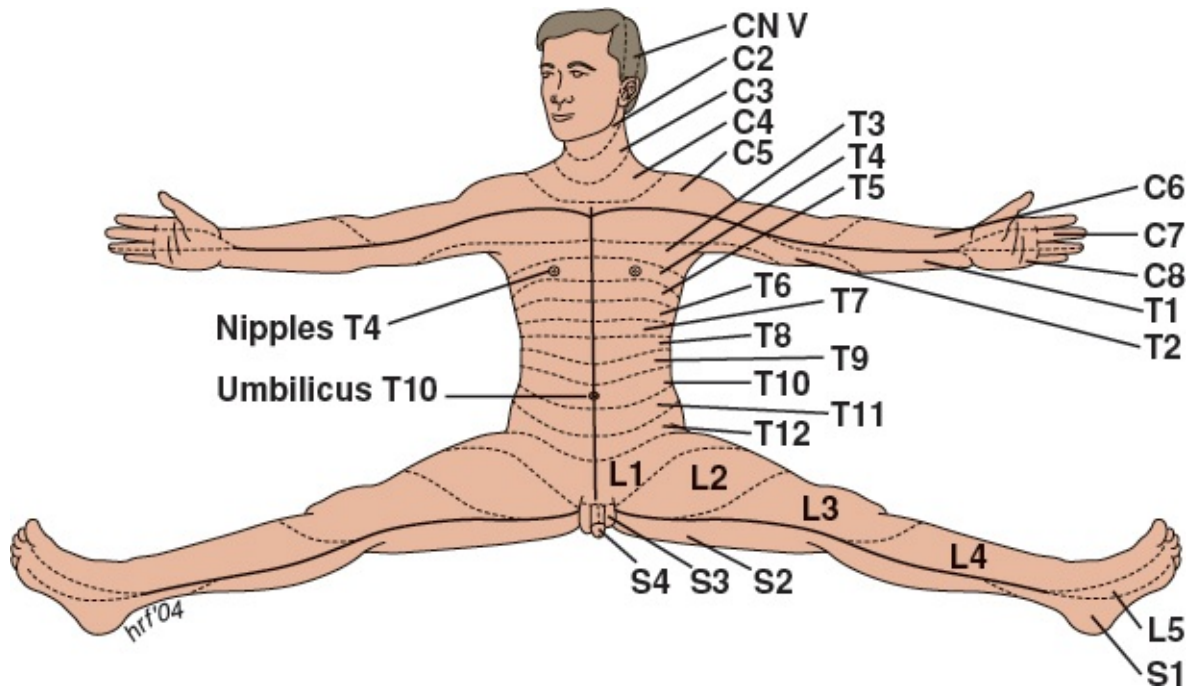
# Chapter 74 Neurosurgery

## HEAD TRAUMA

**What percentage of trauma deaths result from head trauma?**

50%

**Identify the dermatomes:**



**What is the Glasgow Coma Scale (GCS)?**

GCS is an objective assessment of the level of consciousness after trauma

## GCS Scoring System

**Eyes?**

Eye Opening (E)

(Think: **“4 eyes”**)

- 4—opens spontaneously
- 3—opens to voice (command)
- 2—opens to painful stimulus
- 1—does not open eyes

## **Motor?**

Motor Response (M)

(Think: **6 cylinder motor**)

- 6—obeys commands
- 5—localizes painful stimulus
- 4—withdraws from pain
- 3—decorticate posture
- 2—decerebrate posture
- 1—no movement

## **Verbal?**

Verbal Response (V)

(Think: Jackson 5 = **verbal 5**)

- 5—appropriate and oriented
- 4—confused
- 3—inappropriate words
- 2—incomprehensible sounds
- 1—no sounds

## **What indicates coma by GCS score?**

<8 (Think: “less than eight—it may be too late”)

## **What does unilateral, dilated, nonreactive pupil suggest?**

Focal mass lesion with ipsilateral herniation and compression of CN III

## **What do bilateral fixed and dilated pupils suggest?**

Diffusely increased ICP

## **What are the four signs of basilar skull fracture?**

. **Raccoon eyes**—periorbital ecchymoses

- . **Battle's sign**—postauricular ecchymoses
- . **Hemotympanum**
- . **CSF rhinorrhea/otorrhea**

### **What is the initial radiographic neuroimaging in trauma?**

- . Head CT scan (if LOC or GCS <15)
- . C-spine CT scan
- . T/L spine AP and lateral

### **Should the trauma head CT scan be with or without IV contrast? Without!**

### **What is normal ICP?**

5 to 15 mm H<sub>2</sub>O

### **What is the worrisome ICP?**

>20 mm H<sub>2</sub>O

### **What determines ICP (Monroe–Kelly hypothesis)?**

- . Volume of brain
- . Volume of blood
- . Volume of CSF

### **What is the CPP?**

Cerebral **P**erfusion **P**ressure = mean arterial pressure—ICP (normal CPP is >70)

### **What is Cushing's reflex?**

Physiologic response to increased ICP:

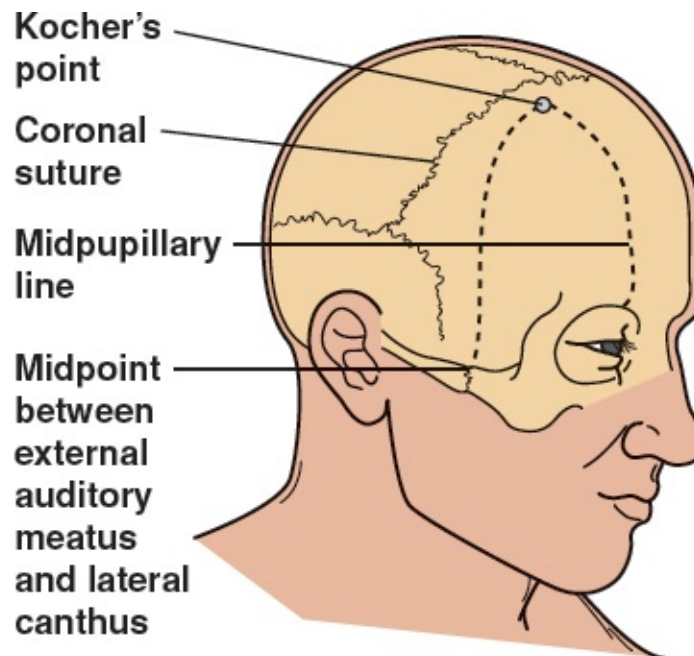
1. Hypertension
2. Bradycardia
3. Decreased RR

### **What are the three general indications to monitor ICP after trauma?**

- . GCS <9
- . Altered level of consciousness or unconsciousness with multiple system trauma
- . Decreased consciousness with focal neurologic examination abnormality

## What is Kocher's point?

Landmark for placement of ICP monitor bolt:



## What nonoperative techniques are used to decrease ICP?

- . **Elevate** head of bed (HOB) 30° (if spine cleared)
- . Diuresis-mannitol (osmotic diuretic), Lasix®, limit fluids
- . Intubation (Pco<sub>2</sub> control)
- . Sedation
- . Pharmacologic paralysis
- . Ventriculostomy (CSF drainage)

## How does hyperventilation ↓ ICP?

By ↓ Pco<sub>2</sub> resulting in cerebral vasoconstriction (and thus less intracranial volume)

## What is the acronym for the treatment of elevated ICP?

**“ICP HEAD”:**

Intubate

Calm (sedate)

Place drain (ventriculostomy)/Paralysis

Hyperventilate to Pco<sub>2</sub> ≈35

Elevate head  
Adequate blood pressure (CPP >70)  
Diuretic (e.g., mannitol)

### **Can a tight c-collar increase the ICP?**

Yes (it blocks venous drainage from brain!)

### **Why is prolonged hyperventilation dangerous?**

It may result in severe vasoconstriction and ischemic brain necrosis!  
Use only for very brief periods

### **What is a Kjellberg? (pronounced “shellberg”)**

Decompressive bifrontal craniectomy with removal of frontal bone frozen for possible later replacement

### **How does cranial nerve examination localize the injury in a comatose patient?**

CNs proceed caudally in the brainstem as numbered: Presence of corneal reflex (CN 5 + 7) indicates intact pons; intact gag reflex (CN 9 + 10) shows functioning upper medulla (**Note:** CN 6 palsy is often a false localizing sign)

### **What is acute treatment of seizures after head trauma?**

Benzodiazepines (Ativan®)

### **What is seizure prophylaxis after severe head injury?**

Give phenytoin for 7 days

### **What is the significance of hyponatremia (low sodium level) after head injury?**

SIADH must be ruled out; remember, **SIADH** = Sodium Is Always Down Here

## **Epidural Hematoma**

### **What is an epidural hematoma?**

Collection of blood between the skull and dura

**What causes it?**

Usually occurs in association with a skull fracture as bone fragments lacerate meningeal arteries

**Which artery is associated with epidural hematomas?**

Middle meningeal artery

**What is the most common sign of an epidural hematoma?**

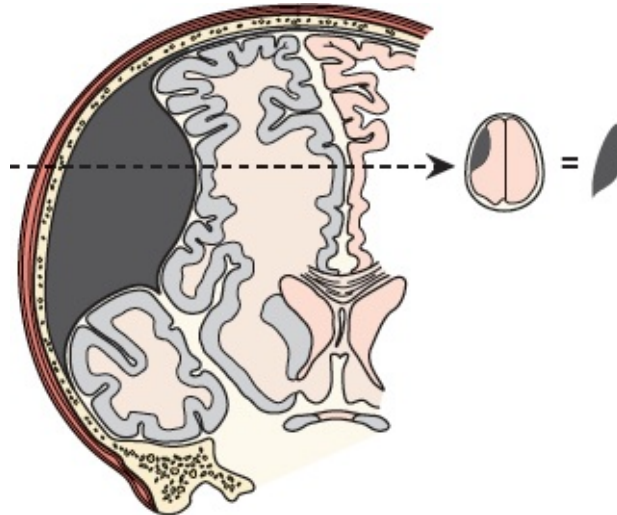
>50% have ipsilateral blown pupil

**What is the classic history with an epidural hematoma?**

LOC followed by a “lucid interval” followed by neurologic deterioration

**What are the classic CT scan findings with an epidural hematoma?**

Lenticular (lens)-shaped hematoma (Think: Epidural = Lenticular)

**What is the surgical treatment for an epidural hematoma?**

Surgical evacuation

## ■ Subdural Hematoma

**What is it?**

Blood collection under the dura

### **What causes it?**

Tearing of “bridging” veins that pass through the space between the cortical surface and the dural venous sinuses or injury to the brain surface with resultant bleeding from cortical vessels

### **What are the three types of subdurals?**

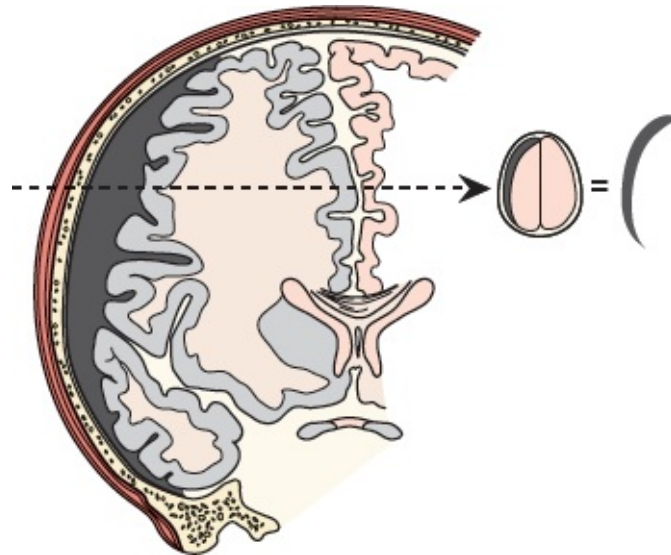
- . Acute—symptoms within 48 hours of injury
- . Subacute—symptoms within 3 to 14 days
- . Chronic—symptoms after 2 weeks or longer

### **What is the treatment of epidural and subdural hematomas?**

Mass effect (pressure) must be reduced; craniotomy with clot evacuation is usually required

### **What classic findings appear on head CT scan for a subdural hematoma?**

Curved, crescent-shaped hematoma (Think: sUbdural = cUrved)



## **Traumatic Subarachnoid Hemorrhage**

### **What is it?**

Head trauma resulting in blood below the arachnoid membrane and above the pia

### **What is the treatment?**

Anticonvulsants and observation

## **Cerebral Contusion**

### **What is it?**

Hemorrhagic contusion of brain parenchyma

### **What are coup and contrecoup injuries?**

Coup—injury at the site of impact

Contrecoup—injury at the site opposite the point of impact

### **What is DAI?**

**Diffuse Axonal Injury** (shear injury to brain parenchyma) from rapid deceleration injury

### **What is the best diagnostic test for DAI?**

MRI

### **What can present after blunt trauma with neurologic deficits and a normal brain CT scan?**

DAI, carotid artery injury

## **Skull Fracture**

### **What is a depressed skull fracture?**

Fracture in which one or more fragments of the skull are forced below the inner table of the skull

### **What are the indications for surgery?**

- . Contaminated wound requiring cleaning and débridement
- . Severe deformity
- . Impingement on cortex
- . Open fracture

- . CSF leak

### **What is the treatment for open skull fractures?**

- . Antibiotics
- . Seizure prophylaxis
- . Surgical therapy

## **SPINAL CORD TRAUMA**

### **What are the two general types of injury?**

- . Complete—no motor/sensory function below the level of injury
- . Incomplete—residual function below the level of injury

### **What is “spinal shock”?**

Loss of all reflexes and motor function

### **What is “sacral sparing”?**

Sparing of sacral nerve level: anal sphincter intact, toe flexion, perianal sensation

### **What are the diagnostic studies?**

CT scan, MRI

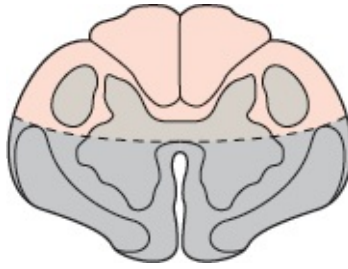
### **What are the indications for emergent surgery with spinal cord injury?**

Unstable vertebral fracture  
Incomplete injury with extrinsic compression  
Spinal epidural or subdural hematoma

### **Describe the following conditions:**

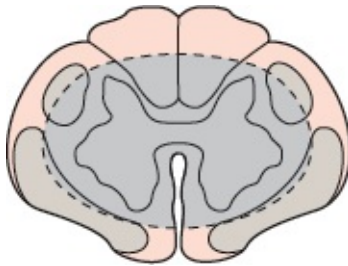
#### **Anterior cord syndrome**

Affects corticospinal and lateral spinothalamic tracts, paraplegia, loss of pain/temperature sensation, preserved touch/vibration/proprioception



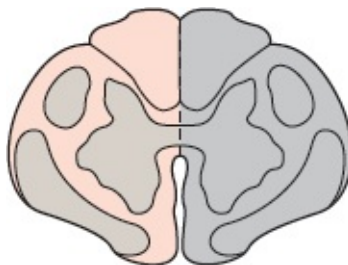
### **Central cord syndrome**

Preservation of some lower extremity motor and sensory ability with upper extremity weakness



### **Brown-Séquard syndrome**

Hemisection of cord resulting in ipsilateral motor touch/proprioception loss with contralateral pain/temperature loss



### **Posterior cord syndrome**

Injury to posterior spinal cord with loss of proprioception distally

**How can the findings associated with Brown-Séquard syndrome be remembered?**

Think: **CAPTAIN** Brown-Séquard = “**CPT**”:

**C**ontralateral

**P**ain

**T**emperature loss

## Define the following terms:

### Jefferson's fracture

Fracture through **C1** arches from axial loading (unstable fracture)

### Hangman's fracture

Fracture through the pedicles of **C2** from hyperextension; usually stable

Think: A hangman (C2) is below stature of President T. Jefferson (C1)

### Odontoid fracture

Fracture of the odontoid process of C2 (view with open-mouth odontoid x-ray)

### Priapism

Penile erection seen with spinal cord injury

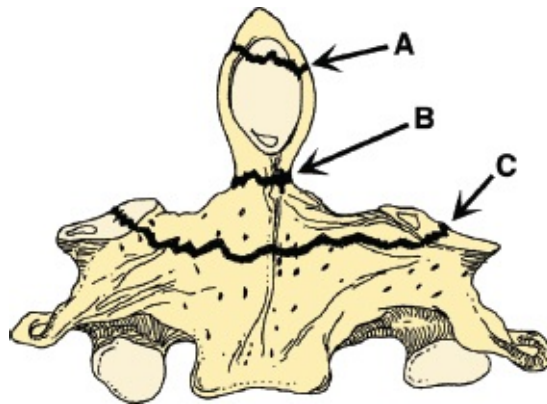
### Chance fracture

Transverse vertebral fracture

### Clay shoveler's fracture

Fracture of spinous process of C7

### Odontoid fractures



A: Type I—fracture through tip of dens

B: Type II—fracture through base of dens

C: Type III—fracture through body of C2

# TUMORS

## ■ General

### **What is the incidence of CNS tumors?**

≈1% of all cancers; third leading cause of cancer deaths in people 15 to 34 years of age; second leading cause of cancer deaths in children

### **What is the usual location of primary tumors in adults/children?**

In adults, ≈66% of tumors are supratentorial, ≈33% are infratentorial; the reverse is true in children (i.e., ≈66% infratentorial)

### **What is the differential diagnosis of a ring-enhancing brain lesion?**

Metastatic carcinoma, abscess, GBM, lymphoma

### **What are the signs/symptoms of brain tumors?**

- . Neurologic deficit (66%)
- . Headache (50%)
- . Seizures (25%)
- . Vomiting (classically in the morning)

### **How is the diagnosis made?**

CT scan or MRI is the standard diagnostic study

### **What are the surgical indications?**

- . Establishing a tissue diagnosis
- . Relief of increased ICP
- . Relief of neurologic dysfunction caused by tissue compression
- . Attempt to cure in the setting of localized tumor

### **What are the most common intracranial tumors in adults?**

Metastatic neoplasms are most common; among primaries, gliomas are #1 (50%) and meningiomas are #2 (25%)

### **What are the three most common in children?**

- . Medulloblastomas (33%)

- . Astrocytomas (33%)
- . Ependymomas (10%)

## ■ Gliomas

### **What is a glioma?**

General name for several tumors of neuroglial origin (e.g., astrocytes, ependymal, oligodendrocytes)

### **What are the characteristics of a LOW-grade astrocytoma?**

Nuclear atypia, high mitotic rate, high signal on T2-weighted images, nonenhancing with contrast CT scan

### **What is the most common primary brain tumor in adults?**

Glioblastoma multiforme (GBM) (Think: **GBM** = **G**reatest **B**rain **M**alignancy)

### **What are its characteristics?**

Poorly defined, highly aggressive tumors occurring in the white matter of the cerebral hemispheres; spread extremely rapidly

### **What is the average age of onset?**

Fifth decade

### **What is the treatment?**

Surgical debulking followed by radiation

### **What is the prognosis?**

Without treatment, >90% of patients die within 3 months of diagnosis; with treatment, 90% die within 2 years

## ■ Meningiomas

### **What is the layer of origination?**

Arachnoid cap cells

**What are the risk factors?**

Radiation exposure

Neurofibromatosis type 2

Female gender

**What are the associated histologic findings?**

Psammoma bodies (concentric calcifications), whorl formations (“onion skin” pattern)

**What is the histologic malignancy determination?**

Brain parenchymal invasion

**What is the peak age of occurrence?**

40 to 50 years

**What is the gender ratio?**

Females predominate almost 2:1

**What is the clinical presentation?**

Variable depending on location; lateral cerebral convexity tumors can cause focal deficits or headache; sphenoid tumors can present with seizures; posterior fossa tumors with CN deficits; olfactory groove tumors with anosmia

**What is the treatment?**

± Preoperative embolization and surgical resection

## Cerebellar Astrocytomas

**What is the peak age of occurrence?**

5 to 9 years

**What is the usual location?**

Usually in the cerebellar hemispheres; less frequently in the vermis

**What are the signs/symptoms?**

Usually lateral cerebellar signs occur: ipsilateral incoordination or dysmetria

(patient tends to fall to side of tumor) as well as nystagmus and ataxia; CN deficits are also frequently present, especially in CNs VI and VII

## ■ Medulloblastoma

**What is the peak age of occurrence?**

First decade (3 to 7 years)

**What is the most common location?**

Cerebellar vermis in children; cerebellar hemispheres of adolescents and adults

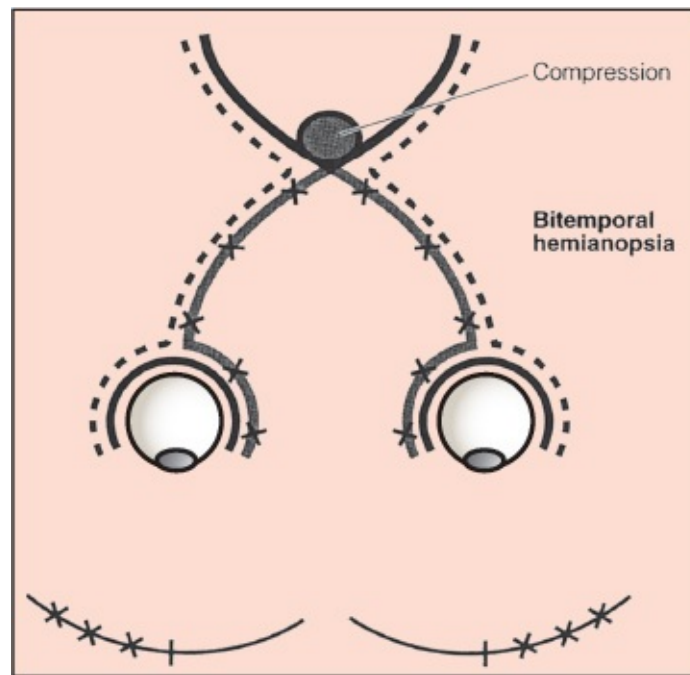
## ■ Pituitary Tumors

**What is the most common pituitary tumor?**

Prolactinoma

**What is the most common presentation of a prolactinoma?**

Bitemporal hemianopsia (lateral visual fields blind)



### **What are the blood prolactin levels with a prolactinoma?**

>300 mg/L is diagnostic for prolactinoma (>100 mg/L is abnormal)

### **Medical treatment of a prolactinoma?**

Bromocriptine

### **Surgical treatment for a prolactinoma?**

Transsphenoidal resection of the pituitary tumor (in cases refractory to bromocriptine)

### **What is the treatment of a recurrent prolactinoma after surgical resection?**

Radiation therapy

## **VASCULAR NEUROSURGERY**

### **■ Subarachnoid Hemorrhage (SAH)**

#### **What are the usual causes?**

Most cases are due to **trauma**; of nontraumatic SAH, the leading cause is ruptured **berry aneurysm**, followed by arteriovenous malformations

#### **What is a berry aneurysm?**

Saccular outpouching of vessels in the circle of Willis, usually at bifurcations

#### **What is the usual location of a berry aneurysm?**

Anterior communicating artery is #1 (30%), followed by posterior communicating artery and middle cerebral artery

#### **What medical diseases increase the risk of berry aneurysms?**

Polycystic kidney disease and connective tissue disorders (e.g., Marfan's syndrome)

#### **What are the signs/symptoms of SAH?**

Classic symptom is **“the worst headache of my life”**; meningismus is documented by neck pain and positive Kernig's and Brudzinski's signs;

occasionally LOC, vomiting, nausea, photophobia

### **What comprises the workup of SAH?**

If SAH is suspected, head CT scan should be the first test ordered

### **What are the possible complications of SAH?**

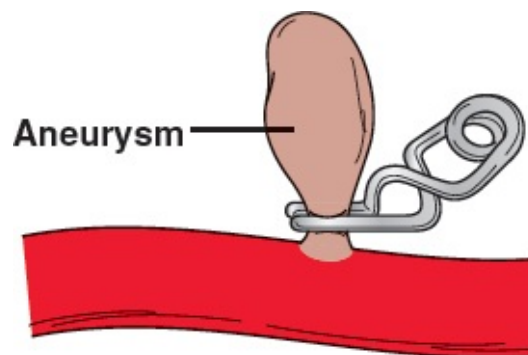
- . Brain edema leading to increased ICP
- . Rebleeding (most common in the first 24 to 48 hours post-hemorrhage)
- . **Vasospasm** (most common cause of morbidity and mortality)

### **What is the treatment for vasospasm?**

Nimodipine (calcium channel blocker)

### **What is the treatment of aneurysms?**

Surgical treatment by placing a metal clip on the aneurysm is the mainstay of therapy; alternatives include balloon occlusion or coil embolization



### **What is the treatment of arteriovenous malformations (AVMs)?**

Many are on the brain surface and accessible operatively; preoperative embolization can reduce the size of the AVM; for surgically inaccessible lesions, radiosurgery (gamma knife) has been effective in treating AVMs <3 cm in diameter

## **SPINE**

### **■ Lumbar Disc Herniation**

**What is it?**

Extrusion of the inner portion of the intervertebral disc (nucleus pulposus) through the outer annulus fibrosis, causing impingement on nerve roots exiting the spinal canal

### **Which nerve is affected?**

Nerve exiting at the level below (e.g., an L4–L5 disc impinges on the L5 nerve exiting between L5 and S1)

### **What are the most common sites?**

L5–S1 (45%)

L4–L5 (40%)

### **What is the treatment?**

Conservative—bed rest and analgesics

Surgical—partial hemilaminectomy and discectomy (removal of herniated disc)

### **What are the indications for emergent surgery?**

- . Cauda equina syndrome
- . Progressive motor deficits

### **What is cauda equina syndrome?**

Herniated disc compressing multiple S1, S2, S3, S4 nerve roots, resulting in bowel/bladder incontinence, “saddle anesthesia” over buttocks/perineum, low back pain, sciatica

## **Cervical Disc Disease**

### **What are the most common sites?**

C6–C7 (70%)

C5–C6 (20%)

### **What is Spurling's sign?**

Reproduction of radicular pain by having the patient turn his head to the affected side and applying axial pressure to the top of the head

## ■ Spinal Epidural Abscess

### **What is the etiology?**

Hematogenous spread from skin infections is most common; also, distant abscesses/infections, UTIs, postoperative infections, spinal surgery, epidural anesthesia

### **What is the most common organism?**

*Staphylococcus aureus*

### **What are the signs/symptoms?**

Fever; severe pain over affected area and with flexion/extension of spine; weakness can develop, ultimately leading to paraplegia; 15% of patients have a back furuncle

### **What is the treatment?**

Surgical drainage and appropriate antibiotic coverage

### **What is the prognosis?**

Depends on preop condition; severe neurologic deficits (e.g., paraplegia) show little recovery; 15% to 20% of cases are fatal

## PEDIATRIC NEUROSURGERY

## ■ Hydrocephalus

### **What is it?**

Abnormal condition consisting of an increased volume of CSF along with distension of CSF spaces

### **What are the signs/symptoms?**

Signs of increased ICP: HA, nausea, vomiting, ataxia, increasing head circumference exceeding norms for age

### **What is the treatment?**

- . Remove obvious offenders
- . Perform bypass obstruction with ventriculoperitoneal shunt or ventriculoatrial shunt

### **What is a “shunt series”?**

Series of x-rays covering the entire shunt length—looking for shunt disruption/kinking to explain malfunction of shunt

## **■ Spinal Dysraphism/Neural Tube Defects**

### **What is spina bifida occulta?**

Defect in the development of the posterior portion of the vertebrae

### **What is the treatment?**

With open myelomeningoceles, patients are operated on immediately to prevent infection

### **Which vitamin is thought to lower the rate of neural tube defects in utero?**

Folic acid

## **■ Craniosynostosis**

### **What is it?**

Premature closure of one or more of the sutures between the skull plates

### **What is the timing of surgery?**

Usually 3 to 4 months of age; earlier surgery increases the risk of anesthesia; later surgeries are more difficult because of the worsening deformities and decreasing malleability of the skull

## **■ Miscellaneous**

## **What is syringomyelia?**

Central pathologic cavitations of the spinal cord

## **RAPID FIRE REVIEW**

**Name the most likely diagnosis:**

**What is the GCS for an 18-year-old woman s/p MVC in a “coma”?**

= 8

**What is the GCS for a 40-year-old man brought in dead after an MVC by the rescue paramedics?**

3: eyes = 1, motor = 1, verbal = 1

**What is the GCS for 20-year-old woman s/p motorcycle collision with open eyes, grunting only, and withdrawals to pain?**

10 = eyes: 4, motor = 4, verbal = 2

**What is the GCS for a 29-year-old woman s/p skiing accident into a tree who is intubated; eyes closed even to pain, decorticate posturing only?**

5T: eyes = 1, intubated = IT, motor = 3

**28-year-old man involved in high-speed MVC with lower back spine fracture, bladder/bowel incontinence, decreased lower extremity sensation, and decreased lower extremity strength**

Cauda equina syndrome

**24-year-old woman with spine fracture; paraplegia but with touch and proprioception intact**

Anterior spinal cord syndrome

**29-year-old man s/p 45-foot fall with left-sided loss of temperature and pain sensation; right-sided paresis and loss of**

**right-sided proprioception**

Brown–Séquard syndrome

**18-year-old woman with a cervical spinal fracture after diving into a shallow pool; intact perianal sensation and decreased lower extremity sensation and movement**

Central cord syndrome

**50-year-old woman with painless proptosis and a brain tumor stuck to the dura**

Meningioma

**19-year-old woman involved in a high-speed MVC and was thrown unrestrained into the windshield; she has a GCS of 15 at the scene and initially upon admission to the ER; she then becomes comatose with a GCS of 3**

Epidural hematoma and “lucid interval”

**Patient with head trauma and a peripheral “crescent”-shaped hematoma on CT scan**

Subdural hematoma

**Patient with head trauma and a peripheral “lenticular” (lens-like) hematoma on CT scan**

Epidural hematoma

**Hypoxia after brain injury without lung injury, no fractures, no DVTs**

Neurogenic pulmonary edema

**Coagulopathy after isolated brain injury**

Brain thromboplastin

**40-year-old s/p fall from a balcony, GCS of 3, heart rate 40, SBP of 190/90, blown right pupil**

Elevated ICP with brain herniation

**22-year-old female s/p MVC, GCS of 3, nl brain CT scan, nl brain MRI, nl EEG**

Cervical vascular injury (e.g., carotid artery dissection with thrombosis)

**21-year-old male s/p MVC with hypotension, bradycardia, nl CXR, nl FAST exam, nl pelvic x-ray**

Spinal cord injury with neurologic shock

**39-year-old woman lifting weights has onset of lower back pain, cannot urinate, and is passing flatus that she cannot control; on exam, the bladder is distended, poor rectal tone, and perineal skin numbness (anesthesia)**

Cauda equina syndrome

**29-year-old diabetic with chronic bacterial sinusitis, new-onset seizures, fever, and right-sided weakness**

Brain abscess

**40-year-old male with chronic low back pain lifts a refrigerator and experiences severe pain shooting down his right leg out his right big toe**

Herniated disc at L4–L5

**Name the diagnostic modality:**

**18-year-old female with fall from horse with loss of consciousness**

Brain CT scan without contrast

**39-year-old female librarian with acute loss of hearing in her left ear**

MRI to rule out acoustic nerve neuroma

**What is the treatment?**

**28-year-old male s/p motorcycle collision, presents with eyes closed, not making any verbal sounds, decorticate posturing to**

**painful stimuli**

GCS of 5 and in a “coma”; must be intubated

**34-year-old female with small prolactinoma**

Bromocriptine (transsphenoidal resection if refractory)

**Name the radiographic test for localizing the following:**

**Pituitary adenoma?**

Gadolinium-enhanced MRI

# Chapter 75 Urology

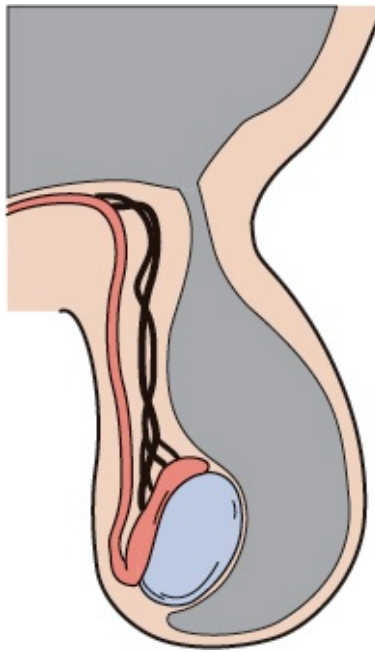
**Define the following terms:**

## **Hydrocele**

Clear fluid in the processus vaginalis membrane

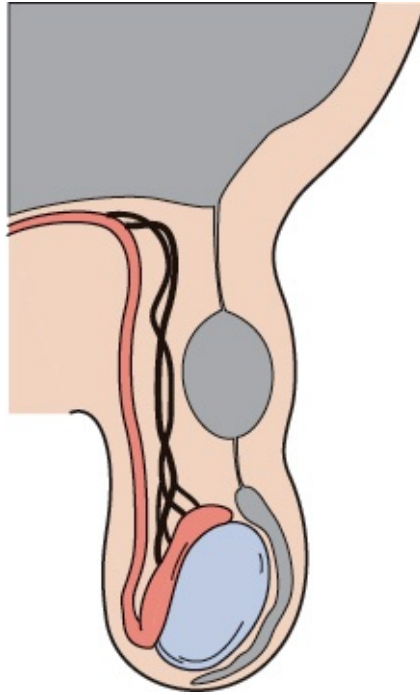
## **Communicating hydrocele**

Hydrocele that communicates with peritoneal cavity and, thus, gets smaller and larger as fluid drains and then reaccumulates



## **Noncommunicating hydrocele**

Hydrocele that does not communicate with the peritoneal cavity; hydrocele remains the same size



### **Varicocele**

Abnormal dilation of the pampiniform plexus to the spermatic vein in the spermatic cord; described as a “bag of worms”

## **UROLOGIC DIFFERENTIAL DIAGNOSIS**

### **What is the differential diagnosis of scrotal mass?**

Cancer, torsion, epididymitis, hydrocele, spermatocele, varicocele, inguinal hernia, testicular appendage, swollen testicle after trauma, nontesticular tumor (paratesticular tumor: e.g., rhabdomyosarcoma, leiomyosarcoma, liposarcoma)

### **What are the causes of hematuria?**

Bladder cancer, trauma, UTI, cystitis from chemotherapy or radiation, stones, kidney lesion, BPH

### **What is the most common cause of severe gross hematuria without trauma or chemotherapy/radiation?**

Bladder cancer

### **What is the differential diagnosis for bladder outlet obstruction?**

BPH, stone, foreign body, urethral stricture, urethral valve

### **What is the differential diagnosis for ureteral obstruction?**

Stone, tumor, iatrogenic (suture), stricture, gravid uterus, radiation injury, retroperitoneal fibrosis

### **What is the differential diagnosis for kidney tumor?**

Renal cell carcinoma, sarcoma, adenoma, angiomyolipoma, hemangiopericytoma, oncocytoma

## **RENAL CELL CARCINOMA (RCC)**

### **What is it?**

Most common solid renal tumor (90%); originates from proximal renal tubular epithelium

### **What is the epidemiology?**

Primarily a tumor of adults 40 to 60 years of age with a 3:1 male-to-female ratio; 5% of cancers overall in adults

### **What are the risk factors?**

Male sex, tobacco, von Hippel–Lindau syndrome, polycystic kidney

### **What are the symptoms?**

Pain (40%), hematuria (35%), weight loss (35%), flank mass (25%), HTN (20%)

### **What is the classic TRIAD of renal cell carcinoma?**

- . Flank pain
- . Hematuria
- . Palpable mass

(**Triad** occurs in only 10% to 15% of cases)

### **How are most cases diagnosed these days?**

Found incidentally on an imaging study (CT scan, MRI, U/S) for another reason

### **What radiologic tests are performed?**

- . IVP

- . Abdominal CT scan with contrast

### **What is the metastatic workup?**

CXR, IVP, CT scan, LFTs, calcium

### **What are the sites of metastases?**

Lung, liver, brain, bone; tumor thrombus entering renal vein or IVC is not uncommon

### **What is the unique route of spread?**

Tumor thrombus into **IVC lumen**

### **What is the treatment of RCC?**

Radical nephrectomy (excision of the kidney and adrenal, including Gerota's fascia) for stages I through IV

### **What gland is removed with a radical nephrectomy?**

Adrenal gland

### **What is the unique treatment for metastatic spread?**

- .  $\alpha$ -interferon
- . **LAK** cells (**L**ymphokine-**A**ctivated **K**iller) and IL-2 (interleukin-2)

### **What is a syndrome of RCC and liver disease?**

Stauffer's syndrome

### **What is the concern in an adult with new-onset left varicocele?**

Left RCC—the left gonadal vein drains into the left renal vein

## **BLADDER CANCER**

### **What is the incidence?**

Second most common urologic malignancy

Male-to-female ratio of 3:1

White patients are more commonly affected than are African American patients

### **What is the most common histology?**

**Transitional Cell Carcinoma (TCC)**—90%; remaining cases are squamous or adenocarcinomas

**What are the risk factors?**

**Smoking**, industrial carcinogens (aromatic amines), schistosomiasis, truck drivers, petroleum workers, cyclophosphamide

**What are the symptoms?**

**Hematuria**, with or without irritative symptoms (e.g., dysuria), frequency

**What is the classic presentation of bladder cancer?**

“Painless hematuria”

**What tests are included in the workup?**

Urinalysis and culture, IVP, cystoscopy with cytology and biopsy

**What is the treatment according to stage:**

**Stage 0?**

TURB and intravesical chemotherapy

**Stage I?**

TURB

**Stages II and III?**

Radical cystectomy, lymph node dissection, removal of prostate/uterus/ovaries/anterior vaginal wall, and urinary diversion (e.g., ileal conduit) ± chemo

**Stage IV?**

± Cystectomy and systemic chemotherapy

**What are the indications for a partial cystectomy?**

Superficial, isolated tumor, apical with 3-cm margin from any orifices

**What is TURB?**

TransUrethral Resection of the Bladder

**If after a TURB the tumor recurs, then what?**

Repeat TURB and intravesical chemotherapy (mitomycin C) or bacillus Calmette-Guérin

**What is and how does bacillus Calmette-Guérin work?**

Attenuated TB vaccine—thought to work by immune response

## PROSTATE CANCER

**What is the incidence?**

**Most common** GU cancer (>100,000 new cases per year in the United States); most common carcinoma in U.S. men; second most common cause of death in U.S. men

**What is the epidemiology?**

“Disease of elderly men” present in 33% of men 70 to 79 years of age and in 66% of men 80 to 89 years of age at autopsy; African American patients have a 50% higher incidence than do White patients

**What is the histology?**

Adenocarcinoma (95%)

**What are the symptoms?**

Often asymptomatic; usually presents as a nodule found on routine rectal examination; in 70% of cases cancer begins in the **periphery** of the gland and moves centrally; thus, obstructive symptoms occur late

**What percentage of patients have metastasis at diagnosis?**

40% of patients have metastatic disease at presentation, with symptoms of bone pain and weight loss

**What are the common sites of metastasis?**

Osteoblastic bony lesions, lung, liver, adrenal

**What provides lymphatic drainage?**

Obturator and hypogastric nodes

**What is the significance of Batson's plexus?**

Spinal cord venous plexus; route of isolated skull/brain metastasis

**What are the steps in early detection?**

- . Prostate-specific antigen (PSA)—most sensitive and specific marker
- . Digital rectal examination (DRE)

**When should men get a PSA-level check?**

Controversial:

1. All men >50 years old
2. >40 years old if first-degree family history or African American patient

**What percentage of patients with prostate cancer will have an elevated PSA?**

≈60%

**What is the imaging test for prostate cancer?**

TransRectal UltraSound (TRUS)

**How is the diagnosis made?**

Transrectal biopsy

**What is the Gleason score?**

Histologic grades 2 to 10:

- Low score = well differentiated
- High score = poorly differentiated

**What are the indications for transrectal biopsy with normal rectal examination?**

PSA >10 or abnormal transrectal ultrasound

**What does a "radical prostatectomy" remove?**

- . Prostate gland
- . Seminal vesicles
- . Ampullae of the vasa deferentia

**What is "androgen ablation" therapy?**

- . Bilateral orchiectomy or
- . Luteinizing **H**ormone–**R**eleasing **H**ormone (**LHRH**) agonists

**What are the generalized treatment options according to stage:**

**Stage I?**

Radical prostatectomy

**Stage II?**

Radical prostatectomy, ± lymph node dissection

**Stage III?**

Radiation therapy, ± androgen ablation

**Stage IV?**

Androgen ablation, radiation therapy

**What is the medical treatment for systemic metastatic disease?**

Androgen ablation

**What is the option for treatment in the early-stage prostate cancer patient >70 years old with comorbidity?**

XRT

## **BENIGN PROSTATIC HYPERPLASIA**

**What is it also known as?**

BPH

**What is it?**

Disease of elderly men (average age is 60 to 65 years); prostate gradually enlarges, creating symptoms of urinary outflow obstruction

**What is the size of a normal prostate?**

20 to 25 g

**Where does BPH occur?**

Periurethrally (**Note:** Prostate cancer occurs in the periphery of the gland)

### **What are the symptoms?**

Obstructive-type symptoms: hesitancy, weak stream, nocturia, intermittency, UTI, urinary retention

### **How is the diagnosis made?**

History, DRE, elevated **PostVoid Residual (PVR)**, urinalysis, cystoscopy, U/S

### **What lab tests should be performed?**

Urinalysis, PSA, BUN, CR

### **What is the differential diagnosis?**

**Prostate cancer** (e.g., nodular)—biopsy

Neurogenic bladder—history of neurologic disease

Acute prostatitis—hot, tender gland

Urethral stricture—RUG, history of STD

Stone

UTI

### **What are the treatment options?**

Pharmacologic— $\alpha$ -1 blockade

Hormonal—antiandrogens

Surgical—TURP, TUIP, open prostate resection

Transurethral balloon dilation

### **Why do $\alpha$ adrenergic blockers work?**

- . Relax sphincter
- . Relax prostate capsule

### **What is Proscar®?**

Finasteride: 5- $\alpha$ -reductase inhibitor; blocks transformation of testosterone to dihydrotestosterone; may shrink and slow progression of BPH

### **What is Hytrin®?**

Terazosin:  $\alpha$ -blocker; may increase urine outflow by relaxing prostatic smooth muscles

## **What are the indications for surgery in BPH?**

Because of obstruction:

- Urinary retention
- Hydronephrosis
- UTIs
- Severe symptoms

## **What is TURP?**

**TransUrethral Resection of Prostate:** resection of prostate tissue via a scope

## **What is TUIP?**

**TransUrethral Incision of Prostate**

## **What percentage of tissue removed for BPH will have malignant tissue on histology?**

Up to 10%!

## **What are the possible complications of TURP?**

Immediate:

- Failure to void
- Bleeding
- Clot retention
- UTI
- Incontinence

# **TESTICULAR CANCER**

## **What is the incidence?**

Rare; Two to three new cases per 100,000 men per year in the United States

## **What is its claim to fame?**

Most common solid tumor of young adult males (20 to 40 years)

## **What are the risk factors?**

Cryptorchidism (6% of testicular tumors develop in patients with a history of cryptorchidism)

### **What is cryptorchidism?**

Failure of the testicle to descend into the scrotum

### **Does orchiopexy as an adult remove the risk of testicular cancer?**

NO

### **What are the symptoms?**

Most patients present with a painless lump, swelling, or firmness of the testicle; they often notice it after incidental trauma to the groin

### **What percentage of patients present with an acute hydrocele?**

10%

### **What percentage present with symptoms of metastatic disease (back pain, anorexia)?**

≈10%

### **What is the major classification based on therapy?**

Seminomatous and nonseminomatous tumors

### **What are the tumor markers for testicular tumors?**

- .  $\beta$ -Human chorionic gonadotropin ( $\beta$ -HCG)
- .  $\alpha$ -Fetoprotein (AFP)

### **What are the tumor markers by tumor type?**

$\beta$ -HCG—↑ in choriocarcinoma (100%), embryonal carcinoma (50%), and rarely in pure seminomas (10%); nonseminomatous tumors (50%)

AFP—↑ in embryonal carcinoma and yolk sac tumors; nonseminomatous tumors (50%)

### **Define the difference between seminomatous and NONseminomatous germ cell testicular tumor markers.**

NONseminomatous **common** = 90% have a positive AFP and/or  $\beta$ -HCG

Seminomatous **rare** = **only** 10% are AFP positive

### **In which tumor is $\beta$ -HCG almost always found elevated?**

Choriocarcinoma

**What other tumor markers may be elevated and useful for recurrence surveillance?**

LDH, CEA, **H**uman **C**horionic **S**omatomammotropic (**HCS**), **G**amma-**G**lutamyl **T**ranspeptidase (**GGT**), **P**Lacental **P**hosphate (**PLAP**)

**What are the steps in workup?**

PE, scrotal U/S, check tumor markers, CXR, CT scan (chest/pelvis/abd)

**Define the stages according to TMN staging (AJCC):**

**Stage I?**

Any tumor size, no nodes, no metastases

**Stage II?**

**Positive** nodes, no metastases, any tumor

**Stage III?**

Distant **metastases** (any nodal status, any size tumor)

**What is the initial treatment for all testicular tumors?**

**Inguinal** orchiectomy (removal of testicle through a groin incision)

**What is the treatment of *seminoma* at the various stages:**

**Stage I and II?**

Inguinal orchiectomy and **radiation** to retroperitoneal nodal basins

**Stage III?**

Orchiectomy and chemotherapy

**What is the treatment of NONseminomatous disease at the various stages:**

**Stages I and II?**

Orchiectomy and retroperitoneal lymph node **dissection** versus close follow-up for retroperitoneal nodal involvement

**Stage III?**

Orchiectomy and chemotherapy

**What percentage of stage I seminomas are cured after treatment?**

95%

**Which type is most radiosensitive?**

Seminoma (Think: Seminoma = Sensitive to radiation)

**Why not remove testis with cancer through a scrotal incision?**

It could result in tumor seeding of the scrotum

**What is the major side effect of retroperitoneal lymph node dissection?**

Erectile dysfunction

## TESTICULAR TORSION

**What is it?**

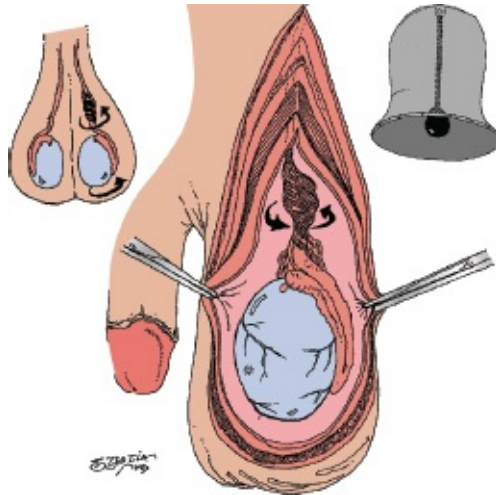
Torsion (twist) of the spermatic cord, resulting in venous outflow obstruction, and subsequent arterial occlusion → infarction of the testicle

**What is the classic history?**

Acute onset of scrotal pain usually after vigorous activity or minor trauma

**What is a “bell clapper” deformity?**

Bilateral nonattachment of the testicles by the gubernaculum to the scrotum (free like the clappers of a bell)

**What are the symptoms?**

Pain in the scrotum, suprapubic pain

**What are the signs?**

Very tender, swollen, elevated testicle; nonillumination; absence of cremasteric reflex

**What is the differential diagnosis?**

Testicular trauma, inguinal hernia, epididymitis, appendage torsion

**How is the diagnosis made?**

Surgical exploration, U/S (solid mass) and Doppler flow study

**What is the treatment?**

Surgical detorsion and bilateral orchiopexy to the scrotum

**How much time is available from the onset of symptoms to detorse the testicle?**

<6 hours will bring about the best results

**What are the chances of testicle salvage after 24 hours?**

<10%

## EPIDIDYMITIS

**What is it?**

Infection of the epididymis

**What are the signs/symptoms?**

Swollen, tender testicle; dysuria; scrotal ache/pain; fever; chills; scrotal mass

**What is the cause?**

Bacteria from the urethra

**What are the common bugs in the following types of patients:****Elderly patients/children?**

*Escherichia coli*

**Young men?**

STD bacteria: Gonorrhea, chlamydia

**What is the major differential diagnosis?**

Testicular torsion

**What is the workup?**

U/A, urine culture, swab if STD suspected, ± U/S with Doppler or nuclear study to rule out torsion

**What is the treatment?**

Antibiotics

## PRIAPISM

**What is priapism?**

Persistent penile erection

**What are its causes?**

Low flow: leukemia, drugs (e.g., prazosin), sickle-cell disease, erectile dysfunction treatment gone wrong

High flow: pudendal artery fistula, usually from trauma

### What is first line treatment?

- . Aspiration of blood from corpus cavernosum
- .  $\alpha$ -Adrenergic agent

## ERECTILE DYSFUNCTION

### What is it?

Inability to achieve an erection

### What are the six major causes?

- . **Vascular:** decreased blood flow or leak of blood from the corpus cavernosus (most common cause)
- . **Endocrine:** low testosterone
- . **Anatomic:** structural abnormality of the erectile apparatus (e.g., Peyronie's disease)
- . **Neurologic:** damage to nerves (e.g., postoperative, IDDM)
- . **Medications** (e.g., clonidine)
- . **Psychologic:** performance anxiety, etc. (very rare)

### What lab tests should be performed?

Fasting GLC (rule out diabetes and thus diabetic neuropathy)

Serum testosterone

Serum prolactin

## CALCULUS DISEASE

### What is the incidence?

1 in 10 people will have stones

### What are the risk factors?

Poor fluid intake, IBD, hypercalcemia ("CHIMPANZEES"), renal tubular acidosis, small bowel bypass

### What are the four types of stones?

- . Calcium oxalate/calcium PO<sub>4</sub> (75%)—secondary to hypercalciuria ( $\uparrow$  intestinal

- absorption, ↓ renal reabsorption, ↑ bone reabsorption)
- . Struvite (MgAmPh) (15%)—infection stones; seen in UTI with urea-splitting bacteria (*Proteus*); may cause staghorn calculi; high urine pH
  - . Uric acid (7%)—stones are radiolucent (Think: **U**ric = **U**nseen); seen in gout, Lesch–Nyhan, chronic diarrhea, cancer; low urine pH
  - . Cystine (1%)—genetic predisposition

### **What type of stones is not seen on AXR?**

Uric acid (Think: **U**ric = **U**nseen)

### **What stone is associated with UTIs?**

Struvite stones (Think: Struvite = Sepsis)

### **What stones are seen in IBD/bowel bypass?**

Calcium oxalate

### **What are the symptoms of calculus disease?**

Severe pain; patient cannot sit still: renal colic (typically pain in the kidney/ureter that radiates to the testis or penis), hematuria (remember, patients with peritoneal signs are motionless)

### **What are the classic findings/symptoms?**

Flank pain, stone on AXR, hematuria

### **Diagnosis?**

KUB (90% radiopaque), IVP, urinalysis and culture, BUN/Cr, CBC

### **What is the significance of hematuria and pyuria?**

Stone with concomitant infection

### **Treatment?**

Narcotics for pain, vigorous hydration, observation

Further options: ESWL (lithotripsy), ureteroscopy, percutaneous lithotripsy, open surgery; metabolic workup for recurrence

### **What are the indications for intervention?**

Urinary tract obstruction

Persistent infection

Impaired renal function

### **What are the contraindications of outpatient treatment?**

Pregnancy, diabetes, obstruction, severe dehydration, severe pain, urosepsis/fever, pyelonephritis, previous urologic surgery, only one functioning kidney

### **What are the three common sites of obstruction?**

- . UreteroPelvic Junction (UPJ)
- . UreteroVesicular junction (UVJ)
- . Intersection of the ureter and the iliac vessels

## **INCONTINENCE**

### **What are the common types of incontinence?**

Stress incontinence, overflow incontinence, urge incontinence

### **Define the following terms:**

#### **Stress incontinence**

Loss of urine associated with coughing, lifting, exercise, etc.; seen most often in women, secondary to relaxation of pelvic floor following multiple deliveries

#### **Overflow incontinence**

Failure of the bladder to empty properly; may be caused by bladder outlet obstruction (BPH or stricture) or detrusor hypotonicity

#### **Urge incontinence**

Loss of urine secondary to detrusor instability in patients with stroke, dementia, Parkinson's disease, etc.

#### **Mixed incontinence**

Stress **and** urge incontinence combined

#### **Enuresis**

Bedwetting in children

### **How is the diagnosis made?**

History (including meds), physical examination (including pelvic/rectal examination), urinalysis, **PostVoid Residual (PVR)**, urodynamics, cystoscopy/**VesicoCystoUrethroGram (VCUG)** may be necessary

### **What is the “Marshall test”?**

Woman with urinary stress incontinence placed in the lithotomy position with a full bladder leaks urine when asked to cough

### **What is the treatment of the following disorders:**

#### **Stress incontinence?**

Bladder neck suspension

#### **Urge incontinence?**

Pharmacotherapy (anticholinergics,  $\alpha$ -agonists)

#### **Overflow incontinence?**

Self-catheterization, surgical relief of obstruction,  $\alpha$ -blockers

## **URINARY TRACT INFECTION (UTI)**

### **What is the etiology?**

Ascending infection, instrumentation, coitus in females

### **What are the three common organisms?**

- . *E. coli* (90%)
- . *Proteus*
- . *Klebsiella*

### **What are the predisposing factors?**

Stones, obstruction, reflux, diabetes mellitus, pregnancy, indwelling catheter/stent

### **What are the symptoms?**

Lower UTI—frequency, urgency, dysuria, nocturia  
Upper UTI—back/flank pain, fever, chills

### **How is the diagnosis made?**

Symptoms, urinalysis ( $>10$  WBCs/HPF,  $>10^5$  CFU)

### **When should workup be performed?**

After the first infection in male patients (unless Foley is in place)  
After the first pyelonephritis in prepubescent female patients

### **What is the treatment?**

Lower: 1 to 4 days of oral antibiotics  
Upper: 3 to 7 days of IV antibiotics

## **MISCELLANEOUS UROLOGY QUESTIONS**

### **What is the most common intraoperative bladder tumor?**

Foley catheter—don't fall victim!

### **What provides drainage of the left gonadal (e.g., testicular) vein?**

Left renal vein

### **What provides drainage of the right gonadal vein?**

IVC

### **What are the signs of urethral injury in the trauma patient?**

“High-riding, ballottable” prostate, blood at the urethral meatus, severe pelvic fracture, ecchymosis of scrotum

### **What is the evaluation for urethral injury in the trauma patient?**

RUG (Retrograde UrethroGram)

### **What is the evaluation for a transected ureter intraoperatively?**

IV indigo carmine and then look for leak of blue urine in the operative field

### **What aid is used to help identify the ureters in a previously radiated retroperitoneum?**

Ureteral stents

**How can a small traumatic EXTRAperitoneal bladder rupture be treated?**

Foley catheter

**How should a traumatic INTRAperitoneal bladder rupture be treated?**

Operative repair

**What is the classic history for papillary necrosis?**

Patient with diabetes taking NSAIDs or patient with sickle cell trait

**What is Fournier's gangrene?**

Necrotizing fasciitis of perineum, polymicrobial, diabetes = major risk factor

**What unique bleeding problem can be seen with prostate surgery?**

Release of TPA and urokinase (treat with  $\epsilon$ -aminocaproic acid)

**What is the scrotal "blue dot" sign?**

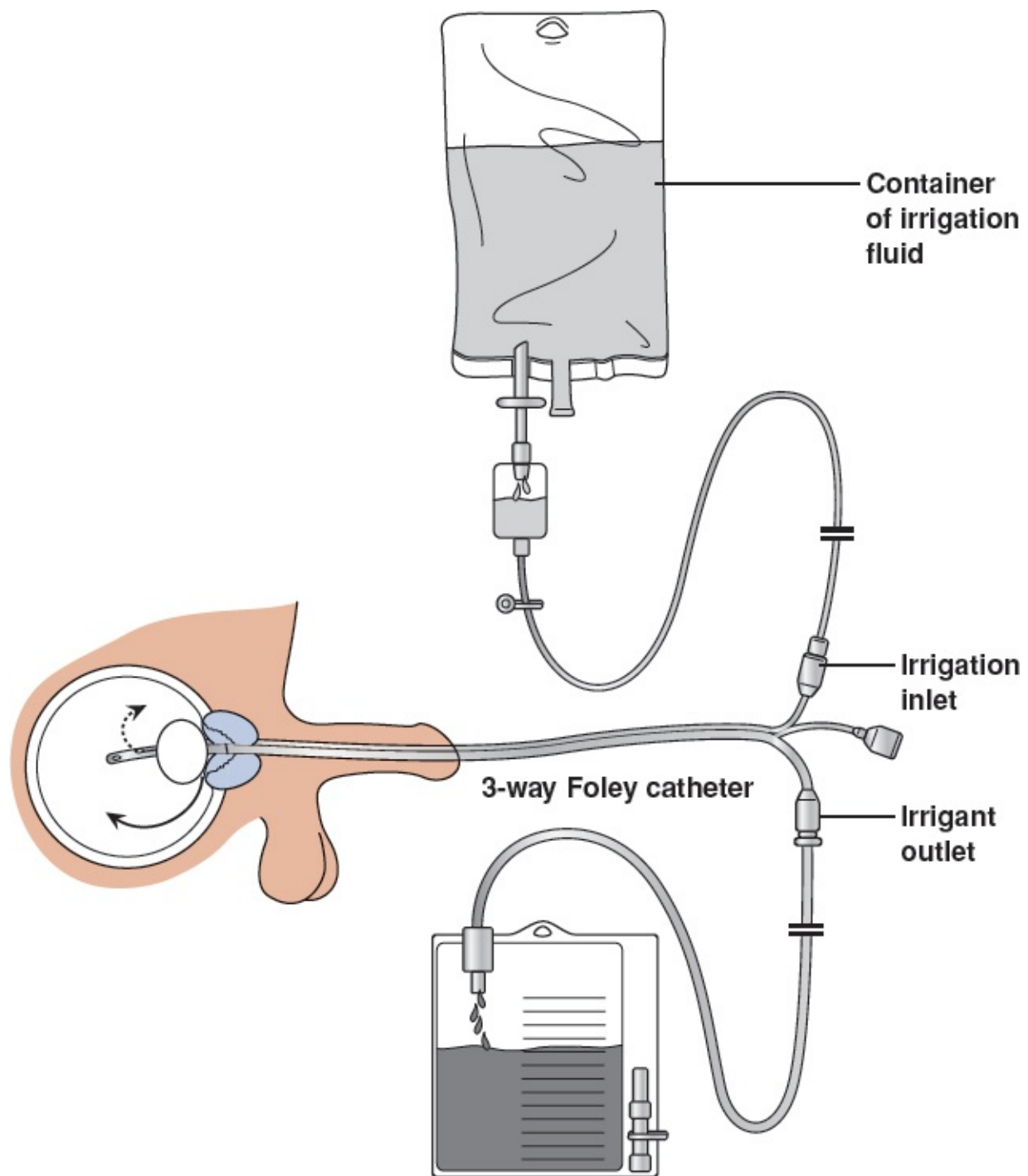
Torsed appendix testis

**What is Peyronie's disease?**

Curved penile orientation with erection due to fibrosis of corpora cavernosa

**What is a "three-way" irrigating Foley catheter?**

Foley catheter that irrigates and then drain



## RAPID FIRE REVIEW

What is the correct diagnosis?

**Abdominal pain, flank mass, hematuria**

Renal cell carcinoma

**Acute varicocele and hematuria**

Left renal tumor

**56-year-old male presents with right sided flank pain; cannot sit still, blood in his urine, and fever; x-ray nl; no mass palpated on exam**

Nephrolithiasis due to uric acid stone with obstructive urinary infection

**60-year-old White male smoker who works at a refinery develops hematuria; no pain or other symptoms**

Bladder cancer (“painless hematuria”)

**Name the most likely diagnosis:**

**70-year-old male retired leather worker, cigarette smoker; presents with painless gross hematuria**

Bladder transitional cell carcinoma

**22-year-old male who develops a right scrotal hydrocele with elevated serum  $\beta$ -HCG**

Testicular cancer

**55-year-old woman with diabetes, recurrent pyelonephritis, increased creatinine, increased BUN; IVP reveals radiolucent defects in the kidney collecting system**

Papillary necrosis

**31-year-old man with right flank pain radiating into scrotum, gross hematuria, right-sided hydronephrosis, and normal abdominal x-ray**

Uric acid kidney stone

**18-year-old women with fever; costovertebral tenderness; flank mass; and WBCs, RBCs, and gram-negative rods in the urine**

Kidney (renal) abscess

**65-year-old man with groin pain who goes into septic shock after a rectal prostatic exam**

Bacterial prostatitis

**19-year-old man status post (s/p) spinal anesthetic for a groin hernia repair returns to clinic with back pain, fever, and decreased left lower extremity sensation and movement**

Epidural abscess

**Name the diagnostic modality:**

**80-year-old male with history of intermittent hematuria; CT scan is normal**

Cystoscopy to rule out bladder cancer

**27-year-old male s/p MVC with pelvic fracture and blood at the urethral meatus**

Retrograde urethrogram (RUG) to rule out urethral injury

**30-year-old female with a pelvic fracture and free fluid in the pelvis**

CT scan with CT cystogram to rule out bladder injury

# Index

*Note:* Page locators followed by f indicates figure.

## A

- AB blood group, 80
- Abdomen
  - acute, 132–134
  - pain in, 132–135, 236
  - radiologic studies, 121–124, 121f–124f
  - wall, layers of, 139
- Abdominal aortic aneurysm (AAA), repair of, 51, 51f
- Abdominal compartment syndrome, 99
- Abdominal perineal resection (APR), 214
- Abdominal trauma, 11
- Abdominal wall, layers of, 139
- Abdominal wound dehiscence, 54
- Abdominoperineal resection (APR), 46
- Abduction, 489
- Abscess, 111
  - breast, 292–293
  - drainage of, 37, 37f
  - of liver, 244–246
    - amebic, 245
    - bacterial, 244–245
    - hydatid liver cyst, 245–246
  - pancreatic, 272

- Absorbable sutures, [20](#)
- Absorption atelectasis, [103](#)
- ACE inhibitors, [88](#)
- Acid chemical burns, [166](#)
- Acquired heart disease, [456–457](#)
  - aortic stenosis, [459](#)
  - CABG, [457](#)
  - cardiopulmonary bypass, [458](#)
  - coronary artery disease, [456](#)
  - mitral stenosis, [462](#)
  - postpericardiotomy syndrome, [457](#)
- Acral lentiginous melanoma, [335](#)
- Actinic keratosis, [333](#)
- Actinomyces, [116](#), [117](#)
- Acute abdomen, [132–134](#)
  - surgery, in United States, [132](#)
- Acute acalculous cholecystitis, [259–260](#)
- Acute appendicitis, [10](#)
  - surgical percentages, [11](#)
- Acute arterial occlusion, [355](#)
- Acute cholecystitis, [258–259](#)
- Acute mesenteric ischemia, [358](#)
- Acute pancreatitis, [11](#), [267–269](#)
- Acute renal failure, lab values, [340–341](#)
- Acute respiratory distress syndrome, [343](#)
- Acute respiratory distress syndrome (ARDS), [8](#)
- Acute sinusitis, [421](#)
- Acute suppurative otitis media (OM), [417](#)
- Addisonian crisis, [94–95](#), [95f](#)
- Addison's disease, [301](#)
- Adduction, [489](#)
- Adenomatous polyposis coli (APC) gene, [216](#)

- Adrenal adenoma, 296
- Adrenal carcinoma, 296
- Adrenal gland, 294–301
- Adreno cortico tropic hormone (ACTH), 295
- Adson pickup, 14, 14f
- Advanced Trauma Life Support (ATLS) protocol, 148
- AEIOU, for dialysis, 98
- Afferent loop syndrome, 8
- Afterload, 342
- Aganglionic megacolon, 384
- A-gram, 234
- Airway, assessment of, 148–149, 149f
- Airway pressure release ventilation, 346
- Alcohol, 11
  - antibiotics with, 84
  - withdrawal, 102
- Alkali chemical burns, 166
- Allen's test, 3, 3f
- Allis clamp, 17, 17f
- Allograft bone, 489
- Allograft STSG, 168
- Amaurosis fugax, 359
- Amebic liver abscess, 245
- Amelanotic melanoma, 335
- Aminoglycoside, 85
- Amoebic infections, antibiotics for, 84
- Amphotericin, 85
- Anaerobic infections, 85
  - antibiotics for, 84
- Anal cancer, 224–231
- Anal fissure, 228–229, 229f
  - position of, 11

- Anaphylactic shock, [110](#)
- Anaplastic carcinoma, [317–318](#)
- Androgen ablation therapy, [533](#)
- Anesthesia, [124–127](#)
- Annular pancreas, [276](#), [396](#)
- Anorectal fistulas, [227](#)
- Anorectal malformations, [383](#)
- Anterior cord syndrome, [519](#)
- Anterior hip dislocation, [163](#), [163f](#)
- Anterior spinal syndrome, [65](#), [65f](#)
- Antibrogram, [84](#)
- Antibiotics, [84–85](#)
  - with alcohol, [84](#)
  - for amoebic infections, [84](#)
  - for anaerobic infections, [84](#)
  - with cholestasis, [84](#)
  - for gram-negative infections, [84](#)
  - not for children/pregnant women, [84](#)
- Antidiuretic hormone (ADH), [95](#), [96](#)
- Antrectomy, [53](#)
  - vagotomy and, [178](#)
- Anus, [224–232](#)
  - anal cancer, [224–231](#)
  - anatomy of, [224](#), [224f](#)
- Aortic insufficiency (AI), [460](#)
- Aortic stenosis (AS), [459](#)
- Aphthous ulcer, [128](#)
- Appendectomy, [48](#)
- Appendiceal artery, [198](#)
- Appendiceal tumors, [202–203](#)
- Appendicitis, [10](#), [133](#), [199–202](#), [391](#)
  - antibiotics in, [201](#)

- causes, [199](#)
- complications of, [202](#)
- differential diagnosis, [200](#)
- nonperforated, [201](#)
- perforated, [201](#)
- radiographic studies, [201](#)
- signs/symptoms, [199](#)
- surgical percentages, [11](#)
- tests for, [200](#)
- Appendix, [198–203](#)
  - appendicitis, [199–202](#)
  - blood supply to, [198](#)
  - intraoperative questions, [202](#)
  - mesentery of, [198](#)
  - tracing of, [65](#)
  - tumors, [202–203](#)
- Army–navy retractor, [19f](#)
- Artery, layers of, [66](#), [66f](#)
- Artery of Adamkiewicz, [65](#), [65f](#)
- Arthritis, [507–508](#)
- Arthrodesis, [491](#)
- Arthroplasty, [491](#)
- Artificial valve placement, [463](#)
- Aspirated foreign body (FB), [371](#)
- Aspiration pneumonia, [92](#)
- Aspirin, [80](#), [81](#)
- Atelectasis, [11](#), [89](#)
- Augmentin, [84](#), [85](#)
- Auscultation, abdomen, [132](#)
- Autograft STSG, [168](#)
- Ax Fem, [51](#), [51f](#)
- Axilla, nerves in, [278–279](#), [279f](#)

- Axillary vein, [279](#)
- Aztreonam (Azactam), [84](#), [85](#)

## B

- Babcock clamp, [16](#), [16f](#)
- Backwash ileitis, [236](#)
- Bacteremia, [110](#)
- Bacterial liver abscess, [244–245](#)
- *Bacteroides fragilis*, [85](#)
- Ballance's sign, [4](#)
- Bandage scissors, [14](#), [14f](#)
- Bariatric surgery, [188–190](#), [189f–190f](#)
- Barrett's esophagus, [183](#)
- Basal cell carcinoma, [333](#)
- Bassini procedure, [141](#)
- Battle's sign, [4](#), [4f](#)
- Beck's triad, [4](#), [4f](#), [152](#)
- Beckwith–Wiedemann syndrome, [398](#)
- Bell clapper deformity, [537](#)
- Bell's Palsy, [419](#)
- Benign breast disease, [291](#)
- Benign prostatic hyperplasia, [533–535](#)
- Benign thyroid disease, [318–319](#)
- Bennett's fracture, [495](#)
- Benzodiazepines, [87](#)
  - reversal of, [127](#)
- Berry aneurysm, [523](#)
- Bile, daily secretion, [69](#)
- Bile duct
  - adenocarcinoma of, [254](#)
  - cholangiocarcinoma of, [254](#)
  - epithelium, [252](#)

- obstruction, cause of, 10
- Bilhemia, 246
- Biliary atresia, 395
- Biliary colic, 254
- Biliary tract, 251–266, 395
  - acute acalculous cholecystitis, 259–260
  - acute cholecystitis, 258–259
  - anatomy of, 251–252, 251f, 252f
  - carcinoma of gallbladder, 263
  - cholangiocarcinoma, 264, 264f
  - cholangitis, 260–261, 260f
  - cholelithiasis, 257–258
  - diagnostic studies of, 255, 255f
  - gallstone ileus, 262–263, 262f
  - miscellaneous conditions, 265
  - obstructive jaundice, 256–257
  - pathophysiology of, 253–254
  - physiology of, 252–253
  - sclerosing cholangitis, 261–262
  - and surgery, 256
- Billroth II (BII) procedure, 45, 45f, 179, 179f
- Billroth I (BI) procedure, 45, 45f, 178, 178f
- Biloma, 254
- Biopsy, 54
- Bird's beak sign, 122, 122f
- Bladder cancer, 531–532
- Bladder candidiasis, 111
- Bleeding
  - esophageal varices, 349–350
  - GI (See GI bleeding)
- Blind loop syndrome, 8, 93
- Blood, 79–83

- infected with HIV, risk of, [80](#)
- products, [79–83](#)
- transfusion
  - cause of, [11](#)
  - and fever, [81](#)
  - Hgb and, [81](#)
- types, [80](#)
- vessels on rib, [64](#)
- Bloody diarrhea, in ulcerative colitis, [236](#)
- Blount's disease, [511](#)
- Blue dot sign, [542](#)
- Blumer's shelf, [4](#), [185](#)
- Body fluid
  - composition of, [67](#)
  - distribution by weight, [67](#), [67f](#)
  - extracellular, [67](#)
  - hypovolemia, response to, [68](#)
  - intracellular, [67](#)
- Body mass index (BMI), [188](#)
- Boerhaave's syndrome, [8](#), [181](#)
- Bolus, [70](#)
- Bovie electrocautery, [17](#), [17f](#), [83](#), [83f](#)
- Bowen's disease, [225](#), [334](#)
- Boxer's fracture, [496](#)
- Branchial cleft anomalies, [370](#)
- *BRCA1* gene, [280](#)
- *BRCA2* gene, [280](#)
- Breast, [278–294](#)
  - abscess, [292–293](#)
  - anatomy of, [278–280](#), [279f](#)
  - benign breast disease, [291](#)
  - bloody nipple discharge in young woman, [290](#)

- cancer, [11](#), [280–287](#)
  - adjuvant therapy for, [287](#)
  - axillary dissection, [286](#)
  - biopsy, indications for, [283](#)
  - biopsy for, [283](#), [284](#)
  - *BRCA1/BRCA2* and, [280](#)
  - differential diagnosis, [282](#)
  - history risk factors for, [280](#)
  - incidence of, [280](#)
  - infiltrating ductal, [10](#)
  - inflammatory carcinoma, [285](#)
  - lumpectomy for, [285](#)
  - male, [290](#)
  - mammogram, [282](#), [282f](#)
  - mammotome biopsy, [283](#)
  - misdiagnosed, [280](#)
  - modified radical mastectomy, [286](#)
  - needle localization biopsy, [283](#)
  - physical/anatomic risk factors for, [281](#)
  - preoperative staging, [284](#)
  - radiation therapy, indications for, [285](#)
  - reconstruction options, [286–287](#)
  - screening recommendations for, [282](#)
  - site of, [10](#)
  - sites of metastases, [285](#)
  - staging system for, [284–285](#)
  - symptoms/signs of, [281](#)
  - tamoxifen and, [286–287](#)
  - treatments of, [285](#)
  - types of, [10](#), [282](#)
  - in women with BRCA, [280](#)
- cystosarcoma phyllodes, [291](#)

- ductal carcinoma in situ in, [287–288](#), [287f](#)
- fibroadenoma, [291–292](#)
- fibrocystic disease, [292](#)
- ligaments, [280](#)
- lobular carcinoma in situ in, [289](#) [289f](#)
- lymphatic drainage of, [279](#)
- male gynecomastia, [293](#)
- mammogram, [282](#), [283](#)
- mastitis, [292](#)
- milk production, hormone for, [280](#)
- Paget's disease of, [290](#)
- Breast mass, [283](#), [284](#)
- Breast self-examination, [282](#)
- Breathing, assessment of, [149–152](#)
- Bright red blood per rectum (BRBPR), [232](#)
- Brooke formula, for burn resuscitation, [169](#)
- Brooke ileostomy, [46](#), [192](#), [192f](#)
- Brown–Séquard syndrome, [519](#)
- Budd–Chiari syndrome, [8](#), [249](#)
- Bullous Myringitis, [417](#)
- Bupivacaine (Marcaine), [126](#)
- Burns, [166–171](#)
  - airway management in, [169](#)
  - alkali chemical, [166](#)
  - antibiotic agents in, [170–171](#)
  - assessment, [168](#)
  - Brooke formula and, [169](#)
  - carbon monoxide inhalation, [171](#)
  - fever in patients, [170](#)
  - full-thickness, [167](#), [168](#)
  - level of, [166–167](#)
  - Parkland formula, [169](#)

- partial-thickness, 166–167, 168
- resuscitation, 168
- rule of nines, 167, 167f
- rule of palm, 168
- rule of 10's, 169
- severity, 167
- shock, 169
- smoke inhalation, 168–169
- split-thickness skin graft, 166, 168
- superficial, 166–167, 168
- tetanus prophylaxis in, 171
- total body surface area, 166
- ulcers injury with, 171
- wound infections, 170
- Burn shock, 169
- Butyrate, 106

## C

- Calcitonin, 312
- Calculus disease, 539–540
- Calot's node, 64, 252
- Calot's triangle, 64
- Canal cancer, 225
- Cancer
  - anal, 224–231
  - breast, 11, 280–287
    - infiltrating ductal, 10
    - site of, 10
    - type of, 10
  - canal, 225
  - in females, 11
  - gallbladder, 263

- lung, [11](#)
- in males, [11](#)
- margin, [225](#)
- prostate, [11](#)
- spread, [213](#)
- Cantle's line, [64](#), [241](#), [242](#)
- Caput medusae, [248](#)
- Carbohydrate antigen 19–9, [275](#)
- Carbon monoxide inhalation, [171](#)
- Carbuncle, [117](#)
- Carcinoid syndrome, [9](#), [204](#), [204f](#), [205](#), [205f](#)
- Carcinoid triad, [5](#)
- Carcinoid tumors, [202](#), [203–206](#), [204f–205f](#)
- Carcinoma of gallbladder, [263](#)
- Cardiac electrolytes, [78](#)
- Cardiac tamponade, [152](#)
- Cardiac tumors, [469](#)
- Cardiogenic shock, [109](#)
- Cardiovascular surgery, [456–474](#)
  - acquired heart disease, [456–457](#)
  - cardiac tumors, [469](#)
  - congenital heart disease, [465](#)
  - diseases of great vessels, [470](#)
- Carotid endarterectomy (CEA), [46](#)
  - incision, [41](#), [41f](#)
- Carotid vascular disease, [359–361](#)
  - anatomy, [359](#)
- Carpal tunnel syndrome, [413](#)
- Catheter-related bloodstream infections, [112](#)
- Cattel maneuver, [47](#)
- Cecal volvulus, [222–223](#), [222f](#)
- Cefazolin (Ancef), [85](#)

- Cefotetan, [84](#)
- Cefoxitin (Mefoxin), [84](#)
- Ceftazidime (Ceftaz), [85](#)
- Ceftriaxone (Rocephin), [84](#)
- Cellulitis, [111](#)
- Central cord syndrome, [519](#)
- Central line–associated bloodstream infection (CLABSI), [112](#)
- Central line infections, [112](#)
- Central lines, [63](#)
- Cephalosporins, [85](#)
- Cerebellar astrocytomas, [522](#)
- Cerebral contusion, [518](#)
- Cerebrovascular accident, [359](#)
- Cerebro vascular accident (CVA), postoperative, [97](#)
- Cervical disc disease, [525](#)
- Chance fracture, [520](#)
- Charcot’s triad, [5](#)
- Chemical burns, [166](#)
- Chest, radiology of, [120–121](#), [121f](#)
- Chest tubes, [56–60](#)
  - air leak, checking for, [60](#)
  - centimeter measurements on, [57](#)
  - connection, [58](#), [58f](#)
  - Heimlich valve, [60](#), [60f](#)
  - insertion of, [57](#), [57f](#)
  - Pleuravac box, [58–59](#)
  - positioning of, [57](#)
  - purpose of, [56](#)
  - removal of, [60](#)
  - run the system of, [60](#)
  - thoracostomy tube, [56](#)
  - tidling, [60](#)

- on water seal, [59](#)
- water seal chamber, [59](#)
- Chief cells, [182](#)
- Chilaiditi's sign, [123](#)
- Child's class, [240](#), [241](#)
- Cholangiocarcinoma, [254](#), [264](#), [264f](#), [396](#)
- Cholangitis, [254](#), [260–261](#), [260f](#)
- Cholecystectomy, [48](#), [256](#)
- Cholecystitis, [254](#), [254f](#)
- Cholecystokinin (CCK), [130](#), [253](#)
- Cholecystostomy tube, [56](#)
- Choledochal cyst, [396](#)
- Choledochojejunostomy, [49](#), [49f](#), [254](#)
- Choledocholithiasis, [10](#), [254](#), [254f](#), [258](#)
- Cholelithiasis, [253](#), [253f](#), [257–258](#), [396](#)
- Cholestasis, antibiotics with, [84](#)
- Cholesteatoma, [416](#)
- Chromium deficiency, [106](#)
- Chronic mesenteric ischemia, [358](#)
- Chronic pancreatitis, [11](#), [269–271](#)
- Chronic sinusitis, [422](#)
- Chvostek's sign, [5](#), [75](#)
- Ciprofloxacin (Cipro), [84](#), [85](#), [87](#)
- Circulation, assessment of, [152–154](#)
- Cirrhosis
  - and portal hypertension, [247](#)
- "Clean" wound, [113](#)
- Clindamycin, [84](#), [85](#), [87](#)
- Clonidine, [88](#)
- Clopidogrel, [80](#)
- Closed reduction, [489](#)
- Clostridial myositis, [115](#)

- *Clostridium difficile*, 85
- Closure, 21–22
- “Coffee bean” sign, 223
- Colic, 132
- Colles’ fracture, 495, 495f
- Colloid fluid, 78
- Colon, 65
  - anatomy of, 210–211, 210f
  - arterial blood supply to, 210, 210f
  - bacteria in, 116
  - cancer, 11, 80
  - colorectal carcinoma of, 211–215
  - diverticular disease of, 218–223
  - nutrient of, 106
  - nutritional source, 131
  - polyposis syndromes of, 216–218
  - polyps, 215–216
  - purpose of, 131
  - vs. small bowel, 65, 211
- Colonic fistulas, 208, 208f
- Colonic polyps, 215–216
- Colonic volvulus, 220–221
- Colonoscopy, 234
- Colorectal carcinoma, 211–215
  - adjuvant treatment for, 214
  - causes of, 211
  - diagnostic tests for, 212–213
  - differential diagnosis of, 212
  - incidence of, 211
  - LAR vs. APR in, 214
  - preoperative IV antibiotics in, 214
  - preoperative workup for, 213

- recommendations for, [212](#)
- risk factors, [211](#)
- signs/symptoms, [212](#)
- spread of, [213](#)
- survival rate from, [215](#)
- TNM stages, [213](#)
- treatment options, [214](#)
- Colostomy, [191](#)
- Colovesical fistula, [208](#)
- Communicating hydrocele, [378](#), [529](#)
- Compartment syndrome, [9](#), [356](#), [498](#)
- Compliance, [342](#)
- Congenital diaphragmatic hernia, [376](#)
- Congenital hip dislocation, [509](#)
- Congenital pyloric stenosis, [381](#)
- Congenital heart disease, [465](#)
  - coarctation of aorta, [467](#)
  - cyanotic heart disease, [469](#)
  - Ebstein's anomaly, [469](#)
  - IHSS, [467](#)
  - patent ductus arteriosus, [466](#)
  - transposition of great vessels, [468](#)
  - ventricular septal defect, [465](#)
- Conjoint tendon, [143](#)
- Connell's stitch, [25](#), [25f](#)
- Conn's syndrome, [300–301](#), [300f](#)
- Constipation, [93](#)
- Contaminated wound, [113](#)
- Continuous positive airway pressure, [346](#)
- Contractility, [342](#)
- Conventional cutting needle, [22](#), [22f](#)
- Cooper's ligaments, [280](#)

- Cordis, [63](#)
- Cord lipoma, [143](#)
- Coronary artery bypass grafting (CABG), [52](#), [52f](#)
- Corticotropin-releasing hormone (CRH), [294](#)
- Coudé catheter, [62](#), [62f](#)
- Courvoisier's gallbladder, [265](#)
- Courvoisier's law, [5](#)
- Courvoisier's sign, [275](#)
- Cranio-Caudal (C-C) mammogram, [124](#)
- Cricoid pressure, [125](#), [125f](#)
- Cricothyroidotomy, [47](#), [149](#), [149f](#)
- Crigler–Najjar syndrome, [395](#)
- Crohn's disease, [235–239](#)
  - anal involvement, [236](#)
  - anatomic distribution, [236](#)
  - bowel wall involvement, [236](#)
  - cancer risk, [237](#)
  - complications of, [237](#)
  - diagnostic tests, [237](#)
  - extraintestinal manifestations, [235](#)
  - incidence, [235](#)
  - initial symptoms, [236](#)
  - medical treatment of, [238](#)
  - mucosal findings, [237](#)
  - rectal involvement, [236](#)
  - route of spread, [236](#)
  - surgery, indications for, [238](#)
  - toxic megacolon, incidence of, [237](#)
- Cronkhite–Canada syndrome, [218](#)
- Cryoprecipitate (cryo), [79](#)
- Cryptorchidism, [378](#), [535](#)
- Cullen's sign, [5](#), [5f](#), [271](#)

- Curling's ulcer, [128](#), [128f](#), [170](#), [171](#)
- Cushing's syndrome, [9](#), [295–296](#), [295f](#)
- Cushing's triad, [5](#)
- Cushing's ulcer, [128](#)
- Cut-off sign, [122](#)
- Cyproheptadine, [206](#)
- Cystic hygroma, [371](#)
- Cystosarcoma phyllodes, [291](#)

## D

- Dakin solution, [54](#)
- Damage control surgery, [161](#)
- Dantrolene, [127](#)
- Dapsone, [164](#), [164f](#)
- DDAVP (desmopressin), [80](#)
- Dead space, [343](#)
- Death, ages [1](#) to [44](#), cause of, [11](#)
- Deaver retractor, [18f](#)
- DeBakey pickup, [13](#), [13f](#)
- Decubitus ulcer, [128](#)
- Deep venous thrombosis (DVT), [90–92](#)
- Delayed primary closure (DPC), [54](#)
- Desmoid tumor, [217](#)
- Diabetes insipidus (DI), [96](#)
- Diabetic ketoacidosis (DKA), [94](#)
- Diagnostic peritoneal lavage (DPL), [158](#)
- Diaphragm, [65](#)
- Diaphysis, [491](#)
- DIC, [99](#)
- Dieulafoy's ulcer, [128](#)
- Diphenhydramine hydrochloride IV (Benadryl), [87](#)
- Direct inguinal hernia, [139](#)

- Dirty wound, [113](#)
- Disability, assessment of, [154–155](#)
- Diseases of vessels, [470](#)
  - thoracic aortic aneurysm, [470](#)
  - aortic dissection, [470](#)
- Dislocation, [491](#)
- Dislocations
  - elbow, [500](#)
  - hip, [500](#)
  - knee, [501](#)
  - shoulder, [500](#)
- Diverticular abscess, [220](#)
- Diverticular disease, of colon, [218–223](#)
- Diverticulitis, [208](#), [219–220](#)
- Diverticulosis, [218–219](#), [218f](#)
- Dobbhoff tube, NGT vs., [62](#)
- Dobutamine, [341](#)
- Dopamine, [341](#)
- Double-barrel colostomy, [191](#)
- Drains
  - Jackson–Pratt, [55](#), [55f](#)
  - Penrose, [56](#), [56f](#)
  - purpose of, [55](#)
  - of pus, [50](#)
- Ductal carcinoma in situ (DCIS), [287–288](#), [287f](#)
- Ducts of Luschka, [252](#)
- Duhamel procedures, [385](#)
- Dumping syndrome, [9](#), [93–94](#)
- Duodenal atresia, [382](#)
- Duodenal mucosal cells, [253](#)
- Duodenal ulcer, [10](#)
  - gastroduodenal artery and, [10](#)

- Duodenal ulcers, [64](#), [174–175](#)
- Duodenum, [105](#), [106](#)
- Dupuytren's contracture, [412](#)
- D5W, [69](#)

## E

- Ear, tumors of, [415](#)
- Epididymitis, [537–538](#)
- Electrolyte loss, daily, [68](#)
- Electrolyte-mediated ileus, [78](#)
- Elemental tube feed, [106](#)
- Emergency abdominal surgery, [10](#)
- Emergent endoscopic sclerotherapy, [249](#)
- Empiric infection, [111](#)
- End colostomy, [191](#)
- Endocrine system, [294–309](#)
  - Addison's disease, [301](#)
  - adrenal gland, [294–301](#)
    - anatomy, [294](#)
    - Conn's syndrome, [300–301](#), [300f](#)
    - Cushing's syndrome, [295–296](#), [295f](#)
    - incidentaloma, [296–297](#)
    - pheochromocytoma, [297–300](#), [297f](#), [298f](#)
    - physiology of, [294–295](#)
  - glucagonoma, [303](#)
  - insulinoma, [302](#)
  - multiple endocrine neoplasia, [306](#)
    - type I, [306–307](#), [307f](#)
    - type IIA, [307–308](#)
    - type IIB, [308–309](#)
  - somatostatinoma, [303](#)
  - Zollinger–Ellison syndrome, [303–306](#), [305f](#)

- Endoscopic band ligation, [249](#)
- Enterocutaneous fistula, [207](#)
- Enterolysis, [48](#)
- Enuresis, [540](#)
- Epidermal/sebaceous cyst, removal of, [38](#), [38f](#)
- Epidural analgesia, [126](#)
- Epidural anesthesia, [124](#)
- Epidural hematoma, [516](#)
  - cause of, [11](#)
- Epigastric hernia, [139](#)
- Epigastric pain, [134](#)
- Epiglottitis, [428](#)
- Epinephrine (EPI), [342](#)
- Epistaxis, [421](#)
- Erectile dysfunction, [538](#)
- *Escherichia coli*, [11](#)
- Esophageal atresia without tracheoesophageal (TE) fistula, [373](#)
- Esophageal atresia with tracheoesophageal (TE) fistula, [374](#)
- Esophageal hiatal hernias, [145–146](#)
  - paraesophageal, [146](#), [146f](#)
  - sliding, [145](#), [145f](#)
- Esophageal variceal bleeding, [180–181](#)
- Esophageal varices, [248](#), [249](#)
- Esophagus, [65](#)
- Eversion, [489](#)
- Ewing's sarcoma, [506](#)
- Excisional biopsy, [54](#), [331](#)
- External pancreatic fistulas, [208–209](#), [208f](#)
- Extremity fractures, [162](#), [162f](#)

## F

- Facial fractures, [432](#)

- Facial nerve paralysis, [419](#)
- Factor V Leiden, [82](#)
- Familial adenomatous polyposis (FAP), [216](#)
- Familial hypocalciuric hypercalcemia, [323](#)
- Familial polyposis, [216](#)
- FAST exam, [156](#), [157](#)
- Fat soluble, [106](#)
- Fatty acid deficiency, [106](#)
- Felon, [117](#)
- Femoral hernia, [139](#), [144–145](#)
- Femoral vein, drawing blood from, [31](#), [31f](#)
- Femoral vessels, order of, [64](#)
- Fem pop bypass, [50](#), [51f](#)
- Fever
  - in burn patients, [170](#)
  - cause of, [11](#), [103](#), [118](#)
  - postoperative, [118](#)
  - workup, [118](#)
- Fibroadenoma, [291–292](#)
- Fibrocystic disease, [292](#)
- Figure-of-eight suture, [84](#), [84f](#)
- First-degree burns. *See* [Superficial burns](#)
- First-degree hemorrhoid, [230](#), [230f](#)
- Fistula in ano, [226–228](#), [226f](#), [227f](#)
- Fistulas, [207–209](#)
  - colonic, [208](#), [208f](#)
  - with diverticulitis, [219](#)
  - enterocutaneous, [207](#)
  - external pancreatic, [208–209](#), [208f](#)
- Fitz–Hugh–Curtis syndrome, [9](#), [117](#)
- Fixation, [489](#)
- Flagyl, [87](#)

- Flail chest, [151–152](#), [151f](#)
- Fluconazole (Diflucan), [85](#)
- Fludrocortisone, [95](#)
- Fluid accumulation, [68](#)
- Fluids and electrolytes, [67–68](#)
  - imbalances, [71–78](#)
  - IV replacement fluids, [69–70](#)
  - maintenance fluids, calculation of, [70](#)
  - third spacing, [68–69](#)
- Fluids maintenance, calculation of, [70](#)
- Fluid status, assessment of, [69](#)
- Flumazenil (Romazicon), [88](#), [127](#)
- Fluorescein, [168](#)
- Focal nodular hyperplasia (FNH), [242–243](#), [242f](#)
- Fogarty balloon catheter, [355](#)
- Fog reduction elimination device (FRED), [147](#)
- Foley catheter, [62](#), [62f](#), [63](#), [63f](#)
  - placement of, [33](#), [33f](#)
- Follicular adenocarcinoma, [315–316](#)
- Foot dorsiflexion, [489](#)
- Forceps, [13](#), [13f](#)
- Fournier’s gangrene, [116](#), [542](#)
- Fourth-degree hemorrhoid, [231](#)
- Fox’s sign, [271](#)
- Fractional excretion of Na<sup>+</sup> (FENa), [98](#)
- Frank-Starling curve, [343](#)
- Free air, [122](#), [123](#), [123f](#)
- Free peritoneal air, cause of, [11](#)
- Fresh frozen plasma (FFP), [79](#), [80](#)
- Frey procedure, [270](#)
- Full-thickness burns, [167](#), [168](#)
- Furuncle, [117](#)

## G

- Galeazzi fracture, 496
- Gallbladder
  - calcified, 265
  - carcinoma of, 263
  - Courvoisier's, 265
  - hydrops of, 265
- Gallstone ileus, 262–263, 262f
- Gallstone pancreatitis, 271
- Gallstones, 11
- Gamekeeper's thumb, 412
- Gardner's syndrome, 9, 216–217, 217f
- Gas bloat syndrome, 184
- Gastric, daily secretion, 69
- Gastric bypass, 189, 189f, 190
- Gastric cancer, 185–187, 186f
- Gastric dilatation, 92
- Gastric parietal cells, 182
- Gastric ulcers, 127, 175–176
- Gastric volvulus, 188
- Gastrin, 130–131
- Gastrinoma triangle, 64. See [Passaro's triangle](#)
- Gastroduodenal artery, 64
- Gastroesophageal reflux disease, 380
- Gastroesophageal reflux disease (GERD), 182–184, 184f
- Gastrografen enema, 221
- Gastrointestinal anastomosis (GIA) device, 25, 25f
- Gastrointestinal stromal tumor (GIST), 187
- Gastrointestinal system
  - hormones, 130–131
    - cholecystokinin (CCK), 130
    - gastrin, 130–131

- miscellaneous, [131](#)
  - secretin, [130](#)
  - somatostatin, [131](#)
- physiology of, [130–131](#)
- Gastroschisis, [389–390](#)
- Gastrostomy, [191](#)
- G cells, [182](#)
- General anesthesia, [124](#), [125](#)
- General endotracheal anesthesia (GETA), [125](#)
- Gentamicin, [84](#), [85](#)
- GI bleeding
  - in adults, [220](#)
  - with diverticulitis, [220](#)
  - lower, [232–234](#), [233f](#)
  - upper, [172–182](#)
    - Boerhaave's syndrome, [181](#)
    - differential diagnosis of, [172](#)
    - duodenal ulcers, [174–175](#)
    - esophageal variceal bleeding, [180–181](#)
    - gastric ulcers, [175–176](#)
    - Mallory–Weiss syndrome, [179–180](#)
    - peptic ulcer disease, [173](#)
    - perforated peptic ulcer, [176–177](#)
    - stress gastritis, [179](#)
    - and surgeries, [177–179](#), [177f–179f](#)
- Gilbert's syndrome, [265](#), [395](#)
- GI Lymphoma, [332](#)
- Glasgow Coma Scale (GCS), [154](#)
- Gleason score, [533](#)
- Glomus tumors, [421](#)
- Glottic lesions, [430](#)
- Glucagonoma, [303](#)

- Glucose level, in ICU, [76](#)
- Glutamine, [106](#)
- Goodsall's rule, [6](#), [6f](#), [226–227](#), [226f](#), [227f](#)
- Graham patch, [49](#), [176](#), [177](#), [177f](#)
- Gram-negative aerobic, [85](#)
- Gram-negative anaerobes, [85](#)
- Gram-negative bacteria, [11](#)
- Gram-negative infections, antibiotics for, [84](#)
- Grey Turner's sign, [271](#)
- Groin hernias, [140–145](#)
  - femoral hernia, [144–145](#)
  - inguinal hernia
    - direct, [140](#)
    - indirect, [140–141](#), [140f](#)
    - intraoperative, [142–144](#), [143f–144f](#)
    - repair of, [141](#)
- G-tube, [56](#)

## H

- Halo sign, [156](#)
- Hamartomatous polyps, [215](#)
- Hamman's sign, [6](#), [181](#)
- Hangman's fracture, [496](#), [520](#)
- Hartmann's pouch, [52](#), [191](#)
- Hartmann's procedure, [46](#), [220](#)
- Hasson technique, [147](#)
- Heart transplant, [485–486](#)
- Heimlich valve, [60](#), [60f](#)
- Heineke–Mikulicz pyloroplasty, [49](#), [49f](#)
- Hemangioma, [11](#)
- Hematochezia, [172](#), [232](#)
- Hemicolectomy, [53](#), [53f](#)

- Hemobilia, [246](#)
- Hemodynamic monitoring, [344–345](#)
- Hemophilia A, clotting factor for, [81](#)
- Hemophilia B, [81](#)
- Hemorrhagic pancreatitis, [271–272](#)
- Hemorrhoidectomy, [231](#)
- Hemorrhoids, [229–231](#), [230f–231f](#), [248](#)
- Heparin, [86](#)
- Heparin-induced thrombocytopenic thrombosis (HITT) syndrome, [9](#)
- Hepatic encephalopathy, [251](#)
- Heparin rebound, [459](#)
- Hepatic hemangioma, [243](#)
- Hepaticojejunostomy, [47](#), [47f](#), [254](#)
- Hepatoblastoma, [401](#)
- Hepatocellular adenoma, [242](#)
- Hepatocellular carcinoma, [243–244](#)
- Hepatoma. See [Hepatocellular carcinoma](#)
- Hereditary nonpolyposis colon cancer (HNPCC), [212](#)
- Hernias, [10](#), [136–146](#)
  - esophageal hiatal, [145–146](#)
  - groin, [140–145](#)
  - incidence of, [136](#)
  - Petersen’s hernia, [190](#)
  - precipitating factors, [136](#)
  - reducing of, [137](#), [137f](#)
  - types of, [137–140](#)
- Hesselbach’s triangle, [64](#), [377](#)
  - boundaries of, [139](#)
- Hesselbach’s triangle, [377](#), [377](#)
- Heterotopic pancreatic tissue, [276](#)
- Hgb, [81](#)
  - to Hct, formula for conversion, [79](#)

- Hiatal hernia, [139](#)
- Hickman catheter, [63](#)
- Hidradenitis suppurativa, [115](#)
- High frequency ventilation, [346](#)
- High imperforate anus, [383](#)
- High ligation procedure, [141](#)
- Hirschsprung's disease, [384](#)
- Histrionic adult's abdomen, [133](#)
- Hollenhorst plaque, [361](#)
- Homan's sign, [90](#)
- Howship–Romberg sign, [6](#)
- Human chorionic gonadotropin (HCG), [325](#)
- Hungry bone syndrome, [325](#)
- Hürthle cell thyroid cancer, [316](#)
- Hutchinson's freckle, [336](#)
- Hydatid liver cyst, [245–246](#)
- Hydrocele, [378](#), [529](#)
- Hydrocephalus, [525](#)
- 5-Hydroxyindoleacetic acid (5-HIAA), [205](#)
- Hypercalcemia, [74–75](#), [74f](#)
- Hyperglycemia, [76](#)
- Hyperkalemia, [71](#), [71f](#), [77](#), [77f](#), [78](#), [78f](#), [125](#)
- Hypermagnesemia, [76](#)
- Hypernatremia, [72–73](#)
- Hyperparathyroidism (HPTH), [322–325](#)
- Hyperphosphatemia, [77](#)
- Hyperplastic polyps, [215](#)
- Hypersplenism, [329](#)
- Hypertension (HTN)
  - surgically correctable, [330](#)
- Hypertension, postoperative, [101](#)
- Hypocalcemia, [75](#)

- Hypochloremic alkalosis, surgical causes of, 68
- Hypochloremic metabolic alkalosis, 68
- Hypoglycemia, 77
- Hypokalemia, 11, 71–72, 72f
- Hypokalemic, 68
- Hypokalemic metabolic alkalosis, 68
- Hypomagnesemia, 76
- Hyponatremia, 73–74, 74f
- Hypophosphatemia, 77
- Hypotension, 101
- Hypovolemia
  - physiologic response to, 68
  - vital signs, changes in, 69
- Hypovolemic shock, 107–108
- Hypoxia, 101
- Hytrin®, 534

## I

- Idiopathic thrombocytopenic purpura (ITP), 329
- Ileum, 65
- Ileus
  - electrolyte deficiency and, 11
- Imipenem, 84
- Incentive spirometry, 103, 103f
- Incidentaloma, 296–297
- Incisional biopsy, 54, 331
- Incisional hernia, 138
- Incision(s), 38–41
  - carotid endarterectomy, 41, 41f
  - inguinal hernia repair, 41, 41f
  - Kocher, 39, 39f
  - laparoscopic cholecystectomy, 41, 41f

- McBurney's, [39](#), [39f](#)
- median sternotomy, [40](#), [40f](#)
- midline laparotomy, [39](#), [39f](#)
- pfannenstiel, [40](#), [40f](#)
- of pus, [50](#)
- relaxing, [143](#)
- thoracotomy, [40](#), [40f](#)
- Indirect inguinal hernia, [140–141](#), [140f](#)
- Infections, [110–117](#)
  - burns wound, [170](#)
  - central line, [112](#)
  - clostridial myositis, [115](#)
  - hidradenitis suppurativa, [115](#)
  - miscellaneous, [116–117](#)
  - necrotizing fasciitis, [114–115](#)
  - parotitis, [116](#)
  - prophylactic antibiotics, [116](#)
  - pseudomembranous colitis, [115](#)
  - urinary tract, [111](#)
  - wound, [112–114](#)
- Infectious endocarditis, [464](#)
- Infiltrating ductal, [10](#)
- Inflammatory bowel disease, [235–239](#). *See also* [Crohn's disease](#); [Ulcerative colitis \(UC\)](#)
- Inflammatory carcinoma, [285](#)
- Inflammatory polyps, [215](#)
- Inguinal anatomy, [144](#), [144f](#)
- Inguinal hernia
  - Hesselbach's triangle, [377](#)
  - silk glove sign, [378](#)
- Inherited hypercoagulable state, [82](#)
- Inspection, abdomen, [132](#)

- Insulinoma, [277](#), [302](#)
- Intensive care physiology, [342–344](#)
- Intensive care unit formulas, [338–340](#)
- Intercostobrachial nerve, [279](#)
- Intermittent Mandatory Ventilation, [345](#)
- Internal hernia, [137](#)
- International Normalized Ratio (INR), [79](#), [87](#)
- Intestinal transplantation, [486](#)
- Intra-abdominal injury, [156](#)
  - in children, [163](#)
- Intraductal carcinoma. *See* [Ductal carcinoma in situ \(DCIS\)](#)
- Intravenous (IV) replacement fluids, [69–70](#)
- Intussusception, [390–391](#)
- Inversion, [489](#)
- Involuntary guarding, [132](#)
- Ionized calcium, [79](#)
- Iris scissors, [14](#), [14f](#)
- Isoproterenol, [342](#)
- Isotonic fluids, [70](#)
- IVC filter, [91](#), [91f](#)
- IV Cipro, [88](#)

## J

- Jackson–Pratt drain, [55](#), [55f](#)
- Jefferson’s fracture, [519](#)
- Jejunostomy, [191](#)
- Jejunum, [65](#), [106](#)
- Jersey finger, [412](#)
- Jones’ fracture, [495](#)
- J-tube, [56](#)
- Juvenile nasopharyngeal angiofibroma, [423](#)
- Juvenile polyps, [218](#)

## K

- Kanavel's signs, [410](#)
- Kasabach–Merritt syndrome, [243](#)
- Kehr's sign, [327](#)
- Kelly clamp, [15](#), [15f](#)
- Kidney
  - stone in, [133](#)
  - transplant, [480](#)
- Kjellberg, [515](#)
- Klatskin's tumor, [254](#)
- Klatskin tumor, [264](#), [264f](#)
- Knot tying
  - instrument tie, [28f](#)
  - knots and ears, [26–28](#)
  - two-hand tie, [29–30](#), [29f–30f](#)
- Kocher clamp, [17](#), [17f](#)
- Kocher maneuver, [47](#), [47f](#), [266](#)
- Kocher's point, [515](#)
- Kulchitsky cells, [203](#)
- Kussmaul's sign, [152](#)

## L

- Lactated Ringer's (LR), [69](#)
- Lactational mastitis, [293](#)
- Ladd's bands, [387](#), [387f](#)
- Lambert stitch, [25](#), [25f](#)
- Langer's lines, [403](#)
- Language, surgical, [43](#)
- Lap appy, [48](#), [201](#)
- Laparoscopic cholecystectomy, [256](#), [256f](#)
  - complications of, [258](#)
- Laparoscopy, [146–147](#)

- complications of, [147](#)
- contraindications to, [147](#)
- driving camera during, [147](#)
- Hasson technique, [147](#)
- and laparotomy, [147](#)
- Veress needle, [147](#)
- Laparotomy, [50](#)
- Lap-band, [190](#), [190f](#)
- Lap chole, [48](#)
- Lap Nissen, [49](#)
  - for GERD, [184](#), [184f](#)
- Large bowel obstruction
  - cause of, [11](#)
- Laryngeal fracture, [160](#)
- Laryngotracheobronchitis, [427](#)
- Lateral pectoral nerve, [278](#), [279f](#)
- LE arterial insufficiency ulcer, [128](#)
- Left hepatic lobectomy, [242](#)
- Left lateral decubitus, [42](#), [42f](#)
- Left testicular vein, drainage of, [64](#)
- Legg–Calvé–Perthes disease, [511](#)
- Lentigo maligna melanoma, [335](#)
- Leriche's syndrome, [9](#)
- Lethal triad, [161](#)
- Lichtenstein procedure, [141](#)
- Lidocaine, [126](#)
- Linitis plastica, [185](#)
- Lithotomy, [42](#), [42f](#)
- Little League elbow, [511](#)
- Littre's hernia, [137](#)
- Liver, [11](#)
  - abscesses of, [244–246](#)

- amebic, [245](#)
- bacterial, [244–245](#)
- hydatid liver cyst, [245–246](#)
- anatomy of, [239–241](#), [239f–240f](#)
- benign tumor of, [11](#)
- blood supply to, [131](#)
- hemobilia, [246](#)
- lobes of, [64](#)
- malignancy of, [11](#)
- transplant, [482–484](#)
- tumors of, [241–244](#)
  - focal nodular hyperplasia, [242–243](#), [242f](#)
  - hepatic hemangioma, [243](#)
  - hepatocellular adenoma, [242](#)
  - hepatocellular carcinoma, [243–244](#)
- Lobular carcinoma in situ (LCIS), [289](#) [289f](#)
- Local anesthesia, [124](#), [125](#)
- Long thoracic nerve, [278](#), [279f](#)
- Loop colostomy, [192](#), [192f](#)
- Low anterior resection (LAR), [46](#), [214](#)
- Lower GI bleeding, [232–234](#), [233f](#)
  - cause of, [11](#)
- Low imperforate anus, [383](#)
- Low-molecular-weight heparin (LMWH), [86](#), [119](#)
- Lumpectomy, [285](#)
  - radiation and, [50](#)
- Lungs
  - cancer, [11](#)
  - transplantation, [487](#)
- Lynch's syndrome, [212](#)
- Lysis of adhesions (LOA), [48](#)

## M

- Mackler's triad, [181](#)
- Mafenide acetate (Sulfamylon), [170](#)
- Maintenance fluids, [70](#)
- Male breast cancer, [290](#)
- Male gynecomastia, [293](#)
- Malignant hyperthermia (MH), [126–127](#)
- Malignant thyroid nodules, [313–314](#)
- Malignant lesions of larynx, [429](#)
- Malignant otitis externa (MOE), [415](#)
- Malleable retractor, [20](#), [20f](#)
- Mallory–Weiss syndrome, [9](#), [179–180](#)
- Malrotation and midgut volvulus, [386](#)
- MALToma, [187–188](#)
- Mammotome biopsy, [283](#)
- Mandibular fractures, [155](#)
- Marginal ulcer, [128](#)
- Margin cancer, [225](#)
- Marjolin's ulcer, [128](#), [333](#)
- Marshall test, [540](#)
- Massive hemothorax, [152](#)
- Mastectomy, [49](#)
- Mastitis, [292](#)
- Mayo scissors, [16](#), [16f](#)
- Mayo tray, [2](#), [2f](#), [3](#)
- McBurney incision, [202](#)
- McBurney's point, [6](#), [65](#), [200](#), [200f](#)
- McMurray's sign, [502](#)
- McVay procedure, [141](#)
- Mechanical ventilation, [345–347](#)
- Meckel's Diverticulum, [392](#)
- Meckel's diverticulum, [196–197](#), [196f](#), [392–393](#)

- rule of 2s, 6, 197
- Meckel's scan, 197, 393
- Meconium ileus, 382
- Meconium peritonitis, 383
- Meconium plug syndrome, 383
- Medial pectoral nerve, 278, 279f
- Median arcuate ligament syndrome, 358–359
- Mediolateral oblique (MLO) mammogram, 124, 124f
- Medullary carcinoma, 316–317
- Medulloblastoma, 522
- Melanoma, 334–337
  - superficial spreading, 10
  - type of, 10, 335
- Mendelson's syndrome, 9
- Ménière's disease, 420
- Meningiomas, 521
- Mesenteric adenitis, 202
- Mesoappendix, 198
- Metabolic acidosis, surgical causes of, 68
- Metabolic alkalosis, surgical causes of, 68
- Metachronous tumors, 129
- Metallic skin staples, 58f
- Metaphysis, 491
- Metastasis, 11
- Metastatic disease, 241
- Methicillin-resistant *Staphylococcus aureus* (MRSA), 85
- Metronidazole (Flagyl), 84, 85
- Metzenbaum scissors, 16, 16f
- Minute ventilation, 345
- Mirizzi's syndrome, 9, 265
- Miscellaneous skin lesions, 333–334
- Mitral Regurgitation (MR), 463

- Mitral Stenosis (MS), [462](#)
- Mixed incontinence, [540](#)
- Model for end-stage liver disease (MELD) score, [241](#)
- Modified neck dissection, [431](#)
- Modified radical mastectomy, [286](#)
- Mohs surgery, [334](#)
- Monteggia fracture, [496](#)
- Morbid obesity, [188](#)
- Morrison's pouch, [64](#)
- Motion pain, [132](#)
- Mucosal-associated lymphoproliferative tissue (MALT), [187–188](#)
- Mucous fistula, [47](#), [191](#)
- Mucous neck cells, [182](#)
- Multiple endocrine neoplasia (MEN), [306](#)
  - type I, [306–307](#), [307f](#)
  - type IIA, [307–308](#)
  - type IIB, [308–309](#)
- Munchausen's syndrome, [9](#)
- Murphy's sign, [6](#), [259](#)
- Myocardial infarction (MI), [96–97](#)
- Myoglobinuria, [166](#)

## N

- Naloxone (Narcan), [88](#), [126](#), [127](#)
- Narcotics, [88](#)
  - respiratory depression with, [126](#)
- Nasogastric tubes (NGT)
  - aspirate, [78](#)
  - clogged, [62](#)
  - excessive drainage, [62](#)
  - and feeding tube, [61](#), [62](#)
  - hypokalemia with, [68](#)

- placement of, [61](#)
- procedures, [34–38](#), [34f–38f](#)
- removal of, [61](#)
- suctioning, [68](#)
- unclogging, [62](#)
- working of, [61](#), [61f](#)
- Neck injuries, penetrating, [158–159](#), [158f–159f](#)
- Neck mass, [430](#)
- Necrotizing enterocolitis, [393](#)
- Necrotizing fasciitis, [114–115](#)
- Needle driver, [15](#), [15f](#)
- Needle localization biopsy (NLB), [283](#)
- Negative-pressure wound therapy (NPWT), [55](#)
- Nelson’s syndrome, [296](#)
- Neoplastic polyps, [215](#)
- Nephrotoxicity, [85](#)
- Neural tube defects, [526](#)
- Neuroblastoma, [398](#)
- Neurogenic shock, [109–110](#)
- Neurosurgery, [513–526](#)
  - cerebral contusion, [518](#)
  - epidural hematoma, [516](#)
  - GCS scoring system, [514](#)
  - pediatric, [525–526](#)
  - skull fracture, [518](#)
  - spine, [524](#)
  - subdural hematoma, [517](#)
  - traumatic subarachnoid hemorrhage, [518](#)
  - vascular, [523–524](#)
- NIGRO protocol, [225–226](#)
- Nissen, [48](#), [48f](#)
- Nitrous oxide, [126](#)

- Nodular melanoma, [335](#)
- Nonabsorbable sutures, [20](#)
- Noncommunicating hydrocele, [378](#), [529](#)
- Nondepolarizing neuromuscular blocking agents, [127](#)
- Nonperforated acute appendicitis, [201](#)
- Nonrebreather mask, [104](#), [104f](#)
- Non-union, [491](#)
- Norepinephrine (NE), [342](#)
- Normal saline (NS), [69](#)
- Nose and paranasal sinuses
  - acute sinusitis, [421](#)
  - chronic sinusitis, [422](#)
  - epistaxis, [421](#)
- Nosocomial infection, [111](#)
- Nursemaid's elbow, [511](#)
- Nutrition
  - surgical, [105–107](#)
- Nystatin, [85](#)

## O

- Obstructive jaundice, [256–257](#)
  - itching in, [253](#)
  - signs and symptoms of, [253](#)
- Obturator hernia, [138](#)
- Obturator sign, [6](#), [6f](#), [199](#)
- Octreotide, [206](#)
- Odontoid fracture, [520](#)
- Odontoid fractures, [520](#)
- Ogilvie's syndrome, [9](#)
- Omphalocele, [388–389](#)
- Oncology, surgical, [129](#)
- O negative blood, [79](#)

- Open reduction, [489](#)
- Operating room FAQs, [1–3](#), [2f](#), [3f](#)
- Oral cavity and pharynx, [424](#)
  - cancer of oral cavity, [425](#)
  - ludwig angina, [425](#)
  - peritonsillar abscess, [425](#)
  - pharyngotonsillitis, [424](#)
  - salivary gland tumors, [426](#)
- Ortho bowel routine (OBR), [93](#)
- Orthopedic surgery
  - achilles tendon rupture, [502](#)
  - arthritis, [507](#)
  - dislocations, [497](#)
  - fractures, [492](#)
  - infections, [504](#)
  - knee, [501](#)
  - pediatric, [508](#)
  - rotator cuff, [503](#)
  - trauma, [491](#), [497](#)
  - tumors, [505](#)
- Orthopaedic tumors
  - ewing's sarcoma, [506](#)
  - osteosarcoma, [506](#)
- Orthostatic hypotension, [126](#)
- Ortolani's sign, [510](#)
- Osgood–Schlatter's disease, [512](#)
- Osteosarcoma, [506](#)
- Osteotomy, [491](#)
- Otitis externa, [414](#)
- Ostomies, [191–193](#)
- Otolaryngology
  - acute suppurative otitis media, [417](#)

- bullous myringitis, [417](#)
- cholesteatoma, [416](#)
- malignant otitis externa, [415](#)
- otitis externa, [414](#)
- tympanic membrane (TM) perforation, [415](#)
- Otosclerosis, [418](#)
- Overflow incontinence, [540](#)
- Overwhelming post splenectomy sepsis (OPSS), [328](#)
- Oxygenation, [345](#)
- Oxygen-induced hypoventilation, [103](#)
- Oxygen nasal cannula, [104](#)

## P

- P53, for gastric cancer, [186](#)
- Packed red blood cells (PRBCs), [79](#)
  - with Lactated Ringer's, [80](#)
  - storage, [80](#)
  - “universal” donor for, [79](#)
- Paget's disease, [225](#)
- Palpation, abdomen, [132](#)
- Pancreas, [266–278](#)
  - anatomy of, [266](#), [266f](#)
  - annular, [276](#)
  - divisum, [276](#)
  - endocrine function of, [266](#)
  - exocrine function of, [266](#)
  - glucagonoma tumors, [277](#)
  - heterotopic pancreatic tissue, [276](#)
  - insulinoma, [277](#)
  - islet cell tumor, [277](#)
  - maneuver for, [266](#)
  - pancreatic abscess, [272](#)

- pancreatic carcinoma, [274–276](#), [274f](#)
- pancreatic necrosis, [272](#)
- pancreatic pseudocyst, [273–274](#), [273f](#)
- pancreatitis, [267–272](#)
- transplant, [484](#)
- Pancreatic, daily secretion, [69](#)
- Pancreatic abscess, [272](#)
- Pancreatic carcinoma, [274–276](#), [274f](#)
- Pancreatic divisum, [276](#)
- Pancreatic glucagonoma tumors, [277](#)
- Pancreatic necrosis, [272](#)
- Pancreatic pseudocyst, [273–274](#), [273f](#)
- Pancreatitis, [267–272](#)
  - acute, [11](#), [267–269](#)
  - chronic, [11](#), [269–271](#)
  - gallstone, [271](#)
  - hemorrhagic, [271–272](#)
  - postoperative, [92–93](#)
- Pantaloon hernia, [138](#), [138f](#)
- Papillary adenocarcinoma, [314–315](#)
- Paradoxical alkalotic aciduria, [69](#)
- Paraesophageal hiatal hernias, [146](#), [146f](#)
- Paraneoplastic syndrome, [129](#)
- Parastomal hernia, [138](#)
- Parathyroid, [321–326](#)
  - anatomy of, [321–322](#)
  - carcinoma, [325–326](#)
  - hyperparathyroidism, [322–325](#)
  - physiology of, [322](#)
- Parathyroidectomy, postoperative complications of, [325–326](#)
- Parathyroid hormone (PTH), [322](#)
- Parathyromatosis, [326](#)

- Parkland formula, [169](#)
- Parotitis, [116](#)
- Partial SBO, [194](#), [195](#)
- Partial-thickness burns, [166–167](#), [168](#)
- Partial thromboplastin time (PTT), [79](#)
- Passaro’s triangle, [305](#), [305f](#)
- PDS sutures, [21](#)
- Pectus carinatum, [373](#)
- Pectus deformity, [372](#)
- Pectus excavatum, [372](#)
- Pediatric surgery
  - anorectal malformations, [383](#)
  - chest, [372](#)
  - congenital pyloric stenosis, [380](#)
  - duodenal atresia, [382](#)
  - ECMO, [369](#)
  - fetal circulation, [368](#)
  - inguinal hernia, [377](#)
  - meconium ileus, [382](#)
  - meconium peritonitis, [383](#)
  - meconium plug syndrome, [383](#)
  - neck, [369](#), [369f](#)
  - pediatric blood volumes, [368](#)
  - pediatric IV fluids and nutrition, [367](#)
  - pulmonary sequestration, [376](#)
  - thyroglossal duct cyst, [369](#)
  - tumors, [397](#)
  - umbilical hernia, [380](#)
- Pediatric trauma, [401](#)
- Pelvic fractures, [156](#), [160](#)
- Penicillins, [85](#)
- Penrose drain, [56](#), [56f](#)

- Peptic ulcer disease (PUD), [127](#), [173](#)
- Percussion, abdomen, [132](#)
- Percutaneous endoscopic gastrostomy (PEG), [52](#), [52f](#)
- Perforated acute appendicitis, [201](#)
- Perforated peptic ulcer, [176–177](#)
- Perianal warts, [229](#)
- Peripheral intravenous (IV) catheter, placement of, [31](#), [31f](#)
- Peritoneal abscess, [114](#)
- Peritoneal signs, [132](#)
- Petersen's hernia, [138](#), [138f](#), [190](#)
- Peutz–Jeghers syndrome, [9](#), [217–218](#)
- Peyronie's disease, [542](#)
- Pharyngotonsillitis, [424](#)
- Pheochromocytoma, [297–300](#), [297f](#), [298f](#)
- Pheochromocytoma SYMPTOMS triad, [7](#), [7f](#)
- Physis, [491](#)
- Pickups. *See* [Forceps](#)
- Pilon fracture, [497](#), [497f](#)
- Pituitary tumors, [522](#)
- Plantarflexion, [489](#)
- Plasmapheresis, [329](#)
- Platelets, [79](#), [80](#)
  - count, [80](#)
  - life of, [81](#)
- Plavix, [80](#)
- Pleuravac box, [58–59](#)
  - collection chamber, [58](#), [58f](#)
  - suction-control chamber, [59](#), [59f](#)
  - water-seal chamber, [59](#), [59f](#)
- Plicae circulares, [65](#)
- Plug and patch procedure, [141](#)
- Plummer's disease. *See* [Toxic multinodular goiter](#)

- Pneumatosis intestinalis, [122](#)
- Pneumonia
  - in ICU, [11](#)
- Pneumoperitoneum, cardiovascular effects of, [147](#)
- Pneumothorax, [103](#), [150–151](#), [151f](#)
- Polyposis syndromes, [216–218](#)
  - diverticular disease of colon, [218–223](#)
  - familial polyposis, [216](#)
  - Gardner's syndrome, [216–217](#), [217f](#)
  - Peutz–Jeghers syndrome, [217–218](#)
- Polysporin, [171](#)
- Popliteal artery aneurysm, [364](#)
- Pop-off suture, [26](#), [26f](#)
- Porcelain gallbladder, [263](#), [265](#)
- Port-A-Cath, [63](#)
- Portal hypertension, [247–251](#)
  - causes, [247](#)
  - complication of, [249](#)
  - diagnostic test in, [249](#)
  - etiology of, [247](#), [248](#)
  - pathophysiology of, [247](#)
  - physical finding in patients with, [247](#), [248](#), [248f](#)
  - portal–systemic collateral blood flow, routes of, [247](#)
  - portal–systemic collateral circulation in, [248](#)
  - related anatomy, [247](#)
  - rule of 2/3 of, [249](#)
  - shunts for, [250–251](#), [250f](#)
  - TIPS procedure, [250](#), [250f](#)
- Positive end expiration pressure, [346](#)
- Posterior cord syndrome, [519](#)
- Postlaparoscopic shoulder pain, [147](#)
- Postoperative peritoneal adhesions, [10](#)

- Postvagotomy diarrhea, [93](#)
- Pott's disease, [497](#)
- Pott's fracture, [497](#)
- Prealbumin, [107](#)
- Preload, [342](#)
- Preoperative issues, [44](#)
- Priapism, [520](#)
- Primary survey, trauma, [148–155](#)
  - airway, [148–149](#), [149f](#)
  - breathing, [149–152](#)
  - circulation, [152–154](#)
  - disability, [154–155](#)
  - environment, [155](#)
  - exposure, [155](#)
- Primary wound closure, [54](#)
- Pringle maneuver, [50](#), [50f](#)
- Procedures
  - common, [31–34](#)
  - nasogastric tube, [34–38](#)
- Prolactin, [280](#)
- Pronation, [489](#)
- Prone position, [42](#)
- Prophylactic infection, [111](#)
- Propyl thio uracil (PTU), [319](#)
- Proscar<sup>®</sup>, [534](#)
- Prostate cancer, [11](#), [532–533](#)
- Protamine IV, [86](#)
- Prothrombin complex concentrate (PCC), [87](#)
- Prothrombin time (PT), [79](#)
- Pseudohyponatremia, [74](#)
- Pseudomembranous colitis, [100](#), [115](#)
- *Pseudomonas*, [85](#)

- Psoas sign, [7](#), [7f](#), [199](#)
- Puestow procedure, [48](#), [48f](#), [277](#)
- Pulmonary embolism, [90–92](#)
- Pulmonary sequestration, [376](#), [376f](#), [377](#)
- Pursestring sutures, [24](#), [24f](#)
- Pyloroplasty, vagotomy and, [177](#), [177f](#)
- Pylorus-preserving Whipple, [276](#)

## R

- Raccoon eyes, [7](#), [7f](#)
- Radial arterial blood gas (ABG), [37](#), [37f](#)
- Radical mastectomy, modified, [50](#)
- Radical Neck Dissection, [431](#)
- Radiology, [120–124](#)
  - abdomen, [121–124](#), [121f–124f](#)
  - chest, [120–121](#), [121f](#)
- Rally pack, [120](#)
- Ranson's criteria, acute pancreatitis, [268–269](#)
- Rapid-sequence anesthesia induction, [125](#)
- Rebound tenderness, [132](#)
- Rectal polyps, [215–216](#)
- Rectum
  - blood supply to, [211](#)
  - colorectal carcinoma of, [211–215](#)
  - polyposis syndromes of, [216–218](#)
  - polyps, [215–216](#)
  - venous drainage of, [211](#)
- Recurrent laryngeal nerves, [311](#)
- Red blood cells (RBCs)
  - life of, [81](#)
- Red-man syndrome, [85](#)
- RED reaction syndrome, [10](#)

- Reduction, [489](#)
- Refeeding syndrome, [10](#), [106](#)
- Referred pain, [134–135](#)
- Refractory pancreatic fistula, [209](#)
- Regional anesthesia, [124](#), [125](#)
- Relaxing incision, [143](#)
- Renal artery stenosis, [363](#)
- Renal cell carcinoma (RC ), [530–531](#)
- Renal failure, postoperative, [97–98](#)
- Rendu–Osler–Weber (ROW) syndrome, [10](#)
- Respiratory acidosis, surgical causes of, [68](#)
- Respiratory alkalosis, surgical causes of, [68](#)
- Respiratory care, [103–104](#), [103f–104f](#)
- Respiratory depression, with narcotics, [126](#)
- Respiratory failure, postoperative, [89–90](#)
- Respiratory quotient (RQ), [105](#)
- Respiratory tract infection, [111](#)
- Retention sutures, [26](#), [26f](#)
- Retractors
  - army–navy, [19f](#)
  - Deaver, [18f](#)
  - malleable, [20](#), [20f](#)
  - Richardson, [19f](#)
  - sweetheart, [19f](#)
  - toe in, [18](#)
- Retrograde urethrogram (RUG), [158](#)
- Retroperitoneal varices, [248](#)
- Reverse trendelenburg, [43](#)
- Reversible ischemic neurologic deficit, [359](#)
- Reynold’s pentad, [7](#), [261](#)
- Rhabdomyosarcoma, [400](#)
- Rib, blood vessels on, [64](#)

- Richardson retractor, 19f
- Richter's hernia, 139, 139f
- Riedel's thyroiditis, 320
- Right-angle clamp, 15, 15f
- Right hepatic lobectomy, 241
- Right lateral decubitus, 42
- Right testicular vein, drainage of, 64
- Right trisegmentectomy, 242
- Rotter's nodes, 280
- Roux-en-Y limb, 46, 46f
- Rovsing's sign, 7, 199
- 4/2/1 rule, for IV fluids maintenance, 70
- Rule of 2/3, of portal hypertension, 249
- Rule of nines, burns, 167, 167f
- Rule of palm, burns, 168
- Rule of 2s, 393
- Rule of 2s, Meckel's diverticulum, 197
- Rule of 10's, burns, 169
- Rule of two thirds, of esophageal variceal hemorrhage, 180
- Rule 33-to-1, HPTH, 323

## S

- Sacral sparing, 518
- Saddle embolus, 91, 91f
- Sarcoma
  - site of distant metastasis of, 11
- Scalpel blades, 18, 18f
- Scissors, 12, 12f
- Sclerosing cholangitis, 261–262
- Seatbelt sign, 156
- Sebaceous cyst, 333
- Seborrheic keratosis, 334

- Secondary survey, trauma, [155–157](#)
- Secondary wound closure, [54](#)
- Second-degree burns. *See* [Partial-thickness burns](#)
- Second-degree hemorrhoid, [230](#), [230f](#)
- Secretin, [130](#)
- Secretin-stimulation test, [304](#)
- Sedative medication, [107](#)
- Seizures
  - medications for, [88–89](#)
- Seldinger technique, [47](#)
- Selective exploration, [159](#)
- Selective neck dissection, [431](#)
- Sengstaken–Blakemore tube, [249](#)
- Sentinel loops, [122](#)
- Sentinel pile, [228](#)
- Sepsis, [111](#)
- Septic shock, [109](#), [111](#)
- Serotonin, [203](#)
- Seton, [227](#), [227f](#)
- Shock, [107–110](#)
  - anaphylactic, [110](#)
  - cardiogenic, [109](#)
  - hypovolemic, [107–108](#)
  - neurogenic, [109–110](#)
  - septic, [109](#)
  - signs of, [107](#)
- Short bowel syndrome, [93](#)
- Short-gut syndrome, [10](#)
- Shortness of breath, [101](#)
- Shunt fraction, [343](#)
- Sigmoid volvulus, [221–222](#), [221f](#)
- Silk glove sign, [378](#)

- Silver sulfadiazine (Silvadene), [170](#)
- Sitz bath, [228](#)
- Skin flora, surgical prophylaxis for, [85](#)
- Skin grafts, [405](#)
- Skin lesions
  - basal cell carcinoma, [333](#)
  - miscellaneous skin lesions, [333–334](#)
  - squamous cell carcinoma, [332–333](#)
- Skull fracture, [518](#)
- Sleeve gastrectomy, [189](#), [189f](#)
- Sliding hernia, [137](#), [137f](#)
- Sliding hiatal hernias, [145](#), [145f](#)
- Slipped capital femoral epiphysis, [511](#), [511f](#)
- Small bowel, [65](#)
  - anatomy, [193](#)
  - daily secretion, [69](#)
  - Meckel's diverticulum, [196–197](#), [196f](#)
  - nutritional source, [131](#)
  - obstruction, [121](#), [193–195](#), [194f](#)
  - submucosa of, [65](#)
  - tumors, [196](#)
  - vs. colon, [65](#), [211](#)
- Small bowel obstruction (SBO), [121](#), [193–195](#), [194f](#)
  - in adults, [10](#)
  - with carcinoid, [203](#)
  - in children, [10](#)
- Smith's fracture, [495](#)
- Smoking, [119](#)
- Sodium Nitroprusside (SNP), [342](#)
- Soft tissue sarcomas, [330–332](#)
  - and lymphoma, [332](#)
  - types, [330](#)

- Somatostatin, [131](#), [249](#)
- Somatostatinoma, [277](#), [303](#)
- Sphincterotomy, [256](#)
- Spider bite, [164](#), [164f](#)
- Spigelian hernia, [137](#)
- Spinal anesthesia, [124](#)
- Spinal cord trauma, [518](#)
- Spinal epidural abscess, [525](#)
- Spinal immobilization, [149](#)
- Spinal shock, [110](#), [518](#)
- Spine
  - cervical disc disease, [525](#)
  - lumbar disc herniation, [524](#)
  - spinal epidural abscess, [525](#)
- Spironolactone, [301](#)
- Spleen
  - delayed splenic rupture, [327](#)
  - functions of, [327](#)
  - ruptured/injured, [327](#)
  - and splenectomy, [326–330](#)
  - splenic artery, [326](#), [326f](#)
  - venous drainage of, [327](#)
- Splenectomy, [327–330](#)
  - complications for, [328](#)
  - indications for, [327–328](#)
- Splenic artery aneurysm, [363](#)
- Splenomegaly, [329](#)
- Splenorrhaphy, [327](#)
- Split-thickness skin graft (STSG), [166](#)
  - allograft, [168](#)
  - autograft, [168](#)
  - thickness, [168](#)

- Spurling's sign, [525](#)
- Squamous cell carcinoma, [332–333](#)
- Stanford classifications, [471](#)
- Staple removal, [24f](#), [32](#), [32f](#)
- Steri-Strips, placement of, [32](#), [32f](#)
- Steroids, [85](#)
- Stick tie. *See* [Sutures ligature](#)
- Stitch
  - Connell's, [25](#), [25f](#)
  - Lambert, [25](#), [25f](#)
  - removal of, [32](#)
  - simple interrupted, [22](#), [22f](#)
  - simple running (continuous), [23](#), [23f](#)
  - subcuticular, [23](#), [23f](#)
  - vertical mattress, [23](#), [23f](#)
- "Stitch" abscess, [116](#)
- Stoma, [191](#)
- Stomach, [182–188](#)
  - gastric cancer, [185–187](#), [186f](#)
  - gastric physiology, [182](#)
  - gastric volvulus, [188](#)
  - gastroesophageal reflux disease, [182–184](#), [184f](#)
  - gastrointestinal stromal tumor, [187](#)
  - MALToma, [187–188](#)
- Stress gastritis, [179](#)
- Stress incontinence, [540](#)
- Stridor, [371](#)
- Stroke, [97](#)
- Subarachnoid hemorrhage (SAH), [523](#)
- Subclavian steal syndrome, [362](#)
- Subcuticular stitch, [23](#), [23f](#)
- Subdural hematoma, [517](#)

- Subluxation, [491](#)
- Submucosa, [65](#)
- Subtotal gastrectomy, [186](#), [186f](#)
- Succinylcholine, [127](#)
- Sucking chest wound, [150](#)
- Sugammadex, [126](#)
- Sulfamethoxazole-trimethoprim, [84](#)
- Sump pump, [61](#), [61f](#)
- Superficial burns, [166](#), [167](#), [168](#)
- Superficial spreading melanoma, [335](#)
- Superinfection, [111](#)
- Superior laryngeal nerve, [311](#)
- Superior mesenteric artery (SMA) syndrome, [194](#)
- Superior vena cava (SVC) syndrome, [10](#)
- Supination, [489](#)
- Supine position, [42](#)
- Supraglottic Lesions, [429](#)
- Surgeon's knot, [27](#), [27f](#)
- Surgical airway. See [Cricothyroidotomy](#)
- Surgical anatomy, [64–66](#)
- Surgical complications
  - abdominal compartment syndrome, [99](#)
  - aspiration pneumonia, [92](#)
  - atelectasis, [89](#)
  - cardiovascular
    - cerebro vascular accident, postoperative, [97](#)
    - myocardial infarction, [96–97](#)
  - DIC, [99](#)
  - endocrine
    - Addisonian crisis, [94–95](#), [95f](#)
    - diabetes insipidus, [96](#)
    - diabetic ketoacidosis, [94](#)

- SIADH, [95](#)
- gastrointestinal
  - blind loop syndrome, [93](#)
  - constipation, [93](#)
  - dumping syndrome, [93–94](#)
  - gastric dilatation, [92](#)
  - pancreatitis, postoperative, [92–93](#)
  - postvagotomy diarrhea, [93](#)
  - short bowel syndrome, [93](#)
- pseudomembranous colitis, [100](#)
- pulmonary embolism, [90–92](#)
- renal failure, postoperative, [97–98](#)
- respiratory failure, postoperative, [89–90](#)
- urinary retention, [99–100](#)
- Surgical hemostasis, [83–84](#), [83f](#), [84f](#)
- Surgical instruments, [12–18](#)
- Surgical intensive care, [336–447](#)
  - drugs, [341–342](#)
  - formula, [338](#)
  - hemodynamic monitoring, [344–345](#)
  - ICU, [337–338](#)
  - physiology, [342–343](#), [342–344](#)
- Surgical medications
  - antibiotics, [84–85](#)
  - heparin, [86](#)
  - miscellaneous agents, [87–88](#)
  - narcotics, [88](#)
  - other agents, [88](#)
  - steroids, [85](#)
  - warfarin, [87](#)
- Surgical most commons, [10–11](#)
- Surgical nutrition, [105–107](#)

- Surgical percentages, [11–12](#)
- Surgical positions, [42–43](#)
  - left lateral decubitus, [42](#), [42f](#)
  - lithotomy, [42](#)
  - pregnant patient, [43](#)
  - prone, [42](#)
  - reverse trendelenburg, [42](#), [42f](#)
  - right lateral decubitus, [42](#)
  - supine, [42](#)
  - trendelenburg, [42](#), [42f](#)
- Surgical prophylaxis, [119–120](#)
- Surgical respiratory care, [103–104](#), [103f–104f](#)
- Surgical syndromes, [8–10](#)
- Sutures
  - absorbable, [20](#)
  - catgut, [20–21](#)
  - classification of, [20](#)
  - ligature, [26](#), [26f](#)
  - materials for, [20](#)
  - nonabsorbable, [20](#)
  - PDS, [21](#)
  - pop-off, [26](#), [26f](#)
  - pursestring, [24](#), [24f](#)
  - retention, [26](#), [26f](#)
  - techniques, [22–26](#)
  - Vicryl®, [21](#)
- Sutures ligature, [26](#), [26f](#)
- Swan–Ganz (PA) catheter, [344](#)
- Sweetheart retractor, [19f](#)
- Swenson procedures, [385](#)
- Sympathetic ophthalmia, [163](#)
- Synchronous tumors, [129](#)

- Syndrome of inappropriate antidiuretic hormone (SIADH), [10](#), [95](#)
- Synthroid, [312](#)
- Syringomyelia, [526](#)
- Systemic inflammatory response syndrome (SIRS), [110](#)

## T

- T10, dermatome, [66](#)
- Tachycardia, [102](#)
- Tamoxifen, [286–287](#)
- Taper-point needle, [22](#), [22f](#)
- Tenosynovitis, [410](#)
- Tension pneumothorax, [150–151](#), [151f](#)
- Terminal ileum, [105](#), [106](#)
- Testicular cancer, [535–536](#)
- Testicular torsion, [537](#)
- Testicular vein, drainage of, [64](#)
- Tetanus, [117](#), [168](#)
- Therapeutic PT, [82](#)
- Third-degree burns. *See* [Full-thickness burns](#)
- Third-degree hemorrhoid, [231](#), [231f](#)
- Third-generation cephalosporins, [84](#)
- Third-spacing, [68–69](#)
- Thoracic great vessel injury, [156](#)
- Thoracic outlet syndrome (TOS), [10](#), [437](#)
- Thoracic surgery, [437–454](#)
  - chest wall tumors, [437](#)
  - diseases of esophagus, [448](#)
  - diseases of lungs, [440](#)
  - diseases of mediastinum, [445](#)
  - diseases of pleura, [439](#)
  - esophageal reflux, [450](#)
  - thoracic outlet syndrome, [437](#)

- Thoracodorsal nerve, [278](#), [279f](#)
- Thoracostomy tube, [56](#)
- Thrombocytopenia, [80](#), [328](#)
- Thrombotic thrombocytopenic purpura (TTP), [329](#)
- Thumbprinting, [122](#)
- Thyroid carcinoma, [314](#)
- Thyroid gland, [310–321](#)
  - anaplastic carcinoma, [317–318](#)
  - anatomy of, [310–311](#), [310f](#), [311f](#)
  - benign thyroid disease, [318–319](#)
  - follicular adenocarcinoma, [315–316](#)
  - Hürthle cell thyroid cancer, [316](#)
  - malignant thyroid nodules, [313–314](#)
  - medullary carcinoma, [316–317](#)
  - papillary adenocarcinoma, [314–315](#)
  - physiology of, [312](#)
  - thyroid carcinoma, [314](#)
  - thyroiditis, [319–320](#)
  - thyroid nodule, [312–313](#)
  - toxic multinodular goiter, [319](#)
- Thyroid isthmus, [311](#)
- Thyroiditis, [319–320](#)
- Thyroid nodule, [312–313](#)
- Thyroid-stimulating hormone (TSH), [312](#)
- Thyrotropin-releasing hormone (TRH), [312](#)
- Tibial pin, [490](#)
- Tibial plateau fracture, [496](#)
- Tibial “plateau” fracture, [496](#), [496f](#)
- Ticarcillin-clavulanic acid, [84](#)
- Tidal volume, [345](#)
- TIPS procedure, [250](#), [250f](#)
- Tissue perfusion, [107](#)

- Toldt, white lines of, [65](#)
- Tonicity, accounts for, [69](#)
- Toradol, [88](#)
- Total body surface area (TBSA), [166](#)
- Total gastrectomy, [186](#), [186f](#)
- Totally extra peritoneal approach (TEPA), inguinal hernia repair procedure, [141](#)
- Total parenteral nutrition (TPN), [106](#), [107](#)
- Toupet, for GERD, [184](#), [184f](#)
- Toxic megacolon, [238](#)
- Toxic multinodular goiter, [319](#)
- Toxic shock syndrome, [10](#)
- Tracheostomy, [54](#)
- Trans abdominal pre peritoneal (TAPP), inguinal hernia repair procedure, [141](#)
- Transcervical fracture, [496](#)
- Transfusion hemolysis, [80](#)
  - treatment for, [81](#)
- Transfusion reaction, [80](#)
- Transient ischemic attack, [359](#)
- Transplant complications, [487](#)
- Transplant surgery
  - basic immunology, [475](#)
  - immunosuppression, [475](#)
  - kidney transplant, [480](#)
  - organ preservation, [479](#)
  - overview of immunosuppression mechanisms, [478](#)
  - rejection, [479](#)
- Transurethral incision of prostate, [534](#)
- Transurethral resection of bladder, [532](#)
- Transurethral resection of prostate, [534](#)
- Transurethral resection of prostate (TURP), [50](#)
- Trauma, [11](#), [148–166](#)

- ATLS protocol, [148](#)
- facts, [159–164](#)
- penetrating neck injuries, [158–159](#), [158f–159f](#)
- primary survey, [148–155](#)
- secondary survey, [155–157](#)
- studies, [157–158](#)
- Trauma injuries and complications, [499](#)
- Trauma resuscitation fluid, [153](#)
- Traumatic subarachnoid hemorrhage, [518](#)
- Trendelenburg, [42](#), [42f](#)
- Trendelenburg operation, [91](#)
- Triangle of Calot, boundaries of, [252](#), [252f](#)
- Triple A repair, [51](#)
- Trophic tube feeds, [107](#)
- Trousseau's sign, [8](#), [75](#)
- Trousseau's syndrome, [10](#)
- Truncal vagotomy, [53](#), [53f](#), [177](#)
- T-tube, [56](#), [56f](#)
- Tube check, [193](#)
- Tube thoracostomy, [150](#)
- Tubular adenomas, [215](#)
- Tubulovillous adenomas, [215](#)
- Tumors
  - appendiceal, [202–203](#)
  - carcinoid, [203–206](#), [204f–205f](#)
  - hepatoblastoma, [400](#)
  - of liver, [241–244](#)
    - focal nodular hyperplasia, [242–243](#), [242f](#)
    - hepatic hemangioma, [243](#)
    - hepatocellular adenoma, [242](#)
    - hepatocellular carcinoma, [243–244](#)
  - neuroblastoma, [398](#)

- rhabdomyosarcoma, [400](#)
- small bowel, [196](#)
- Wilms' tumor, [397](#)
- Turcot's syndrome, [218](#)
- Type II hiatal hernia, [146](#)
- Tympanic membrane (TM) perforation, [415](#)

## U

- Ulcerative colitis (UC), [235–239](#)
  - anal involvement, [236](#)
  - anatomic distribution, [236](#)
  - bowel wall involvement, [236](#)
  - cancer risk, [237](#)
  - complications of, [237](#)
  - diagnostic tests, [237](#)
  - extraintestinal manifestations, [235](#)
  - incidence, [235](#)
  - initial symptoms, [236](#)
  - medical treatment of, [238](#)
  - mucosal findings, [237](#)
  - rectal involvement, [236](#)
  - route of spread, [236](#)
  - surgery, indications for, [238](#)
  - toxic megacolon, incidence of, [237](#)
- Ulcers
  - with burn injury, [171](#)
  - duodenal, [174–175](#)
  - perforated peptic ulcer, [176–177](#)
  - PUD, [173](#)
  - surgical, [127–128](#)
- Umbilical hernia, [139](#), [380](#)
- Unasyn, [85](#)

- Universal donor
  - for FFP, [80](#)
  - for PRBCs, [79](#)
- Urethra in females, finding of, [34](#), [34f](#)
- Urge incontinence, [540](#)
- Urinary retention, [99–100](#)
- Urinary tract infection (UTI), [111](#)
  - bacterial cause of, [11](#)
- Urine output
  - adult trauma patient, [159](#)
  - for burn patients, [170](#)
  - decreased, [102](#)
- Urology, [529–543](#)
  - benign prostatic hyperplasia, [533–535](#)
  - bladder cancer, [531–532](#)
  - calculus disease, [539–540](#)
  - differential diagnosis, [530](#)
  - epididymitis, [537–538](#)
  - erectile dysfunction, [538](#)
  - incontinence, [540](#)
  - priapism, [538](#)
  - prostate cancer, [532–533](#)
  - renal cell carcinoma (RC ), [530–531](#)
  - testicular cancer, [535–536](#)
  - urinary tract infection (UTI), [541](#)

## V

- Vagotomy
  - and antrectomy, [178](#), [178f](#)
  - and pyloroplasty, [177](#), [177f](#)
- Valentino's sign, [8](#)
- Vancomycin, [85](#)

- Varicocele, [529](#)
- Vascular surgery
  - abdominal aortic aneurysms, [356](#)
  - acute arterial occlusion, [355](#)
  - carotid vascular disease, [359](#), [362](#)
  - lower extremity amputations, [354](#)
  - median arcuate ligament syndrome, [358](#)
  - mesenteric ischemia, [358](#)
  - popliteal artery aneurysm, [364](#)
  - renal artery stenosis, [363](#)
  - splenic artery aneurysm, [363](#)
- Vasopressin, [249](#), [251](#), [342](#)
- Venous stasis ulcer, [128](#)
- Ventilation, [345](#)
- Ventilator associated pneumonia (VAP), [119](#)
- Ventral hernia, [138](#)
- Veress needle, [147](#)
- Vertical mattress stitch, [23](#), [23f](#)
- Vicryl® sutures, [21](#)
- Villous adenomas, [215](#)
- Virchow's node, [7](#), [185](#)
- Virchow's triad, [8](#), [8f](#), [90](#)
- Vitamin A deficiency, [106](#)
- Vitamin B12/folate deficiency, [105](#), [106](#)
- Vitamin C deficiency, [106](#)
- Vitamin K deficiency, [106](#)
- Vitamin K–dependent clotting factors, [106](#)
- Vitamins soluble, [106](#)
- Volarflexion, [489](#)
- Voluntary guarding, [132](#)
- von Willebrand's disease, [81](#)

## W

- Ward emergencies, causes of, [101–102](#)
- Warfarin (Coumadin), [82](#), [87](#)
- Warren shunt, [250–251](#), [250f](#)
- WDHA syndrome, [277](#)
- Weiss protocol, [76](#)
- Wenckebach phenomenon, [474](#)
- Wernicke's encephalopathy, [120](#)
- Wet-to-dry dressing, [54](#)
- Wheezing, postoperative, [90](#)
- Whipple procedure, [53](#), [53f](#), [276](#)
- Whipple's triad, [8](#), [277](#), [302](#)
- White lines of Toldt, [65](#), [210](#)
- Wilms' tumor, [397](#)
- Winged scapula, [279](#)
- Wolff–Parkinson–White, [474](#)
- Wound contraction, [404](#)
- Wound dehiscence, abdominal, [54](#)
- Wound healing, [404](#)
- Wound infection
  - protection from, [119](#)
- Wounds, [54–55](#)
  - clamp in, [84](#)
  - closure, [21–22](#), [54](#)
  - delayed primary closure, [54](#)
  - healing, [21–22](#), [54](#)
  - infections, [112–114](#)
  - operative, classification of, [113](#)
  - primary wound closure, [54](#)
  - secondary wound closure, [54](#)
  - wet-to-dry dressing, [54](#)
- Wound vac. See [Negative-pressure wound therapy \(NPWT\)](#)

- Wrist dorsiflexion, [489](#)

## Y

- Yankauer suction, [18](#), [18f](#)
- *Yersinia enterocolitica*, [202](#)

## Z

- Zinc deficiency, [106](#)
- Zollinger–Ellison syndrome (ZES), [10](#), [174](#), [303–306](#), [305f](#)
- Zosyn, [84](#), [85](#)